

## Postoperative Outcome of Robot-Assisted Transforaminal Lumbar Interbody Fusion: A Pilot Study

### Abstract

**Introduction:** Transforaminal lumbar interbody fusion (TLIF) surgery is well established for the treatment of discopathy, foraminal disc herniation, and recurrent disc herniation. At the Amiens university medical center, we have been using a robot-assisted technique for performing the TLIF. The purpose of this study is to evaluate the radiological and clinical outcome, specifically pain, of patients having undergone robot-assisted TLIF. **Materials and Methods:** We performed a retrospective analysis of prospectively collected data of patients having undergone minimally invasive (MI) robot-assisted TLIF between November 2014 and July 2018 in a French university medical center. In clinical consultations at 6 weeks, 12 months, and 24 months posttreatment, patients were assessed for back and leg pain (on a visual analog scale), breached screws, and sagittal parameters. **Results:** A total of 136 pedicle screws were inserted with robot guidance into 32 patients. Four of the patients required laminectomy before fusion. No pedicle breach occurred for 94% of the screws, and no joint violation was observed for 90%. Lordosis was improved in 78% of the cases. **Conclusions:** The robot provides valuable assistance during MI arthrodesis; it facilitates the surgical procedure by preplanning the trajectory, providing instantaneous navigation and tracking, and thus assure the accuracy of screw positioning.

**Keywords:** Degenerative, lumbar spine fusion, minimally invasive spine surgery, robot-assisted surgery, screw position, spinal instrumentation, spine disease, transforaminal lumbar interbody fusion

### Introduction

Lumbar spine fusion is widely used to treat various spinal conditions, including degenerative spinal diseases such as degenerative spondylolisthesis, recurrent disc herniation, and foraminal disc herniation. Various techniques for spinal fusion have been described, including transforaminal lumbar interbody fusion (TLIF) – a method that has gained popularity among spine surgeons over the past two decades. The open TLIF technique was first introduced by Harms and Jerszenszky in 1998.<sup>[1]</sup> A posterior approach is now generally used; it involves passing through the foramen to decompress the nerve root (without excessive retraction over the nerve roots) and then insertion of the intervertebral cage. Relative to the standard approach, a posterior approach is associated with a lower incidence of postoperative neuropathy and radiculitis.<sup>[2]</sup> In contrast, it is also associated with greater

morbidity, including blood loss, muscle degeneration (due to the extensive exposure), and an extended length of hospital stay.<sup>[3]</sup> To overcome these disadvantages, Foley *et al.* developed a minimally invasive TLIF approach (MI-TLIF) in 2003.<sup>[3]</sup> Lieber *et al.* recently compared robot-assisted TLIF with conventional TLIF in terms of intraoperative complications (e.g., hemorrhage, and the requirement for blood transfusion) and postoperative complications (e.g., pulmonary embolism, deep venous thrombosis, nerve root injuries, and dural tears).<sup>[4]</sup> In a previous report, we described the robot-assisted TLIF technique and cases of associated pedicle breach.<sup>[5]</sup>

The primary objective of the present study was to perform a descriptive retrospective analysis of patients having undergone robot-assisted TLIF at a French University Medical Center (Amiens, France) between November 2014 and July 2018.

Sultan Alsalmi<sup>1,2</sup>,  
Mohammad  
Alsofyani<sup>3</sup>,  
Abdulgadir  
Bugdadi<sup>4,5</sup>,  
Abdu Alkhairi<sup>6</sup>,  
Johann Peltier<sup>1</sup>,  
Michel Lefranc<sup>1</sup>

<sup>1</sup>Department of Neurosurgery, Amiens Picardie University Medical Center, Jules Verne University of Picardie, Amiens,

<sup>4</sup>Department of Neurosurgery, Faculty of Medicine, Sorbonne University, <sup>6</sup>Department of Neurosurgery, Faculty of Medicine, University Paris Descartes, Paris, France,

<sup>2</sup>Department of Neurosurgery, Imam Abdulrahman Bin Faisal University, Dammam,

<sup>3</sup>Department of Orthopedic, Faculty of Medicine, University of Hail, Hail, <sup>5</sup>Department of Surgery, Faculty of Medicine, Umm Al Qura University, Makkah Al Mukarramah, Saudi Arabia

### Address for correspondence:

Dr. Sultan Alsalmi,  
Department of Neurosurgery,  
Amiens University Medical  
Center, Amiens University,  
Avenue René Laennec, Salouel,  
F-80054 Amiens Cedex 1,  
Amiens, France.  
E-mail: sultan.alsalmi@hotmail.com

### Access this article online

Website: [www.asianjns.org](http://www.asianjns.org)

DOI: 10.4103/ajns.AJNS\_558\_20

### Quick Response Code:



This is an open access journal, and articles are distributed under the terms of the Creative Commons Attribution-NonCommercial-ShareAlike 4.0 License, which allows others to remix, tweak, and build upon the work non-commercially, as long as appropriate credit is given and the new creations are licensed under the identical terms.

For reprints contact: WKHLRPMedknow\_reprints@wolterskluwer.com

**How to cite this article:** Alsalmi S, Alsofyani M, Bugdadi A, Alkhairi A, Peltier J, Lefranc M. Postoperative outcome of robot-assisted transforaminal lumbar interbody fusion: A pilot study. Asian J Neurosurg 2021;16:759-64.

Submitted: 27-Dec-2020

Revised: 27-Jan-2021

Accepted: 02-Mar-2021

Published: 18-Dec-2021

## Materials and Methods

### Study design, population, and setting

We retrospectively studied prospectively collected data of patients having undergone TLIF, assisted by the ROSA® spine robot (Medtech, Montpellier, France) with a flat-panel computed tomography (FPCT) guidance O-arm® (Medtronic, Minneapolis, USA).

### Inclusion and exclusion criteria

The main inclusion criteria were age 18 or over, and surgery for a degenerative lumbar or sacral spinal disease (lumbar spondylolisthesis, recurrent lumbar disc herniation, foraminal disc herniation, or discogenic low back pain) for which TLIF was indicated. Patients with spine fractures were excluded from this study.

### Description of the technique

After general anesthesia, the patient was placed in the prone position on a Wilson frame mounted on a radiolucent spinal operating table. The abdomen was unsupported, and the spine was flexed to open up the interlaminar space. All pressure points were adequately padded. The O-arm FPCT device and the ROSA spine robot were installed to the right of the patient at an angle of 90° and 45°, respectively [Figure 1]. For the navigation system, a percutaneous reference frame was attached to the right posterior iliac crest for left-side disc pathology (and vice versa) through an incision parallel to the midline [Figure 1]. Next, a three-dimensional (3D) FPCT scan was acquired after covering the metallic part of the fiducial box attached to the robotic arm [Figure 2]. The 3D image was transferred from the O-arm CT scanner to the ROSA robot's workstation. The 3D trajectory for bilateral transpedicular screw placement was then planned and visualized on the workstation's screen [Figure 3]. The screw positioning parameters were chosen (along with

the screw length and width) so as not to breach the pedicle or damage the facet joint. The screw trajectories were planned such that they would provide enough space to work between the two heads of the screws, especially at the decompression side-and to align the heads of the screws as much as possible for easier rod insertion and a more solid construct [Figures 4 and 5]. The insertion of the screws, cage, and finally, the rod was carried out as described in our previous article.

## Results

### Demographic characteristics of the study population

Thirty-two patients underwent robot-assisted TLIF between November 2014 and July 2018. Twenty-eight patients underwent single-level arthrodesis, and four underwent two-level arthrodesis. For single-level arthrodesis, the most frequently concerned levels were L4–L5 ( $n = 14$  cases, 43.7%), L5–S1 ( $n = 11$ , 34.3%), and L3–L4 ( $n = 3$ , 9.3%). In accordance with the inclusion criteria, the indications for surgery were herniated foraminal disc, discogenic low back pain, recurrent disc herniation, isthmic/degenerative spondylolisthesis, and lumbar spinal stenosis [Table 1]. Four patients were operated on through an open approach as a result of severe, generalized stenosis; hence, complete laminectomy had to be performed before fusion. Details of the operating time and radiation exposure have been reported previously.<sup>[5]</sup>

**Table 1: Number of operated patients, by indication**

Diagnosis	Number of patients, <i>n</i> (%)
Recurrent disc herniation	6 (24)
Discogenic low back pain	5 (20)
Foraminal stenosis	5 (20)
Isthmic spondylolisthesis	4 (16)
Degenerative spondylolisthesis	4 (16)
Central stenosis	1 (4)

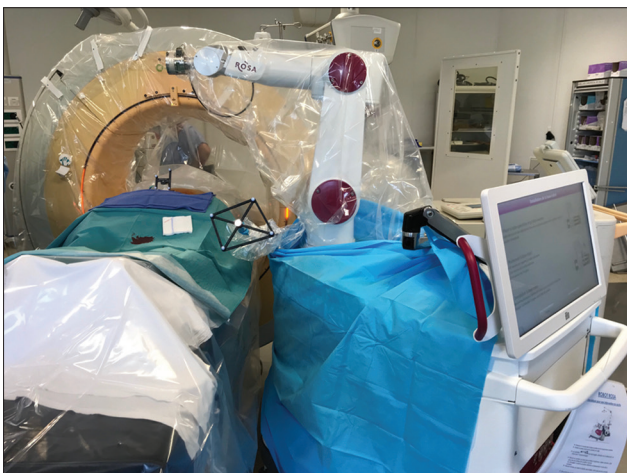

Figure 1: Installation of the patient, the O-arm computed tomography device and the ROSA® robot

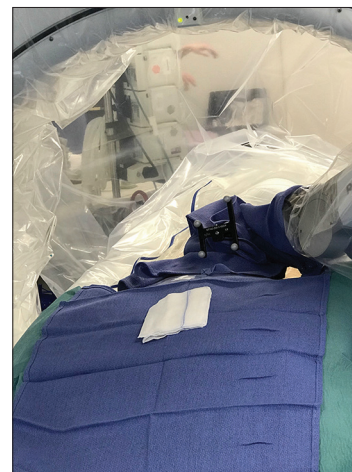

Figure 2: Covering the metallic part of the fiducial box attached to the robotic Arm through using large compress during the acquisition of the three-dimensional image



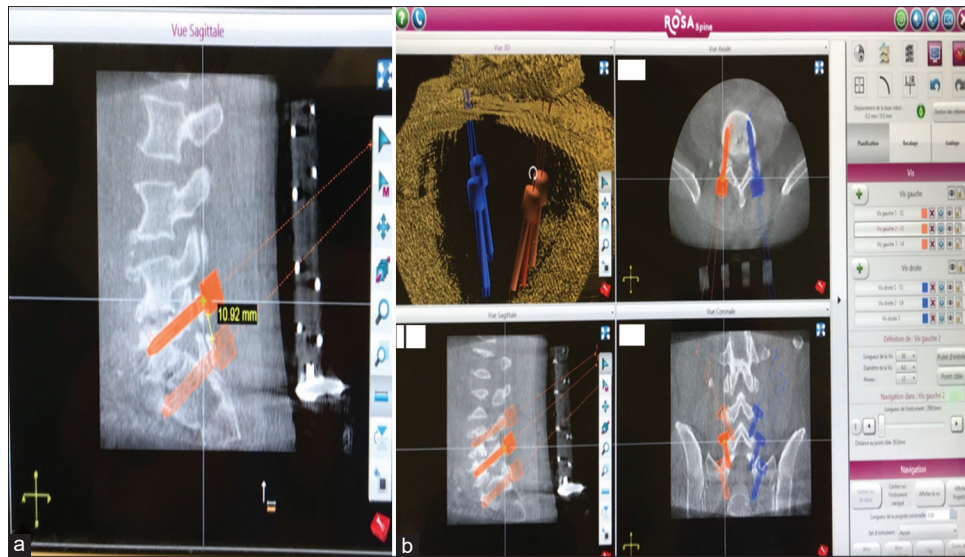


Figure 3: Preoperative planning images: (a) Measurement of the distance between the heads of two screws at the decompression side (red arrow); (b) A check to ensure that the heads of the two screws are not in contact with each other and that there is enough space between them (white arrows)

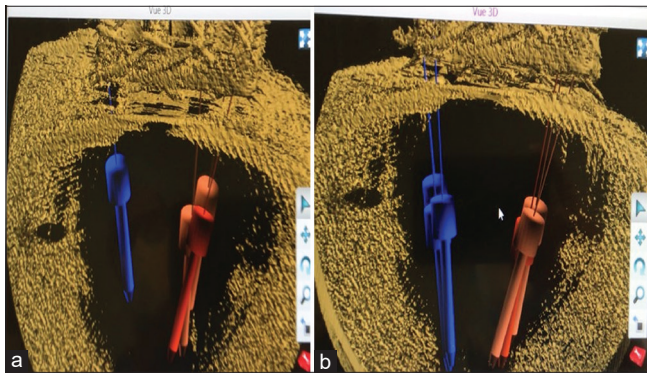


Figure 4: Three-dimensional views of maneuvers intended to align the heads of three screws without affecting the optimal trajectory, as thus to facilitate subsequent rod insertion. (a) Screw heads before alignment (white arrows); (b) after alignment (white arrows)

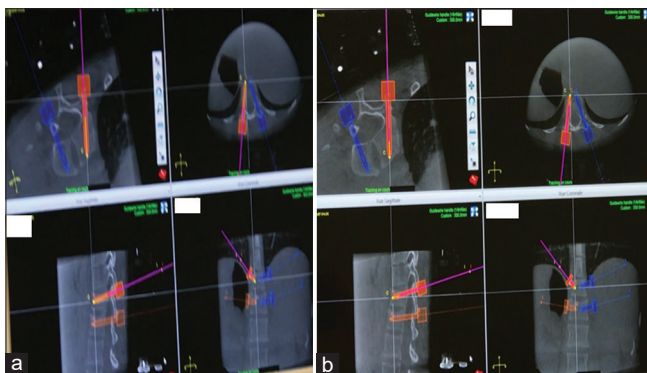


Figure 5: Inserting the Kirschner-wire with navigational guidance, along the yellow line (the preplanned trajectory). The purple line represents the navigated Kirschner wire insertion. (a) The Kirschner wire passes through the pedicle (arrow); (b) The K-wire arrives at the middle of the vertebrae

### Clinical outcome

The clinical outcomes have been reported for 24 of the 32 patients because eight of them have yet to complete 12

months of follow-up. Changes in pain levels were rated subjectively by the patient on a visual analog scale (VAS) before surgery and on the postoperative day 3.<sup>[6]</sup> Early and late pain reductions were defined as a reduction in pain within one and 2 years of surgery, respectively. We considered VAS  $\leq 3$  as a sign of pain relief and based on this criterion, 16 patients (66%) experienced early pain reductions, and eight (33%) experienced late reductions [Table 2]. At the 2-year consultation, 18 patients (75%) reported that they were satisfied with the degree of pain reduction. Of the six patients (18%) who were not satisfied, two were referred to a pain specialist, one was referred to a specialist in physical and rehabilitation medicine, and the three others were treated for neuropathic pain.

### Radiological measurements

A total of 136 screw placements were analyzed intraoperatively using the FPCT device and graded according to Ravi's classification [Table 3].<sup>[7]</sup> This radiologic assessment revealed that 128 screws (94%) were Ravi grade A, five (4%) were grade B, two (1%) were grade C, and two (1%) were grade D [Figure 4]. One of the two Ravi grade D screws was replaced during surgery, and the final intraoperative CT scan confirmed the improvement in the screw's position [Figure 5]. Artifacts on the FPCT image prevented adequate visualization of the other grade D screw (in a different patient), which was revealed by a standard postoperative CT scan. The screw was not replaced because it had not triggered any symptoms.

For the 68 operated vertebral levels, the joint violation was graded according to Shah's classification [Table 4 and Figure 6].<sup>[8]</sup> Sixty-one joints (90%) were grade 1, five (7%) were grade 2, and two (3%) were grade 3.

**Table 2: Visual Analogue Scale score in pre and postoperative**

VAS in preoperative	VAS in postoperative	
	Early	Late
3	1	
3	0	
0	3	
10	8	3
8	5	3
5	3	
4	2	
6	3	
4	2	
7	2	
7	1	
8	5	2
4	2	
6	3	
8	8	3
4	4	1
5	8	2
4	1	
2	4	1
7	2	
7	3	
10	6	4
4	2	
6	3	

VAS – Visual analogue scale

**Table 3: Ravi’s pedicle breach classification**

Grade	Description
A	Screw inside the pedicle
B	Pedicle cortex perforation up to 2 mm
C	Pedicle cortex breach from 2.1-4 mm
D	Pedicle cortex breach >4 mm

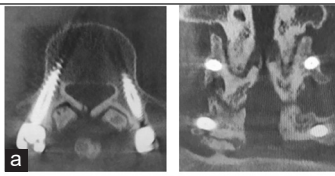
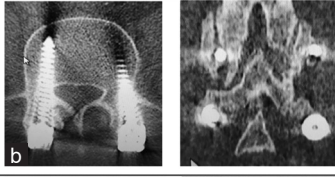

**Table 4: Shah’s joint violation classification**

Grade	Facet joint violation
1	No
2	Unilateral
3	Bilateral

Finally, we were able to reduce lordosis in 26 of the 32 patients (78%). However, lordosis worsened in four patients (13%) and was unchanged in two (7%) of them [Table 5].

### Discussion

The TLIF approach was introduced by Harms and Jerszenszky in 1998.<sup>[1]</sup> This technique involves a three-column fusion through a unilateral, transforaminal trajectory and a single posterior approach. The risk of postoperative radiculitis is greatly decreased because of the lesser need for nerve root retraction compared to previous techniques.<sup>[9]</sup>

Shah classification	Characteristic	Examples
Grade 1	No joint violation	
Grade 2	Unilateral violation	
Grade 3	Bilateral violation	

Shah classification of facet joint violation with cases examples.

**Figure 6: Examples of joint violation grades, according to Shah’s classification. (a) Grade 1; (b) Grade 2; (c) Grade 3**

Given the morbidity associated with the traditional open TLIF (primarily blood loss and delayed recovery), alternative approaches (such as MI-TLIF) have been adopted. This MI technique is associated with less blood loss, lower postoperative pain levels, more rapid recovery, and lower health costs.<sup>[10,11]</sup>

In contrast to the open approach (in which anatomic landmarks can be visualized and thus facilitate the use of the correct instrumentation), the “semi-blind” percutaneous technique raises issues of pedicle breach and joint violation.<sup>[12]</sup> The emergence of robot-assisted spine surgery can address these issues and optimize the screw’s trajectory and final position. Here, we have presented our experience with assisted MI-TLIF using the ROSA® spine robot and reported the short-term clinical and radiological outcomes.

We found that one of the great benefits of robotic guidance (relative to the conventional percutaneous technique) is the ability to predict intraoperative problems. One difficulty in MI-TLIF is estimating the distance between two screws at the decompression side. In the conventional percutaneous technique, it is impossible to calculate the distance between the two screw heads before insertion. However, robot guidance makes it possible to properly plan the screw trajectory so that there is enough space for the insertion of instruments (e.g., the high-speed drill or the Kerrison rongeur forceps) and the intervertebral cage [Figure 4]. Furthermore, we were able to align the heads of the screws without affecting the optimal trajectory, thereby avoiding difficulties when the rods were inserted [Figure 4]. The ability to plan, navigate, and track the trajectory with the robot, decreases the risk of screw malpositioning and pedicle breach [Figure 6]. We believe that in difficult cases with distorted anatomy, it is impossible to achieve satisfactory results (in terms of screw

**Table 5: Segmental lordosis evaluation in pre and postoperative**

Preoperative lordosis	Postoperative lordosis
44	48
41	48
54	66
30	38
26	41
32	48
41	46
50	57
58	59
49	51
59	62
32	42
55	64
33	45
38	48
59	46
40	30
48	39
39	39
35	45
44	45
40	45
66	68
50	57
31	36
49	51
74	60
47	54
53	59
57	59
48	49
40	40

positioning and avoidance of joint violation) without using the navigation function.

Ringel *et al.* reported a higher incidence of pedicle breach (according to the Gertzbein Robbins classification) for robot-assisted surgery than for freehand surgery (93% and 85%, respectively).<sup>[13]</sup> With regard to pedicle breach, studies have shown that 93.7% of the screws were of Ravi grade A, whereas 5.7% and 0.6% were of Ravi grade B, and C, respectively.<sup>[14]</sup> Kim *et al.* reported the absence of joint violation in a robot-assisted group.

Regarding different types of percutaneous approaches, Ohba *et al.* found that using intraoperative CT with navigation significantly reduced the risk of joint violation compared to the fluoroscopy technique (risk: Of 3.8% [3/79] vs. 30.5% [11/36]).<sup>[15]</sup> In addition, Yson *et al.* have confirmed the benefits of using a navigation system, especially in cases of the percutaneous approach and its ability to significantly decrease the risk of joint violation (only 4% of the joint violation [5/125] cases were of grade one).<sup>[16]</sup>

On the other hand, Lau *et al.* reported that intraoperative CT with navigation did not decrease the risk of joint violation.<sup>[17]</sup> They showed that the risk of joint violation was 10.8% (4 of 37 patients) in the navigation group and 4.8% (5 of 105 patients) in the fluoroscopic group.<sup>[17]</sup>

The correction of lumbar lordosis is critical for the prevention of flatback syndrome and adjacent segment disease. These undesirable outcomes could be a consequence of lumbar hypolordosis and sagittal imbalance.<sup>[18-20]</sup> The best approach for lordosis correction is the anterior approach (with the use of lordotic cages with a large angle). However, in the present series, with the posterior approach, lordosis was reduced in 78% of the cases, while it worsened in 15%, and remained unchanged in 6% of them. Some MI-TLIF techniques are capable of correcting lordosis in a high proportion of cases.<sup>[5,21]</sup>

There are several limitations to the application of robotic assistance in this type of surgery. First, is the high cost of the robot approximately (€700,000), making it available in only large institutions/cities. Second, preoperative planning is not possible with the ROSA robot's software, which we think would save a lot of time. Third, there is no way to merge the data from CT and magnetic resonance imaging (as is possible for the brain version). Finally, the system lacks the ability to simulate the optimal sagittal balance, which we believe would be very valuable in giving the surgeon an idea of how much lordosis has to be restored or at least how much of the sagittal balance will be improved at the operation site.

The initial challenges associated with the use of the robotic system include the application of the toothed cannula for drilling (to avoid the skiving effect). We, therefore, replaced it with a nontoothed cannula, with modification of the drilling maneuver (a very high-speed in-and-out movement, several times until penetration of the whole pedicle). Moreover, especially for the ROSA robot, the problem of registration related to the exposed metal part attached to the mire was resolved by adequately covering it with a large blue gauze, as shown in Figure 2.

This pilot study has several limitations. First was the uneven follow-up of patients, as not all the patients completed 12 months at the time of this article preparation. Second, the only clinical outcome measured was the pain score using the VAS. Third, due to the small number of patients, we included a variety of degenerative conditions operated using robot assistance. Fourth, the robot-assisted technique and the conventional percutaneous method were not formally compared to reach a solid conclusion on equality, superiority, or inferiority of the former method. The goal of this pilot study was to evaluate the feasibility of the robot-assisted technique and acceptability of results before a formal comparison can be made with the percutaneous technique. Future studies, including a larger series of patients, should, therefore, compare the robotic technique with the conventional



percutaneous method. Furthermore, a spine-specific outcome to evaluate the quality of life, such as the Oswestry disability index, should be used.

## Conclusions

Lumbar spine fusion is now a widely accepted treatment option for various spinal diseases. MI-TLIF is increasingly used to reduce the postoperative morbidity associated with open techniques. Large prospective studies or retrospective reviews are needed to formally compare various outcomes in robot-assisted TLIF versus conventional percutaneous surgery. However, based on our experience, robot-assisted MI-TLIF facilitates the surgical procedure and helps to improve the accuracy and outcomes.

## Financial support and sponsorship

Nil.

## Conflicts of interest

There are no conflicts of interest.

## References

- Harms JG, Jaszszky D. Posterior lumbar interbody fusion in unilateral transforaminal technique. *Oper Orthop Traumatol*. 1998;10:90-102. German. doi: 10.1007/s00064-006-0112-7. PMID: 17332991.
- Hackenberg L, Halm H, Bullmann V, Vieth V, Schneider M, Liljenqvist U. Transforaminal lumbar interbody fusion: A safe technique with satisfactory three to five year results. *Eur Spine J* 2005;14:551-8.
- Foley KT, Holly LT, Schwender JD. Minimally invasive lumbar fusion. *Spine (Phila Pa 1976)* 2003;28:S26-35.
- Lieber AM, Kirchner GJ, Kerbel YE, Khalsa AS. Robotic-assisted pedicle screw placement fails to reduce overall postoperative complications in fusion surgery. *Spine J* 2019;19:212-7.
- Chenin L, Capel C, Fichten A, Peltier J, Lefranc M. Evaluation of screw placement accuracy in circumferential lumbar arthrodesis using robotic assistance and intraoperative flat-panel computed tomography. *World Neurosurg* 2017;105:86-94.
- Ohnhaus EE, Adler R. Methodological problems in the measurement of pain: A comparison between the verbal rating scale and the visual analogue scale. *Pain* 1975;1:379-84.
- Ravi B, Zahrai A, Rampersaud R. Clinical accuracy of computer-assisted two-dimensional fluoroscopy for the percutaneous placement of lumbosacral pedicle screws. *Spine (Phila Pa 1976)* 2011;36:84-91.
- Jia L, Yu Y, Khan K, Li F, Zhu R, Zeng Z, *et al.* Superior facet joint violations during single level minimally invasive transforaminal lumbar interbody fusion: A preliminary retrospective clinical study. *Biomed Res Int* 2018;2018:6152769.
- Humphreys SC, Hodges SD, Patwardhan AG, Eck JC, Murphy RB, Covington LA. Comparison of posterior and transforaminal approaches to lumbar interbody fusion. *Spine (Phila Pa 1976)* 2001;26:567-71.
- Schwender JD, Holly LT, Rouben DP, Foley KT. Minimally invasive transforaminal lumbar interbody fusion (TLIF): Technical feasibility and initial results. *J Spinal Disord Tech* 2005;18 Suppl:S1-6.
- Rosenberg WS, Mummaneni PV. Transforaminal lumbar interbody fusion: Technique, complications, and early results. *Neurosurgery* 2001;48:569-74.
- Babu R, Park JG, Mehta AI, Shan T, Grossi PM, Brown CR, *et al.* Comparison of superior-level facet joint violations during open and percutaneous pedicle screw placement. *Neurosurgery* 2012;71:962-70.
- Ringel F, Stür C, Reinke A, Preuss A, Behr M, Auer F, *et al.* Accuracy of robot-assisted placement of lumbar and sacral pedicle screws: A prospective randomized comparison to conventional freehand screw implantation. *Spine (Phila Pa 1976)* 2012;37:E496-501.
- Kim HJ, Jung WI, Chang BS, Lee CK, Kang KT, Yeom JS. A prospective, randomized, controlled trial of robot-assisted vs freehand pedicle screw fixation in spine surgery. *Int J Med Robot* 2017;13:e1779.
- Ohba T, Ebata S, Fujita K, Sato H, Haro H. Percutaneous pedicle screw placements: Accuracy and rates of cranial facet joint violation using conventional fluoroscopy compared with intraoperative three-dimensional computed tomography computer navigation. *Eur Spine J* 2016;25:1775-80.
- Yson SC, Sembrano JN, Sanders PC, Santos ER, Ledonio CG, Polly DW Jr. Comparison of cranial facet joint violation rates between open and percutaneous pedicle screw placement using intraoperative 3-D CT (O-arm) computer navigation. *Spine (Phila Pa 1976)* 2013;38:E251-8.
- Lau D, Terman SW, Patel R, La Marca F, Park P. Incidence of and risk factors for superior facet violation in minimally invasive versus open pedicle screw placement during transforaminal lumbar interbody fusion: A comparative analysis. *J Neurosurg Spine* 2013;18:356-61.
- Yamasaki K, Hoshino M, Omori K, Igarashi H, Nemoto Y, Tsuruta T, *et al.* Risk factors of adjacent segment disease after transforaminal inter-body fusion for degenerative lumbar disease. *Spine (Phila Pa 1976)* 2017;42:E86-92.
- Recnik G, Košak R, Vengust R. Influencing segmental balance in isthmic spondylolisthesis using transforaminal lumbar interbody fusion. *J Spinal Disord Tech* 2013;26:246-51.
- Glassman SD, Bridwell K, Dimar JR, Horton W, Berven S, Schwab F. The impact of positive sagittal balance in adult spinal deformity. *Spine (Phila Pa 1976)* 2005;30:2024-9.
- Harms J, Rolinger H. A one-stager procedure in operative treatment of spondylolistheses: Dorsal traction-reposition and anterior fusion (author's transl). *Z Orthop Ihre Grenzgeb* 1982;120:343-7.