



# Whole brain 7T-fMRI during pelvic floor muscle contraction in male subjects

Ilse M. Groenendijk<sup>1</sup>  | Sven P. R. Luijten<sup>1</sup> | Chris I. de Zeeuw<sup>2,3</sup> |  
Joan C. Holstege<sup>2</sup> | Jeroen R. Scheepe<sup>1</sup> | Wietske van der Zwaag<sup>4</sup> | Bertil F. M. Blok<sup>1</sup> 

<sup>1</sup>Department of Urology, Erasmus Medical Center, Rotterdam, The Netherlands

<sup>2</sup>Department of Neuroscience, Erasmus Medical Center, Rotterdam, The Netherlands

<sup>3</sup>Netherlands Institute for Neuroscience, Amsterdam, The Netherlands

<sup>4</sup>Spinoza Centre for Neuroimaging, Amsterdam, The Netherlands

## Correspondence

Ilse M. Groenendijk, Department of Urology, Erasmus Medical Center, Wytemaweg 80, Room NA-1524, 3015 CN Rotterdam, The Netherlands.  
Email: i.groenendijk@erasmusmc.nl

## Funding information

Nederlandse Organisatie voor Wetenschappelijk Onderzoek—Aard en Levenswetenschappen; European Research Council-Advanced Grant—Proof Of Concept Grant; EU-Neurotime; Zon-MW and Stichting Urologisch Wetenschappelijk Onderzoek; Zorg Onderzoek Nederland en Medische Wetenschappen; Koninklijke Nederlandse Akademie van Wetenschappen

## Abstract

**Aim:** The primary aim of this study is to demonstrate that 7-tesla functional magnetic resonance imaging (7T-fMRI) can visualize the neural representations of the male pelvic floor in the whole brain of a single subject.

**Methods:** In total, 17 healthy male volunteers (age 20-47) were scanned in a 7T-MRI scanner (Philips Achieva). The scanning protocol consisted of two functional runs using a multiband echo planar imaging sequence and a T1-weighted scan. The subjects executed two motor tasks, one involving consecutive pelvic floor muscle contractions (PFMC) and a control task with tongue movements.

**Results:** In single subjects, results of both tasks were visualized in the cortex, putamen, thalamus, and the cerebellum. Activation was seen during PFMC in the superomedial and inferolateral primary motor cortex (M1), supplementary motor area (SMA), insula, midcingulate gyrus (MCG), putamen, thalamus, and in the anterior and posterior lobes of the cerebellum. During tongue movement, activation was seen in the inferolateral M1, SMA, MCG, putamen, thalamus, and anterior and posterior lobes of the cerebellum. Tongue activation was found in the proximity of, but not overlapping with, the PFMC activation. Connectivity analysis demonstrated differences in neural networks involved in PFMC and tongue movement.

**Conclusion:** This study demonstrated that 7T-fMRI can be used to visualize brain areas involved in pelvic floor control in the whole brain of single subjects and defined the specific brain areas involved in PFMC. Distinct differences between brain mechanisms controlling the pelvic floor and tongue movements were demonstrated using connectivity analysis.

## KEYWORDS

7 tesla, brain mapping, fMRI, high-field imaging, pelvic floor, primary motor cortex, single subject

Ilse M. Groenendijk and Sven P. R. Luijten contributed equally.

This is an open access article under the terms of the Creative Commons Attribution-NonCommercial License, which permits use, distribution and reproduction in any medium, provided the original work is properly cited and is not used for commercial purposes.

© 2019 The Authors. *Neurourology and Urodynamics* published by Wiley Periodicals, Inc.

## 1 | INTRODUCTION

Pelvic floor disorders (PFDs), such as urinary and fecal incontinence as well as pelvic organ prolapse, are highly prevalent in both men and women.<sup>1</sup> Given the increase of PFD symptoms with increasing age and the steady increase in life expectancy, PFD currently forms a major healthcare problem with significant economic and social burden.<sup>1,2</sup>

The pelvic floor musculature and pelvic organs are innervated by the pudendal and pelvic nerves, the activity of which is controlled by various parts of the central nervous system. Indeed, over the past decades, different studies using a variety of imaging techniques have revealed that many different brain areas are involved in voluntary pelvic floor muscle contraction (PFMC).<sup>3-8</sup> In healthy volunteers, group analyses showed that the primary motor cortex, supplementary motor area (SMA), insula, thalamus, and cerebellum can all be activated during PFMC.<sup>3,4,8,9</sup> Voluntary control of the pelvic floor must be distinguished from involuntary control of the pelvic floor during continence, which is controlled by separate central pathways.<sup>3</sup>

Interestingly, patients suffering from PFD may show different activations of the central nervous system during PFMC compared with healthy volunteers.<sup>10,11</sup>

fMRI studies using 1.5- or 3-tesla (T) magnets typically study blood oxygen level-dependent (BOLD) responses in groups of subjects, which requires additional smoothing to compensate for the variability of anatomical structures. Obtaining reliable single-subject responses requires higher signal-to-noise ratio (SNR) and BOLD sensitivity. Therefore, the use of dynamic brain imaging as a diagnostic tool in individual PFD patients had so far only limited value in daily clinical practice.

Recently, high-resolution (voxel size  $\sim 1$  mm<sup>3</sup>) fMRI at increased field strengths (7T) has led to significant improvement in the achievable spatial resolution.<sup>12</sup> The increases in both SNR and BOLD signal at high fields<sup>12</sup> make single subject imaging possible.<sup>13</sup> Furthermore, 7-tesla functional magnetic resonance imaging (7T-fMRI) has been used successfully to map digit representations in individuals.<sup>14</sup> With state-of-the-art 7T-fMRI, one can obtain a higher resolution BOLD signals from cortical to cerebellar regions simultaneously.<sup>15</sup>

The primary aim of this study is to demonstrate that 7T-fMRI can visualize the neural representations of the male pelvic floor in the whole brain of a single subject. Secondary aims are to define the involved brain areas in male pelvic floor control and to compare the individual results with our group results in the context of the available literature. Furthermore, we aimed to study the differences of functional connectivity of the involved brain areas between both tasks. Movements of tongue muscles were

chosen as a control task because this midline motor task is mainly involved in different, well-automated voluntary behaviors such as eating and speaking.

## 2 | MATERIALS AND METHODS

### 2.1 | Subjects

Approval for this study was given by the Medical Ethics Committee of the Erasmus Medical Center Rotterdam (MERC 2015-451). All included subjects provided written informed consent. A total of 17 healthy right-handed male volunteers (mean age 29.6; standard deviation  $\pm 7.8$  years) participated in this study. We limited our study to a single sex, since the male and female pelvic floor motor control should be anatomically distinguished and differences in the central control have not been fully identified.<sup>16</sup> Furthermore, our study is the first to use 7T-fMRI to study pelvic floor representations in single subjects. Given the exploratory design, a homogeneous study population was desired. Subject exclusion criteria were any known impairment of urogenital or tongue motor innervation; current or known neurological, psychiatric or urological disorder(s) and contraindications for MRI.

### 2.2 | Stimuli and functional paradigm

All subjects completed the same scanning protocol, consisting of two functional runs followed by a T<sub>1</sub>-weighted anatomical scan. Functional runs consisted of two motor tasks (pelvic floor contraction and tongue movement), performed using a block paradigm. Before the scanning session, all subjects underwent a training session in a mock scanner to ensure correct task execution. During this training session, motor tasks were performed as described below. For the task “pelvic floor muscle contraction,” subjects were visually cued to strain their pelvic floor by contracting their anal sphincter or perineum. To prevent patients from contracting the gluteal muscles, they were instructed to lay still on the MRI bed. The motor task “tongue movement” required subjects to perform horizontal tongue movements. During this condition, subjects were instructed to keep their mouths closed by passively resting the lips and jaws together. Cues were generated in MATLAB using Psychtoolbox (Brainard, 1997)<sup>17</sup> and presented on a 32-inch BOLD screen (Cambridge Research Systems, Rochester, UK). The active condition was indicated by the text “MOVE” and the rest condition by a fixation cross “+.” The PFMC task consisted of an active condition of 21.5 s, in which the subject was instructed to repeatedly contract their pelvic floor followed by 19.5 s of rest, this cycle was repeated 12 times with an

additional rest condition at the start of the run, resulting in a total scan time of 500 s. The tongue movement task consisted of an active condition of 10 s followed by a rest condition of 10 s. This cycle was repeated 24 times with an additional rest condition at the start of the run, resulting in a total scan time of 490 s.

## 2.3 | Data acquisition

All data were acquired on a 7T-MRI scanner (Philips Achieva) using a volume transmit coil and a 32-channel receive coil (Nova Medical). Functional data were acquired using a multiband echo planar imaging (mb-EPI) sequence with multiband factor 2.<sup>18</sup> Whole brain coverage with the exception of the most inferior regions of the cerebellum and the caudal brainstem was achieved using the following parameters: voxel size:  $1.77 \times 1.77 \times 1.75 \text{ mm}^3$ , matrix size:  $104 \times 127$ ; FOV =  $184 \times 223 \text{ mm}$ ; number of slices: 70, TR/TE = 2000/25 ms; flip angle =  $70^\circ$ ; in-plane SENSE factor R = 3. Whole brain anatomical data were acquired using the MPRAGE sequence with the following parameters: voxel size  $0.7 \times 0.7 \times 0.7 \text{ mm}^3$ , matrix size:  $352 \times 353$ , FOV = 246 mm; number of slices: 249; TR/TE = 4.4/1.97 s, SENSE factors R = 1.6 (anterior-posterior) and R = 1.5 (right-left); total acquisition time 8'35". To account for the signal loss in infratentorial areas, a dielectric pad of calcium titanate ( $\text{CaTiO}_3$ ) was placed just below theinion at the back of the subjects' heads.<sup>19</sup>

## 2.4 | Data preprocessing

All data were reconstructed on an offline workstation using dedicated reconstruction software (Recon Frame; Gyrotools, Zürich, Switzerland). Further data processing was done in SPM12 (Wellcome Trust Center for Neuroimaging, London, UK). Preprocessing steps included joint image realignment of the functional runs, coregistration of the anatomical image to the resulting mean functional image and smoothing of functional data with a Gaussian kernel (FWHM 2.5 mm).

## 2.5 | Data analysis

For the extraction of the peak activation coordinates, anatomical and functional data were normalized to the standard brain template of the Montreal Neurological Institute (MNI152).

First-level statistical analysis was conducted using the general linear model. Each functional task was modeled as a boxcar convolved with a canonical hemodynamic response function and its temporal derivative as basic functions. Realignment parameters were added as nuisance regressors to account for confounding motion

effects. In single subjects, activation maps were thresholded at  $P < .05$  voxel-based family-wise error, if clusters were not found, thresholds were changed to  $P < .001$  (only in putamen and thalamus results). Second-level statistical analysis was conducted using a one-sample *t* test on individuals' task responses. Activation maps were thresholded at  $P < .001$  uncorrected for multiple comparisons, if the cluster was not found, the threshold was changed to  $P < .005$  uncorrected. Both single subject and group level cortical activation maps were projected on inflated cortical surfaces created in Freesurfer and sampled halfway the gray matter (projfrac = 0.5). To aid the inflation process, all images were first bias corrected (bias FWHM = 18, sampling distance = 2) and resliced to 1-mm isotropic in SPM.

## 2.6 | Functional connectivity analysis

Connectivity analysis was performed by calculating the correlation between time series from different regions of interest (ROIs) in each single subject. ROIs were isolated using individuals' contrast images. Where necessary, for example, between primary motor and sensory regions, merged ROIs were manually separated in ITK-SNAP. Subsequently, voxel time series were extracted from each ROI per single subject and denoised for signal arising from white matter, gray matter, and cerebrospinal fluid using linear regression. Furthermore, the task model was added as a regressor of no interest. Connectivity was defined as the linear correlation between time series of different ROIs, which was computed with the Pearson's correlation coefficient. Single subject correlation matrices were used to compute a mean correlation matrix.

To assess the overlap of clusters of both tasks in specific brain areas, the dice index was calculated using the extracted ROIs of the single subjects. The dice index was calculated for overlap in the M1, SMA, insula, and cerebellum ROIs.

## 3 | RESULTS

The scanning protocol was completed in all 17 subjects. Data concerning four subjects were excluded due to motion artefacts (>1 mm displacement), yielding a total of 13 subjects for in-depth analyses.

### 3.1 | Single subject and group analyses following PFMC

PFMC resulted in significant activation of various different brain regions following analyses of both single

**TABLE 1** Results of group activation whole brain (MNI) with height threshold  $T = 3.93$   $P < .001$  uncorrected

Region	Hemisphere	Pelvic				Tongue			
		x	y	z	Peak T	x	y	z	Peak T
SupMed M1	L	-12	-26	66	8.77	-	-	-	-
	R	12	-24	66	5.79	-	-	-	-
InfLat M1	L	-48	-2	52	3.33*	-54	-8	40	8.31
	R	42	-2	54	3.72*	62	4	28	7.62
SMA	L	-2	-16	68	6.56	-2	-2	60	4.03
	R	2	-6	64	7.62	6	0	64	5.12
MCG	L	-4	-6	46	5.61	-2	2	38	3.20*
	R	8	-4	46	4.83	10	14	40	3.60*
Insula	L	-32	0	12	6.28	-34	-10	14	3.63*
	R	46	4	2	6.10	38	-2	12	6.01
Putamen	L	-26	-8	12	12.98	-28	-4	-6	3.85*
	R	28	-4	14	9.93	28	2	-6	5.39
Thalamus	L	-12	-16	6	5.11	-14	-20	0	5.86
	R	10	-16	8	4.13	12	-16	0	7.28
Cerebellum	L	-16	-48	-14	5.29	-20	-60	-24	8.28
	R	10	-46	-10	3.91*	20	-64	-20	7.06

Abbreviations: InfLat, inferolateral; M1, primary motor cortex; MCG: midcingulate gyrus; SMA, supplementary motor area; Sup Med, superomedial.

\* $T = 3.05$   $P < .005$  uncorrected

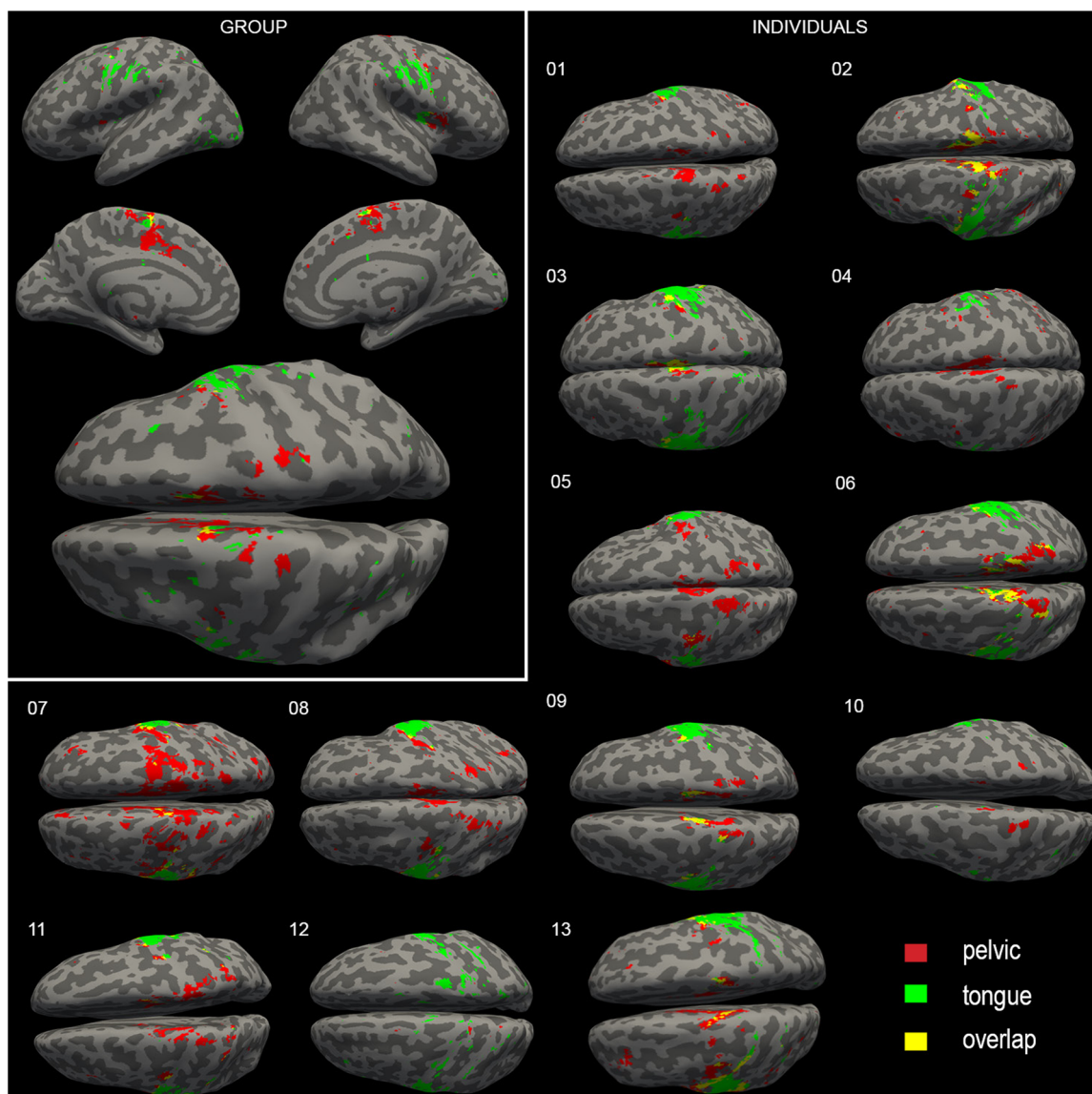
subjects and groups (for group results: Table 1). The superomedial primary motor cortex (M1) was activated in all subjects. In the group analysis, this cluster was split into two separate clusters, one more anterior and the other more posterior on M1 (Figure 1). Moreover, on M1, a second, more inferolateral cluster was found bilaterally in 11 out of 13 subjects. This inferolateral M1 cluster was also activated bilaterally in the group analysis (Figure 1). In 11 subjects, active clusters were found in the putamen (eight bilateral/three unilateral). Thalamus activation was found in 10 subjects (five bilateral/five unilateral). In group analysis, this resulted in combined activation of the putamen and the thalamus in both hemispheres (Figure 2). Concerning the cerebellum, activation in lobule IV was seen bilaterally in seven subjects and unilaterally in one subject (indicated by circles, Figure 3). More posterior, in lobule VI, an active cluster was found bilaterally in six subjects and unilateral in five subjects (Figure 3). In the posterior lobe of the cerebellum, specifically in lobule VIII, active clusters were found during PFMC in two subjects bilaterally and in six subjects unilaterally (data not shown). In the group analysis, cerebellar activation was found in lobule IV bilaterally, comparable with the single subject results. The cluster seen in single subjects in lobule VI was found unilateral in the left hemisphere of the cerebellum in the group analysis. Group analysis did not show activation in lobule VIII.

### 3.2 | Connectivity analyses following PFMC

Connectivity analysis was performed in the nine individuals who showed active voxels in all ROIs except for the thalamus, the activity of which was not present in a sufficient number of subjects to include it as an ROI in this analysis. Figure 4 shows the results of the connectivity analysis. Superomedial M1 was highly correlated with the SMA and less correlated with the other ROIs. SMA was correlated with superomedial M1, but also other cortical ROIs like the MCG, the insula, and the inferolateral M1 during PFMC.

### 3.3 | Activation during tongue movements

Tongue movements resulted in large active clusters lateral of M1 in all subjects (Figure 1). The SMA was found active in all but three subjects. In four subjects, tongue movements resulted in bilateral activation in the putamen, and in one subject the putamen was activated unilaterally. were shown in four subjects due to activation in the putamen bilaterally and in one subject unilaterally. In six subjects, bilateral thalamus activation was found, and in four subjects unilaterally (Figure 2). Cerebellar activation during tongue movement in single subjects was found consistently in lobule VI bilaterally.



**FIGURE 1** Results of both PFMC and tongue movement tasks are presented on the cortex. Left upper corner: Inflated MNI brain representing group analysis ( $P < .005$  uncorrected). The rest: brain-inflations of single subjects representing single subject activation ( $P < .05$  FEW). MNI, Montreal Neurological Institute; PFMC, pelvic floor muscle contractions

In eight subjects, bilateral activation was also found in lobule VIII in the posterior cerebellum and in two subjects unilaterally (Figure 3). Group analysis showed activity in M1, the SMA, the anterior insula, MCG, putamen, thalamus (presumably in the VL/VA nuclei), and the cerebellum (Table 1). The connectivity analysis ( $n = 13$ ) showed that M1 correlates with SMA, the insula, and the cerebellum (Figure 5).

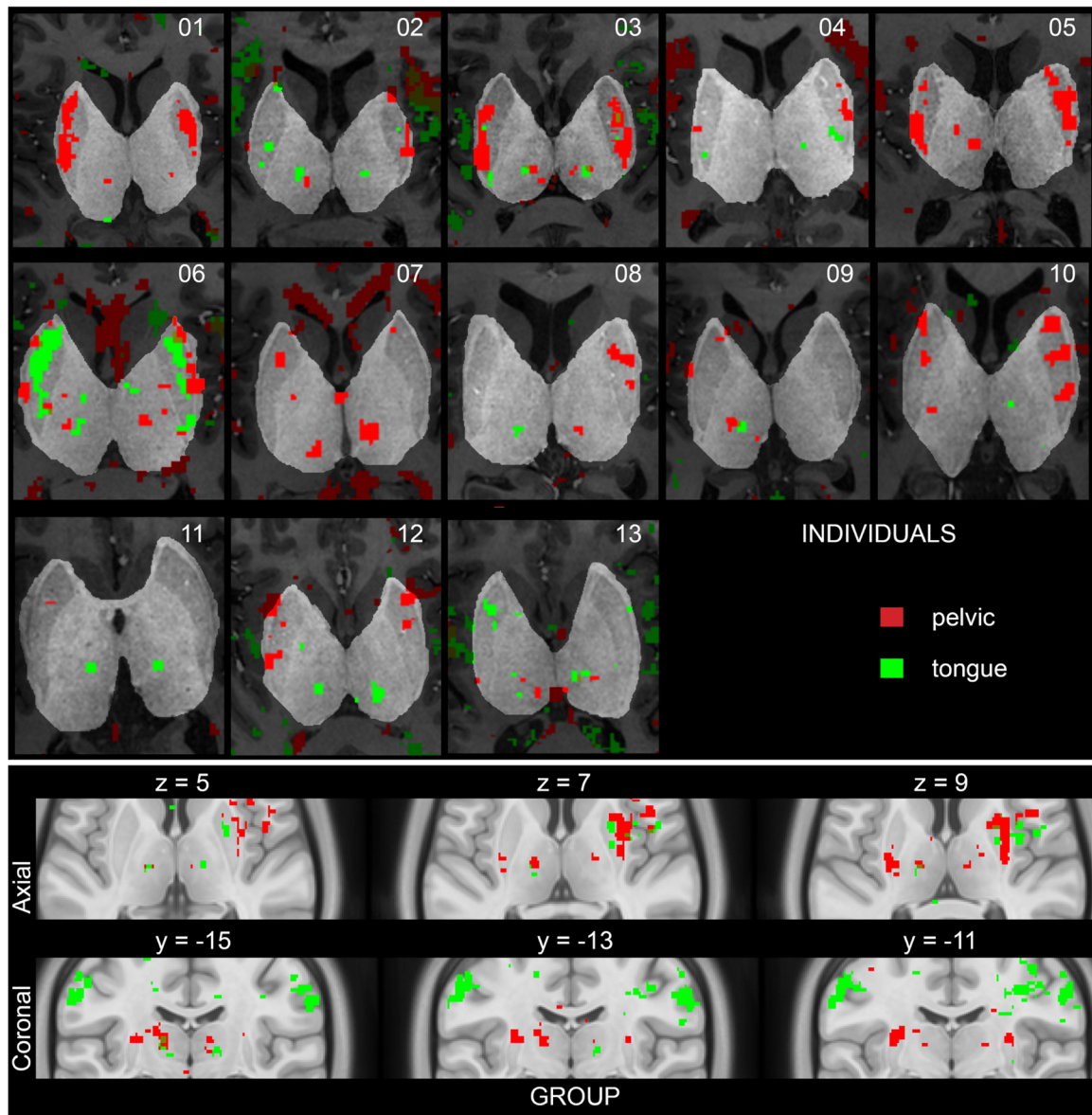
### 3.4 | Overlap

The overlap of activation clusters of PFMC and tongue movement in M1, SMA, insula, and cerebellum was calculated using the ROIs of the same subjects as used for the functional connectivity. In the M1 ROIs, there was no

overlap, the dice index was  $0.0 \pm 0.0$  (mean  $\pm$  standard error). For SMA ( $0.12 \pm 0.05$ ), insula ( $0.09 \pm 0.04$ ), and especially the cerebellum ROIs ( $0.04 \pm 0.02$ ), the overlap was minor.

## 4 | DISCUSSION

This is the first study demonstrating that 7T-fMRI is a suitable technique to study motor behavior of the pelvic floor in the whole brain of male individuals, showing concomitant cortical, subcortical, and cerebellar activation. The superomedial M1, inferolateral M1, SMA, MCG, the putamen, the thalamus (VL/VA), and the cerebellum were activated during contraction



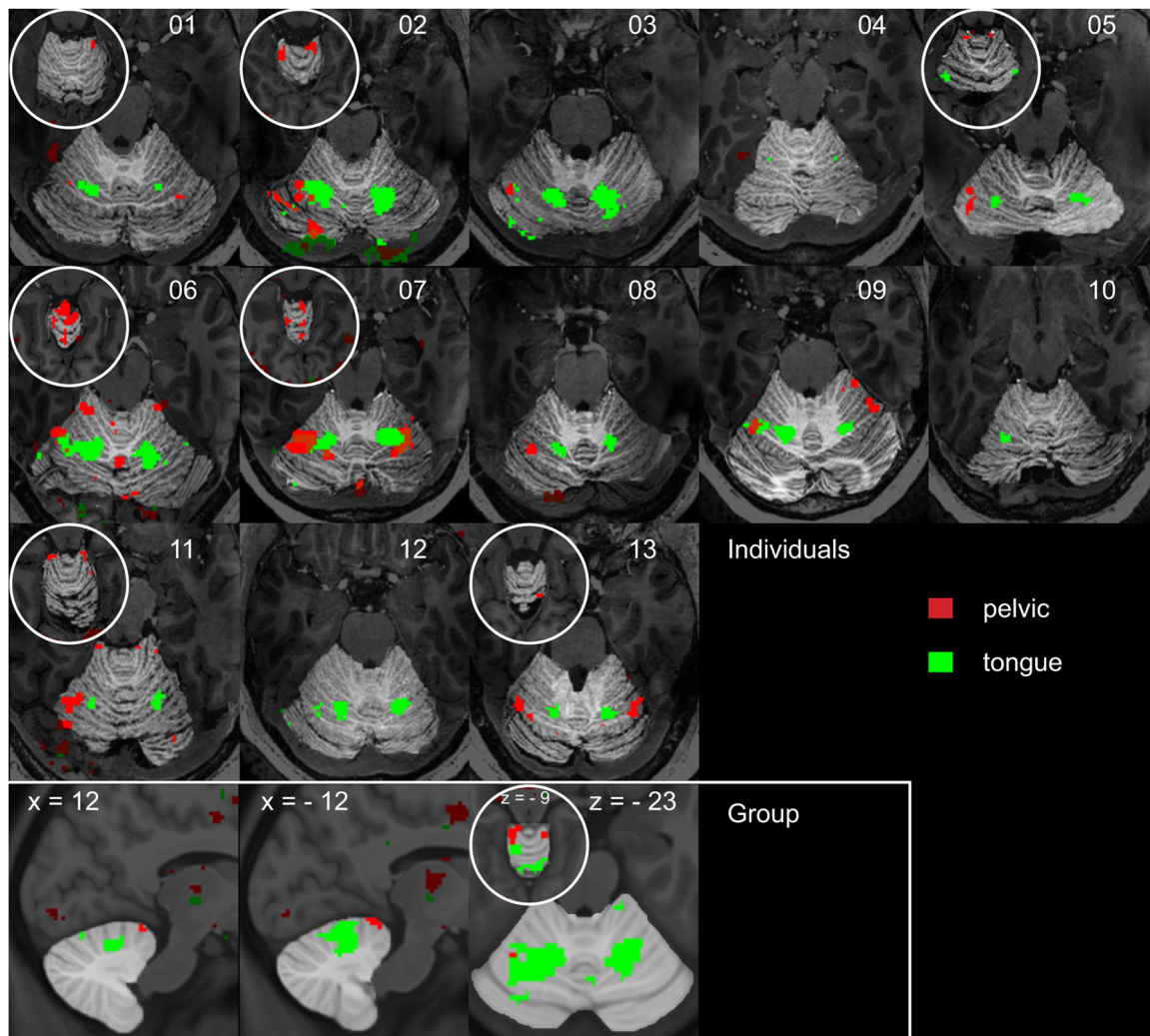
**FIGURE 2** Activation in the putamen and thalamus in single subjects ( $P < .001$  uncorrected) and group analysis ( $P < .001$  uncorrected)

of the pelvic floor. The similarities and differences between the results of the individuals and the group results tell us more about the genesis of group results and the applicability of group results in individuals.

#### 4.1 | Cortical representations

Our results showed a strong activation bilaterally in superomedial M1 during contraction of the pelvic floor consistently in all individuals and in groups' analyses. Activation of M1 during PFMC was first demonstrated using PET,<sup>3</sup> which supplemented the earlier described concept of the homunculus of Penfield and Rasmussen.<sup>20</sup> The activation found in M1 during PFMC, in the "hip-region" of the homunculus, is in line with other

conducted neuroimaging studies using group analysis.<sup>3,6,7,9,21</sup> In addition, during PFMC, in both single subject and group analysis, a bilateral inferolateral M1 cluster was found, directly superior of the tongue clusters. Two studies found activation in the precentral gyrus, 3 cm from the midline and suggested that this activation was associated with concomitant contraction of the abdominal muscles.<sup>3,22</sup> In other publications, a similar cluster is visible in some figures but has not been described in detail.<sup>10,23,24</sup> The current 7T-fMRI results further pinpoint the exact areas in the human motor cortex involved in PFMC. The group results showed moderate overlap of PFMC and tongue clusters in the SMA but no overlap in M1. The strong somatotopy of M1 has been described extensively,

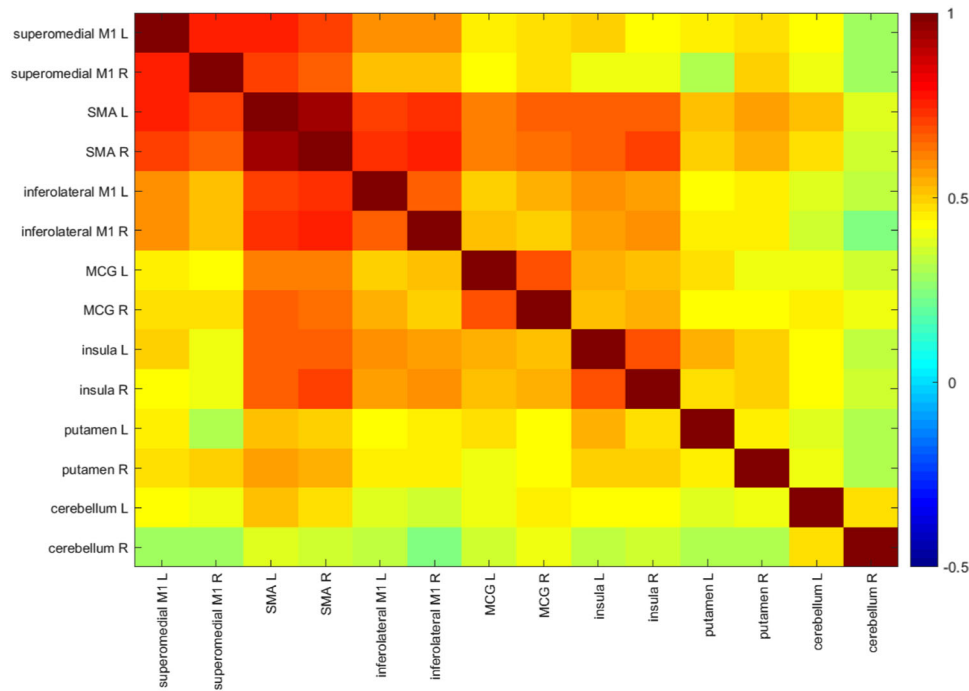


**FIGURE 3** Axial and sagittal coupes of the group analyses of the cerebellum and axial coupes of cerebellar activation in single subjects within circles a more superior coupe of the cerebellum. Single subjects threshold  $T = 5.2$ ,  $P < .05$  FEW, group threshold  $T = 3.05$ ,  $P < .005$  uncorrected

and overlap of clusters in M1 was therefore not expected. Research investigated a possible somatotopy of the SMA and suggested that the cranial to the caudal body is represented from anterior to posterior respectively, in the SMA.<sup>25,26</sup> Our results did not clearly demonstrate this somatotopy. In these smaller cortical body representations, the shorter distances between neighboring body parts result in larger overlap in the BOLD results. Note that this does not necessarily mean that the neural circuits for pelvic and tongue are shared in SMA, just that they are spatially closer.

The connectivity analysis showed a strong correlation between the superomedial M1 and the SMA during PFMC. Previously, it has been suggested that the SMA has a facilitatory effect on M1 during voluntary motor tasks.<sup>4,27</sup> Di Gangi Herms et al<sup>24</sup> compared cortical activation of women with stress urinary incontinence before and after pelvic floor muscle therapy (PFMT) using 3T-fMRI. Before the start of

the PFMT, significant clusters were found in the SMA during PFMC; after 12 weeks of daily PFMT, this cluster in the SMA was not found during PFMC and activation in the M1 was smaller and more focused. Our subjects had practiced voluntary PFMC just before the 7T-fMRI, and in the connectivity analysis we see that the SMA was strongly connected to the M1 and other cortical and subcortical areas. The connectivity of the SMA to other brain areas during the tongue task was less pronounced than during PFMC and active clusters shown in the SMA during tongue movements were smaller (Figure 1). Voluntary tongue movement is necessary for speaking and chewing, usually highly conditioned tasks. This indicates that the SMA is especially important in less conditioned movement control, such as PFMC. In this context, it is important to realize that cortical and subcortical activations were much more consistent among the participants during tongue movement than during PFMC (Figure 1).



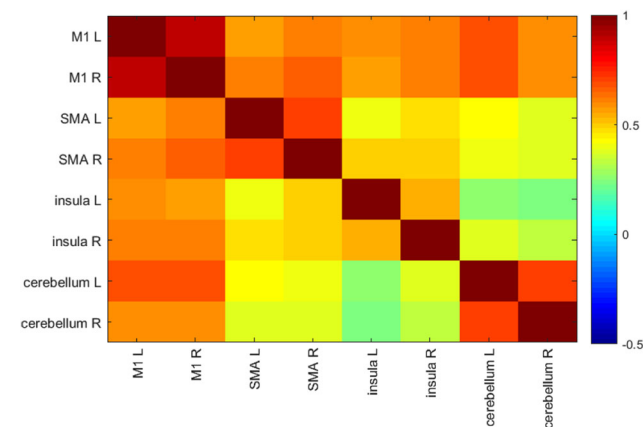
**FIGURE 4** Mean correlation of regions of interest during pelvic floor muscle contraction in  $n = 9$

## 4.2 | Putamen

In the present study, PFMC and tongue movement resulted in all single subjects and in the group analysis, in activation of the putamen, especially in the caudal putamen (Figure 2). Although specific caudal activation of the putamen during PFMC and tongue movement has not been described previously, activation in the putamen as a whole has been observed before during both tasks.<sup>28</sup> The putamen is part of the cortico-basal ganglia (BG)-thalamocortical-loop which participates in motor action selection.<sup>29</sup>

## 4.3 | Thalamus

The last part of the cortico-BG-thalamocortical-loop is the VL/VA nuclei of the thalamus, which, in turn, project to the motor cortex.<sup>30,31</sup> Our results showed bilateral activation in the thalamus during both tasks. In individuals and groups analyses, activation was seen possibly in the VL/VA nuclei (Figure 2). Activation was not found in all single subjects, but when found, it was consistently found on the same location. The current study is the first to show these results consistently in individuals. Previous studies on PFMC and tongue movement showed activation in thalamus without specification of a thalamic subnucleus.<sup>5,6,28</sup>



**FIGURE 5** Mean correlation of regions of interest during tongue movement  $n = 13$

## 4.4 | The cingulate gyrus

The midcingulate gyrus was activated bilaterally during PFMC and tongue movements. The location is comparable with previous studies during similar tasks: repetitive PFMC with empty bladder.<sup>4,5,24</sup> The involvement of this cluster can be explained by the presumed role of the MCG in the decision to perform a reward-based motor task.<sup>32</sup>

## 4.5 | The insula

Bilateral anterior insular activity was found during both tasks. Insular activity during PFMC and tongue



movement is described before, but not particularly in the anterior insula.<sup>4,21,24,33</sup> The conducted connectivity analysis showed that the insula is connected to cortical structures like the SMA but also to the MCG. Evidence suggests that the anterior insula is in particular strongly connected to the MCG to regulate attention related responses, for instance, pelvic floor contractions for retaining continence.<sup>34</sup> In addition, the insula shows increased connectivity to the motor cortex in patients with chronic pelvic pain syndrome compared with healthy controls, explained by the insular involvement of visceral sensations.<sup>10</sup> In the future, this might be of great interest to further explore the pathophysiology of PDFs.

#### 4.6 | Cerebellum

The cerebellum contains a double homunculus, one in the anterior lobe and a reversed in the posterior lobe.<sup>35</sup> We investigated anterior cerebellum activation not only for groups but also for single subjects. We found clusters in lobules I-IV of the cerebellum during PFMC, and clusters in lobule VI during tongue movement. This “upside-down” somatotopic representation of the human body agrees with previously obtained somatotopic maps.<sup>36</sup> This is the first study to show these results during PFMC in single subjects, which are comparable with two other studies on group analysis of cerebellar activations during PFMC.<sup>3,6</sup> In single subjects, tongue movement created large and consistent clusters in the cerebellum compared with PFMC. The ratio of the size of these tongue and PFMC clusters appear comparable with the ratio of the found clusters on the primary motor cortex.

#### 4.7 | Tongue movements as control task

Tongue movements were chosen as a control task, since this midline motor task can be controlled both voluntarily and involuntarily, such as PFMC. PFMC presumably diverges from tongue movement, because it may involve more affective-emotional aspects. Moreover, tongue movement is a more conditioned motor task, which explains the different connectivity during the two tasks. Existing literature describes active clusters during tongue movement in the same brain areas as the active clusters found in the present study with comparable coordinates,<sup>28,37</sup> also for the cerebellar clusters.<sup>36</sup>

#### 4.8 | Technical insights

This study analyzed both single subject results and group data. In the group results, during PFMC, activation in

superiomedial M1 is split into two separate clusters with less activation compared with the single subject results. The smoothing is indispensable when performing group analysis in view of the large intersubject variability of the brain anatomy. Consequently, this might cause disappearance of the less significant findings in individuals, like the present clusters in M1. The high folding of the superior end of M1 further complicates group analysis done in a 3D space. The increased BOLD signal at 7T-fMRI makes high-resolution single subject activation maps available and allows for a more accurate understanding of the central organization in humans.<sup>12</sup> Cortical single subject results during PFMC have been visualized previously at 3 T (see Figure 3 in Yani et al<sup>23</sup>). The direct comparison between 3 and 7 T results within individuals is left for future work.

## 5 | CONCLUSION

We have demonstrated that 7T-fMRI can visualize the neural representations in the whole brain involved in voluntary control of the pelvic floor in healthy male subjects. This has been done for the first time with whole brain coverage and high-field imaging, creating a high spatial resolution and a more accurate understanding of the involved brain areas. Our study shows that voluntary PFMC is represented in M1, SMA, MCG, insula, putamen, thalamus, and the cerebellum. Our connectivity analysis showed distinct differences between brain mechanisms controlling PFMC and tongue movement. The present high-field fMRI study may help to design future 7T studies in individual patients. These studies should provide new insights on the pathological circuits to improve clinical practice.

## ACKNOWLEDGMENTS

We would like to thank all the volunteers for their participation and Pieter Buur, Dieuwke de Waard, Sara Jaffari, Diederick Stoffers, Peter Morris, and Loes Groenendijk for their help. Chris De Zeeuw was funded by Nederlandse Organisatie voor Wetenschappelijk onderzoek—Aard en Levenswetenschappen (NWO-ALW), Zorg Onderzoek Nederland en Medische wetenschappen (Zon-MW), European Research Council-Advanced Grant—Proof Of Concept Grant (ERC-Adv/ERC-POC) Koninklijke Nederlandse Akademie van Wetenschappen (KNAW), and EU-Neurotime. Bertil Blok was funded by Zon-MW and Stichting Urologisch Wetenschappelijk Onderzoek.

## ORCID

Ilse M. Groenendijk  <http://orcid.org/0000-0002-7899-8267>

Bertil F. M. Blok  <http://orcid.org/0000-0001-9354-7395>

## REFERENCES

- Nygaard I. Prevalence of symptomatic pelvic floor disorders in US women. *JAMA*. 2008;300(11):1311-1316.
- Berghmans B, Nieman F, Leue C, Weemhoff M, Breukink S, van Koeveeringe G. Prevalence and triage of first contact pelvic floor dysfunction complaints in male patients referred to a Pelvic Care Centre. *NeuroUrol Urodyn*. 2016;35(4):487-491.
- Blok BF, Sturms LM, Holstege GA. A PET study on cortical and subcortical control of pelvic floor musculature in women. *J Comp Neurol*. 1997;389(3):535-544.
- Kuhtz-Buschbeck JP, van der Horst C, Wolff S, et al. Activation of the supplementary motor area (SMA) during voluntary pelvic floor muscle contractions—an fMRI study. *Neuroimage*. 2007;35(2):449-457.
- Schrum A, Wolff S, van der Horst C, Kuhtz-Buschbeck JP. Motor cortical representation of the pelvic floor muscles. *J Urol*. 2011;186(1):185-190.
- Seseke S, Baudewig J, Kallenberg K, Ringert RH, Seseke F, Dechent P. Voluntary pelvic floor muscle control—an fMRI study. *Neuroimage*. 2006;31(4):1399-1407.
- Seseke S, Baudewig J, Kallenberg K, Ringert RH, Seseke F, Dechent P. Gender differences in voluntary micturition control—an fMRI study. *Neuroimage*. 2008;43(2):183-191.
- Zhang H, Reitz A, Kollias S, Summers P, Curt A, Schurch B. An fMRI study of the role of suprapontine brain structures in the voluntary voiding control induced by pelvic floor contraction. *Neuroimage*. 2005;24(1):174-180.
- Krhut J, Holy P, Tintera J, Zachoval R, Zvara P. Brain activity during bladder filling and pelvic floor muscle contractions: a study using functional magnetic resonance imaging and synchronous urodynamics. *Int J Urol*. 2014;21(2):169-174.
- Kutch JJ, Yani MS, Asavasopon S, et al. Altered resting state neuromotor connectivity in men with chronic prostatitis/chronic pelvic pain syndrome: a MAPP. *NeuroImage: Clinical*. 2015;8:493-502.
- Seseke S, Baudewig J, Ringert RH, Rebmann U, Dechent P. Monitoring brain activation changes in the early postoperative period after radical prostatectomy using fMRI. *Neuroimage*. 2013;78:1-6.
- van der Zwaag W, Francis S, Head K, et al. fMRI at 1.5, 3 and 7 T: characterising BOLD signal changes. *Neuroimage*. 2009;47(4):1425-1434.
- Dumoulin SO, Fracasso A, van der Zwaag W, Siero JCW, Petridou N. Ultra-high field MRI: advancing systems neuroscience towards mesoscopic human brain function. *Neuroimage*. 2018;168:345-357.
- Martuzzi R, van der Zwaag W, Farthouat J, Gruetter R, Blanke O. Human finger somatotopy in areas 3b, 1, and 2: a 7T fMRI study using a natural stimulus. *Hum Brain Mapp*. 2014;35(1):213-226.
- Boillat Y, van der Zwaag W. Whole brain measurements of the positive BOLD response variability during a finger tapping task at 7 T show regional differences in its profiles. *Magn Reson Med*. 2019;81:2720-2727.
- Kuhtz-Buschbeck JP, Gilster R, van der Horst C, Hamann M, Wolff S, Jansen O. Control of bladder sensations: an fMRI study of brain activity and effective connectivity. *Neuroimage*. 2009;47(1):18-27.
- Brainard DH. The psychophysics toolbox. *Spat Vis*. 1997;10(4):433-436.
- Moeller S, Yacoub E, Olman CA, et al. Multiband multislice GE-EPI at 7 tesla, with 16-fold acceleration using partial parallel imaging with application to high spatial and temporal whole-brain fMRI. *Magn Reson Med*. 2010;63(5):1144-1153.
- Vaidya MV, Lazar M, Deniz CM, et al. Improved detection of fMRI activation in the cerebellum at 7T with dielectric pads extending the imaging region of a commercial head coil. *J Magn Reson Imaging*. 2018;48(2):431-440.
- Penfield W, Rasmussen T. *The Cerebral Cortex of Man: A Clinical Study of Localization of Function*. New York, NY: Macmillan; 1950.
- Kern MK, Arndorfer RC, Hyde JS, Shaker R. Cerebral cortical representation of external anal sphincter contraction: effect of effort. *Am J Physiol Gastrointest Liver Physiol*. 2004;286(2):G304-G311.
- Carr LJ, Harrison LM, Stephens JA. Evidence for bilateral innervation of certain homologous motoneurone pools in man. *J Physiol*. 1994;475(2):217-227.
- Yani MS, Wondolowski JH, Eckel SP, et al. Distributed representation of pelvic floor muscles in human motor cortex. *Sci Rep*. 2018;8(1). 7213.
- Di Gangi Herms AM, Veit R, Reisenauer C, et al. Functional imaging of stress urinary incontinence. *Neuroimage*. 2006;29(1):267-275.
- Arienzo D, Babiloni C, Ferretti A, et al. Somatotopy of anterior cingulate cortex (ACC) and supplementary motor area (SMA) for electric stimulation of the median and tibial nerves: an fMRI study. *Neuroimage*. 2006;33(2):700-705.
- Luppino G, Matelli M, Camarda RM, Gallese V, Rizzolatti G. Multiple representations of body movements in mesial area 6 and the adjacent cingulate cortex: an intracortical microstimulation study in the macaque monkey. *J Comp Neurol*. 1991;311(4):463-482.
- Luppino G, Matelli M, Camarda R, Rizzolatti G. Corticocortical connections of area F3 (SMA-proper) and area F6 (pre-SMA) in the macaque monkey. *J Comp Neurol*. 1993;338(1):114-140.
- Sakamoto K, Nakata H, Perrucci MG, Del Gratta C, Kakigi R, Romani GL. Negative BOLD during tongue movement: a functional magnetic resonance imaging study. *Neurosci Lett*. 2009;466(3):120-123.
- Jarbo K, Verstynen TD. Converging structural and functional connectivity of orbitofrontal, dorsolateral prefrontal, and posterior parietal cortex in the human striatum. *J Neurosci*. 2015;35(9):3865-3878.
- Behrens TEJ, Johansen-Berg H, Woolrich MW, et al. Non-invasive mapping of connections between human thalamus and cortex using diffusion imaging. *Nat Neurosci*. 2003;6(7):750-757.
- Jones EG, Wise SP, Coulter JD. Differential thalamic relationships of sensory-motor and parietal cortical fields in monkeys. *J Comp Neurol*. 1979;183(4):833-881.

32. Bush G, Vogt BA, Holmes J, et al. Dorsal anterior cingulate cortex: a role in reward-based decision making. *Proc Natl Acad Sci USA*. 2002;99(1):523-528.
33. Phillips ML, Gregory LJ, Cullen S, et al. The effect of negative emotional context on neural and behavioural responses to oesophageal stimulation. *Brain*. 2003;126(Pt 3):669-684.
34. Crottaz-Herbette S, Menon V. Where and when the anterior cingulate cortex modulates attentional response: combined fMRI and ERP evidence. *J Cogn Neurosci*. 2006;18(5):766-780.
35. Buckner RL, Krienen FM, Castellanos A, Diaz JC, Yeo BT. The organization of the human cerebellum estimated by intrinsic functional connectivity. *J Neurophysiol*. 2011;106(5):2322-2345.
36. Grodd W, Hulsmann E, Ackermann H. Functional MRI localizing in the cerebellum. *Neurosurg Clin N Am*. 2005;16(1):77-99.
37. Weiss C, Nettekoven C, Rehme AK, et al. Mapping the hand, foot and face representations in the primary motor cortex—retest reliability of neuronavigated TMS versus functional MRI. *Neuroimage*. 2013;66:531-542.

**How to cite this article:** Groenendijk IM, Luijten SPR, de Zeeuw CI, et al. Whole brain 7T-fMRI during pelvic floor muscle contraction in male subjects. *Neurourology and Urodynamics*. 2020;39:382–392. <https://doi.org/10.1002/nau.24218>