

OPEN ACCESS

Full open access to this and thousands of other papers at <http://www.la-press.com>.

Gait Balance Disorder by Thalamic Infarction with the Disorder of Interstitial Nucleus of Cajal

A. Kurosu¹, Y. Hayashi¹, K. Wada² and M. Nagaoka³

¹Department of Rehabilitation, Juntendo University Nerima Hospital, Nerima, Tokyo 177-8521, Japan. ²Department of Neurology, Juntendo University Nerima Hospital, Nerima, Tokyo 177-8521, Japan. ³Department of Rehabilitation, Juntendo University Faculty of Medicine, Nerima, Tokyo 177-8521, Japan.

Corresponding author email: kurosu@juntendo.ac.jp

Abstract: The interstitial nucleus of Cajal (INC) is thought to play an important role in torsional/vertical eye position and head posture, and disorders of the INC induce abnormal ocular movements and head tilt. Our patients with ocular tilt reactions simultaneously also had disturbances in ambulatory balance, yet no reports address the loss of balance control induced by disorders of the INC. We examined the ambulatory disturbances induced by INC lesion. We experienced three patients with ocular movement disorders and abnormal head tilt due to thalamic infarction. We performed ophthalmic examinations on and checked the balance of them. With funduscopy, abnormal cycloduction was seen in the unaffected side and normal cycloduction was observed in the affected side. Nevertheless, Hess charts showed distortions in the visual image of both eyes. They all had disorders of balance control. We tried to treat them using the Bobath approach for improving their ambulatory balance. With subsequent improvements in balance control it was possible for them to take short walks, but it was difficult to make any improvements in their ocular movement. The INC is related to balance control of ambulation and disorders of the INC induce ambulatory disturbances. Cycloduction was only observed in the unaffected side, but Hess charts showed distortions of the visual image in both eyes. Ambulation was briefly improved, but diplopia persisted in these patients.

Keywords: interstitial nucleus of Cajal, ocular tilt reaction, thalamic infarction, balance control

Clinical Medicine Insights: Case Reports 2011:4 7–11

doi: [10.4137/CCRep.S6232](https://doi.org/10.4137/CCRep.S6232)

This article is available from <http://www.la-press.com>.

© the author(s), publisher and licensee Libertas Academica Ltd.

This is an open access article. Unrestricted non-commercial use is permitted provided the original work is properly cited.

Introduction

The interstitial nucleus of Cajal (INC) is thought to be the “neural center” for torsional/vertical eye position and head posture. Disorders of the INC lead to impairment of ocular movement and head tilt. We experienced 3 cases that had disturbance of ocular movement and disorder of ambulation caused by thalamic infarction that included the region of the INC. They had disorders of balance control. We tried to improve their balance control with use of the Bobath approach which could lead to good recovery in the short time.

Case Report

Case 1

A 34-year-old woman without any complications experienced dizziness and couldn't walk by herself. She was alert and had no motor weakness of her four extremities. She suffered from double vision and both her ocular movements were severely restricted vertically. Magnetic Resonance (MR) Imaging demonstrated a small infarction in the left thalamus and MR angiography revealed dissecting aneurysm of basilar artery (Fig. 1). In ophthalmological examination funduscopy showed 11° of counter-clockwise cycloduction of the right eye (Fig. 2) and the Hess chart revealed a distorted visual field of both eyes (Fig. 3). Her dizziness improved quickly with conservative treatment. Three days after admission physical exercise was started. In sitting position, her body tilted to the right, and during walking her body inclined to the right and she staggered to the right. Apparently her balance control was disordered. We treated her with practice in the Bobath approach for improving her ambulation. Her ambulation was improved gradually and could walk by herself

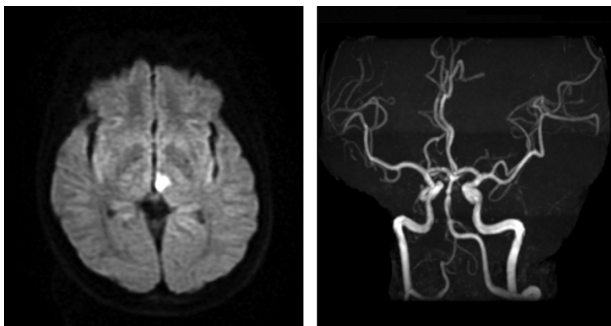


Figure 1. MR images (Diffusion image) revealed small infarction at the posteromedial of left thalamus (left) and MR angiography demonstrated dissecting aneurysm of basilar artery (right).

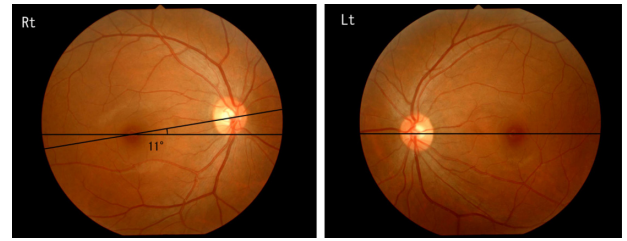


Figure 2. Funduscopy showed 11° of counter-clockwise torsion of the right eye. There is no torsion of left eye.

without staggering few days later. But double vision still distressed her. She transferred to the rehabilitation hospital 28 days later.

Case 2

An 87-year-old woman with an arrhythmia and hypertension was admitted for sudden dysarthria, double vision and gait disturbance. On admission her left eyelid was slightly ptotic. Her left eye was deviated outwardly, left pupil was dilated and there was an absent of light reflex. Vertical movement of both eyes was also disturbed severely. She had no motor weakness. MR Imaging revealed small lacunar infarction in the left thalamus (Fig. 4). Funduscopy showed 27° of counter-clockwise cycloduction of the right eye (Fig. 5) and Hess chart revealed a distorted visual field (Fig. 6). Three days after admission we started to exercise her ambulation. She could not walk without any help because of mild truncal ataxia. She tipped leftward while walking. Her balance control was disturbed. The Bobath approach was used to improve her balance control. As a result her ambulation gradually improved and she could walk by herself, but her double vision continued. She transferred to the rehabilitation hospital 24 days later.

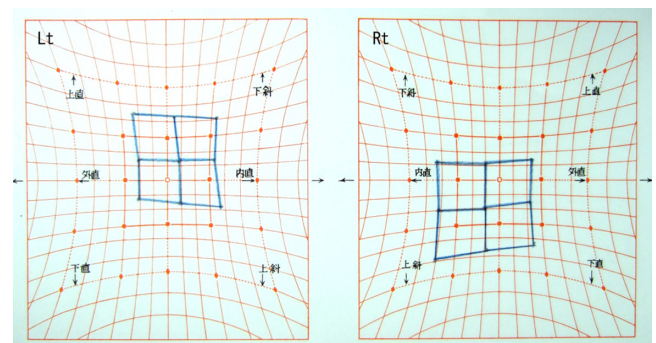


Figure 3. Hess chart suggested that the image of right eye deviated to the lower medial, and the image of left eye deviated to the upper medial.

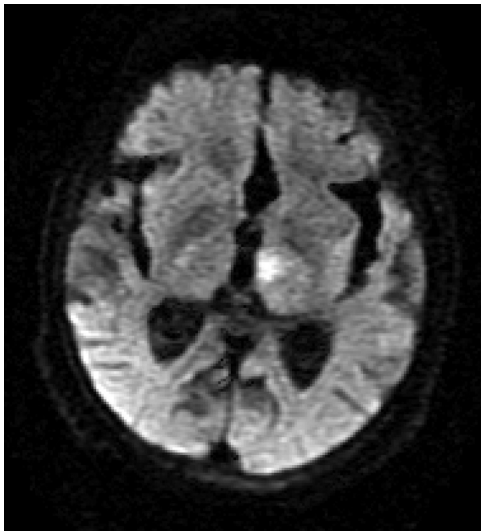


Figure 4. MR images (Diffusion image) revealed small infarction at the left thalamus and the posteromedial of left thalamus.

Case 3

An 86-year-old woman without any complications was found by her family after she fell down and became confused in the lavatory, and was transferred to our hospital. On admission her consciousness was almost clear and she complained of double vision. Her left pupil was dilated and her left eyelid was ptosis, and she had left exotropia and bilateral vertical ocular movement disorder. She had no motor paresis and ataxia in her extremities. MR Imaging revealed a small infarction in left thalamus (Fig. 7), and a Hess chart suggested that the images of bilateral views showed lower medial distortion (Fig. 8). Funduscopy could not be taken because of angle-closure glaucoma. Conservative therapy was conducted and Bobath approach was performed 3 days later on admission. A few days later her walking had improved and she could walk by herself but she suffered from double vision. She transferred to a rehabilitation hospital 26 days later.

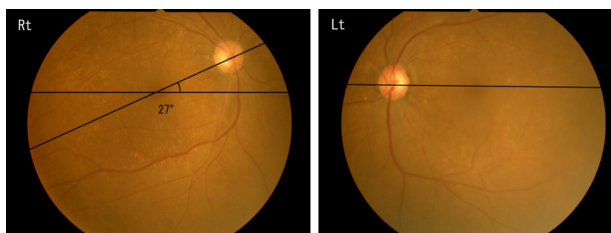


Figure 5. Funduscopy showed 27° of counter-clockwise torsion of the right eye. There is no torsion of left eye.

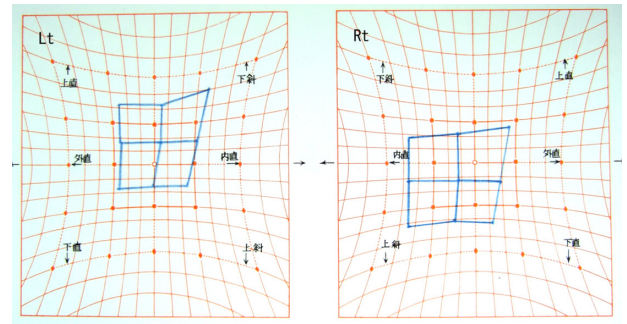


Figure 6. Hess chart suggested that the image of right eye deviated to the lower medial, and the image of left eye deviated to the upper medial.

Discussion

The interstitial nucleus of Cajal (INC) that is located to the mesodiencephalon is thought to be an important center of torsional/vertical ocular movements and head position, and related to the ocular tilt reaction (OTR).¹ The OTR is a triad of signs consisting of: head tilt, ocular torsion and skew deviation of the eyes.^{2,3} Labyrinthine lesions cause ipsilateral OTR, whereas thalamic lesions induce contralateral OTR.^{1,4,5} Some clinical reports showed that the patients who have thalamic vascular accident were tilted their head to contralateral side, complained of double visions and they have bilateral abnormal cycloduction in both eyes.^{6,7} In their cases the thalamic lesion was large, so it might influence the INC where existed in the midbrain. In previous clinical reports, abnormal cycloduction is stronger than an affected side at an unaffected side. Our cases, case 1 and case 2, demonstrated counter-clockwise cycloduction of the right eye, and no cycloduction of the left eye (ie, cycloduction was only seen in the unaffected side, and not in the affected side).

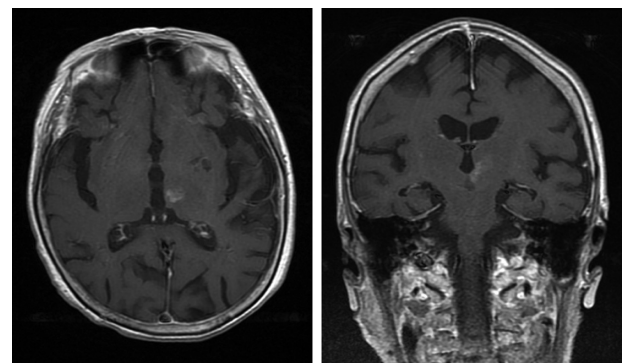


Figure 7. MR images (T1-weighted image with contrast medium) revealed small infarction at the posteromedial of left thalamus.

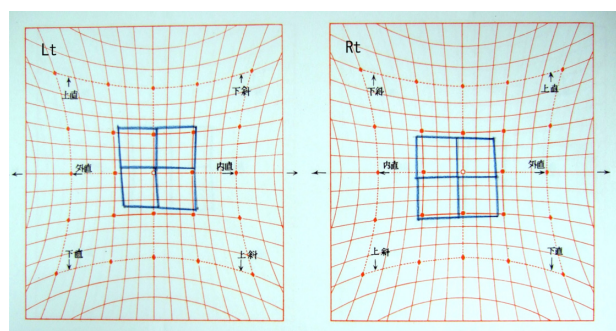


Figure 8. Hess chart suggested that the image of right eye slightly deviated to the lower medial, and the image of left eye also slightly deviated to the upper medial.

We suggest that the reason was the smaller size of the lesion compared to previous clinical reports. The other Hess chart revealed the distortion of visual image appeared in both eyes. The difference of the findings of two examinations remains uncertain, but it is interesting that the visual field of the affected side was distorted although it had no cycloduction. However it is uncertain why characteristic symptoms that appeared due to disorder of the INC emerged from the small thalamic infarction. As one of the causes, since a pathological change was near the INC, INC disorder may be influenced by cerebral edema etc. As another possibility, INC may be affected in the part which does not appear by an image.

Ambulation of our patients was ataxic, and they tended to turn to the unaffected side during walking though they had no motor weakness. So it was thought that the INC had an influence on balance control. There is no report that the vestibular dysfunction caused by the disorder of INC brings about gait balance disorder. We supposed that the massive thalamic vascular accident caused the lesion of pyramidal tract, as a result it became impossible to walk in previous clinical reports. Our patients had no sign of pyramidal tract, but could not walk because of disturbance of balance control. We suggest that balance disorder appeared through the disorder of the vestibular nucleus because one of the INC projections deploys the vestibular nucleus.^{8,9}

The Bobath approach is a rehabilitation method designed by Mr. and Mrs. Bobath about 60 years ago. Its concept is a problem solving approach to the assessment and treatment of individuals with disturbances of function, movement and postural control due to a lesion of the central nervous system, and the goal of

the treatment is to optimize function by improving postural control and selective movement through facilitation.¹⁰ We adopted the Bobath approach as the physical therapy of these cases owing to reports that the Bobath approach is a more effective physical therapy than other exercises for balance disturbance.¹¹ By this method their balance control of ambulation was improved. With respect to evaluation of their walking, the patients could not walk normally when rehabilitation was started, so we were not able to inspect patients' balance function objectively. It is notable that patients' ambulatory ability improved rapidly by ambulation exercise though it was caused by a pathological change of the midbrain and the thalamus.

On the other hand, disturbance of ocular movement lasted and patients complained of double vision during periods of hospitalization. High coordination movement of both sides is necessary for ocular movement. Therefore it seemed that the improvement of the ocular movement disorder was later than the improvement of ambulation.

Conclusion

Disorder of the INC induces disturbance of ocular movement and head posture, and consequently affects disorder of balance control. In cases of small lesion, cycloduction was only seen on the contralateral side of cerebral infarction in funduscopy. Nevertheless the Hess chart revealed distortion of bilateral visual image. It was relatively easy to improve their ambulatory disturbance with Bobath approach in a short term, but it was hard to improve their double vision by treating their balance control.

Acknowledgements

We wish to acknowledge the rehabilitation staff, especially Ms. Toshie Ishida: Basic Bobath Instructor, International Bobath Instructors Training Association, for their efforts towards good clinical practice with patients.

Disclosure

This manuscript has been read and approved by all authors. This paper is unique and is not under consideration by any other publication and has not been published elsewhere. The authors and peer reviewers of this paper report no conflicts of interest. The authors confirm that they have permission to reproduce any



copyrighted material. Written consent was obtained from the patient or relative for publication of this study.

References

1. Fukushima K, Ohashi T, Fukushima J. Effects of chemical deactivation of the interstitial nucleus of Cajal on the vertical vestibulo-collic reflex induced by pitch rotation in alert cats. *Neurosci Res.* 1994;20(3):281–6.
2. Lueck CJ, Hamlyn P, Crawford TJ, et al. A case of ocular tilt reaction and torsional nystagmus due to direct stimulation of the midbrain in man. *Brain.* 1991;114(Pt 5):2069–79.
3. Westheimer G, Blair SM. The ocular tilt reaction—a brainstem oculomotor routine. *Invest Ophthalmol.* 1975;14:833–9.
4. Chen CM, Lin SH. Ipsiversive partial ocular tilt reaction in a patient with acute paramedian thalamic infarctions. *Acta Neurol Taiwan.* 2006;15(1):29–33.
5. Kokoroyannis T, Scudder CA, Balaban CD, Highstein SM, Moschovakis AK. Anatomy and physiology of the primate interstitial nucleus of Cajal I. efferent projections. *J Neurophysiol.* 1996;75:725–39.
6. Halmagyi GM, Brandt T, Dieterich M, Curthoys IS, Stark RJ, Hoyt WF. Tonic contraversive ocular tilt reaction due to unilateral meso-diencephalic lesion. *Neurology.* 1990;40:1503–9.
7. Oh SY, Choi KD, Shin BS, Seo MW, Kim YH, Kim JS. Paroxysmal ocular tilt reactions after mesodiencephalic lesions: report of two cases and review of the literature. *J Neurol Sci.* 2009;277:98–102. Epub 2008 Nov 26. Review.
8. Dieterich M, Brandt T. Thalamic infarctions: differential effects on vestibular function in the roll plane (35 patients). *Neurology.* 1993;43:1732–40.
9. Rambold H, Helmchen C, Büttner U. Vestibular influence on the binocular control of vertical-torsional nystagmus after lesions in the interstitial nucleus of Cajal. *Neuroreport.* 2000;11:779–84.
10. Sue Raine, Linzi Meadows, Mary Lynch-Ellerington. *Bobath Concept. Theory and clinical practice in neurological rehabilitation.* United Kingdom: Wiley-Blackwell; 2009:23–42.
11. Kollen BJ, Lennon S, Lyons B, et al. The effectiveness of the Bobath concept in stroke rehabilitation: what is the evidence? *Stroke.* 2009;40:89–97.

Publish with Libertas Academica and every scientist working in your field can read your article

“I would like to say that this is the most author-friendly editing process I have experienced in over 150 publications. Thank you most sincerely.”

“The communication between your staff and me has been terrific. Whenever progress is made with the manuscript, I receive notice. Quite honestly, I’ve never had such complete communication with a journal.”

“LA is different, and hopefully represents a kind of scientific publication machinery that removes the hurdles from free flow of scientific thought.”

Your paper will be:

- Available to your entire community free of charge
- Fairly and quickly peer reviewed
- Yours! You retain copyright

<http://www.la-press.com>