CANADIAN SOCIETY FOR AESTHETIC (COSMETIC) PLASTIC SURGERY
SOCIÉTÉ CANADIENNE DE CHIRURGIE PLASTIQUE ESTHÉTIQUE
OPEN FORUM

Breast Surgery

A Simplified Approach to Breast Reduction Using the Medial Pedicle

Sarah C. Hunt, MSc; Yue Sun, MD; and Sanjay Azad, MD

Aesthetic Surgery Journal Open Forum
2022, 1–14
© 2022 The Aesthetic Society.
This is an Open Access article distributed under the terms of the Creative Commons Attribution-NonCommercial License (https://creativecommons.org/licenses/by-nc/4.0/), which permits non-commercial re-use, distribution, and reproduction in any medium, provided the original work is properly cited. For commercial re-use, please contact journals.permissions@oup.com
https://doi.org/10.1093/asjof/ojac019
www.asjopenforum.com
OXFORD UNIVERSITY PRESS

Abstract

Background: Breast reduction is a common procedure for plastic surgery. The authors have adopted a modified technique using the medial pedicle, with markings using a 15-9-9 framework and a methodical step-wise approach.

Objectives: This study introduces the 15-9-9 framework as a design for medial pedicle breast reductions that is easy to perform and teach, with favorable outcomes.

Methods: Markings using the 15-9-9 framework were used, describing the mosque dome and medial pedicle length and width. The technique was performed in day surgery under general anesthesia. Patients were followed up for 1 year, with photographs taken at each visit and complications recorded. A retrospective review of 80 patients between November 2013 and July 2019 was completed in a single-surgeon's practice.

Results: Patients were an average of 49 years (18-72 years) with a BMI of 28 kg/m^2 (23-32). The average planned postoperative sternal notch to areola distance was 22 cm (19-26 cm) and sternal notch to nipple distance was 24 cm (21-28 cm). The average duration of the surgical procedure was 3.4 hours. An average of 464 g (90-1210 g) was removed from each breast. Complication rates were low with minor fat necrosis (14%), T-junction breakdown (10%), hematoma (3.8%), dog ear formation (3.8%), junctional necrosis (2.5%), and partial nipple loss (1.3%). One patient had a cerebrovascular accident in the late postoperative period. Aesthetically pleasing results were achieved postoperatively.

Conclusions: This technique using the 15-9-9 framework is simple to learn, perform, and teach with overall aesthetically pleasing outcomes.

Level of Evidence: 4

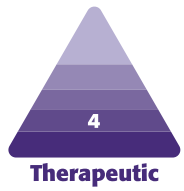

Editorial Decision date: March 16, 2022; online publish-ahead-of-print April 1, 2022.

Breast reduction is one of the most performed procedures in plastic surgery.[1] It has the dual benefit of enhancing the appearance of breasts and relieving symptoms of macromastia, including pain in the neck, shoulders and back, postural problems, breathing difficulties, and interference with daily activities such as exercise.[2-4]

The inverted T inferior pedicle technique remains the most commonly used technique by plastic surgeons[4-6] because it is reliable, quick, and easy to teach, and it achieves a good aesthetic result following surgery.[7,8] However, the inverted T inferior pedicle technique has been criticized for bottoming out over time.[5,8]

Recent studies have encouraged the use of medial and superomedial pedicles for the reduction of mammaplasties.[7,9] Aesthetic advantages to the medial and superomedial pedicles include better upper pole fullness and less bottoming out over time.[9,10] Less complications

From the Northern Ontario School of Medicine, Thunder Bay, ON, Canada.

Corresponding Author:
Ms. Sarah C. Hunt, Northern Ontario School of Medicine, 955 Oliver Road, Thunder Bay, ON P7B 5E1, Canada.
E-mail: sahunt@nosm.ca; Instagram: @drsanjayazad

have also been reported with the medial technique compared with the inferior pedicle technique.[11] There are also anatomical advantages to these pedicles, including preservation of the internal mammary perforators which help prevent necrosis of the nipple-areola complex (NAC)[3,12] and preservation of the medial branches of the intercostal nerves which help sustain sensation.[8] Despite the benefits of these techniques, there remains hesitance among plastic surgeons who fear the learning curve associated with these techniques.

In this article, we describe a modified inverted T medial pedicle technique utilized by one plastic surgeon over a 6-year period. The technique described in this article utilizes markings, referred to as the 15-9-9 framework, describing the mosque dome length, pedicle width, and pedicle length, respectively. This design has achieved consistent aesthetic results and stable outcomes, and it has the advantage of being easy to learn and to teach. The operation for the technique described in this article can be completed in as little as 2 hours in a day surgery model if no liposuction is required and does not require the use of drains.

METHODS

Ethics Approval

This retrospective study obtained ethics approval from the Thunder Bay Regional Health Sciences Centre Research Ethics Board (REB). The Tri-Council Policy Statement: Ethical Conduct for Research Involving Humans (TCPS-2)[13] was used as a guideline for this research study, and the Declaration of Helsinki was followed. Written consent for the use of photographic images and videos was obtained from each patient before surgery. The REB determined that written consent was not required for the retrospective chart review portion of this study, as the study involved minimal risks to patients and would not adversely affect the welfare of patients who had already undergone the procedure. Furthermore, no patient identifiers were used in this retrospective study.

Patient Selection

A retrospective chart review was conducted at the practice of one plastic surgeon. All patients who underwent breast reduction using the 15-9-9 framework between November 2013 and July 2019 were considered. All patients referred to the surgeon experienced symptoms of macromastia, including back pain, neck pain, shoulder grooves, and sometimes rash. Inclusion criteria for this retrospective study included nonsmoker status and optimized BMI. Nonsmoking patients with optimized BMI of approximately 30 kg/m^2 or less were ideal patients selection parameters because of the reduced rates of complications among this group.[4,14] The single surgeon who performed this technique had an office policy in which they would not operate on patients without an optimized BMI or on patients who were actively smoking. Due to this policy, the surgeon only operated on patients who fit the inclusion criteria, and none of the patients who were operated on were excluded from the study. Patients included in this study were followed for up to 1 year following their operation.

Preoperative Counseling and Preparation

The patient has standardized preoperative counseling and 6-position medical photography in the office setting before surgery. Smoking status is again checked by requesting that the patient disclose any recent smoking, as our office protocol is to not operate on smokers. It is ensured that the patient has been fully optimized for BMI and overall health to get the best outcomes.

Preoperative preparation for the postoperative period is emphasized including the use of a sports bra and an anti-bruising and scar management regime following surgery. The patient is given an information sheet regarding the perioperative care.

Before surgery, the patient has relevant blood work. It is our practice to administer only a single dose of intravenous antibiotics before surgery along with oral acetaminophen. Deep venous thrombosis prophylaxis is addressed with the application of T.E.D. stockings (Cardinal Health, Dublin, OH) and Sequential Compression Devices to the calf for the whole operative episode. Patients are routinely managed as day surgery and sent home. They are advised to mobilize, drink water, and remove the stockings after they are adequately ambulant.

Preoperative Markings

Clinical markings are done in a standing position (Figure 1, Video 1). Three colored markers are used for uniform markings. Red is used for the décolletage and liposuction areas, blue is used for all measurements, and black is used for the breast markings.

Initially, the midline is marked from the suprasternal notch to the xiphoid and onto the umbilicus. Next, the breast footprint is marked. This is followed by the breast meridian. The décolletage is then clearly marked out to facilitate the markings on the rest of the breast.

The sternal notch to areola (SNA) and sternal notch to nipple (SNN) distance is measured on both sides and marked on the respective chest wall. The distance of the breast meridian from the midline is measured and marked. Next, the inframammary approach is checked with anterior transposition of the folded hand to assess the Pitanguy point. This is marked and then this is checked to see if it correlates with the mid-humeral point. This is adjusted accordingly, giving more credence to the mid-humeral point

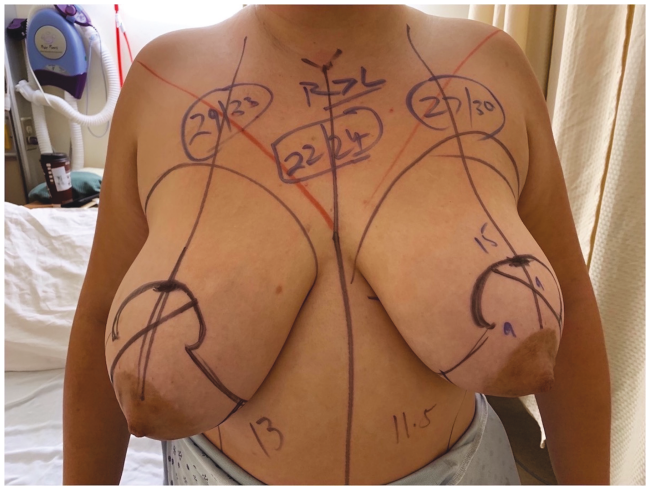

Figure 1. Markings are shown on a 22-year-old female patient using the 15-9-9 rule. Markings (left to right, top to bottom): 29 cm = right preoperative sternal notch to areola (SNA), 33 cm = right preoperative sternal notch to nipple (SNN), 22 cm = right and left planned SNA, 24 cm = right and left planned SNN, 27 cm = left preoperative SNA, 30 cm = left preoperative SNN, 15 cm = mosque dome, 9 cm = medial pedicle length, 9 cm = medial pedicle width, 13 cm = right breast meridian to midline distance, and 11.5 cm = left breast meridian to midline distance.

for the ultimate SNA/SNN distance. This is now measured equally on both sides and written on the chest wall as the final measurement for the procedure.

The mosque dome is now marked free hand aiming for a dimension of about 15 cm. The freehand marking starts at the point at which the new SNA is marked. The breast is now transposed medially and laterally to drop lines down from the mosque dome to the breast meridian. These vertical lines are then connected to each other about 3-4 cm above the inframammary crease. After the mosque dome is drawn, the circumference from one end to the other end before the vertical lines is then measured to ensure a dimension of approximately 15 cm. If it is significantly less or more than 15 cm in length, then an appropriate modification is made.

The medial pedicle is then designed. It starts on the mosque dome at the level of the breast meridian intersecting this area and then an equal length is marked on the medial limb of the vertical marking. We find the typical figure for the length and width of the pedicle is near about 9 cm for both. This is also clearly marked.

Any area for liposuction is clearly marked with the red permanent marker in the axilla all the way back to the posterior axillary line. All of these are clearly noted on a grid which we use to simplify documentation.

Operative Technique

The operative technique is summarized in Video 2. Once the patient is brought to the room, a surgical pause is followed

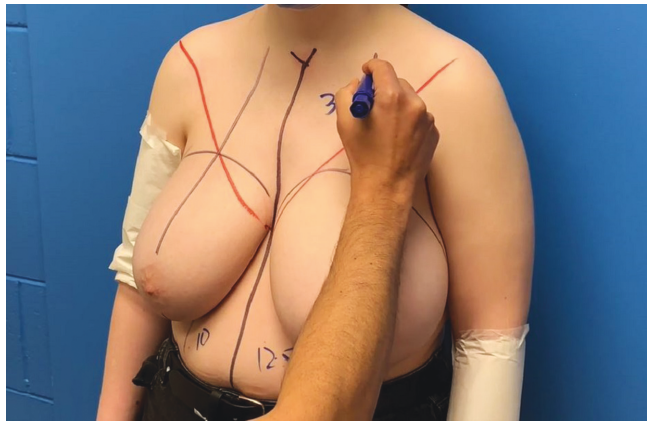

Video 1. Watch now at http://academic.oup.com/asjopenforum/article-lookup/doi/10.1093/asjof/ojac019

by intubation, and the patient is positioned in the supine position, arm at 90°C abduction, with all pressure areas protected with sponge pads and a lower body warmer used to prevent hypothermia. After the preparation with chlorhexidine/alcohol antiseptic and sterile draping, the areola is marked out with a 4.5-cm diameter nipple marker (Figure 2). Stab incisions are made with No. 15 blade in the resection area of the inferior pole of the breast. Infiltration is done in the inferior and lateral poles of the breast. This is done using a 1.5-mm multi-hole cannula with a pump device at 100 mmHg. The solution has 1 L of normal saline with 15 mL of 1% plain lidocaine and 1 mL of 1:1000 epinephrine. This infiltration aids in hemostasis and postoperative analgesia. The main dissection is done with No. 10 scalpel assisted laterally for pillar thinning, with a curved Mayo's scissor.

For any patient needing axillary liposuction, this is done at this stage on both sides with additional infiltration using a solution of 1 L of normal saline with 1 mL of 1:1000 epinephrine. Power-assisted liposuction is done using the PAL Liposuction System (MicroAire, Charlottesville, VA) device with a 3- or 4-mm double Mercedes tip cannula. The liposuction amount is carefully recorded.

Once infiltration has been done bilaterally, all incisions are incised superficially. The medial pedicle design is carefully de-epithelialized using a No. 10 scalpel blade using the assistant to stretch out the area with some counter-traction (Figure 3A). The dermis is preserved ensuring venous preservation. This is followed by pedicle isolation with the breast allowed to drop laterally and ensuring that the pedicle is not chamfered. The pedicle is then raised with dissection done underneath to raise it till about 4-5 cm from the midline (Figure 3B, C). This is to ensure that the perforator of the third internal mammary artery is intact which is the main blood supply of the pedicle. The thickness of the medial pedicle that is left behind is typically at least 7-8 cm.

The resection proceeds thereafter superiorly ensuring that the superior pole is not chamfered (Figure 4A). The

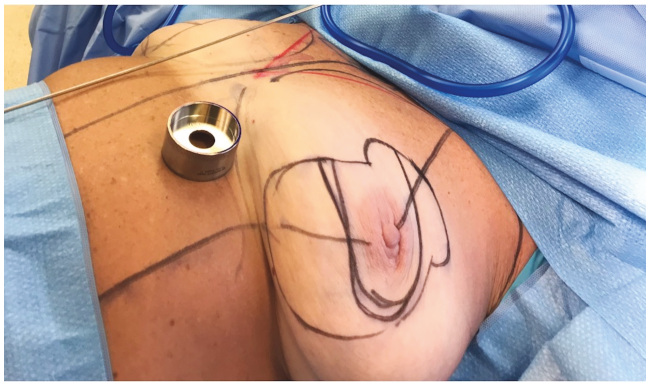

Figure 2. A 4.5-cm nipple marker is used on a 54-year-old female patient to mark the areola before the skin is de-epithelialized.

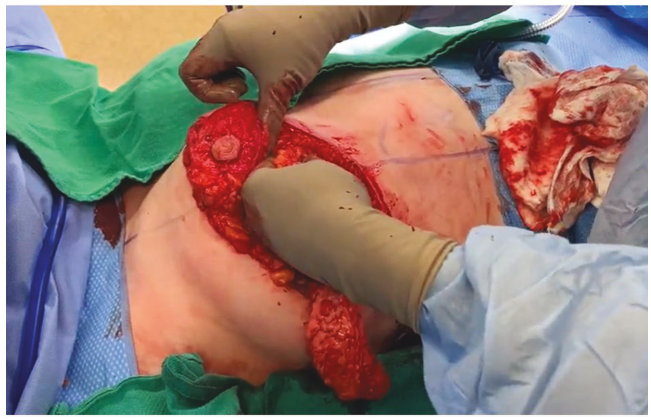

Video 2. Watch now at http://academic.oup.com/asjopenforum/article-lookup/doi/10.1093/asjof/ojac019

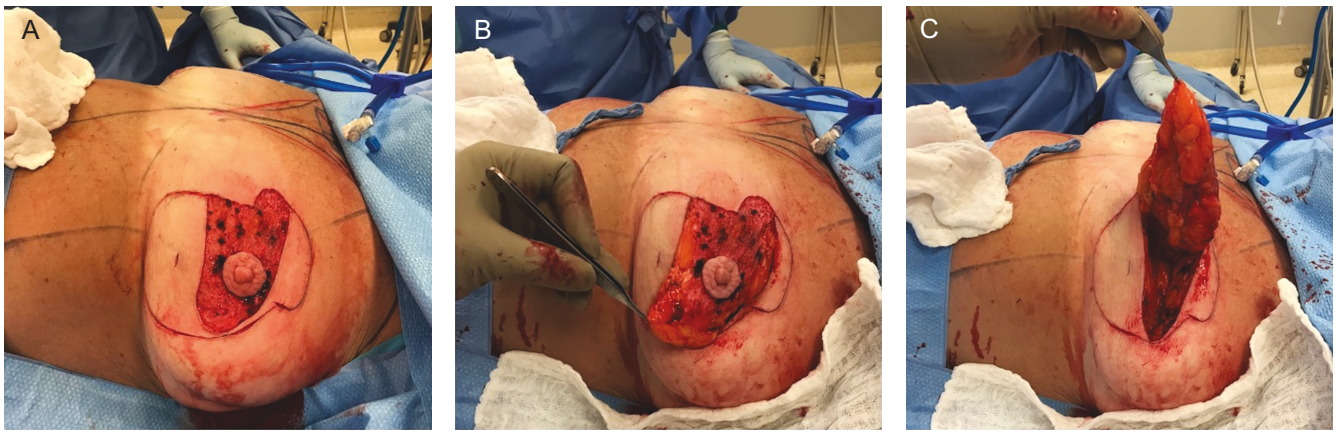

Figure 3. (A) Skin is de-epithelialized on a 54-year-old female patient; (B) the pedicle is raised so that dissection can be completed underneath; and (C) the dissection underneath is completed, and the pedicle is isolated.

medial dissection is done next and progressed inferiorly and then laterally (Figure 4B). The superior and inferior tissues are held by the assistant, and the lateral pillar is sharply dissected in a concave manner to the chest wall ensuring about a 1-inch-thick flap of tissue is left to ensure an appropriate approximation of the pillars.

The breast cavity is now meticulously washed out with saline to remove loose fat and check on hemostasis with a monopolar cautery (Figure 5A). The mosque dome is brought together with 3-0 Monocryl (Ethicon, Cincinnati, OH) (Figure 5B). The pedicle is then transposed into the mosque dome (Figure 5C) and exteriorized (Figure 5D).

The inferior dog ear is obvious (Figure 6A and B) and is marked 6 cm vertically down from the mosque dome closure point (Figure 6C). It is marked essentially in a lower pole Wise pattern manner with an inverted V at the level of the breast meridian to reduce tension at the T-junction closure (Figure 6D). Although not routinely measured, the height of the V is approximately 1-3 cm. This area is resected (Figure 6E), and the specimen is now weighted and sent for pathology.

Closure of the medial pedicle and lateral pedicle is brought together with 2 sutures of 2-0 polydioxanone suture (PDS). This is done by ensuring the inferior pole is well created with a good contour. The horizontal element of the closure is done with 0-0 Stratafix (Ethicon, Cincinnati, OH) continuous sutures, taking bites of the dermis. The double-ended suture is started in the midline and progresses rapidly on both sides. This is followed by intracuticular 3-0 Monocryl sutures. The areola is anchored at 3 o′clock, 9 o′clock, and 12 o′clock with 3-0 Monocryl. The circumareolar and vertical closure is done with intracuticular 3-0 Stratafix (Figure 6F).

No drains are used, and the wound is dressed with Dermabond (Ethicon, Cincinnati, OH). Abdominal sterile pads are placed and followed by a customized sports bra.

Postoperative Care

The patient is taken to recovery and then day surgery and discharged the same day with acetaminophen and ibuprofen for pain relief. A follow-up appointment is scheduled

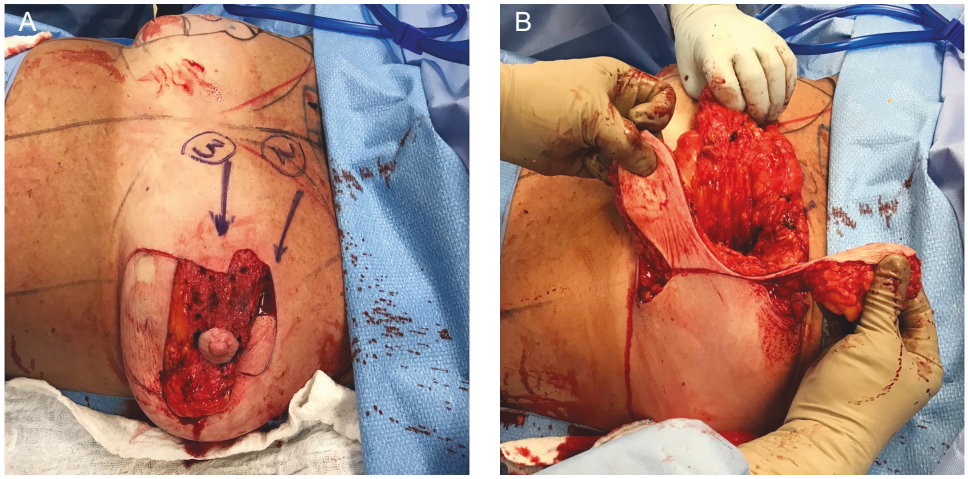

Figure 4. (A) Resection on a 54-year-old female patient proceeds superiorly and (B) resection is continued medially, then inferiorly, and laterally.

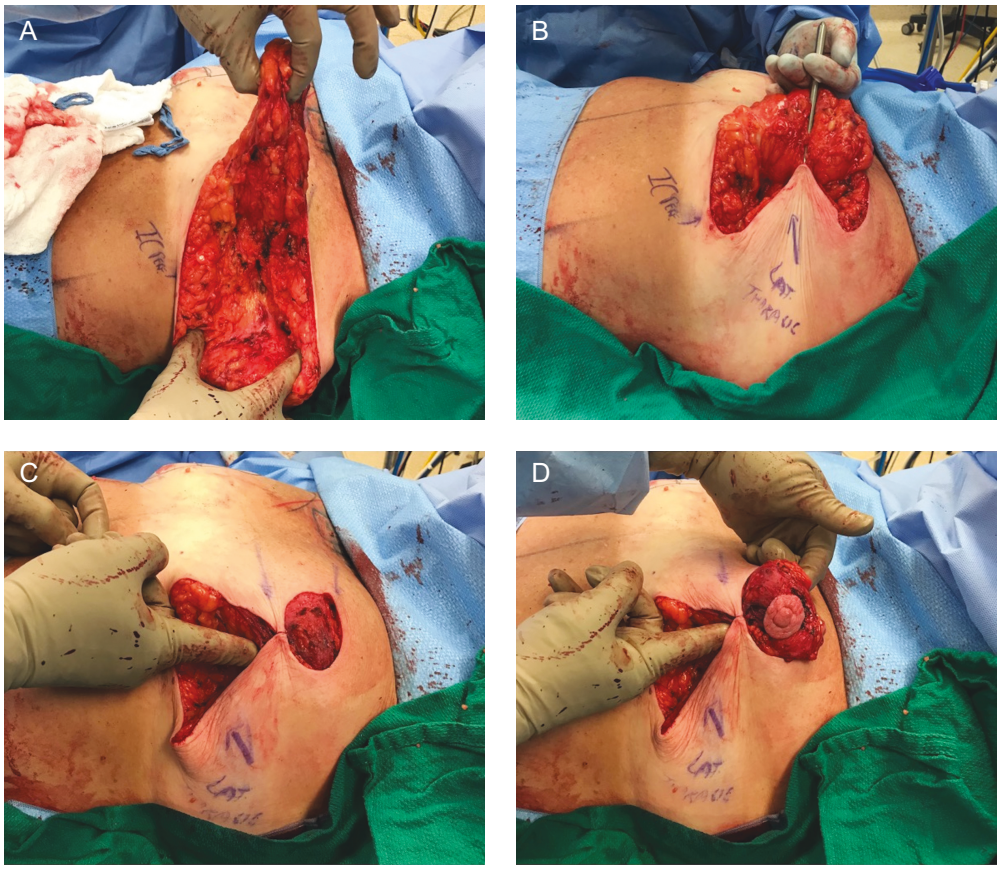

Figure 5. (A) The breast cavity of a 54-year-old female patient is inspected for loose tissue and hemostasis; (B) the mosque dome is brought together; (C) the mosque dome is secured with 3-0 Monocryl (Ethicon, Cincinnati, OH), and the medial pedicle is then transposed into the mosque dome; and (D) the medial pedicle is exteriorized from the mosque dome.

with the operating surgeon 1 week and 2 weeks following the procedure.

Patients are informed that recovery time is 8 weeks in length. They are asked to perform 30% of their normal activities in the first 2 to 3 weeks. Driving is permitted at 2 weeks with the addition of a soft interface beneath the seatbelt. Patients can expect bruising to clear around 4 weeks, and patients may start going for longer walks at this point. Arm movements with activity are permitted within a range of comfort. After 8 weeks, the patient may resume work. Contact sports and high-intensity activities are recommended 12 weeks postsurgery.

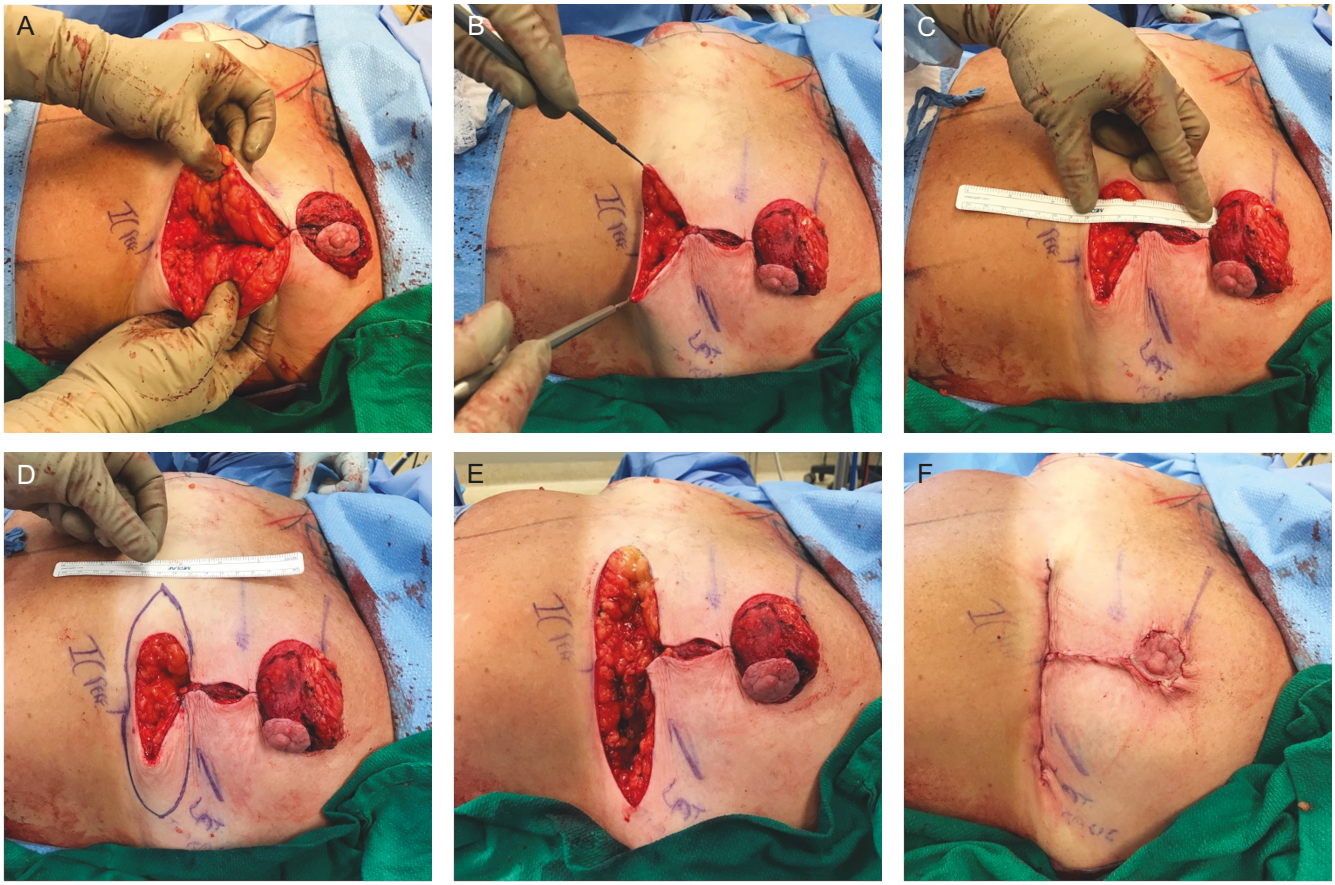

Figure 6. (A) Inferior tissue of a 54-year-old female patient is secured with an additional suture; (B) inferior dog ear is prominent; (C) the inferior dog ear is marked 6 cm from the first mosque dome closure; (D) inverted Vs are marked at the level of the breast meridian to reduce tension at the T-junction; (E) the marked area is resected; and (F) the remaining tissue is secured with sutures.

Scar management is commenced at 3 weeks after surgery with a combination of Micropore (3M, London, ON, Canada) taping and Vitamin E cream massage used for 5 days and 2 days, respectively, for a 6-month period. Upon patient self-removal of the Dermabond, the patient is instructed to apply Micropore tape over the scar for 5 days on a continuous basis. This is followed by 2 days of Vitamin E cream massaged over the scar for 15 minutes 3 times daily. The patient is then expected to continue this 7-day scar management regime for 6 months. This is emphasized by a scar management information sheet that is given to each patient undergoing the breast reduction procedure. Patients are followed up for 1 year after surgery, and final photographs are taken at 6 months and/or 1 year.

RESULTS

Patient Demographics

There were 80 patients included in this retrospective study who underwent breast reduction using the 15-9-9 medial pedicle design over the 6-year period. The average patient age was 49 years (range, 18-72 years). The average BMI was 28 kg/m^2 (range, 23-32 kg/m^2). These results are summarized in Table 1. Significant comorbidities were also noted. Of the 80 patients in this study, 1 patient (1.3%) had diabetes, 2 patients (2.5%) had coronary artery disease, and 8 patients (10%) had hypertension. None of the patients included in this study had a personal history of breast cancer. These patients were followed up to 1 year after their surgery, as per office policy. Most patients were seen for 6 months (Table 1).

Surgical Outcomes

Preoperative markings generally followed the 15-9-9 framework, with mosque dome measurements averaging 15 cm (range, 13-18 cm), pedicle length averaging 10 cm (range, 7-12 cm), and pedicle width averaging 9 cm (range, 7-12 cm). Before surgery, the SNA length was an average of 29 cm (range, 24-37 cm), and the SNN length was an average of 30 cm (range, 23-36 cm). Using the mid-humerus as a reference point for the new position of the areola, the ideal postoperative SNA length was an average

Table 1. Summary of Patient Demographics, Surgical Outcomes, and Follow-Up

Variable	Level	Mean	Median	Min	Max
Patient demographics	Age (years)	49	51	18	72
	BMI (kg/m^2)	28	28	23	32
Surgical outcomes	Duration of surgical procedure (h)	3.4	2.4	1.5	7.0
	Amount of breast tissue removed (g)	464	425	90	1210
	Sternal notch to areola length (cm)				
	Pre-breast reduction	29	28	24	37
	Post-breast reduction (planned)	22	22	19	26
	Sternal notch to nipple length (cm)				
	Pre-breast reduction	30	30	23	36
	Post-breast reduction (planned)	24	24	21	28
	Mosque dome length (cm)	15	15	13	18
	Pedicle length (cm)	10	9	7	12
	Pedicle width (cm)	9	9	7	12
Follow-up length	Months	6.6	5	0.5	17

Table 2. Postoperative Complications

Complication	No. of occurrences (%)
Fat necrosis	11 (14%)
T-junction breakdown	8 (10%)
Hematoma	3 (3.8%)
Dog ear	3 (3.8%)
Junctional necrosis	2 (2.5%)
Partial nipple loss	1 (1.3%)
Left cerebrovascular accident	1 (1.3%)

of 22 cm (range, 19-26 cm), and the ideal postoperative SNN length was an average of 24 cm (range, 21-28). These measurements are based on the preoperatively planned markings. The average duration of the surgical procedure was 3.4 hours (range, 1.5-7.0 hours). The longer surgical duration was associated with additional liposuction and/or a combined abdominoplasty. An average of 464 g (range, 90-1210 g) was removed from each breast and weighed intraoperatively. These results are summarized in Table 1. Photographs of patient results were taken at follow-up visits (Figures 7-9).

Postoperative Complications

The most common postoperative complication was fat necrosis, which occurred in 11 cases (14%) and resolved on their own. Fat necrosis was diagnosed if the patient presented with a palpable discrete lump in the postoperative period. Patients were reassured and followed closely. Ultrasound was not routinely requested, and none of these cases required intervention. The second most common postoperative complication was T-junction breakdown, which occurred in 8 cases (10%). T-junction breakdown was defined as wound dehiscence at the site of the T-junction, requiring dressings and close follow-up. Three hematomas were developed (3.8%), all of which resolved on their own. Three dog ears (3.8%) required surgical revision. Junctional necrosis, defined as wound dehiscence at the areola and vertical scar junction, was observed in 2 cases (2.5%) and required debridement. Partial nipple loss was observed in only 1 case (1.3%). The most severe postoperative complication was one instance (1.3%) in which a patient had a cerebrovascular accident following surgery. It is important to note, however, that this patient was at a higher risk of stroke given their medical history significant for hypertension, hyperlipidemia, ischemic heart disease, and obesity. Postoperative complications are summarized in Table 2.

DISCUSSION

Breast reduction is a common procedure in plastic surgery and an important index operation for any trainee who is completing full training in the specialty.[15] Over the years, numerous techniques have been promulgated, each with its own advantages and disadvantages. When the senior author of this paper started performing this procedure

Figure 7. A 48-year-old female patient is shown (A, C, E, G, I) before breast reduction and (B, D, F, H, J) 1 year following breast reduction.

as a trainee, the most common technique was the inferior pedicle.[16] The procedure was onerous to perform with extensive de-epithelialization, blood loss, drains, and hospital stay. The retained tissue was inferior dominant, which created a less than satisfactory cosmetic outcome and problems with pseudoptosis deformity. The initial

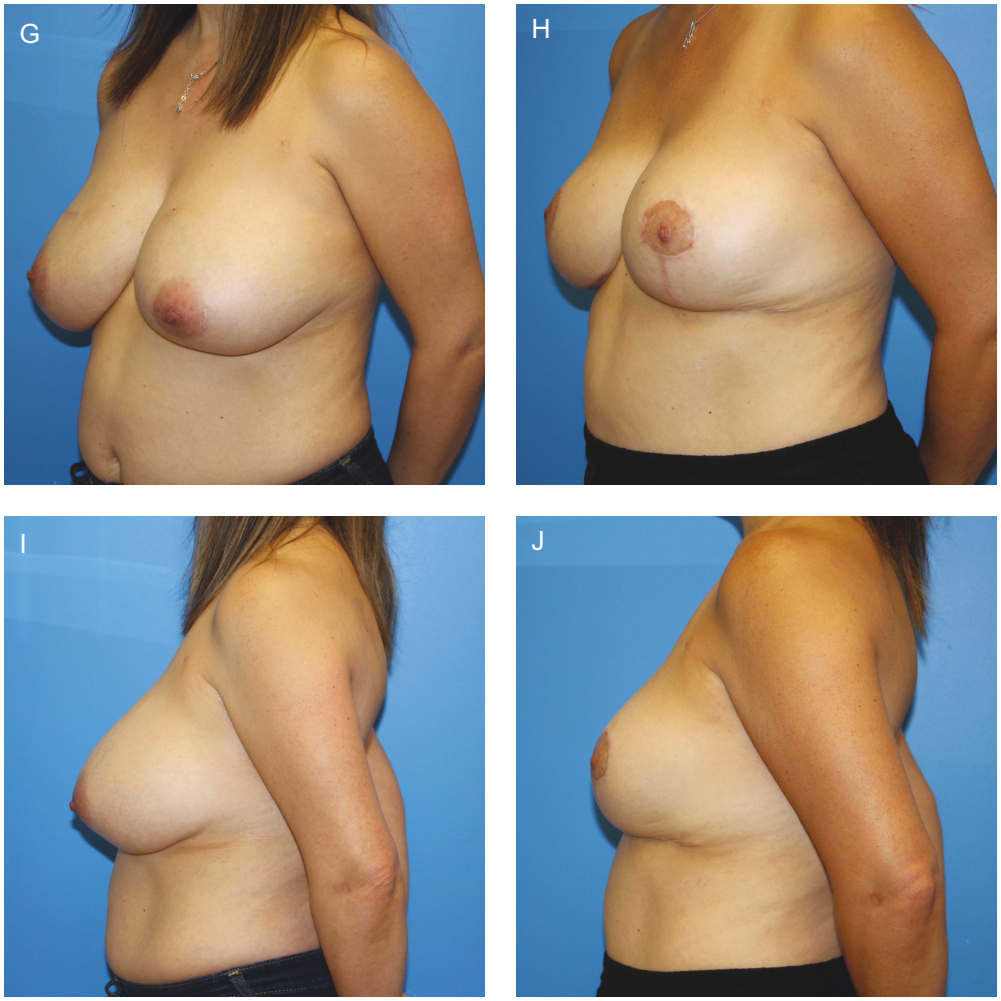

Figure 7. Continued.

result was also not sustained with progressive lower pole drop-down issues.

The senior author then proceeded to use the superomedial pedicle, with the recruitment of the second and third perforators of the internal mammary axis.[17] This created better results, as the inferior pole was removed, and there was a robust blood supply from the 2 perforators. Attempts were made at this stage of the evolution to use only a single vertical scar espoused by proponents of this technique. However, some issues persisted. It was surgically more challenging to inset the pedicle into the mosque dome, and there were significant problems with dog ears at the inferior pole of the breasts. The latter created a much higher revisional rate than acceptable. This experience is consistent with other studies in the literature, which reported revisional rates greater than 5% with the vertical scar technique.[11,18-20] These revisional rates were greater than those with Wise pattern inverted T techniques.[18,19] A change was necessary to remediate these issues which finally evolved into the current technique. The medial pedicle technique improved ease of inset, which is consistent with other views reported in the literature.[21-23] Despite the fact that the medical pedicle recruits a single blood supply from the third perforator of the internal mammary artery, the results in this study have demonstrated that the blood supply to the NAC is adequate, as there was only one case of partial nipple loss. Others have commented on the adequacy of the blood flow to the NAC when using a medial pedicle technique.[24] The horizontal skin excision technique for dog ear removal used in this study has also been supported by other authors.[25]

There are other elements of our proposed technique that contribute to successful results and low complication rates. One critical piece of this operative technique was the infiltration of short-lasting local anesthetic with epinephrine dominantly in the lateral and inferior poles of the breast. This aided in efficient, sharp dissection with reduced operative blood loss.[26] Furthermore, the low rates of wound-healing complications may be partially explained

Figure 8. A 47-year-old female patient is shown (A, C, E, G, I) before breast reduction and (B, D, F, H, J) 1 year following breast reduction.

by the use of barbed suture technology.[27] Arnica was recommended in oral and ointment form to reduce bruising, which we believe did aid in earlier recovery.[28] Finally, scar management was done for a minimum of 6 months with a combination of taping and Vitamin E cream massage, which is supported by the literature.[29] Complication rates

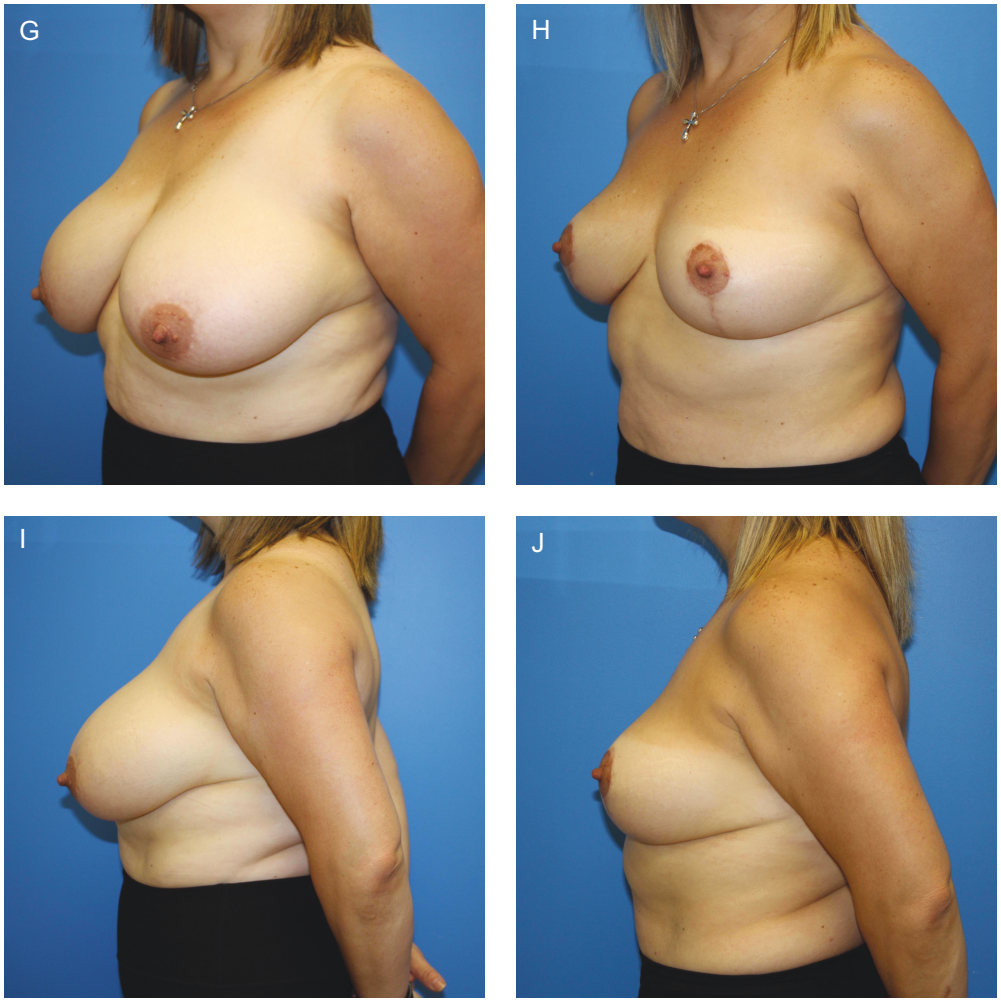

Figure 8. Continued.

in this study were low and were comparable to others in the literature.[4,7,10,30]

The 15-9-9 framework presented in this article is a new insight into medial pedicle breast reduction markings that has not been described elsewhere in the literature. We believe that this approach to preoperative markings yields favorable results and is easy to learn and to teach. In addition to the improved ease of preoperative markings, the operative technique that we have described is reliable and achieves consistent results. The simplified approach to breast reduction in our retrospective single-surgeon review provides a sound approach to performing and achieving good outcomes for this common plastic surgical procedure.

Limitations

The major limitation of this study is the retrospective nature of it. A prospective study would have resulted in more robust data collection and results. Surgical outcomes could have been better evaluated by measuring the final SNA/SNN distance at the final follow-up visit to obtain more accurate results pertaining to the final positioning of the NAC. Furthermore, patient satisfaction and relief of macromastia could have been assessed through a standardized patient survey at follow-up visits during the postoperative period. It would have also been advantageous to have an independent external review of aesthetic outcomes with a panel of plastic surgeons. Another limitation of this study is the inability to comment on the efficacy of this technique for large volume reductions exceeding 1 kg per breast. There were only 2 patients in our study who had large volume reductions exceeding 1 kg. Of these, the only complication was a single dog ear that was removed. Other studies have demonstrated that the medial pedicle combined with an inverted T or Wise pattern skin excision is a safe and reliable technique for severe mammary hypertrophy that yields excellent long-term results

Figure 9. A 40-year-old female is shown (A, C, E, G, I) before breast reduction and (B, D, F, H, J) 1 year following breast reduction.

with few complications.[23,24] Finally, this study was limited to a single plastic surgeon's practice at a single institution. This technique should be trialed by other plastic surgeons to provide further insights into the ease and reliability of the technique.

CONCLUSIONS

This paper presents a retrospective review of a medial pedicle technique with specific design modifications using the 15-9-9 framework to give stable results. This is

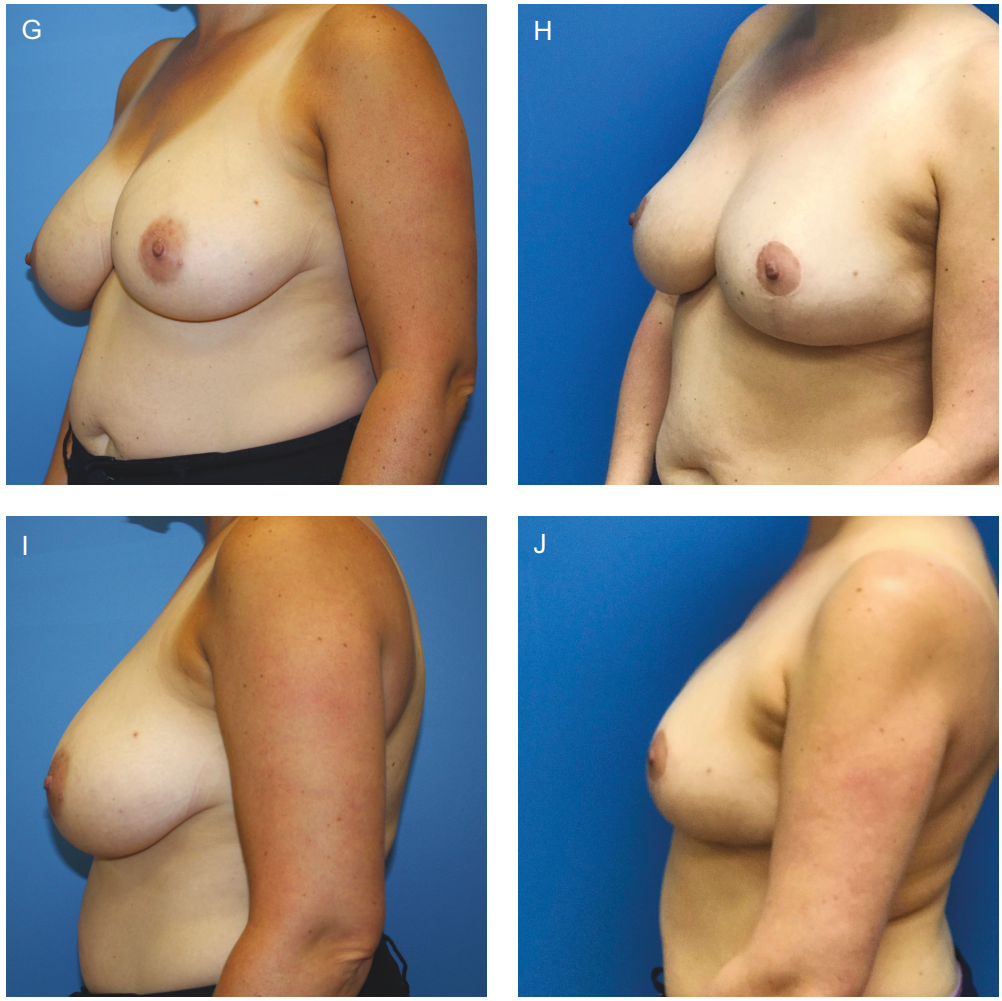

Figure 9. Continued.

easy to learn and teach to any plastic surgeon or trainee wanting to learn the essential technique of breast reduction.

Disclosures

The authors declared no potential conflicts of interest with respect to the research, authorship, and publication of this article.

Funding

The authors received no financial support for the research, authorship, and publication of this article.

REFERENCES

1. Aesthetic Plastic Surgery National Databank: Statistics 2020. *Aesthet Surg J.* 2021;41(Supplement_2):1-16. doi: 10.1093/asj/sjab178
2. Fernandez S, Coady L, Cohen-Shohet R, Molas-Pierson J, Mast BA. Comparative outcomes and quality analysis of inverted-T and pure vertical scar techniques in superomedial pedicle reduction mammaplasty. *Ann Plast Surg.* 2016;76:S328-S331. doi: 10.1097/SAP.0000000000000732
3. Uslu A, Korkmaz MA, Surucu A, Karaveli A, Sahin C, Ataman MG. Breast reduction using the superomedial pedicle- and septal perforator-based technique: our clinical experience. *Aesthetic Plast Surg.* 2019;43(1):27-35. doi: 10.1007/s00266-018-1177-z
4. Manahan MA, Buretta KJ, Chang D, Mithani SK, Mallalieu J, Shermak MA. An outcomes analysis of 2142 breast reduction procedures. *Ann Plast Surg.* 2015;74(3):289-292. doi: 10.1097/SAP.0b013e31829d2261
5. Hammond DC, Loffredo M. Breast reduction. *Plast Reconstr Surg.* 2012;129(5):829e-839e. doi: 10.1097/PRS.0b013e31824a2efc
6. Greco R, Noone B. Evidence-based medicine: reduction mammaplasty. *Plast Reconstr Surg.* 2017;139(1):230e-239e. doi: 10.1097/PRS.0000000000002856
7. Antony AK, Yegiyants SS, Danielson KK, et al. A matched cohort study of superomedial pedicle vertical scar breast reduction (100 breasts) and traditional inferior pedicle Wise-pattern reduction (100 breasts): an outcomes study over 3 years. *Plast Reconstr Surg.* 2013;132(5):1068-1076. doi: 10.1097/PRS.0b013e3182a48b2d

8. Colohan SM, Massenburg BB, Gougoutas AJ. Breast reduction: surgical techniques with an emphasis on evidence-based practice and outcomes. *Plast Reconstr Surg*. 2020;146(3):339e-350e. doi: 10.1097/PRS.0000000000007263
9. McCulley SJ, Schaverien MV. Superior and superomedial pedicle wise-pattern reduction mammaplasty: maximizing cosmesis and minimizing complications. *Ann Plast Surg*. 2009;63(2):128-134. doi: 10.1097/SAP.0b013e318188d0be
10. Ogunleye AA, Leroux O, Morrison N, Preminger AB. Complications after reduction mammaplasty: a comparison of wise pattern/inferior pedicle and vertical scar/superomedial pedicle. *Ann Plast Surg*. 2017;79(1):13-16. doi: 10.1097/SAP.0000000000001059
11. James A, Verheyden C. A Retrospective study comparing patient outcomes of wise pattern-inferior pedicle and vertical pattern-medial pedicle reduction mammoplasty. *Ann Plast Surg*. 2011;67(5):481–483. doi: 10.1097/SAP.0b013e3181fc0523
12. van Deventer PV, Graewe FR. Enhancing pedicle safety in mastopexy and breast reduction procedures: the posteroinferomedial pedicle, retaining the medial vertical ligament of Würinger. *Plast Reconstr Surg*. 2010;126(3):786-793. doi: 10.1097/PRS.0b013e3181e5f7da
13. Canadian Institutes of Health Research, Natural Sciences and Engineering Research Council of Canada, Social Sciences and Humanities Research Council. Tri-Council Policy Statement: Ethical Conduct for Research Involving Humans – TCPS 2 (2018). Published April 1, 2019. https://ethics.gc.ca/eng/policy-politique_tcps2-eptc2_2018.html. Accessed January 16, 2022.
14. Srinivasaiah N, Iwuchukwu OC, Stanley PRW, Hart NB, Platt AJ, Drew PJ. Risk factors for complications following breast reduction: results from a randomized control trial. *Breast J*. 2014;20(3):274-278. doi: 10.1111/tbj.12256
15. Nelson RA, Colohan SM, Sigurdson LJ, Lalonde DH. Practice profiles in breast reduction: a survey among Canadian plastic surgeons. *Can J Plast Surg*. 2008;16(3):157-161. doi: 10.1177/229255030801600311
16. Brown RH, Izaddoost S, Bullocks JM. Preventing the "bottoming out" and "star-gazing" phenomena in inferior pedicle breast reduction with an acellular dermal matrix internal brassiere. *Aesthetic Plast Surg*. 2010;34(6):760-767. doi: 10.1007/s00266-010-9538-2
17. Hall-Findlay EJ, Shestak KC. Breast reduction. *Plast Reconstr Surg*. 2015;136(4):531e-544e. doi: 10.1097/PRS.0000000000001622
18. Rinker B. Lowering revision rates in medial pedicle breast reduction by the selective addition of "Inverted-T" technique. *Aesth Plast Surg*. 2013;37(2):341-348. doi: 10.1007/s00266-013-0061-0
19. Cruz-Korchin N, Korchin L. Vertical versus wise pattern breast reduction: patient satisfaction, revision rates, and complications. *Plast Reconstr Surg*. 2003;112(6):1573-1578; discussion 1579. doi: 10.1097/01.PRS.0000086736.61832.33
20. Serra MP, Longhi P, Sinha M. Breast reduction with a superomedial pedicle and a vertical scar (Hall-Findlay's technique): experience with 210 consecutive patients. *Ann Plast Surg*. 2010;64(3):275-278. doi: 10.1097/SAP.0b013e3181b0a611
21. Lista F, Ahmad J. Vertical scar reduction mammaplasty: a 15-year experience including a review of 250 consecutive cases. *Plast Reconstr Surg*. 2006;117(7):2152-2165; discussion 2166. doi: 10.1097/01.prs.0000218173.16272.6c
22. Hall-Findlay EJ. Invited Discussion on: Superomedial pedicle breast reduction for gigantic breast hypertrophy: experience in 341 breasts and suggested safety modifications. *Aesth Plast Surg*. 2021;45(2):386-389. doi: 10.1007/s00266-020-02065-7
23. Nahabedian MY, McGibbon BM, Manson PN. Medial pedicle reduction mammaplasty for severe mammary hypertrophy. *Plast Reconstr Surg*. 2000;105(3):896-904. doi: 10.1097/00006534-200003000-00011
24. Abramson DL, Pap S, Shifteh S, Glasberg SB. Improving long-term breast shape with the medial pedicle wise pattern breast reduction. *Plast Reconstr Surg*. 2005;115(7):1937-1943. doi: 10.1097/01.PRS.0000165085.23537.A7
25. Roei S, Gal B, Tariq Z, et al. Superiomedial pedicle breast reduction for gigantic breast hypertrophy: experience in 341 breasts and suggested safety modifications. *Aesthetic Plast Surg*. 2021;45(2):375-385. doi: 10.1007/s00266-020-01973-y
26. Hardwicke JT, Jordan RW, Skillman JM. Infiltration of epinephrine in reduction mammaplasty: a systematic review of the literature. *Plast Reconstr Surg*. 2012;130(4):773-778. doi: 10.1097/PRS.0b013e318262f085
27. Hurwitz DJ, Reuben B. Quill barbed sutures in body contouring surgery: a 6-year comparison with running absorbable braided sutures. *Aesthet Surg J*. 2013;33(3 Suppl):44S-56S. doi: 10.1177/1090820X13498506
28. Knackstedt R, Gatherwright J. Perioperative homeopathic Arnica and Bromelain: current results and future directions. *Ann Plast Surg*. 2020;84(3):e10-e15. doi: 10.1097/SAP.0000000000002043
29. Tran B, Wu JJ, Ratner D, Han G. Topical scar treatment products for wounds: a systematic review. *Dermatol Surg*. 2020;46(12):1564-1571. doi: 10.1097/DSS.0000000000002712
30. Cunningham BL, Gear AJL, Kerrigan CL, Collins ED. Analysis of breast reduction complications derived from the BRAVO study. *Plast Reconstr Surg*. 2005;115(6):1597-1604. doi: 10.1097/01.PRS.0000160695.33457.DB