



Endoscopic-Assisted Percutaneous Sigmoidopexy: New Highlights on Technique and Outcomes

Abdel Rahman A Al Manasra ¹, Tarik Alhmoud², Zaid Mesmar¹, Ahmad Hamaydeh ¹

¹Department of General Surgery, Faculty of Medicine, Jordan University of Science and Technology, Irbid, Jordan; ²Department of Internal Medicine, Faculty of Medicine, Jordan University of Science and Technology, Irbid, Jordan

Correspondence: Abdel Rahman A Al Manasra, Department of General Surgery and Urology, Jordan University of Science and Technology, Faculty of Medicine, P.O. Box 3030, Irbid, Jordan, Tel +962 796453510, Email aaalmanasra@just.edu.jo

Background: Sigmoid volvulus is primarily a disease of the elderly.

Case Presentation: We describe a case of recurrent sigmoid volvulus in an elderly woman who refused surgery due to the high risk posed by general anesthesia and surgical intervention. She underwent endoscopic-assisted percutaneous sigmoidopexy using only three 2-shot anchor sets. No radiographic observation was necessary during the procedure. Some puncture sites were secured using endoscopic clips.

Conclusion: Endoscopic-assisted percutaneous sigmoidopexy is increasingly used as an effective alternative to surgical sigmoidopexy when surgery under general anesthesia poses a high risk. Despite clinical improvement and resolution of the recurrent volvulus, after sigmoidopexy patients may continue to experience motility dysfunction and diffuse dilation of the colon for a few weeks, which may correlate with the episodes of obstruction experienced prior to fixation.

Keywords: sigmoidopexy, volvulus, percutaneous, anchor suture

Introduction

Volvulus is an abnormal twisting of the intestines which results in luminal obstruction and impaired blood supply to the involved segment.¹ Multiple factors have been implicated in this condition, including chronic constipation, intestinal malrotation, Hirschsprung's disease and neuropsychiatric disorders. The sigmoid colon and cecum are the most commonly affected parts of the intestines.

Endoscopic decompression or a barium enema are usually attempted. Operative intervention is recommended during patients' index admission or soon thereafter.

Since adult-onset volvulus is more prevalent among elderly patients, co-morbid illnesses frequently preclude surgical intervention and general anesthesia. Less invasive treatment options include percutaneous endoscopic colostomy and percutaneous endoscopic-assisted sigmoidopexy. Both interventions are performed using topical anesthesia and minimal sedation. We present a case of endoscopic-assisted percutaneous sigmoidopexy for recurrent sigmoid volvulus in an elderly patient who refused surgery and general anesthesia due to high risk. We applied several technical modifications as discussed below.

Case Report

An 82-year-old female patient, who is a known case of diabetes mellitus (DM), hypertension and cerebral vascular accident with residual dysarthria and right-sided weakness, classified as American Society of Anesthesiologists (ASA) physical status III–IV, had six previous episodes of sigmoid volvulus that were treated with colonoscopic detorsion.

During her latest admission to our facility, she had typical symptoms and signs of recurrent sigmoid volvulus, including severe abdominal pain, distention and inability to pass stool or flatus. She manifested no fever or vomiting. On examination, no signs of peritonitis were present. The rectal vault was empty. Abdominal X-ray was consistent with sigmoid volvulus.

Upon admission, electrolyte deficits were replenished, and potassium and magnesium levels were normalized. The patient underwent an urgent colonoscopy which successfully reversed the volvulus; rectal tube was left in place.

Given the high risk of recurrence, surgical treatment with sigmoidectomy was discussed with the patient. However, the patient refused to consent to the operation given the high risk posed by surgery and anesthesia. The patient and her family were offered an alternative intervention using transcutaneous sigmoidopexy in order to prevent further episodes.

Procedure

After explaining the procedure benefits, risks and alternatives, an informed consent to perform the procedure was obtained; another written informed consent was provided by the patient and her family to have the case details and any accompanying images published. The patient was placed in a semi-lateral position on an endoscopy unit bed. The abdomen was prepped and draped, and 50 mg of intravenous (IV) fentanyl was administered for sedation. The scope passed until the sigmoid colon was reached. The sigmoid was still dilated but not twisted. A scope light was used for transillumination to confirm the sigmoid position was close to the abdominal wall (**Figure 1**). The sites of all punctures were guided by endoscopic view. Following infiltration of local analgesia (1% lidocaine), a syringe was attached, and then a 17Fr needle was inserted through the abdominal wall (Entuit secure gastrointestinal suture anchor set, COOK Medical, IN, USA) (**Figure 2**); the needle was thrust into the sigmoid colon and its position verified. Tension was maintained on the trailing suture and the syringe was disconnected. A wire was introduced into the needle to release the internal anchor, and then the needle was removed. While the guide-wire was still in position, traction was applied to the suture to maintain the position of the anterior wall of the sigmoid against the abdominal wall. The guide-wire was then removed, while maintaining traction on the suture anchor. Another suture anchor from the same set was introduced in close proximity to the initial one (1–2 cm apart); both sutures were ligated together, and the resulting knot was buried into the subcutaneous tissue.

The maneuver was repeated twice using two more double sets of suture anchors; the three sets formed a Mercedes-Benz sign pattern, at about 10 cm distance from each other, anchoring a triangular area of the sigmoid to the abdominal wall (**Figure 3**).

One of the luminal puncture sites was secured by an endoscopic clip after withdrawal of the needle. No radiographic observation (fluoroscopy) was necessary during the procedure. The patient was discharged after overnight observation for signs of peritoneal irritation and sepsis.

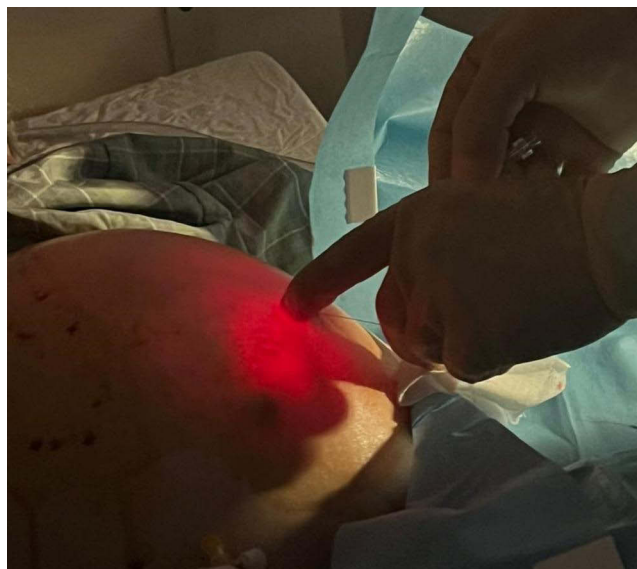

Figure 1 Colonoscopic transillumination through sigmoid and abdominal walls.




Figure 2 Suture anchor set showing the needle and T fastener.

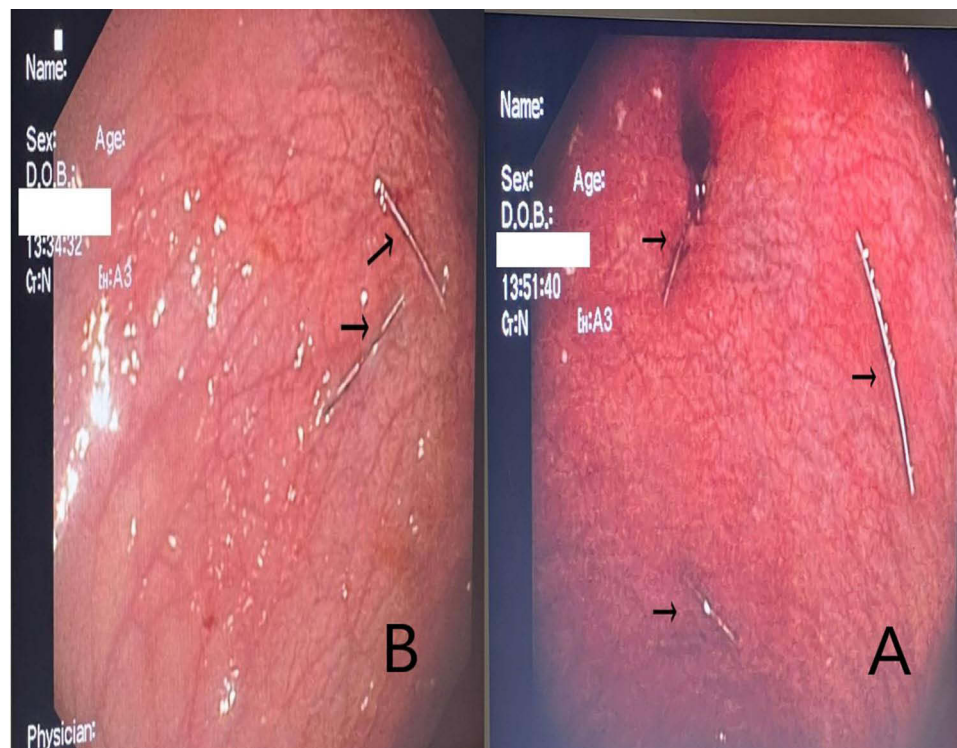


Figure 3 (A) Endoscopic view of the three paired anchor shots (tips of arrows) disposed in a triangular fashion, (B) Endoscopic view of one pair of the anchor shots (tips of arrows).

The interval follow-up at four weeks after sigmoidopexy revealed persistent abdominal distension and diffuse colon dilation consistent with chronic intestinal pseudo-obstruction (CIPO), probably due to multiple previous volvulus episodes. Abdominal X-ray showed diffuse colon dilation with some fecal loading. This was treated with laxatives and enemas. Sigmoidoscopy was necessary once after two weeks; the rectal tube was left in place for 24 hrs to decompress the colon.

The patient subsequently continued to have regular bowel habits (using laxatives as needed) and required no further hospitalizations. There was no recurrence of volvulus at the three-month follow-up.

Discussion

We describe a case using an endoscopic-assisted approach to sigmoidopexy using T-fasteners, performed under a combination of conscious sedation and topical anesthesia. The technique involved few modifications from previously described reports. First, sigmoidopexy was performed using only three 2-shot anchor sets. Second, no radiographic observation was necessary during the procedure, which was performed in the endoscopy unit. The colon was extremely dilated and the patient was underweight, which made scope trans-abdominal illumination adequate. Third, one of the puncture sites was secured using an endoscopic clip, after it showed minor bleeding and gas bubbling after needle withdrawal. This was secondary to the use of the wide-bore needle (17F) included in the kit to introduce the thread and wire through the sigmoid wall.

Different endoscopic-assisted percutaneous techniques have been described for the management of recurrent sigmoid volvulus. These include percutaneous endoscopic colostomy (PEC)² and percutaneous endoscopic sigmoidopexy (PES). The first modality, PEC, is associated with a relatively higher incidence of immediate and late serious adverse events, which makes PES more popular among gastroenterologists and surgeons.

The first report of percutaneous endoscopic sigmoidopexy dates to 1998, in Glasgow, the UK, where a 93-year-old woman with multiple comorbidities underwent endoscopic-assisted three-point fixation of the sigmoid using percutaneous gastrostomy equipment (PEG). The procedure was successfully conducted after five episodes of sigmoid volvulus the patient had experienced over six years.³

A larger series of six patients revealed a variety of complications secondary to sigmoidopexy, including skin infection, sepsis, transient subcutaneous emphysema, recurrence of volvulus, and peritonitis due to colon perforation at the fixation site early after the procedure. One patient was admitted after one month with small bowel obstruction thought to be resulting from internal herniation between fixation points; the obstruction was resolved by releasing the sigmoidopexy sutures.⁴ In 2001, Pinedo and Kirberg described fixation using three T-fasteners in a triangular disposition; they intentionally cut the T-fasteners at the skin after 28 days, and no complications were reported.⁵

There is no consensus on the minimum number of T-fasteners to be used for fixation. Imakita et al, for example, stated that fixation was repeated at 5 to 10 sites (average 8.8).⁶ The number may be affected by the length of twisted segment, the proximity of the colon to the abdominal wall at different spots, or the thickness or contour of the patient's abdomen. However, from a surgical perspective, we advise the disposition of sutures in a triangular shape, as this may reduce the risk of internal herniation.

Negm et al conducted the first prospective randomized trial to compare endoscopic-assisted sigmoidopexy to the classic surgical treatment. Both groups of patients demonstrated similar rates of non-recurrence. Endoscopic fixation was associated with better postoperative quality of life, shorter hospital stays and shorter procedure times, but did not show significant differences in terms of post-operative complications.⁷

This procedure has certain per-requirements and limitations. It is essential to confirm successful repositioning of the sigmoid prior to fixation. In addition, the colon has to be close enough to the abdominal wall with no small bowel loops or stomach in between. The feasibility of this procedure seems to be impacted by multiple other factors, including central obesity, ventral hernias and previous abdominal surgeries.

The procedure's primary goal is to achieve sigmoid fixation with no recurrence of volvulus. However, it is worth mentioning that the patient may continue to experience colonic dilation and distension. The risk of distension appears to be directly proportional to the number of volvulus episodes which occurred prior to the sigmoidopexy, as well as to the duration of malrotation at each episode. Both factors may contribute to motility dysfunction (constipation) and distension that may persist after the procedure for a few weeks. In our case, this was managed successfully using a combination of laxatives and endoscopic decompression.

Conclusions

Endoscopic-assisted percutaneous sigmoidopexy is increasingly used as an effective alternative to surgical sigmoidopexy when surgery or general anesthesia pose a high risk. Despite clinical improvement and resolution of the recurrent

volvulus, sigmoidopexy patients may continue to have motility dysfunction and diffuse dilation of the colon for a few weeks, which may correlate with the episodes of obstruction experienced prior to fixation.

Data Sharing Statement

All data generated or analyzed during this study are included in this article.

Ethics Approval and Informed Consent

Ethical approval has been waived by the local IRB committee (Jordan university of science and technology committee), because of the retrospective nature of the case report. The study participant has given consent to participate in this study.

Consent for Publication

The study participant has given consent to participate as well as consent to publish the data represented in this manuscript.

Funding

The authors declare that no funds, grants, or other supports were received during the preparation of this manuscript.

Disclosure

The authors declare no conflicts of interest related to this work.

References

1. Le CK, Nahirniak P, Anand S, et al. Volvulus. In: *StatPearls*. Treasure Island (FL): StatPearls Publishing; 2023
2. Tun G, Bullas D, Bannaga A, Said EM. Percutaneous endoscopic colostomy: a useful technique when surgery is not an option. *Ann Gastroenterol*. 2016;29(4):477–480. doi:10.20524/aog.2016.0058 PMID: 27708513; PMCID: PMC5049554.
3. Choi D, Carter R. Endoscopic sigmoidopexy: a safer way to treat sigmoid volvulus? *J R Coll Surg Edinb*. 1998;43(1):64. PMID:9560517.
4. Gallagher HJ, Aitken D, Chapman AH, Ambrose NS. Additional experience of endoscopic T-bar sigmoidopexy. *Dis Colon Rectum*. 2002;45(11):1565–1566. PMID: 12432311. doi:10.1007/s10350-004-6470-z
5. Pinedo G, Kirberg A. Percutaneous endoscopic sigmoidopexy in sigmoid volvulus with T-fasteners: report of two cases. *Dis Colon Rectum*. 2001;44(12):1867–1869. doi:10.1007/BF02234469 PMID: 11742176.
6. Imakita T, Suzuki Y, Ohdaira H, Urashima M. Colonoscopy-assisted percutaneous sigmoidopexy: a novel, simple, safe, and efficient treatment for inoperable sigmoid volvulus (with videos). *Gastrointest Endosc*. 2019;90(3):514–520. doi:10.1016/j.gie.2019.04.246 PMID: 31077700.
7. Negm S, Farag A, Shafiq A, et al. Endoscopic management of acute sigmoid volvulus in high risk surgical elderly patients: a randomized controlled trial. *Langenbecks Arch Surg*. 2023;408:338. doi:10.1007/s00423-023-03071-4

Clinical and Experimental Gastroenterology

Dovepress

Publish your work in this journal

Clinical and Experimental Gastroenterology is an international, peer-reviewed, open access, online journal publishing original research, reports, editorials, reviews and commentaries on all aspects of gastroenterology in the clinic and laboratory. This journal is indexed on American Chemical Society's Chemical Abstracts Service (CAS). The manuscript management system is completely online and includes a very quick and fair peer-review system, which is all easy to use. Visit <http://www.dovepress.com/testimonials.php> to read real quotes from published authors.

Submit your manuscript here: <https://www.dovepress.com/clinical-and-experimental-gastroenterology-journal>