



# Pelvic floor myofascial manipulation combined with Kegel exercise and mecobalamin in the treatment of atypical diabetic neurogenic bladder: a case report

Hui-Yu Jiang<sup>#</sup>, Yan-Qing Chen<sup>#</sup>, Ju-Hui Li, Zhao-Wei Wang

Department of Rehabilitation, The Second Affiliated Hospital of Hainan Medical University, Haikou, China

*Contributions:* (I) Conception and design: HY Jiang; (II) Administrative support: ZW Wang; (III) Provision of study materials or patients: HY Jiang; (IV) Collection and assembly of data: YQ Chen; (V) Data analysis and interpretation: JH Li; (VI) Manuscript writing: All authors; (VII) Final approval of manuscript: All authors.

<sup>#</sup>These authors contributed equally to this work and should be considered as co-first authors.

*Correspondence to:* Zhao-Wei Wang. Department of Rehabilitation, The Second Affiliated Hospital of Hainan Medical University, Haikou 570311, China. Email: transtty@163.com.

**Background:** Diabetic neurogenic bladder (DNB) is one of the autonomic neuropathies of diabetes mellitus (DM), with an incidence rate reaching 40–60%. This study combined bladder function rehabilitation training and mecobalamin to treat a patient with DNB to provide reference for clinical work.

**Case Description:** A 67-year-old woman was admitted to our hospital on 5 December 2018, with a 3-year history of dysuria that had progressively worsened for 15 days. The patient was treated with pelvic floor myofascial manipulation combined with Kegel training and mecobalamin for 6 months. Pelvic organ prolapse (POP), pelvic floor surface electromyography (EMG), psychological status, and quality of life were evaluated before, during, and after treatment, and the changes in urodynamics were observed. After comprehensive rehabilitation treatment, the patient's POP, pelvic floor muscle strength, mental state, and quality of life were significantly improved. The results of the urodynamic examination showed that the patient's safe bladder capacity reached 500 mL after treatment, in contrast to the first safe bladder capacity measurement of 90 mL. The symptoms of ureteral reflux disappeared, the detrusor compliance increased from 2 to 20 mL/cmH<sub>2</sub>O, which roughly indicated a return to healthy function. However, there was no detrusor contraction in the bladder during urination.

**Conclusions:** This patient achieved good curative effect after the treatment of comprehensive pelvic floor rehabilitation combined with mecobalamin. However, the safe capacity of the patient reported in this case showed a small bladder safe capacity, and the patient's detrusor muscle did not contract during urination. Thus, urination in this patient may be accomplished by increasing abdominal pressure. When treating patients with atypical neurogenic bladder, the adverse effects caused by excessive abdominal pressure and abdominal wall relaxation need to be considered.

**Keywords:** Neurogenic bladder; pelvic floor fascia; Kegel training; exercise therapy; case report

Submitted Nov 21, 2022. Accepted for publication Jan 06, 2023. Published online Jan 11, 2023.

doi: 10.21037/tau-22-840

**View this article at:** <https://dx.doi.org/10.21037/tau-22-840>

## Introduction

Diabetic neurogenic bladder (DNB) (1), also known as diabetic cystopathy (DCP), is one of the autonomic neuropathies of diabetes mellitus (DM), with an incidence rate reaching 40–60% (2). DCP can be manifested as various types of bladder dysfunction, among which the increase in bladder residual urine (BRU) is predominant. The increased BRU is generally due to intermittent and prolonged urination due to involvement of the detrusor autonomic nerve. Further, the lesions involve the trigone of the bladder and sphincter vesicae, which prevents the bladder from emptying properly, often resulting in urinary retention and secondary infection (3). In diabetic patients, due to metabolic disorders, vascular disorders, nerve conduction disorders, and other causes, the peripheral nerves that innervate the bladder and urethral sphincter are damaged, resulting in a neurogenic bladder (4). Furthermore, DNB may eventually develop into a series of complications such as stubborn urinary tract infection, renal failure, hydronephrosis, and so on, which seriously endanger the health and quality of life of patients (5).

Because the etiology of DNB is not completely clear and the pathogenesis is complex, there is no effective clinical treatment. Clinically, comprehensive treatment measures are used, such as controlling plasma glucose, using neurotrophic drugs such as methyl B12 and gangliosides, and nerve growth factors (6). However, the clinical efficacy is often unsatisfactory, and there is still an

urgent need to explore more effective methods to solve the problem. For patients with DNB, improving urodynamics and avoiding or reducing residual urine volume are the keys to preventing and treating the disease (7,8). Mecobalamin, as endogenous coenzyme B12, improves the conduction of nerve origin, promotes nerve repair, and contributes to the recovery of the neurogenic bladder (6). Comprehensive rehabilitation helps to improve the metabolic level of bladder muscle and pelvic floor muscle group, and facilitates recovery of bladder function. The clinical treatment of DNB is mostly drug based. There are few reports on cases of pelvic floor rehabilitation treatment of urinary retention caused by DNB and causing moderate fluid accumulation in both kidneys. Therefore, this study combined bladder function rehabilitation training and mecobalamin to treat a patient with DNB, and found that the clinical effect was satisfactory. We present the following article in accordance with the CARE reporting checklist (available at <https://tau.amegroups.com/article/view/10.21037/tau-22-840/rc>).

## Case presentation

### Case

All procedures performed in this study were in accordance with the ethical standards of the institutional and/or national research committee(s) and with the Declaration of Helsinki (as revised in 2013). Written informed consent was obtained from the patient for publication of this case report. A copy of the written consent is available for review by the editorial office of this journal.

A 67-year-old woman was admitted to our hospital on 5 December 2018, with a 3-year history of dysuria that had progressively worsened for 15 days. The patient's fasting blood glucose was 15.87 mmol/L. She had symptoms of frequent urination, urgency, and dysuria. The patient urinated 9–10 times at night without gross hematuria, accompanied by orthostatic leakage, difficulty urinating, a feeling of incessant dripping, and in severe cases, an inability to urinate. The patient had difficulty defecating, opening her bowel once every 5–6 days, with dry stool. She presented with pain in the lower back and perineum on the right side. She had sleep disturbance, difficulty falling asleep, and a low mood. Based on urodynamic findings, the patient's neurogenic bladder was classified as a detrusor reflector according to the Krane-Siroky classification (9).

The patient's medical history was as follows. Four years

### Highlight box

#### Key findings

- This study combined bladder function rehabilitation training and mecobalamin to treat a patient with DNB, and found that the clinical effect was satisfactory.

#### What is known and what is new?

- For patients with DNB, improving urodynamics and avoiding or reducing residual urine volume are the keys to preventing and treating the disease.
- This study discussed the clinical treatment of a patient with atypical DNB.

#### What is the implication, and what should change now?

- Based on the lack of evidence-based medical data for such cases, this article can only be analyzed in the form of a case report. There remains a need for more original research to support the treatment of DNB. Further clinical experimental research for exploration is also necessary.

ago, she had experienced a fracture of the right tibia and fibula due to a fall and underwent internal fixation of the fracture in a hospital in Hainan. On admission, the blood sugar was 22.3 mmol/L, but the patient had been unaware that her blood sugar was elevated. In addition, the individual denied a history of DM and had not pursued the relevant treatment.

The patient's admission diagnosis was as follows: (I) type 2 DNB; (II) urinary tract infection; (III) hypertension grade 3.

### *Examination and assessment*

#### **Gynecological examination**

The gynecological examination showed normal labium majus pudendi and labium minus, uniform distribution of pubic hair, widened pudendal cleft, and residual leucorrhea secretion between the labia majora and labia minora, with a peculiar smell (urine smell). Hemorrhoids were visible in the external anal sphincter. The Valsalva maneuver showed the anterior and posterior walls of the vagina and the posterior horn of the bladder. The manual exam showed that the front and rear walls of the vagina were distended, the uterus was soft, and the pelvic floor muscles were loose. The levator ani, coccygeus, obturator internus, and arcus tendineus levator ani all had tenderness of varying degrees [a cord could be touched at the attachment of the bilateral iliococcygeus and ischiococcygeus, and it was painful to press, the visual analog scale (VAS) score was 3 points]. She had flabby and weak abdominal muscles, poor pelvic-abdominal coordination, weak active contraction, and obvious compensation of the hip muscles.

#### **Urinary system examination**

On 5 December 2018, a B-ultrasound of the urinary system was performed, which showed moderate effusion in both kidneys, cysts in both kidneys, full dilation of bilateral ureters, rough and thickened bladder wall, and a residual urine volume of about 526 mL in the bladder.

On 12 December 2018, a urodynamic examination was performed, which indicated that the bladder sensitivity was increased during storage, the safe volume was about 90 mL, and the compliance was significantly reduced (2 mL/cmH<sub>2</sub>O), which may have been caused by contracture after bladder overfill injury. There was no detrusor muscle contraction during urination, and the residual urine volume was about 90 mL. It was considered that the patient may have ureteral reflux and the bulbocavernosus reflex was absent.

#### **Evaluation indicators**

Before and after treatment, the pelvic organ prolapse (POP) quantitative staging method (10) [POP quantification (POP-Q) assessment] and pelvic floor muscle surface electromyography (EMG) (glazer assessment) were used to assess the condition of pelvic floor muscles and organ prolapse. Self-rating anxiety scale (SAS) and self-rating depression scale (SDS) were used to assess psychological state (11). Quality of life was assessed using the 36-item short-form (SF-36) health survey questionnaire.

#### **Treatment**

##### ***Pelvic floor fascia manipulation***

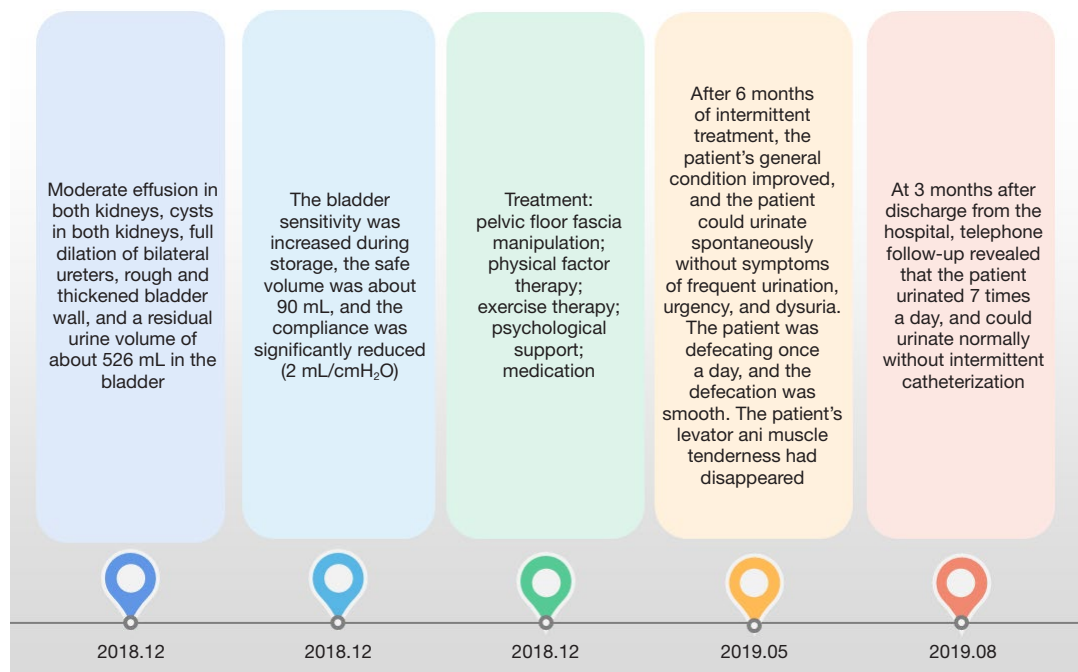
The pelvic floor fascia manipulation was conducted according to the following steps: massage the patient's pelvic floor superficial muscle groups (musculi transversus perinei superficialis, perineal central tendon, and bulbocavernosus). Enter the patient's vagina, find the pelvic floor myofascial trigger point, massage with appropriate pressure on the iliococcygeus muscle, ischiococcygeus, and piriformis muscle, cooperate with the contraction and relaxation of the affected muscle, reduce muscle tension and relieve pain, 15 min/time/day (12).

##### ***Physical factor therapy***

- (I) Pelvic floor muscle biofeedback training (12). Using the Mylander B4PLUS (Medlander, Nanjing, China) biofeedback instrument, fast and slow muscle training and relaxation training were carried out, once a day, 20 min/time.
- (II) Transcutaneous electrical nerve stimulation (13). Neuromuscular electrical stimulation was carried out with Beiyikang transcutaneous electrical nerve stimulator QL/T-III (Beoka, Sichuan, China), the electrodes were placed on both sides of S2–4, and 2 electrodes were placed on the lower abdomen bladder area, 35 Hz, 200 US, once a day, 20 min/time.

##### ***Exercise therapy***

- (I) Strength training: this mainly includes strength training for abdominal muscles, erector spine, and gluteal muscles (14). Training methods: supine position, ankle pump movement of both ankles, glute bridge exercise, balance function training, and so on. Train 3 sets a day with 10 repetitions each.
- (II) Abdominal breathing training: lie on your back, stick your waist to the bed, inhale through your nose and exhale through your nose, inhale deeply/slowly exhale, raise your belly button upwards when you inhale, the belly button and surrounding abdominal wall move



**Figure 1** The brief description of the patient.

toward your lumbar spine when you exhale (15). Train 2 times a day, 15 minutes each time.

- (III) Kegel training: lie on your back, flex your hips and knees, sandwich a 20-cm yoga ball between your knees, and press your fingers to the pelvic wall muscles to stimulate proprioception. The pelvic floor muscles are induced to contract in a circular shape, which is coordinated with the transverse abdominal muscle to exert force in the direction of the navel, and the bilateral costal arches remain stationary. The duration of each contraction was gradually increased from 3 to 5 seconds, followed by a 10-second relaxation. Repeat the process of contraction and relaxation, training 3 sets per day, gradually increasing the repetitions of training from 4 to 10 times per set. At the same time, add advanced training in the lateral position, elbow and knee position, and chest and knee position (6).

#### **Psychological support**

This component should be conducted in a comfortable and quiet environment. During the treatment, cognitive behavioral therapy was used to guide the patient to understand her condition rationally, and to correct her erroneous cognition and behavior. Encourage the patient to express her true thoughts and provide enough psychological support to establish a trusting doctor-patient relationship.

Explain to family members the problems the patient is facing and the prognosis of the disease, and encourage family members to provide the patient with physical and psychological care (16,17).

#### **Medication**

Throughout treatment, the patient took saxagliptin tablets 5 mg [oral once daily (qd)], aspirin enteric-coated tablet 100 mg (oral qd), insulin glargine injection 10 U [subcutaneous once every night (qn)], insulin glulisine injection [6 U, 8 U, 8 U, subcutaneous three times daily (tid)], mecobalamin tablets 500 µg (oral tid), nifedipine controlled release tablet 30 mg (oral qd). The patient's blood glucose was controlled within the normal range as much as possible (18).

A brief description of the patient is shown in *Figure 1*.

#### **Symptoms and functions**

After 6 months of intermittent treatment, the patient's general condition improved, and the patient could urinate spontaneously without symptoms of frequent urination, urgency, and dysuria. The patient was defecating once a day, and the defecation was smooth. The patient's levator ani muscle tenderness had disappeared. She had attained good blood sugar control and the fasting plasma glucose was 6.66 mmol/L. Her signs and symptoms before and after

**Table 1** Changes in the patient's symptoms and signs before and after treatment

Symptom	Before treatment	After treatment
Organ prolapse	Anterior and posterior vaginal wall III degree	Anterior and posterior vaginal wall I degree
Defecation	5–6 times/day, dry	1 time/day, soft
Urination	Intermittent catheterization, 6 times/day	Spontaneous urination, 7 times/day
B-ultrasound BRU	526 mL	13 mL
Hydronephrosis	Moderate	None
Abdominal muscle	Slack	Smooth and firm
Pelvic floor muscle	Tenderness, streak	Tenderness disappears

BRU, bladder residual urine.

**Table 2** Evaluation of psychological state and quality of life before and after treatment

Measure node	SAS	SDS	SF-36
Before treatment	61.0	70.0	49.1
Mid-treatment	45.0	52.5	68.1
After treatment	31.5	33.8	116.8

SAS, self-rating anxiety scale; SDS, self-rating depression scale; SF-36, 36-item short-form.

**Table 3** Glazer assessment of pelvic floor muscles before and after treatment

Measure node	Pre-resting potential	Fast-twitch	Slow-twitch	Stamina	Post-resting potential
Before treatment	3.96	15.60	5.19	3.81	2.29
Mid-treatment	1.87	25.27	9.70	8.25	2.42
After treatment	2.18	35.71	28.34	26.35	5.52

treatment are shown in *Table 1*. At the same time, the patient's anxiety and depression were significantly improved, and her quality of life was also significantly improved (*Table 2*).

### Pelvic floor surface EMG

The pelvic floor EMG was evaluated by Glazer evaluation before and after treatment (19): after treatment, both the fast and slow muscles of the patient improved from the relaxed and weak state before treatment to the normal state, and the patient's resting potential was higher after treatment (*Table 3*).

### OP

A medical examination of the patient on 20 July 2019 indicated that her abdomen was smooth and firm. The Valsalva maneuver showed 1° bulging of the bladder, 1° bulging of the posterior vaginal wall, and hemorrhoids. By

comparing the POP-Q score before and after treatment, the patient had III° bulging of the anterior vaginal wall and II° bulging of the posterior vaginal wall before treatment. After treatment, the prolapse of the anterior vaginal wall was improved from III° to I°, and the prolapse of the posterior vaginal wall was improved to I° from II°. The patient's POP improved significantly (*Table 4*).

### B-ultrasonography and urodynamic tests

On 10 May 2019, the patient's urinary B-ultrasound was reexamined, which showed cysts in both kidneys, right kidney calcifications, right kidney small stones, and no obvious BRU. On 10 May 2019, the urinary catheter was removed as prescribed by the doctor, and intermittent catheterization was performed, 6 times a day. After 1 week, the frequency of intermittent catheterization was reduced to 3 times/day. On 23 May 2019, a re-examination of the

**Table 4** POP-Q score of POP before and after treatment

Measuring position	Before treatment	Mid-treatment	After treatment
Front wall 3 cm point (Aa)	+2	+1	-1
The lowest point of the front wall (Ba)	+3	+2	-1
The most distal end of the external cervical os or vaginal stump (C)	-6	-6	-8
Genital fissure (gh)	4.5	4.5	3.5
Perineal body (pb)	1.5	1.5	2.5
Total vaginal length (Tvl)	7	7	8
3 cm point on the rear wall (Ap)	+1	+0.5	-1
The lowest point of the rear wall (Bp)	+1	+0.5	-1
Posterior fornix (D)	-7	-7	-9

POP-Q, POP quantification; POP, pelvic organ prolapse.

**Table 5** Urodynamic test results before and after treatment

Time	First impression (mL)	Safe bladder capacity (mL)	Residual urine volume (mL)	Bladder sensitivity	Urine leakage	Detrusor stability	Detrusor compliance	Vesicoureteral reflux
2018-12-12	0	90	90	Increased	Yes	Weakness	Significantly reduced (about 2 mL/cmH <sub>2</sub> O)	Yes
2019-04-02	0	230	280	Increased	Yes	Weakness	Significantly reduced (about 5–6 mL/cmH <sub>2</sub> O)	Yes
2019-07-22	102	500	150	Normal	No	Weakness	Basically normal (20 mL/cmH <sub>2</sub> O)	No

urinary system showed that the residual urine volume in the bladder after spontaneous urination was about 13 mL. At 3 months after discharge from the hospital, telephone follow-up revealed that the patient urinated 7 times a day, and could urinate normally without intermittent catheterization.

The patient's urodynamics improved significantly before, during, and after treatment. After treatment, the patient's bladder sensitivity, safe capacity, bladder compliance, and ureteral reflux gradually returned to normal, but the stability of the detrusor remained unchanged (*Table 5*).

## Discussion

Under normal circumstances, the process of urine storage and urination is completed by the coordination among the bladder, urethral smooth muscle, and external urethral sphincter. During storage, the urethra is contracted to prevent urine from flowing out. During urination, the urethra is relaxed to facilitate the excretion of urine. Among these functions, in the control of urethral function, the

sympathetic nerve and  $\alpha 1$  adrenergic receptors play a key role. The mainstream view in recent years has been that neuropathy and detrusor myogenic damage in diabetic patients often induced by disorders of blood glucose metabolism are the main factors for the occurrence of DCP (1). In the early stage of DCP, nerve damage usually starts first. When the sympathetic nerve and  $\alpha 1$  adrenergic receptors are damaged, the urethral contraction or relaxation function that they regulate will be impaired. With the progression of the disease, the detrusor is also damaged in the late stage, and the detrusor cells can be seen to atrophy and decrease. In addition, more collagen and elastic fiber components can be found, and the bladder wall presents a thin and tension-free cystic shape (20). At the same time, the neuropathy is gradually aggravated, leading to obvious adverse consequences such as urinary urgency, frequent micturition, urinary retention, urinary incontinence, and even renal failure and hydronephrosis.

The patient, in this case, was an elderly woman with an atypical DNB. After 6 months of uninterrupted



comprehensive pelvic floor rehabilitation therapy combined with nutritional neurological drugs such as mecobalamin, the patient experienced significant improvements in POP, pelvic floor muscle strength, urodynamics, psychological status, and quality of life.

In pelvic floor comprehensive rehabilitation therapy, percutaneous low-frequency pulsed electrical stimulation therapy can stimulate afferent nerves through continuous low-frequency pulsed current. When afferent nerves are stimulated, the bladder produces a feeling of fullness, which initiates the voiding reflex. Due to its low current intensity, it can protect the afferent nerve from being damaged while ensuring the curative effect. Using biofeedback therapy, the surface EMG activity of the pelvic floor muscles is displayed through the EMG probe in the vagina, and the information of muscle activity is converted into auditory and visual signals and fed back to the patient. In addition, biofeedback therapy can guide patients to perform correct, voluntary pelvic floor muscle contractions, and correct muscle relaxation, weakness, and dysfunction. At the same time, with abdominal breathing, through Valsalva training, the relaxed pelvic floor muscles can learn to contract again and restore coordination (21). The patient was instructed to consciously perform an “O” circular contraction of the pelvic floor muscles dominated by the levator ani. This can enhance the strength of the pelvic floor muscles, improve the function of the pelvic fascia tendinous arch, pubo-urethral ligament, urethra and external urethral ligament, anal sphincter, and have a good effect on the recovery of the anterior and posterior vaginal walls, uterus, bladder, and rectal prolapse (22,23). Abdominal breathing training can move the diaphragmatic muscle up and down by 5 to 10 cm to increase pulmonary ventilation and pulmonary circulation. Abdominal breathing training also has the effect of promoting gastrointestinal motility, accelerating emptying, increasing food intake, smooth defecation, and improving the function of the digestive system (24). For this patient, abdominal breathing training could regulate autonomic nervous function, improve lung ventilation, enhance digestive system function, and relieve stress-induced stress and anxiety. Core stability training applied to this patient could enhance the strength of the patient’s core muscles, optimize the sensory-motor control of the muscles, and improve the stability of the spine and pelvis (25). Among them, static stability training can enhance the tensile strength of muscles and joints and core stability. Dynamic stability training can ensure better energy transfer, improve energy output, force generation, and transfer

efficiency, improve coordination and balance, and enhance proprioception.

The therapist presses the contracture and painful muscles with the fingers perpendicular to the direction of the muscles and performs manipulation of the pelvic floor fascia, which can stretch it, restore blood supply, and relieve pain. Among them, pressing the trigger point can increase the pain threshold of myofascial receptors and reduce pain sensitivity (13). Activating the pelvic floor muscles of the patient in all directions guides the patient to correct circular contractions and improves the coordination of the pelvic and abdominal muscles.

Patients with diabetes and depression have significantly higher disability risk and mortality, and depression is an absolute risk factor for poor compliance in patients with diabetes. In this instance, cognitive-behavioral therapy for patients mainly aims to eliminate bad emotions and behaviors and improve compliance by changing the patients’ bad cognition, thinking, beliefs, and behaviors. These therapies can help patients to become their own therapist and use self-management and regulation techniques to effectively control their cognition and behaviors (26).

This patient was able to urinate on her own after comprehensive pelvic floor rehabilitation. Urodynamic examination revealed normal bladder capacity, normal bladder sensitivity, and normal compliance, but no detrusor contractions were observed during urination. For this phenomenon, we believe that continuous and regular rehabilitation training can partially restore the damaged peripheral nerves. When the bladder is full, the stretch receptors are excited and transmit signals to the micturition center—pons. However, the sympathetic and parasympathetic nerves that control bladder contraction were still inactive, so the detrusor did not contract during urination. The patient’s pelvic floor muscle strength was enhanced, the POP improved, the control of urethral pressure by the pubococcygeus and inherent urethral sphincter was increased, the pelvic floor muscles were relaxed during urination, the intra-abdominal pressure increased to greater than the intra-urethral pressure, and the urine discharge improved. In daily life, a strong pelvic floor muscle type I muscle fiber support system can increase the intraurethral pressure so that urine does not overflow. Exercise therapy helps the organs to maintain a relatively normal position, maintains the biomechanical structure of the pelvic floor, and further promotes the recovery of urination. In the treatment of such patients, we need to pay attention to the risk of urination with

abdominal pressure. For example, increased blood pressure, hemorrhoids, increased POP, and so on. At the same time, it is also necessary to strike the balance between the adverse consequences of urination due to abdominal pressure and clinical symptoms such as dysuria, and to strive to maximize the improvement of patient symptoms and function with minimal risk.

## Conclusions

In this case, 6-month comprehensive rehabilitation therapy combined with mecobalamin drug therapy produced a good effect on the DNB, which provided an important reference for finding effective prevention and treatment of this type of disease in the future. Based on the lack of evidence-based medical data for such cases, this article can only be analyzed in the form of a case report. More original research is still required to support the treatment of DNB. Further clinical experimental research for exploration is also necessary.

## Acknowledgments

*Funding:* None.

## Footnote

*Reporting Checklist:* The authors have completed the CARE reporting checklist. Available at <https://tau.amegroups.com/article/view/10.21037/tau-22-840/rc>

*Conflicts of Interest:* All authors have completed the ICMJE uniform disclosure form (available at <https://tau.amegroups.com/article/view/10.21037/tau-22-840/coif>). The authors have no conflicts of interest to declare.

*Ethical Statement:* The authors are accountable for all aspects of the work in ensuring that questions related to the accuracy or integrity of any part of the work are appropriately investigated and resolved. All procedures performed in this study were in accordance with the ethical standards of the institutional and/or national research committee(s) and with the Declaration of Helsinki (as revised in 2013). Written informed consent was obtained from the patient for publication of this case report. A copy of the written consent is available for review by the editorial office of this journal.

*Open Access Statement:* This is an Open Access article

distributed in accordance with the Creative Commons Attribution-NonCommercial-NoDerivs 4.0 International License (CC BY-NC-ND 4.0), which permits the non-commercial replication and distribution of the article with the strict proviso that no changes or edits are made and the original work is properly cited (including links to both the formal publication through the relevant DOI and the license). See: <https://creativecommons.org/licenses/by-nc-nd/4.0/>.

## References

1. Shi XX, Wang YB, Wang RX. The pathogenesis and diagnosis of diabetic bladder disease. *Clinical Medicine of China* 2015;(4):368-9.
2. Sichuan Da Xue Xue Bao Yi Xue Ban. Application Value of American Urological Association Symptom Index Score in Female Patients with Type 2 Diabetic Neurogenic Bladder. *Journal of Sichuan University (Medical Sciences)* 2019;50:566-70.
3. Xuan LM, Ma LP, Ouyang S, et al. Effect of combined transurethral instillation of SCL and Cx43 gene lentivirus on diabetic bladder function. *Acta Universitatis Medicinalis Anhui* 2022;57:1546-51.
4. Xie YC, Chen WP, Chen XM, et al. Application of intermittent catheterization in refractory diabetic neurogenic bladder. *Modern Rehabilitation* 2002;6:1612-3.
5. Wu QP, Wang LL, Shen LX, et al. Changes of serum and urine oxidative stress indexes of patients with diabetes combined with urinary tract infection. *Chinese Journal of Nosocomiology* 2016;26:3436-8.
6. Gu QX. Curative effect observation of bladder function training combined with Micobao in the treatment of diabetic cystopathy. *Chinese Journal of Physical Medicine and Rehabilitation* 2010;32:451-2.
7. Zheng L, Qin GJ, Liu J, et al. A case of type 2 diabetes with recurrent urinary tract infection and literature review. *Journal of Zhengzhou University (Medical Sciences)* 2018;53:827-9.
8. Han XK, Chen YD, Chen HZ, et al. Establishment and evaluation of a neurogenic bladder model in rats with type 2 diabetes mellitus. *Chinese Journal of Tissue Engineering Research* 2022;26:2713-9.
9. Yang WX. Bladder management after spinal cord injury. *Chinese Journal of Rehabilitation Medicine* 2015;30:850-3.
10. Chen SH, Li GQ, Chen Y, et al. Analysis of Short- and Mid-term Therapeutic Effects of Transvaginal Natural Orifice Transluminal Endoscopic Surgery Sacrocolpopexy in the Treatment of Middle Compartment



- Prolapse. *Journal of Practical Obstetrics and Gynecology* 2022;38:525-8.
11. Zhou CL, Liu Y, Luo XR. Reliability and Validity of Patient Health Questionnaire in Inpatients with Diabetic Foot Ulcers. *Chinese General Practice* 2016;19:3461-6.
  12. Chen J, Zhu L, Pang HX, et al. Manual massage combined with biofeedback treatment for myofascial pelvic pain syndrome-17 cases cohort report. *Chinese Journal of Practical Gynecology and Obstetrics* 2018;34:547-9.
  13. Chu HQ, Zheng H. Application and research progress of transdermal nerve electrical stimulation in pain diagnosis and treatment. *Chinese Journal of Pain Medicine* 2021;27:693-7.
  14. Yang Z. Effect of Progressive Core Strength Training on Balance for Old Adults. *Chinese Journal of Rehabilitation Theory and Practice* 2019;25:836-9.
  15. Chen ML, Wei XY. Progress in studying the effect of abdominal respiratory rehabilitation. *Journal of Medical Biomechanics* 2021;36:423.
  16. Guan YJ, Zeng QF, Zhang JP, et al. Effects of integrated sharing mode based on PSBH theory on mental state, self-management ability and quality of life of diabetes patients. *China Journal of Health Psychology* 2022;30:1643-9.
  17. He YG, Song B. Observation on the effect of psychological intervention in the treatment of neurogenic bladder after spinal cord injury. *Chinese Journal of Physical Medicine and Rehabilitation* 2014;36:472-4.
  18. Wang XM, Zhang MX, Zhao L, et al. The Starling mechanism of the urinary bladder contractile function and the influence of hyperglycemia on diabetic rats. *J Diabetes Complications* 2010;24:121-8.
  19. Glazer HI, Hacad CR. The Glazer Protocol: evidence-based medicine pelvic floor muscle (PFM) surface electromyography (SEMG). *Biofeedback* 2012;40:75-9.
  20. Guo WM, Sun LB, Wang DW. Recent Advances in Diabetic Cystopathy. *Chinese General Practice* 2020;23:2095-101.
  21. Jin J, Zhou QQ, Liu W, et al. The effects of electrical stimulation of the pelvic floor on neurogenic bladder dysfunction after spinal cord injury: A systematic review and meta-analysis of randomized and controlled trials. *Chinese Journal of Physical Medicine and Rehabilitation* 2021;43:64-8.
  22. Li L, Liao LM, Wu J, et al. Effect of Pelvic Floor Muscle Training on Neurogenic Detrusor Overactivity. *Chinese Journal of Rehabilitation Theory and Practice* 2021;27:1093-7.
  23. Wittig L, Carlson KV, Andrews JM, et al. Diabetic Bladder Dysfunction:A Review. *Urology* 2019;123:1-6.
  24. Zhang P, Shi XH, Zhang H, et al. The mechanism and clinical application of abdominal breathing training. *Modern Journal of Integrated Traditional Chinese and Western Medicine* 2012;21:222-4.
  25. Mo HL, Li ZH, Wang SH, et al. Observation of the efficacy of respiratory training combined with core stability training in patients. *Chinese Journal of Physical Medicine and Rehabilitation* 2021;43:690-2.
  26. Dong ZM, Lou PA, Zhang P, et al. Effect of cognitive-behavioral therapy on psychological stress and curative effect in patients with type 2 diabetes mellitus. *Chinese Journal of Diabetes* 2019;27:749-54.
- (English Language Editor: J. Jones)

**Cite this article as:** Jiang HY, Chen YQ, Li JH, Wang ZW. Pelvic floor myofascial manipulation combined with Kegel exercise and mecobalamin in the treatment of atypical diabetic neurogenic bladder: a case report. *Transl Androl Urol* 2023;12(1):139-147. doi: 10.21037/tau-22-840