



All-Arthroscopic Suture Fixation of Patellar Osteochondritis Dissecans

Johannes Barth, M.D., Paul Brossard, M.D., Achilleas Boutsiadis, M.D., Ph.D.,
Nicolas Tardy, M.D., Jean-Claude Panisset, M.D., and Romain Seil, M.D., Ph.D.

Abstract: Osteochondritis dissecans of the knee, despite its cause, is characterized by the impairment of the subchondral bone. Failure of its spontaneous healing makes surgical fixation often necessary. The patella is less affected than other locations in the knee. Its surgical treatment remains a challenge due to the thickness of the lesion and the complex approach of the retropatellar cartilage. Arthroscopy has the theoretical advantage to avoid a possible arthrotomy; however, the retrograde application of fixation materials does not guarantee good fragment compression and may lead to cartilage penetration and damage. The purpose of this Technical Note is to present a reproducible, full arthroscopic suture fixation technique for patellar osteochondritis dissecans lesions. By using the posterior cruciate tibial drill guide, absorbable sutures are passed through the center and the peripheral borders of the lesion resulting in a “spider-parachute-type” fixation with direct fragment compression.

Osteochondritis dissecans (OCD) is characterized by the impairment of the subchondral bone resulting in its necrosis, with associated deterioration of the overlying articular cartilage and potential progression to osteoarthritis. From a functional point of view, it may result in significant limitations of any athletic or even daily activities.^{1,2} It mainly affects 10- to 20-year-old male athletes with an estimated incidence of 15 to 29 per 100,000.³ Its cause remains controversial, and multiple pathophysiological mechanisms such as vascular, genetic, traumatic, or inflammatory have been proposed.^{2,4} Treatment depends on lesional stability and chronicity, on the status of the subchondral bone and the type of lesion (adult or juvenile).⁴

Regarding its location, OCD affects mainly the medial femoral condyle of the knee (approximately 80% of cases).⁴ The patella is less frequently affected (5% to 10% of OCD), and its surgical treatment remains a challenge due to lesional thickness and the complex approach of the area.^{1,3} Internal fixation is the preferred method of treatment, whereas fragment excision and consecutive drilling have led to inferior functional results.³ Several surgical fixation techniques have been described. They include mini-open or arthroscopically controlled techniques, using either osteochondral plugs, metal or bioabsorbable screws, Kirschner wires, or bioabsorbable pins.³ The few arthroscopic techniques published so far have reduced the morbidity of a possible arthrotomy; however, they seem demanding and difficult to reproduce.⁵⁻⁷ Furthermore, the frequently used bioabsorbable pins do not ensure good fragment compression,⁵ whereas the use of even headless metal screws may^{6,7} predispose to postoperative impingement and gradual cartilage wear.^{6,7}

The purpose of this Technical Note is to report a reliable and reproducible full arthroscopic fragment fixation technique for patellar OCD by using only sutures in a retrograde manner and providing direct compression of the lesion.

Surgical Technique

Preoperative Evaluation—Indications

Preoperative imaging (radiographs, magnetic resonance imaging, and sometimes computed tomography-

From the Department of Orthopaedic Surgery, Centre Osteoarticulaire des Cèdres (J.B., P.B., A.B., N.T., J-C.P.), Grenoble, France; Department of Orthopaedic Surgery, Centre Hospitalier Luxembourg (R.S.); and Sports Medicine Research Laboratory, Luxembourg Institute of Health (R.S.), Luxembourg City, Luxembourg.

The authors report the following potential conflicts of interest or sources of funding: J.B. receives support from Arthrex, Science for BioMaterials, Tornier, and the European Society of Sports Traumatology, Knee Surgery and Arthroscopy; he is also a board member of French Society of Arthroscopy. J-C.P. receives support from SBM.

Received December 28, 2016; accepted March 9, 2017.

Address correspondence to Johannes Barth, M.D., Department of Orthopaedic Surgery, Centre Osteoarticulaire des Cèdres, Parc Sud Galaxie, 5 Rue Des Tropiques, 38130 Echirolles, Grenoble, France. E-mail: jrhhbarth@yahoo.fr

© 2017 by the Arthroscopy Association of North America

2212-6287/175/\$36.00

<http://dx.doi.org/10.1016/j.eats.2017.03.017>

Table 1. Imaging Classification of Bedouelle and the Arthroscopic Classification of Guhl for Osteochondritis Dissecans of the Knee

Classifications of OCD	
Imaging classification (MRI) of Bedouelle ⁸	Stage I: clearly incomplete well-defined lesion with few calcifications within Stage II: presence of a nodule with more or less shrinkage of the nodule in relation to the condyle Stage III: sleigh-bell aspect Stage IV: free fragment in the joint with an empty bed
Arthroscopic classification of Guhl ⁸	Stage I: intact lesions Stage II: early separation Stage III: partial detachment Stage IV: craters or loose bodies

MRI, magnetic resonance imaging; OCD, osteochondritis dissecans.

arthrography) is required to validate the thickness, vitality of the fragment and of the underlying bone, and classify the lesion. Patients with a lesional diameter >5 mm and OCD stage II or III (according to the imaging classification of Bedouelle or the arthroscopic classification of Guhl⁸) are the best candidate for the presented technique (Table 1).

Patient Positioning

Under general or regional anesthesia, the patient is positioned supine with a high thigh tourniquet appropriately placed at the affected limb. In addition, a distal foot stop and a lateral support retain the knee stable in 90° of flexion while allowing intraoperative full passive range of motion movements and valgus-varus stress maneuvers without any difficulty.

Portals and Arthroscopic Exploration

Through standard anterolateral (AL) and anteromedial (AM) portals (established slightly lower than

usual) the knee joint is initially evaluated. In cases of OCD, it is important to carefully explore the medial and lateral compartments, the gutters as well as the posteromedial and posterolateral compartments searching for any loose bodies. Finally, after exploration of the patellofemoral compartment in extension, 2 supplementary portals are created using a spinal needle under direct visual arthroscopic control, 1 superomedial (SM) and 1 superolateral (SL). It is important to notice that the preferred localization of these 2 accessory portals is far enough from the patella to permit working without any conflict that could damage the cartilage after repetitive contacts with the metallic guides or the instruments (Fig 1A).

Preparation of the Lesion—Initial Central Tunnel Creation

Initially, by using the arthroscopic probe and through the basic AL and AM portals, the surgeon should define the borders of the patellar lesion and evaluate its

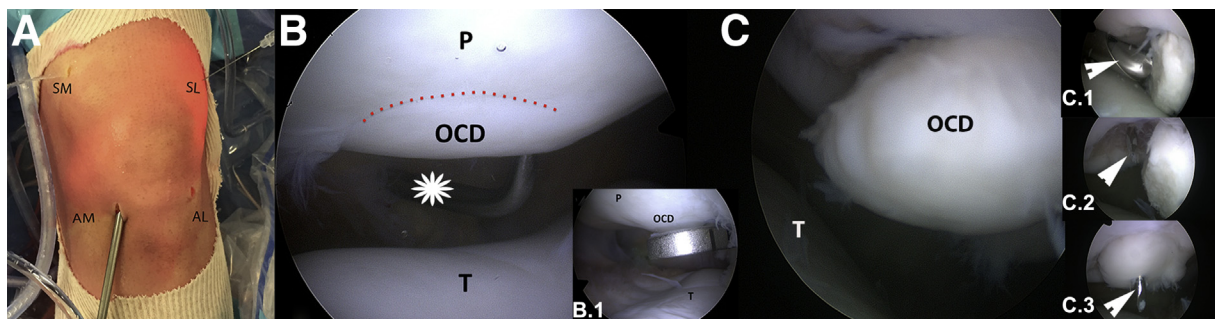


Fig 1. (A) Standard anteromedial (AM) and anterolateral (AL) and accessory superomedial (SM) and superolateral (SL) portals are established. The patient is placed supine with his left knee in extension and the 30° arthroscope in the AL portal. (B) A patellar osteochondritis dissecans (OCD) Guhl stage II (red dots) where no debridement is performed. The lesion is evaluated with an arthroscopic probe from the SL portal (asterisk). The patient is placed supine and the arthroscope is in the AM portal showing the patellofemoral joint of the left knee. (B.1) Arthroscopy of the left patellofemoral joint with the patient in the supine position. By using the AM as a viewing portal the posterior cruciate ligament drill guide is placed through the AL portal directly at the center of the lesion (OCD). (C) An unstable, partially detached Guhl stage III lesion (OCD) of the left knee. The patient is placed supine and the arthroscope is kept in the anterolateral portal showing the patellofemoral joint. (C.1) OCD lesion and socket debridement by using an arthroscopic burr (arrow) from the anteromedial portal (left knee). The arthroscope is placed in the AL portal showing the patellofemoral joint. (C.2, C.3) The 2.4-mm drill pin is placed at the center of the lesion's crater (C.2, white arrow) and sequentially at the center of the OCD fragment, allowing its almost anatomic reduction (C.3, white arrow). The patient is placed supine and the arthroscope is kept in the anterolateral portal (left knee). (P, patella; T, trochlea.)

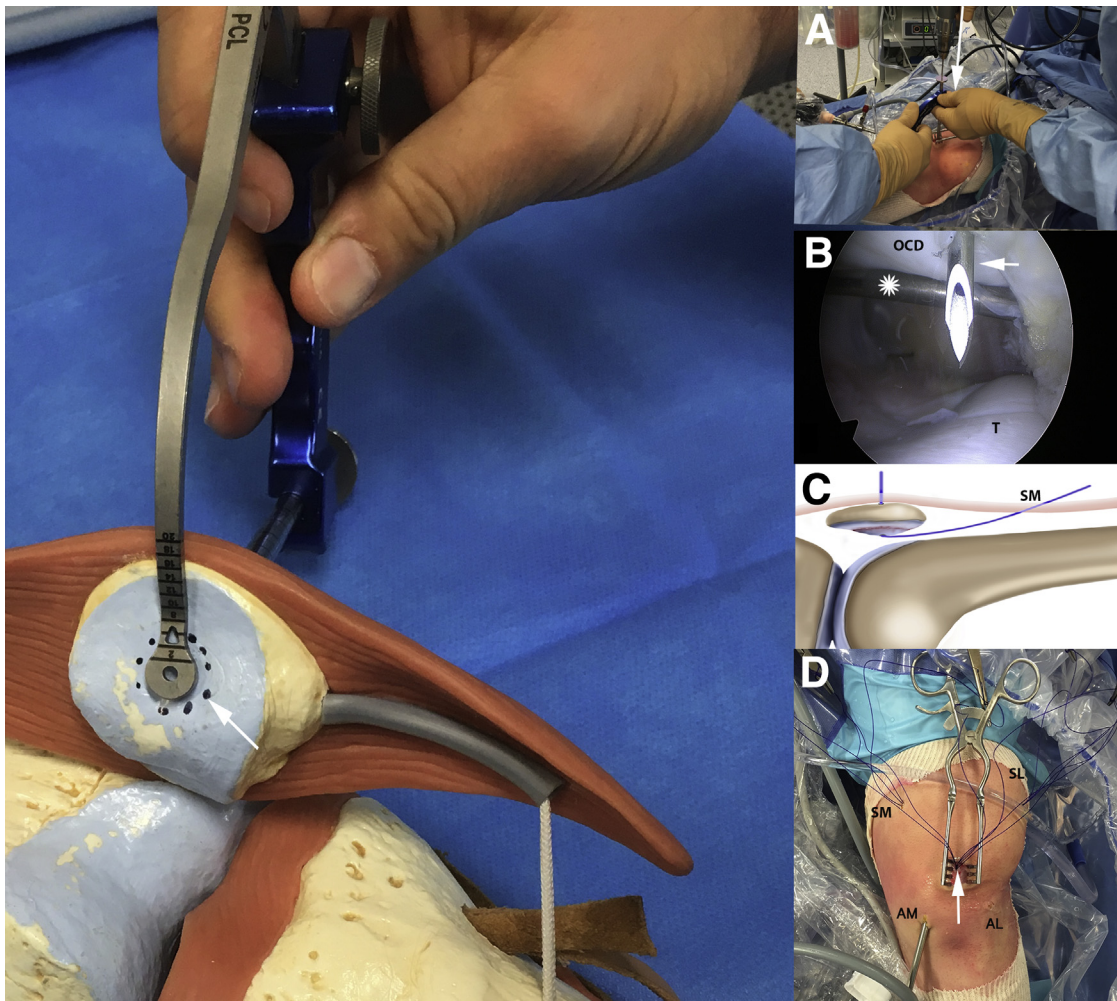


Fig 2. Knee plastic model of a right knee showing the specific drill guide placed at the center of the osteochondritis dissecans (OCD) patellar lesion (black dots, white arrow). (A) The patient is placed supine, the arthroscope is in the anteromedial (AM) portal and the posterior cruciate ligament (PCL) guide in the anterolateral (AL) portal of the left knee. The sleeve of the PCL guide is placed through an anterior incision onto the patella and a 2.4-mm pin (arrow) is drilled to perforate the center of the OCD fragment. (B) Through the central tunnel created, a 16-G needle and a consecutive No. 1 blue PDS suture are introduced into the joint (white arrow). An arthroscopic probe from the AL portal is holding the soft tissues providing good visualization of the lesion (asterisk). The patient is supine with the arthroscope in the AM portal showing the patellofemoral joint of the left knee. (C) Art design with the sagittal view of the knee joint, showing the No. 1 PDS suture passed through the central tunnel and retrieved through the superomedial portal (SM). (D) Six No. 1 PDS sutures are finally introduced from the anterior incision through the central tunnel (white arrow) and retrieved from the superior accessory portals (3 from the SM and 3 from the superolateral [SL]). As shown in this ground view of the left knee in extension, the arthroscope is placed in the AM portal. (T, trochlea.)

stability. In cases of a Guhl stage II stable lesion (Fig 1B), no debridement is necessary because the following drill placement could improve the vascularity of the area. However, for a Guhl stage III (Fig 1C), debridement of the socket and the fragment with a shaver, a burr, or even a curette from the superior accessory portals is highly suggested. This debridement permits good fragment reposition and ensures better subchondral bone bleeding (the irrigation pump is temporarily stopped to confirm the blood flowing from the patella). In chronic cases, fibrotic or bony tissues

may have filled the socket and should be removed to ensure a perfect reposition of the fragment (the cartilage should appear completely flush, without superstructure).

Thereafter, the specific posterior cruciate ligament (PCL) drill guide (Arthrex, Naples, FL) is inserted into the joint through the AM or AL portal, depending on the location of the lesion. Consequently, the arthroscope is placed in the contralateral basic portal (AL or AM, respectively). The specific PCL drill guide should be placed at the center of the OCD fragment, giving also

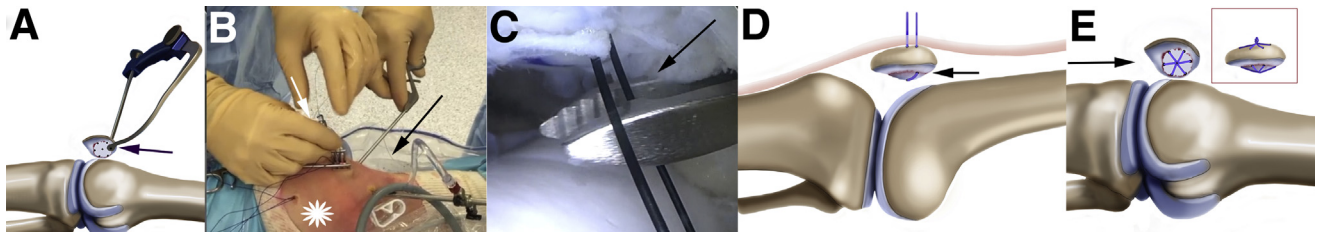


Fig 3. (A) Art design showing that the same specific posterior cruciate ligament drill guide is placed at the borders of the fragment and the healthy cartilage (arrow) and a 2.4-mm tunnel is created. (B and C) From the anterior incision and through the peripheral tunnel a looped No. 2/0 Ethilon suture is introduced into the joint with the aid of a 16-G needle (white arrow). A suture retriever (black arrow) from the anterolateral portal is used to retrieve the No. 2/0 Ethilon and one No. 1 PDS suture (asterisk) from the superomedial portal. The patient is placed supine and the arthroscope is placed in the anteromedial portal of the left knee showing the patellofemoral joint in full extension. (D) Art design of the sagittal view of the knee joint. By using the Ethilon suture loop, one of the PDS sutures is shuttled through the peripheral tunnel (black arrow) and this could act as a hammock strongly supporting and compressing the patella's OCD fragment when tightened. (E) Art design showing the final construct. Tunnels are created at different points of the OCD's fragment periphery, according to its size. Six No. 1 PDS sutures are passed around the lesion in a clockwise manner, creating a parachute-type supporting-compression mechanism (black arrow). (OCD, osteochondritis dissecans.)

the opportunity to reposition it actively if it is mobile (Fig 2). According to the extra-articular position of the PCL guide sleeve, a 2- to 3-cm vertical incision is made at the anterior aspect of the patella. By using the PCL guide, a 2.4-mm drill pin is placed through the patella perforating the center of the OCD fragment and creating the necessary central tunnel for the passage of the sutures (Fig 2A). Under arthroscopic control and with the aid of a 16-gauge needle (BD Infusion Therapy, Sandy, Utah), a No. 1 blue PDS suture (Ethicon SAS, Johnson & Johnson, Issy-les-Moulineaux, France) is introduced into the joint through the central tunnel (Fig 2B). This end of the PDS suture is retrieved

through the SM or SL portal, whereas the other exits the 2.4-mm central tunnel at the anterior aspect of the patella (Fig 2C). Depending on the size of the lesion, 5 to 6 sutures may be introduced from the central tunnel. As mentioned above, all sutures have one end that emerges from the central tunnel and the other from the SL or SM portal (Fig 2D).

Peripheral Suture Passage and “Spider-Parachute-Type” Suture Fixation

The same specific PCL drill guide is reinserted into the joint through the AM or AL portals with its intra-articular part aiming now at the junction between the

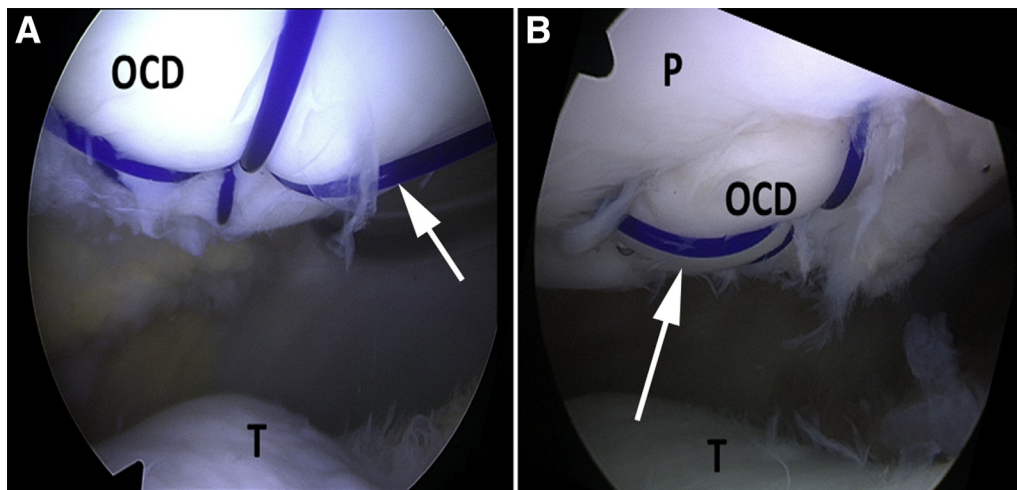


Fig 4. (A) Arthroscopic image showing the final fixation of a Guhl stage II patellar lesion. The No. 1 PDS sutures (white arrow) are passed around the lesion in a clockwise manner, creating a parachute-type supporting-compression mechanism. The patient is placed supine and the arthroscope is placed in the anteromedial portal of the left knee showing the patellofemoral joint in extension. (B) Arthroscopic image showing the final fixation of an unstable Guhl stage III patellar lesion. The No. 1 PDS sutures (white arrow) are passed around the lesion in a clockwise manner, creating a parachute-type supporting-compression mechanism. The patient is placed supine and the arthroscope is placed in the anterolateral portal of the left knee showing the patellofemoral joint in extension. (OCD, osteochondritis dissecans lesion; P, patella; T, trochlea.)

Table 2. Surgical Steps, Tips, and Pearls and Pitfalls of the Technique Described

Surgical Steps	Tips and Pearls	Pitfalls
1. Diagnostic arthroscopy: evaluation of the lesion	<ul style="list-style-type: none"> • Standard anteromedial (AM) and anterolateral (AL) and accessory superomedial (SM) and superolateral (SL) portals are established • Lesion evaluation • Cleaning curettage of Guhl stage III lesions 	<ul style="list-style-type: none"> • Establish the accessory portals far enough from the patella to avoid cartilage damage during instrument insertion into the joint • In chronic cases, the lesion maybe proud and fibrous or bony tissue is present under the lesion. The amount of curettage should lead to acceptable reduction avoiding overstuffing of the patellofemoral joint • In Guhl stage IV lesions, probably the technique of lesion preservation should be abandoned
2. Reduction of the lesion: central tunnel	<ul style="list-style-type: none"> • Through the AL or AM portal (depending on the lesion location) insert the tibial PCL guide in the center of the fragment • By pushing the PCL guide superiorly, an indirect reduction of the lesion (in stage III cases) can be performed • At the tip of the extra-articular position of the PCL guide sleeve, perform a 2- to 3-cm vertical incision • By using the 2.4-mm drill guide through the PCL, make a tunnel at the center of the lesion perforating the cartilage • Through the aforementioned tunnel, insert 5-6 No. 1 PDS sutures or more (depending on the size of the lesion) into the joint • Retrieve these sutures from the SL or SM portals 	<ul style="list-style-type: none"> • During central tunnel drilling, always perform indirect compression of the lesion by the PCL guide to avoid its fragmentation or displacement
3. Peripheral tunnel creation and final suture passage	<ul style="list-style-type: none"> • Place the PCL tibial drill guide at the borders of the lesion and the healthy cartilage • Create a 2.4-mm tunnel and insert a No. 2/0 Ethilon suture loop into the joint. By using the Ethilon loop, shuttle one PDS suture from the superior portals at the anterior aspect of the patella • Perform the same procedure around the periphery of the lesion. The purpose is to pass the No. 1 PDS sutures around the lesion in a clockwise fashion 	<ul style="list-style-type: none"> • The peripheral tunnels should be carefully created and under direct visual control in order not to perforate the fragment and its cartilage
4. Final fixation	<ul style="list-style-type: none"> • Tighten each suture by performing 6 half knots over the anterior surface of the patella. The purpose is to create a parachute-type supporting-compression mechanism • Suture carefully the patellar retinaculum above the PDS knots 	<ul style="list-style-type: none"> • Inconvenience over the anterior aspect of the knee due to the suture knots

PCL, posterior cruciate ligament.

borders of the fragment and the healthy cartilage. Furthermore, the drill sleeve is positioned onto the patella through the already made anterior incision. Consecutively, a small 2.4-mm tunnel is created with the appropriate drill guide at the periphery of the OCD fragment (Fig 3A). Through the latest and again with the aid of a 16-gauge needle (BD Infusion Therapy) a

looped No. 2/0 Ethilon suture (Ethicon SAS, Johnson & Johnson) is introduced into the joint (Fig 3 B and C). By using a retriever, one of the No. 1 PDS sutures from the SM or SL portal is passed through the No. 2/0 Ethilon loop and consecutively shuttled through the peripheral 2.4-mm tunnel. Therefore, this No. 1 PDS suture, passed from the central and peripheral tunnel,

Table 3. Advantages, Risks, and Limitations of All-Arthroscopic Suture Fixation of Patellar Osteochondritis Dissecans

Advantages	<ul style="list-style-type: none"> • Perform intra-articular reduction and accurate tunnel positioning under direct visual control • Use only absorbable sutures • Avoid any materials placed in a retrograde fashion that could penetrate the cartilage and damage the trochlear surface also • Avoid arthrotomy and patellar dislocation • Minimally invasive, reproducible with a cosmetic scar • Provide direct compression of the lesion
Risks	<ul style="list-style-type: none"> • Transforming an unstable stage III lesion to a stage IV free loose body during shaving of the defect • Lesion's and cartilage's fragmentation during the tunnel's performance • Not enough curettage of the underlying area that can result in a nonreduced, proud lesion and consequently to an overstuffed and painful patellofemoral joint • Bulky knots over the anterior aspect of the patella that could be a source of discomfort or swelling and pain before their resorption (after 6 mo)
Limitations	<ul style="list-style-type: none"> • Lesion <5 mm • Cases of Guhl stage IV

could act as a hammock strongly supporting and compressing the patella's OCD fragment when tightened (Fig 3D).

The same procedure is repeated at different points of the OCD's fragment periphery, according to its size and to the remaining number of sutures passed through the central tunnel. The purpose is to pass the No. 1 PDS sutures around the lesion in a clockwise fashion, creating a parachute-type supporting-compression mechanism. Thereafter, the sutures are tightened over the anterior surface of the patella (6 half knots are preferred) and the reduction and compression of the fragment is checked under direct arthroscopic control (Figs 3E and 4).

During wound closure, it is recommended to suture the patellar retinaculum over the PDS knots to minimize skin irritations. A possible initial discomfort may be reported during the first 3 to 4 postoperative months. It usually disappears completely at 6 months postoperatively (Video 1, Table 2).

Follow-up—Rehabilitation

No immobilization is needed and immediate weight bearing is allowed. However, because of initial pain discomfort, mobilization with the aid of crutches is recommended for 8 to 15 days. Recovery of range of motion should be progressive and knee flexion should not exceed 90° after the first 6 weeks of the surgery. To minimize any muscle atrophy, isometric exercises are advised immediately.

Discussion

The purpose of our Technical Note is to propose a reproducible and relatively simple, fully arthroscopic technique that could overcome the fixation difficulties of patella OCD. Regardless of the location of the lesion, an arthrotomy could be avoided in this young fragile population. Also a direct perpendicular compression of the fragment, similar to a direct open antegrade fixation methods, could be achieved (Table 3).

In the few previously published studies, the arthroscopic approach also included a retrograde drilling of the lesion and a consecutive application of implants (pins, screws) in the same direction.⁵⁻⁷ However, Matava and Brown⁵ described an intra-articular prominence of the bioabsorbable pins, which needed to be cut with a scalpel. The authors' main concern was the poor bony compression and the potential delayed inflammatory reaction of the used materials.

To overcome the problems related to the lack of compression, some authors proposed the use of headless Herbert-type screws.⁶ The limitation of this technique is related to the fact that a retrograde screw insertion may lead to fragmentation of the lesion or to penetration of the articular cartilage and intra-articular prominence. Despite a successful consolidation of the lesions, the authors report the need for hardware removal, due to persisting discomfort that resolved postoperatively.⁶ Using the same outside-in philosophy, the use of conical compression screws has also been described. In the single case that has been reported so far, a good final stability of the fragment required accurate hardware placement to the limits of the cartilage surface. In addition, a second operation for its removal was also necessary.⁷

In the most recent and largest study focusing on the OCD of the patellofemoral joint, the authors reported that the preservation of the lesion had a significantly higher risk for reoperation (odds ratio = 8.7, $P = .04$) by using the aforementioned fixation techniques.³ In their conclusion, they stated that especially the arthroscopic fixation of the unstable patellar lesions remains technically demanding and bears difficulties to achieve fragment compression. Therefore, arthrotomy may be required during surgery. Nevertheless, their final conclusion is that the effort of retaining the native cartilage in this younger population is of outstanding importance.³

The described fully arthroscopic technique is reliable and reproducible, and it provides direct perpendicular lesional compression with no need for fluoroscopic control or implantation of specific materials. It should be noted that this report has several limitations. It is not known how many sutures are required to provide the necessary fragment compression and stability. Because of the rarity of patellar OCD, no long-term results are available, and a multicenter comparison with the aforementioned techniques may be required.

Acknowledgment

The authors thank Christina Eleftheriadou, graphic designer, for the design of the professional-quality drawings.

References

1. Peters TA, McLean ID. Osteochondritis dissecans of the patellofemoral joint. *Am J Sports Med* 2000;28:63-67.
2. Flynn JM, Kocher MS, Ganley TJ. Osteochondritis dissecans of the knee. *J Pediatr Orthop* 2004;24:434-443.
3. Kramer DE, Yen Y-M, Simoni MK, et al. Surgical management of osteochondritis dissecans lesions of the patella and trochlea in the pediatric and adolescent population. *Am J Sports Med* 2015;43:654-662.
4. Kocher MS, Tucker R, Ganley TJ, Flynn JM. Management of osteochondritis dissecans of the knee: Current concepts review. *Am J Sports Med* 2006;34:1181-1191.
5. Matava MJ, Brown CD. Osteochondritis dissecans of the patella: Arthroscopic fixation with bioabsorbable pins. *Arthroscopy* 1997;13:124-128.
6. Marandola MS, Prietto CA. Arthroscopic Herbert screw fixation of patellar osteochondritis dissecans. *Arthroscopy* 1993;9:214-216.
7. Sekiya JK, Fontbote CA, Harner CD. Arthroscopically assisted retrograde fixation of patellar osteochondritis dissecans using fluoroscopic guidance: A case report and technical note. *Arthroscopy* 2003;19:E1-E7.
8. Uppstrom TJ, Gausden EB, Green DW. Classification and assessment of juvenile osteochondritis dissecans knee lesions. *Curr Opin Pediatr* 2016;28:60-67.