

A 6-Year Retrospective Review of Histopathological Pattern of Surgical Biopsies in Children with Refractory Constipation in a Tertiary Hospital in Ghana

Abiboye C. Yifeyeh, Babatunde M. Duduyemi¹, Anthony Enimil²

Directorate of Surgery, Komfo Anokye Teaching Hospital, Departments of ¹Pathology and ²Child Health, Kwame Nkrumah University of Science and Technology, Kumasi, Ghana

Abstract

Background: Children with chronic constipation dating to infancy frequently undergo rectal biopsy in order to rule out Hirschsprung's disease (HD) which is a common cause of this sort of presentation. Few publications have however focused on the documentation of the proportion of such patients who truly had histopathological findings confirming the disease. In this preliminary work, we aim to present the histopathological findings of children who had rectal biopsies in our centre from 2009 to 2014. **Patients and Methods:** A retrospective study was undertaken to review the histopathology reports of all rectal biopsies submitted to the Department of Pathology of the Komfo Anokye Teaching Hospital, Kumasi, from 2009 to 2014 on account of refractory constipation and suspected HD. Patient's biodata, clinical signs and symptoms were extracted from the request form. **Results:** Eighty-eight cases were seen during the study period with male to female ratio 2.8:1 and age range 6 months to 10 years. The modal age range is 24–36 months. Seventy-six of the specimens were adequate for histopathological assessment with 64 cases confirmed as HD while 12 cases were normal. Out of the confirmed cases, 3 cases showed absence of ganglion cells but no hypertrophy of nerve fibres. **Conclusion:** This preliminary work reveals that HD is rarely confirmed by biopsy in early infancy in our setting due to late presentation although the epidemiology of the disease is similar to that reported elsewhere.

Keywords: Chronic constipation, Hirschsprung's disease, rectal biopsy

INTRODUCTION

Children with chronic constipation dating to infancy frequently undergo rectal biopsy in order to rule out Hirschsprung's disease (HD).^[1] HD is a congenital absence of the ganglion cells (GCs) in the distal gastrointestinal tract causing a functional intestinal obstruction.^[2-4] Clinical presentation is usually short after birth with either a failure or a delay in the passage of meconium.^[5,6] Presentation in late infancy, childhood and adolescence are known.^[7,8] Histopathological study of rectal biopsy specimens is the means of making a definite diagnosis.^[9] The curative surgical procedures, which are collectively called pull-throughs, entail the resection of the aganglionic segment and coloanal anastomosis.^[5] Few publications have however focused on the histopathological findings from these rectal biopsies with the aim of documenting the proportion of such patients who truly have HD.^[1] In this preliminary work, we aim to present the

histopathological findings of children who either had rectal biopsy or corrective pull-through procedure in our centre from 2009 to 2014.

PATIENTS AND METHODS

A retrospective study was undertaken to review the histopathology reports of all biopsies submitted to the Department of Pathology of the Komfo Anokye Teaching Hospital, Kumasi, from 2009 to 2014 on account of refractory constipation and suspected HD. Full-thickness rectal biopsy is the routine method of rectal biopsy in our hospital.

Address for correspondence: Dr. Babatunde M. Duduyemi, Department of Pathology, Kwame Nkrumah University of Science and Technology, Kumasi, Ghana. E-mail: tundeduduyemi@gmail.com

This is an open access journal, and articles are distributed under the terms of the Creative Commons Attribution-NonCommercial-ShareAlike 4.0 License, which allows others to remix, tweak, and build upon the work non-commercially, as long as appropriate credit is given and the new creations are licensed under the identical terms.

For reprints contact: reprints@medknow.com

How to cite this article: Yifeyeh AC, Duduyemi BM, Enimil A. A 6-year retrospective review of histopathological pattern of surgical biopsies in children with refractory constipation in a Tertiary Hospital in Ghana. Afr J Paediatr Surg 2018;15:111-3.

Access this article online

Quick Response Code:



Website:
www.afripaedurg.org

DOI:
10.4103/ajps.AJPS_70_17

The reports of all pull-through surgical specimens from children with pathologically confirmed HD were also reviewed. Patient's biodata, clinical signs and symptoms were extracted from the request form. Minimum criteria for histopathological confirmation of HD included the absence of GC and the presence of hypertrophic nerve fibres (HNFs).

RESULTS

Eighty-eight cases were seen during the study period with male to female ratio 2.8:1 and age range 6 months to 10 years. The modal age range was 24–36 months. Seventy-six specimens were adequate for histopathological assessment with 64 cases confirmed as HD while 12 cases were normal. Out of the confirmed cases, 3 cases showed the absence of GC but no HNF. Figures 1-3 show the age distribution and histologic diagnosis, sex distribution and histologic diagnosis and yearly frequency of HD, respectively.

Of the pull-through surgical specimens (30), the length of the aganglionic segment was limited to the rectum and sigmoid in 15 (50%) cases. The rare involvement of the small intestine was found in 3 cases, 2 of whom were females. Figure 4 depicts the absolute numbers of rectal biopsies and the extent of aganglionic involvement from the pull-through specimens.

DISCUSSION

Male preponderance in HD, as we found in our study, is well reported.^[4,5,10,11] In most series, confirmatory diagnosis of HD is obtained either during the neonatal period or early infancy through rectal biopsy.^[1,12] Neonatal suction rectal biopsy (SRB), which is a bedside procedure, is the usual means of obtaining the specimens in these studies. It is

comparatively non-invasive and does not require general anaesthesia. These factors have made SRB very appealing. Inadequate sampling and a comparatively more challenging interpretation of histopathological findings especially in premature newborns are some of its drawbacks.^[13] Most of our cases were not diagnosed during early infancy as has been documented in other developing countries.^[5,14-16] In our setting, most children are brought to the hospital only when the enema, which their mothers or grandmothers routinely administer to them, has failed to relieve their constipation. Paucity of trained clinical and laboratory personnel at peripheral hospitals could contribute to this diagnostic delay.^[16]

It is thought that patients with very short segments of aganglionosis would have delay in diagnosis because of less severe symptoms.^[17] There was no relationship between the length of the aganglionic segment and the age at diagnosis among our patients. There were 3 cases of small bowel aganglionosis. Two of these were girls. Small intestinal HD is more common in females.^[10-12]

In only 12 instances (15.8%) were the rectal biopsies normal. This proportion is in contrast to findings in more developed countries. As many as 89% of neonatal rectal biopsies performed on account of suspected HD were negative in a series reported by Rahman *et al.*^[1]

The availability of neonatal SRB devices in those parts of the world has made the mandatory ruling out of HD in newborns that have difficulties passing meconium, a relatively easy process. This may account for the disparity identified.

The histopathological finding of HNF is contributory to the diagnosis of HD. Its absence does not rule out the presence of the disease, especially in total colonic involvement.^[9] Non-hypertrophied nerve fibres have however been better

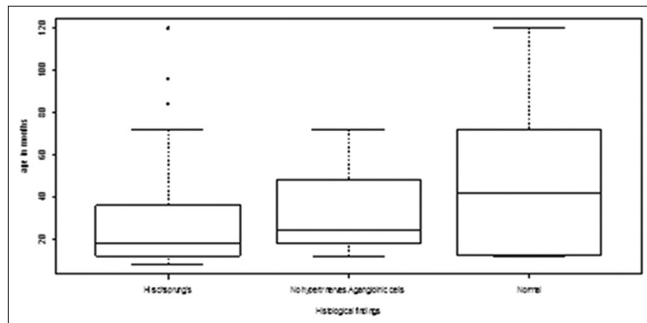


Figure 1: Age distribution with histologic findings of our patients

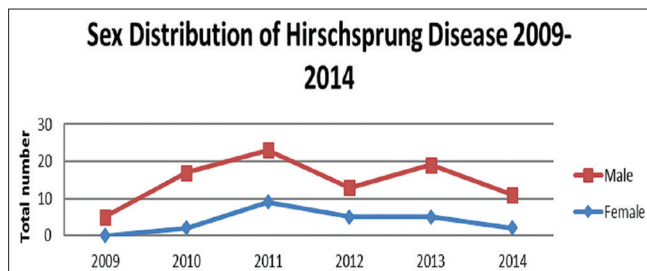


Figure 3: Sex and yearly distribution of our patients

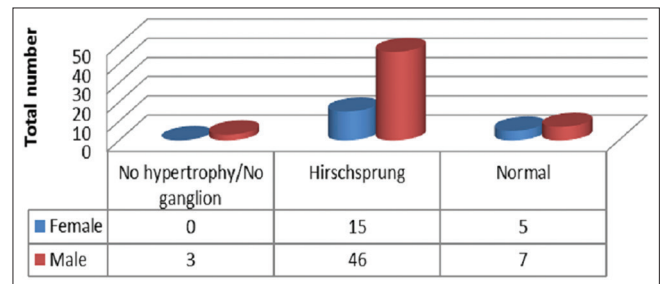


Figure 2: Histology type and sex distribution

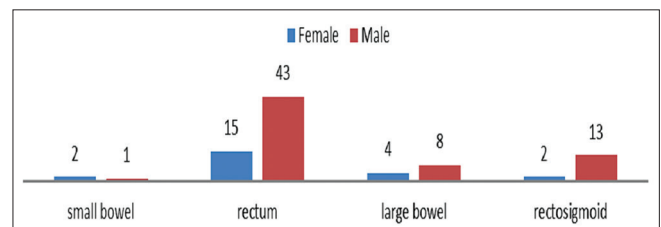


Figure 4: Rectal biopsies and extent of aganglionosis

appreciated in the presence of immature GCs.^[18,19] The nerve fibres were not hypertrophied in 3 of our cases.

CONCLUSION

This preliminary work reveals that HD is rarely confirmed by biopsy in early infancy in our setting. Public health education about the need for early presentation, improving access to specialised health care for infants and the availability of SRB are some of our suggested solutions.

Financial support and sponsorship

Nil.

Conflicts of interest

There are no conflicts of interest.

REFERENCES

- Rahman N, Chouhan J, Gould S, Joseph V, Grant H, Hitchcock R, *et al.* Rectal biopsy for Hirschsprung's disease – Are we performing too many? *Eur J Pediatr Surg* 2010;20:95-7.
- Duess JW, Hofmann AD, Puri P. Prevalence of Hirschsprung's disease in premature infants: A systematic review. *Pediatr Surg Int* 2014;30:791-5.
- Best KE, Glinianaia SV, Bythell M, Rankin J. Hirschsprung's disease in the North of England: Prevalence, associated anomalies, and survival. *Birth Defects Res A Clin Mol Teratol* 2012;94:477-80.
- Ryan ET, Ecker JL, Christakis NA, Folkman J. Hirschsprung's disease: Associated abnormalities and demography. *J Pediatr Surg* 1992;27:76-81.
- Sowande OA, Adejuyigbe O. Ten-year experience with the Swenson procedure in Nigerian children with Hirschsprung's disease. *Afr J Paediatr Surg* 2011;8:44-8.
- Shahnam A, Kamyar S. Epidemiologic and clinical specifications of patients with Hirschsprung's disease in Khuzestan province Iran. *J Surg Pak* 2008;13:75-8.
- Archibong AE. Hirschsprung's disease in children in South Eastern Nigeria. *West Afr J Med* 2001;20:242-5.
- Icaza-Chávez ME, Takahashi-Monroy T, Uribe-Urbe N, Hernández-Ortiz J, Valdovinos MA. Hirschsprung disease in the adult: Report of a case. *Rev Gastroenterol Mexico* 2000;65:171-4.
- Hiradfar M, Sharifi N, Khajedaluee M, Zabolinejad N, Jamshidi ST. Calretinin Immunohistochemistry: An aid in the diagnosis of Hirschsprung's disease. *Iran J Basic Med Sci* 2012;15:1053-9.
- Goldberg EL. An epidemiological study of Hirschsprung's disease. *Int J Epidemiol* 1984;13:479-85.
- Russell MB, Russell CA, Niebuhr E. An epidemiological study of Hirschsprung's disease and additional anomalies. *Acta Paediatr* 1994;83:68-71.
- Best KE, Addor MC, Arriola L, Balku E, Barisic I, Bianchi F, *et al.* Hirschsprung's disease prevalence in Europe: A register based study. *Birth Defects Res A Clin Mol Teratol* 2014;100:695-702.
- Meinds RJ, Kuiper GA, Parry K, Timmer A, Groen H, Heineman E, *et al.* Infant's age influences the accuracy of rectal suction biopsies for diagnosing of Hirschsprung's disease. *Clin Gastroenterol Hepatol* 2015;13:1801-7.
- Martins MR, Marques dos Santos CH, Falcao GR. Late diagnosis of Hirschsprung's disease. *J Coloproctol* 2015;35:178-81.
- Uba AF, Edino ST, Yakubu AA, Sheshe AA. Childhood intestinal obstruction in Northwestern Nigeria. *West Afr J Med* 2004;23:314-8.
- Chirdan LB, Ngiloi PJ, Elhalaby EA. Neonatal surgery in Africa. *Semin Pediatr Surg* 2012;21:151-9.
- Butler Tjaden NE, Trainor PA. The developmental etiology and pathogenesis of Hirschsprung disease. *Transl Res* 2013;162:1-5.
- Henna N, Nagi AH, Sheikh MA, Shaikat M. Morphological patterns in children with ganglion related enteric neuronal abnormalities. *J Ayub Med Coll Abbottabad* 2011;23:14-7.
- Qualman SJ, Murray R. Aganglionosis and related disorders. *Hum Pathol* 1994;25:1141-9.