

Etiopathological and Clinical Study of Acute Generalized Exanthematous Pustulosis: Experience from a Tertiary Care Hospital in North India

Abstract

Background: Acute generalized exanthematous pustulosis (AGEP) is a type of severe cutaneous adverse reaction that is characterized by the rapid development of nonfollicular, sterile pustules on an erythematous base. **Objectives:** The aim of our study was to enroll all cases of AGEP reporting to our department over a period of one year and to find out the clinical and etiological profile of the patients. **Materials and Methods:** All the patients reporting to our department with clinical features suggestive of AGEP were enrolled for the study. Careful history and examination were done to rule out other causes of pustular eruptions, which can resemble AGEP. AGEP validation score of the EuroSCAR study group was used to establish the diagnosis. **Results:** A total of 16 patients were enrolled during the study period of one year. The majority of the patients were females with a mean age of 28.41 ± 12.2 years. Twelve (75%) of the patients had a history of drug intake while 4 (25%) had developed AGEP following an insect bite. Penicillins were the causative factor in five patients followed by cephalosporins in three patients, nonsteroidal anti-inflammatory drugs (NSAIDs) in 2 patients, and terbinafine in 1 patient. Tetanus toxoid was responsible for the development of AGEP in one patient. The insect bites were all spider bites. **Conclusion:** AGEP is a rare type of severe cutaneous adverse drug reaction. We encountered 16 patients of AGEP over a period of one year. An important cause of AGEP was spider bite in our study group.

Keywords: Acute generalized exanthematous pustulosis, clinical pattern, EuroSCAR, histopathology, spider bites

Introduction

Acute generalized exanthematous pustulosis (AGEP) is a type of severe cutaneous adverse reaction that is characterized by the rapid development of nonfollicular, sterile pustules on an erythematous base. In the majority of the cases, the development of AGEP is attributed to drugs, especially antibiotics. Other causes include insect bite, contact dermatitis, and hypersensitivity to virus particles and mercury.^[1-3] The reported incidence of AGEP is one to five cases per million people per year.^[4] AGEP can occur in any age group and is found to be more common in women.^[4] Various clinical patterns of AGEP have been defined. The most common presentation is the development of an acute rash with pinhead-sized pustules on an erythematous edematous base, starting mainly in the body folds (axillary, inguinal, and submammary areas)

This is an open access journal, and articles are distributed under the terms of the Creative Commons Attribution-NonCommercial-ShareAlike 4.0 License, which allows others to remix, tweak, and build upon the work non-commercially, as long as appropriate credit is given and the new creations are licensed under the identical terms.

For reprints contact: reprints@medknow.com

and then spreading quickly within a few hours to involve the trunk and limbs. It can sometimes be associated with itching or burning sensation.^[5,6] In 20–25% of patients, mucosal involvement is seen, especially of the oral mucosa.^[7] However, various atypical and overlap variants of AGEP have been defined.

Aims and objectives

The aim of our study was to enroll all cases of AGEP reporting to our department over a period of one year from March 2017 to February 2018 and to find out the clinical and etiological profile in our study group.

Materials and Methods

All the patients reporting to our department with clinical features suggestive of AGEP were enrolled for the study. Institutional ethical clearance was sought, and informed consent was taken from all patients. Careful history was taken, and a thorough examination was done to rule out other

How to cite this article: Bhat YJ, Akhtar S, Ahmad M, Hassan I, Wani R. Etiopathological and clinical study of acute generalized exanthematous pustulosis: Experience from a tertiary care hospital in North India. Indian Dermatol Online J 2020;11:391-7.

Received: 14-May-2019. **Revised:** 30-Jul-2019.

Accepted: 19-Sep-2019. **Published:** 10-May-2020.

Yasmeen J. Bhat,
Saniya Akhtar,
Muzaffar Ahmad,
Iffat Hassan,
Rohi Wani¹

Departments of Dermatology and ¹Pathology, Sexually Transmitted Diseases and Leprosy, Government Medical College, Srinagar, University of Kashmir, Jammu and Kashmir, India

Address for correspondence:

Dr. Yasmeen J. Bhat,
Department of Dermatology,
Sexually Transmitted Diseases
and Leprosy, Government
Medical College, Srinagar,
University of Kashmir,
Jammu and Kashmir - 190 010,
India.
E-mail: yasmeenasi76@gmail.com

Access this article online

Website: www.idoj.in

DOI: 10.4103/idoj.IDOJ_232_19

Quick Response Code:



causes of pustular eruptions, which can resemble AGEF like pustular psoriasis, subcorneal pustular dermatoses, etc. In all cases, a skin biopsy was done to confirm the diagnosis. Evaluation of the causative factor was done by taking an elaborate history to find out the most relevant cause. Relevant laboratory investigations were done in each case. EuroSCAR criteria were used for scoring the intensity of AGEF in each case. Table 1 shows the AGEF validation score of the EuroSCAR study group. The patients were followed up after 2 weeks of treatment to monitor the treatment response. Also, a monthly follow-up for up to 3 months was done to note any recurrences.

Results

During the stipulated time period, a total of 16 patients were enrolled in the study. Out of all patients attending the out-patient department (OPD), AGEF constituted 0.008% of the patients. Out of these 16 patients, 11 (68.75%) were females and 5 (31.25%) were males. The mean age of the patients was 28.41 ± 12.2 years with age ranging from 7 to 50 years. The majority (62.5%) of the patients were from urban areas while the rest (37.5%) were from rural areas. There was a history of drug intake in 12 (75%) out of 16 patients. In 10 patients, there was a history of intake of medication 2 to 5 days prior to the onset of symptoms. Among these 10 patients, 8 had taken antibiotics (5-amoxicillin clavulanic acid

and 3-cephalosporins) and 2 had taken nonsteroidal anti-inflammatory drugs (NSAIDs). Figure 1 shows a female patient with AGEF over her back after intake of oral antibiotics. In the rest of the patients, one had developed cutaneous rash following the intake of terbinafine for tinea corporis and tinea cruris while the other one had developed symptoms after tetanus toxoid injection. In four patients, there was a history of insect bite by spiders 2 to 4 days before onset of symptoms. In two patients, the site of the bite was the arm while in one it was on the breast and the other on abdomen. Figure 2a shows an eruption of nonfollicular pustules over the left breast in a female with the insect bite in the same area, which later became generalized [Figure 2b]. Most of the patients presented within 1 to 2 days of the onset of symptoms while some presented late after 4 to 5 days. In these 16 patients, 3 had associated systemic comorbidities in the form of diabetes mellitus (DM). Fever was present in 12 of the 16 patients. The most common sites of involvement were the arms, neck, axillae, and abdomen followed by the back, legs, chest, and flanks. None of the patients had associated mucosal involvement. Also, we did not encounter any patient of overlap with drug reaction with eosinophilia and systemic symptoms (DRESS) or toxic epidermal necrolysis (TEN). Only in one patient, the cutaneous eruption was accompanied by erythematous edema of the hands and face. Laboratory investigations like complete blood count (CBC),

Table 1: AGEF validation score of EuroSCAR study group

Variable	Score	Variable	Score
Morphology		Course	
Pustules		Mucosal involvement	
Typical*	+2	Yes	-2
Compatible**	+1	No	0
Insufficient***	0	Acute onset (<10d)	
Erythema		Yes	0
Typical	+2	No	-2
Compatible	+1	Resolution <15 days	
Insufficient	0	Yes	0
Distribution		No	-4
Typical	+2	Fever >38.75°C	
Compatible	+1	Yes	+1
Insufficient	0	No	0
Postpustular desquamation		PMNs >7000/mm ³	
Yes	+1	Yes	+1
No/insufficient	0	No	0
		Histology	
		Other diseases	-10
		Not representative/No histology	0
		Exocytosis of PMN	+1
		Subcorneal and/or intraepidermal nonspongiform or NOS pustules with papillary edema or subcorneal and/or intraepidermal spongiform or NOS pustule (s) without papillary edema	+2
		Spongiform subcorneal and/or intraepidermal pustule (s) with papillary edema	+3

Interpretation: 0=no AGEF, 1-4=Possible AGEF, 5-7=Probable AGEF, and 8-12=Definite AGEF, *Typical: typical morphology, **Compatible: not typical, but not suggestive of other disease, and ***Insufficient: lesions cannot be judged, AGEF=Acute generalized exanthematous pustulosis, PMN=Polymorphonuclear neutrophils, NOS=Not otherwise specified

including total and differential leukocyte count, absolute eosinophil count, C-reactive protein, serum calcium, kidney function test (KFT), liver function test (LFT), blood sugars, routine urine examination, chest X-ray, and electrocardiogram (ECG) were done in all cases. Ten patients had increased leukocyte count with neutrophilia. C-reactive protein was positive in eight patients. Blood sugars were deranged in three patients who had associated DM. Rest all investigations were within the normal limits. Histopathological examination was done in all cases to support the diagnosis. A fresh pustule was selected for biopsy. Figures 3-5 depict the typical histopathological

features seen in cases of AGEP in our study. The AGEP validation score of the EuroSCAR study group was used to establish the diagnosis.^[4] A score between 8 and 12 for AGEP was diagnostic. All the patients in our study fulfilled the EuroSCAR validation score for AGEP as shown in Table 2.

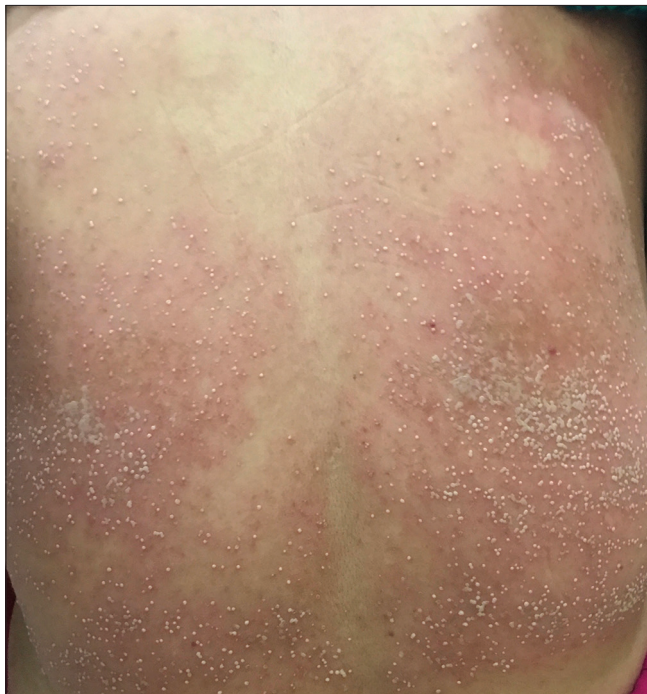

Figure 1: A female patient with AGEP over back after intake of oral antibiotics

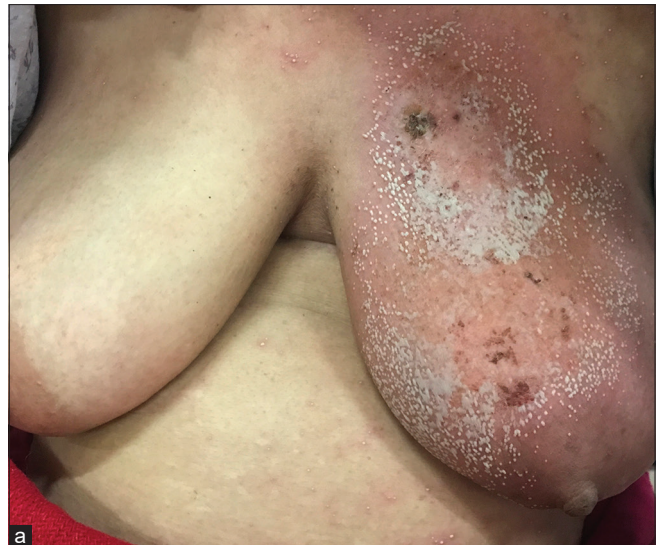

Figure 2: (a) Eruption of nonfollicular pustules over the left breast in a female with insect bite in the same areathat later became generalized (b) Same patient with pustules over both arms after the eruption became generalized

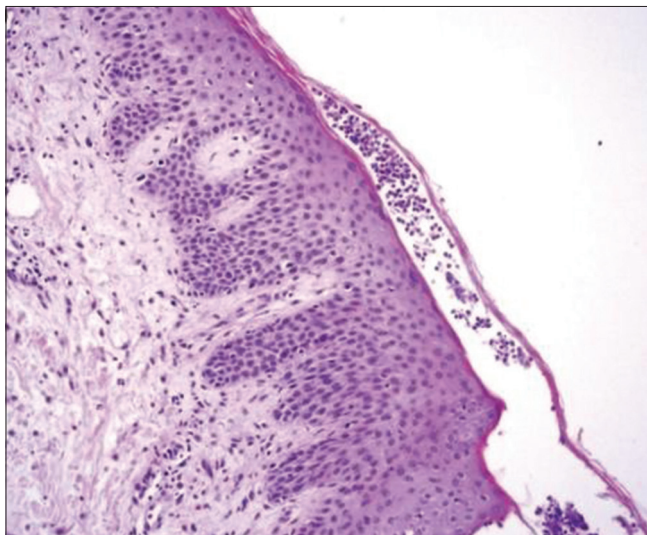


Figure 3: Photomicrograph showing subcorneal bulla filled with acute inflammatory cell infiltrate and superficial dermal inflammation (H and E 100)

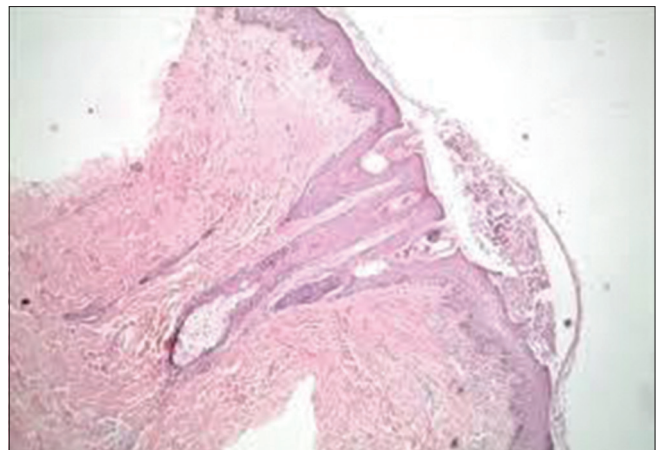


Figure 4: Photomicrograph showing subcorneal pustule and dermal inflammation (H and E 40)

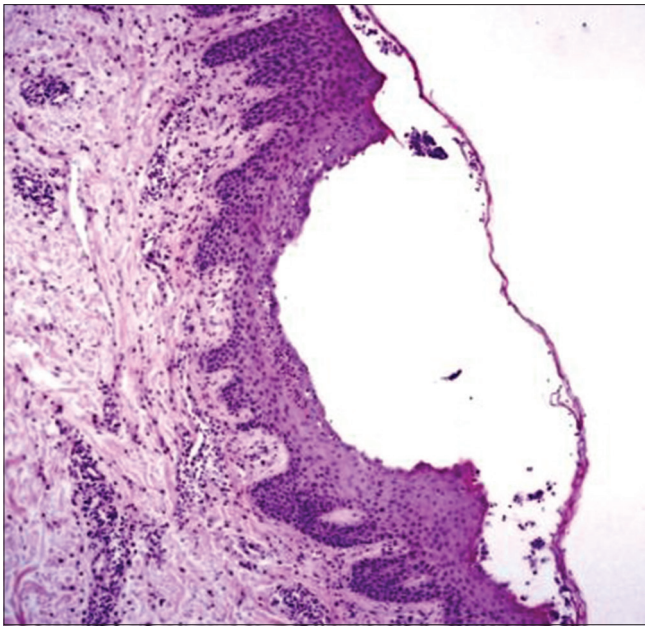


Figure 5: Photomicrograph showing superficial (subcorneal) bulla formation with edema of the papillary dermis and perivascular chronic dermal inflammatory cell infiltrate (H and E 100)

Discontinuation of the causative agent was done in all cases developing AGEF after intake of some medication/vaccine. Supportive treatment in the form of antipyretics and topical steroids was given in all cases who had fever. Depending on the disease severity, a short course of usually 3–5 days of high dose systemic steroids in the form of dexamethasone 8 mg was given to all patients. Patients with AGEF secondary to insect bite were given supportive treatment in the form of antipyretics, antihistamines, and cold sponging along with antibiotics (azithromycin 500 mg once daily for 5 to 7 days depending on severity of bite) and systemic steroids. All patients were followed up after 2 weeks of initiation of treatment. There was the resolution of the pustules in all cases with the desquamation of the skin that was treated with the daily application of moisturizers. No difference in the duration of resolution of lesions was noticed in the drug induced and post spider bite cases. Patients were followed up monthly for 3 months to assess the recurrence of the disease. However, none of the patients developed any recurrence and there was a complete resolution of the lesions by 3 months.

Discussion

AGEF is a rare type of severe cutaneous adverse drug reaction in which we encountered 16 patients over a period of one year. The majority (68.75%) of the patients in our study group were females. AGEF has been reported more commonly in females as compared with males.^[4] The mean age of patients was 28.4 years in our cases, but AGEF has been reported in all age groups in literature.^[4] The main cause of the development of AGEF in our study group was medication. An extensive list

of drugs has been reported to be responsible for AGEF. Certain medications like antibiotics, mainly macrolides and beta-lactams (β -lactams), as well as quinolones and tetracyclines are the most common causative agents for AGEF. Other drugs that have also been implicated include calcium channel blockers like diltiazem and carbamazepine; antimycotics like terbinafine and pristinamycin; antimalarials; and NSAIDs.^[8]

AGEF is a T cell-related Type IVd reaction in which activation, proliferation, and migration of drug-specific CD4 and CD8 T cells play an important role in the development of the disease.^[9,10] Drug-specific cytotoxic T cells and cytotoxic proteins, such as granzyme B and perforin, are believed to induce the apoptosis of keratinocytes, leading to subcorneal vesicles.^[10,11] Chemokine (C-X-C motif) ligand 8 (CXCL8)/IL-8 is thought to play a central role in the formation of pustules by the recruitment of neutrophils. Also, increased levels of IL-17, IL-22, and granulocyte-macrophage colony-stimulating factor (GM-CSF) are believed to lead to strong neutrophilic activity in AGEF patients.^[11,12]

We found the penicillin group of antibiotics to be the major cause of AGEF, which is consistent with a study done in Taiwan, where β -lactam antibiotics were found to be the major drug class responsible for inducing AGEF in the Taiwanese population.^[13] Among antibiotics, penicillins and macrolides are considered to be the most notorious for causing AGEF.^[14,15] However, we found that penicillins followed by cephalosporins are the main causative factors in our study group. Cephalosporins have also been implicated in literature as a causative agent in AGEF^[16,17] although less frequently.

Also, NSAIDs were implicating drugs in two patients. There have been previous case reports of NSAIDs causing AGEF, mainly by acetylsalicylic acid (ASA),^[18] piroxicam,^[19] and mefenamic acid.^[20] Ibuprofen has been reported to cause acute localized exanthematous pustulosis (ALEP)^[21] as well as AGEF.^[22-24]

Terbinafine is an allylamine antifungal drug reported to cause adverse reactions in more than 7% of the cases. It has been associated with AGEF, pustular psoriasis,^[25] and even severe reactions like Stevens–Johnson syndrome (SJS).^[26] We also experienced one case of AGEF secondary to terbinafine in our study group.

Vaccines have also been rarely implicated as a cause of AGEF in few published reports. We found one case of AGEF secondary to the tetanus toxoid vaccine, which the patient received after suffering an injury with a metallic rod. There was no history of any preceding or concomitant infection or drug intake or psoriasis in this patient. So, the development of the rash was attributed to the vaccine itself and on follow-up, the pustules subsided in 2 weeks duration. AGEF secondary to influenza vaccine has been

Table 2: Patient characteristics of all 16 patients with EuroSCAR validation score with the grading of histopathology expanded in the footnote

Incriminating agent	Morphology	Postpustular desquamation	Mucosal involvement	Acute onset (<10d)	Resolution <15 days	Fever >38.75°C	Neutrophils >7000/mm ³	Histology	EuroSCAR score
Amoxicillin clavulanic acid	Pustules +2	Y	N	Y	Y	Y	Y	+1	10
	Erythema +2								
	Distribution +2								
Cephalosporins	Pustules +2	Y	N	Y	Y	Y	Y	0	9
	Erythema +2								
	Distribution +2								
NSAIDs	Pustules +2	Y	N	Y	Y	Y	N	0	8
	Erythema +2								
	Distribution +2								
Amoxicillin clavulanic acid	Pustules +2	Y	N	Y	Y	Y	Y	+3	11
	Erythema +1								
	Distribution +2								
Insect bite	Pustules +2	Y	N	Y	Y	N	Y	+2	10
	Erythema +2								
	Distribution +2								
Cephalosporins	Pustules +2	Y	N	Y	Y	Y	Y	+1	10
	Erythema +2								
	Distribution +2								
Amoxicillin clavulanic acid	Pustules +2	Y	N	Y	Y	Y	N	0	8
	Erythema +2								
	Distribution +2								
NSAIDs	Pustules +2	Y	N	Y	Y	N	Y	+2	10
	Erythema +2								
	Distribution +2								
Insect bite	Pustules +2	Y	N	Y	Y	Y	N	+2	10
	Erythema +2								
	Distribution +2								
Cephalosporins	Pustules +2	Y	N	Y	Y	Y	Y	0	8
	Erythema +2								
	Distribution +1								
Amoxicillin clavulanic acid	Pustules +2	Y	N	Y	Y	Y	N	+1	9
	Erythema +2								
	Distribution +2								
Insect bite	Pustules +2	Y	N	Y	Y	N	Y	+2	10
	Erythema +2								
	Distribution +2								
Insect bite	Pustules +2	Y	N	Y	Y	Y	N	+3	11
	Erythema +2								
	Distribution +2								
Amoxicillin clavulanic acid	Pustules +2	Y	N	Y	Y	N	Y	0	8
	Erythema +2								
	Distribution +2								
Terbinafine	Pustules +2	Y	N	Y	Y	Y	N	+1	9
	Erythema +2								
	Distribution +2								

Contd...

Table 2: Contd...

Incriminating agent	Morphology	Postpustular desquamation	Mucosal involvement	Acute onset (<10d)	Resolution <15 days	Fever >38.75°C	Neutrophils >7000/mm ³	Histology	EuroSCAR score
Tetanus toxoid vaccine	Pustules +2 Erythema +1 Distribution +2	Y	N	Y	Y	Y	Y	+1	9

0=Not representative/No histology, +1=Exocytosis of PMN, Subcorneal and/or intraepidermal non-spongiform or NOS pustules with papillary edema or subcorneal and/or intraepidermal spongiform or NOS pustule(s) without papillary edema: +2, Spongiform subcorneal and/or intraepidermal pustule(s) with papillary edema: +3, NSAIDs=Nonsteroidal anti-inflammatory drugs, PMN=Polymorphonuclear neutrophils, NOS=Not otherwise specified

reported in a Japanese pregnant female.^[27] The mechanisms of AGEP reactions in response to vaccination are not fully understood. It has been assumed that hyperimmunization and/or dysregulated cytokine production is responsible for AGEP reactions after vaccination rather than an allergic response.^[27]

We also noted four cases of AGEP secondary to insect bites. In all these cases, the patients implicated the bite to spiders in their homes. Earlier also, cases of AGEP secondary to insect bites have been reported from India^[3] and also from other parts of the world.^[28-33] The exact mechanism behind the development of AGEP following spider bite is unknown, but it is postulated that the spider venom contains sphingomyelinase, which can lead to the release of various inflammatory mediators that trigger AGEP.^[33,34]

AGEP needs to be differentiated from other pustular eruptions like bacterial or fungal infections and neutrophilic dermatoses by a careful history, examination, and histopathological findings. AGEP is characterised by an acute onset of usually less than 10 days from exposure to an offending agent like medication, vaccine or bite to the appearance of symptoms. It can occur even after the first exposure to an incriminating agent. Also, acute generalized pustular psoriasis may be difficult to differentiate from AGEP as both conditions can present with the same clinical picture, and the histopathology may also not be able to differentiate between the two in some cases. The quicker resolution time seen in cases of AGEP is very helpful in diagnosis. Also, follow up of patients for resolution of the disease and any recurrence is equally important. DRESS and SJS/TEN are other entities that can be confused with severe cases of AGEP. However, the clinical picture of AGEP is dominated by pustules rather than morbilliform rash in DRESS and epidermal detachment in cases of SJS/TEN.

The pattern of AGEP cases seen in our study is primarily like other studies with medications being the most common cause. We did not find any patient with associated DRESS and SJS/TEN. However, AGEP, secondary to insect bites, was reported more commonly in our study group (25% of the cases). The exact cause of this finding is difficult

to ascertain, but we hypothesize that the spiders found in our study location are relatively more toxic than in other parts of India resulting in more cases seen in our study.

Declaration of patient consent

The authors certify that they have obtained all appropriate patient consent forms. In the form, the patient(s) has/have given his/her/their consent for his/her/their images and other clinical information to be reported in the journal. The patients understand that their names and initials will not be published, and due efforts will be made to conceal their identity, but anonymity cannot be guaranteed.

Financial support and sponsorship

Nil.

Conflicts of interest

There are no conflicts of interest.

References

1. Speeckaert MM, Speeckaert R, Lambert J, Brochez L. Acute generalized exanthematous pustulosis: An overview of the clinical, immunological and diagnostic concepts. *Eur J Dermatol* 2010;20:425-33.
2. Spencer JM, Silvers DN, Grossman ME. Pustular eruption after drug exposure: Is it pustular psoriasis or a pustular drug eruption? *Br J Dermatol* 1994;130:514-9.
3. Bhat YJ, Hassan I, Sajad P, Yaseen A, Wani R. Acute generalized exanthematous pustulosis due to insect bites? *Indian J Dermatol* 2015;60:422.
4. Sidoroff A, Halevy S, Bavinck JN, Vaillant L, Roujeau JC. Acute generalized exanthematous pustulosis (AGEP)-A clinical reaction pattern. *J. Cutan Pathol* 2001;28:113-9.
5. Beylot C, Doutre MS, Beylot-Barry M. Acute generalized exanthematous pustulosis. *Semin Cutan Med Surg* 1996;15:244-9.
6. Sidoroff A. Acute generalized exanthematous pustulosis. *Chem Immunol Allergy* 2012;97:139-48.
7. Roujeau JC, Bioulac-Sage P, Bourseau C, Guillaume JC, Bernard P, Lok C, et al. Acute generalized exanthematous pustulosis. Analysis of 63 cases. *Arch Dermatol* 1991;127:1333-8.
8. Chang SL, Huang YH, Yang CH, Hu S, Hong HS. Clinical manifestations and characteristics of patients with acute generalized exanthematous pustulosis in Asia. *Acta Derm Venereol* 2008;88:363-5.
9. Britschgi M, Pichler WJ. Acute generalized exanthematous

- pustulosis, a clue to neutrophil-mediated inflammatory processes orchestrated by T cells. *Curr Opin Allergy Clin Immunol* 2002;2:325-31.
10. Schmid S, Kuechler PC, Britschgi M, Steiner UC, Yawalkar N, Limat A, *et al.* Acute generalized exanthematous pustulosis: Role of cytotoxic T cells in pustule formation. *Am J Pathol* 2002;161:2079-86.
 11. Schlapbach C, Zawodniak A, Irla N, Adam J, Hunger RE, Yerly D, *et al.* NKp46+ cells express granulysin in multiple cutaneous adverse drug reactions. *Allergy* 2011;66:1469-76.
 12. Kabashima R, Sugita K, Sawada Y, Hino R, Nakamura M, Tokura Y. Increased circulating Th17 frequencies and serum IL-22 levels in patients with acute generalized exanthematous pustulosis. *J Eur Acad Dermatol Venereol* 2011;25:485-8.
 13. Yung-Yi Lee, Wen-Hung Chung. Acute generalized exanthematous pustulosis: A retrospective study of 51 cases in Taiwan. *Dermatologica Sinica* 2014;32:137-40.
 14. Manders SM, Heymann WR. Acute generalized exanthematous pustulosis. *Cutis* 1994;54:194-6.
 15. Trevisi P, Patrizi A, Neri I, Farina P. Toxic pustuloderma associated with azithromycin. *Clin Exp Dermatol* 1994;19:280-1.
 16. Botelho LFF, Picossea FR, Padilha MH, Michalanyb N, Góisc A, Porroa AM. Acute generalized exanthematous pustulosis induced by cefepime: A case report. *Case Rep Dermatol* 2010;2:82-7.
 17. Chaabanea A, Aouama K, Gassabb L, Njime L, Boughattas NA. Acute generalized exanthematous pustulosis (AGEP) induced by cefotaxime. *Fund Clin Pharmacol* 2010;24:429-32.
 18. Bahuguna A. Acute generalized exanthematous pustulosis: A rare side effect of a common over-the-counter drug, Acetylsalicylic acid. *Indian Dermatol Online J* 2013;4:231-3.
 19. Cherif Y, Jallouli M, Mseddi M, Turki H, Bahloul Z. Acute generalized exanthematous pustulosis induced by piroxicam: A case report. *Indian J Pharmacol* 2014;46:232-3.
 20. Singh EN, Prakash C, Agarwal US, Verma M. Mefenamic acid induced acute generalized exanthematous pustulosis (AGEP): A case report. *Int J Multispecialty Health (IMJH)* 2017;3:49-52.
 21. Rastogi S, Modi M, Dhawan V. Acute localized exanthematous pustulosis (ALEP) caused by Ibuprofen. A case report. *Br J Oral Maxillofac Surg* 2009;47:132-4.
 22. Yesudian PD, Penny M, AzurdiaRM, King CM. Ibuprofen-induced acute generalized exanthematous pustulosis. *Int J Dermatol* 2004;43:208-10.
 23. Belz D, Persa OD, Haese S, Hunzelmann N. Acute generalized exanthematous pustulosis caused by ibuprofen—Diagnosis confirmed by patch testing. *Contact Dermatitis* 2018;79:40-41.
 24. Arochena L, Zafra MP, Fariña MC, PozoVD, Fernández-Nieto M. Acute generalized exanthematous pustulosis due to ibuprofen. *Ann Allergy Asthma Immunol* 2013;110:386-7.
 25. Duckworth L, Maheshwari MB, Thomson MA. A diagnostic challenge: Acute generalized exanthematous pustulosis or pustular psoriasis due to terbinafine. *Clin Exp Dermatol* 2012;37:24-7.
 25. Beltraminelli HS, Lerch M, Arnold A, Bircher AJ, Haeusermann P. Acute generalized exanthematous pustulosis induced by the antifungal terbinafine: Case report and review of the literature. *Br J Dermatol* 2005;152:780-3.
 27. MatsuoS, NishizawaA, Oshio-Yoshii A, Satoh T. Influenza vaccine-induced acute generalized exanthematous pustulosis during pregnancy. *J Dermatol* 2017;44:598-610.
 28. Davidovici BB, Pavel D, Cagnano E, Rozenman D, Halevy S; EuroSCAR, RegiSCAR study group. Acute generalized exanthematous pustulosis following a spider bite: Report of 3 cases. *J Am Acad Dermatol* 2006;55:525-9.
 29. Ben Said Z, Saidi W, Boussofara L, Ghariani N, Belajouza C, Sriha B, *et al.* Acute generalized exanthematous pustulosis following a spider bite: Three cases from Tunisia. *Ann Dermatol Venereol* 2010;137:813-8.
 30. Makris M, Spanoudaki N, Giannoula F, Chliva C, Antoniadou A, Kalogeromitros D. Acute generalized exanthematous pustulosis (AGEP) triggered by a spider bite. *Allergol Int* 2009;58:301-3.
 31. Pippirs U, Mehlhorn H, Antal AS, Schulte KW, Homey B. Acute generalized exanthematous pustulosis following a *Loxosceles* spider bite in Great Britain. *Br J Dermatol* 2009;161:208-9.
 32. Lane L, McCoppin HH, Dyer J. Acute generalized exanthematous pustulosis and Coombs positive hemolytic anemia in a child following *Loxoscelesreclusa* envenomation. *Pediatr Dermatol* 2011;28:685-8.
 33. Ermertcan AT, Demirer O, Inanir I, Bilaç C, Temiz P. Acute generalized exanthematous pustulosis with lymphangitis triggered by a spider bite. *Cutan Ocul Toxicol* 2010;29:67-9.
 34. Britschgi M, Steiner UC, Schmid S, Depta JP, Senti G, Bircher A, *et al.* T cell involvement in drug induced acute generalized exanthematous pustulosis. *J Clin Invest* 2001;107:1433-41.