

# Cystic Echinococcosis of the Pelvic Bone with Recurrences: A Case Report

Sunila Jain<sup>1,\*</sup> and Prem Chopra<sup>1</sup>

<sup>1</sup>Pathology Department, Sir Ganga Ram Hospital, Rajinder Nagar, New Delhi, Delhi 110060, India

**Abstract:** Hydatid cysts commonly affect the liver and the lung. However, they rarely involve bones with vertebral column. We hereby report a case of a female patient with cystic echinococcosis of the hip bone and ilium. She presented with a long history of frequent recurrences highlighting the dismal prognosis at this rare site. Resection of the hydatid cyst from the sacroiliac region was done with allograft and autograft (rib graft) with lumbosacroiliac fixation. Follow-up of the patient at 6 months showed no detectable abnormality on radiology and the patient was doing well.

**Key words:** *Echinococcus granulosus*, pelvic bone, hydatid, case report, India

## INTRODUCTION

Cystic echinococcosis of the bone is rare with an incidence of 0.5 to 2.5% [1], and as compared to other sites, osseous hydatidosis presents late, as it is usually not suspected clinically because of its rare occurrence at this site. Bone hydatidosis is difficult to treat and carries high morbidity due to frequent recurrences, especially in certain locations, like ilium and hip, where radical surgery is difficult. We herein report a case of cystic echinococcosis of the hip bone and pelvis for its uncommon site and frequent recurrences depicting a poor prognosis and high morbidity at this site. Only a few case reports of long term follow-up of such cases are available in literature.

## CASE REPORT

A 31-year-old Asian Indian female presented to the outpatient department of Sir Ganga Ram Hospital, New Delhi, India with a history of increasing pain in the right hip and pelvis for the last 3 years. Pain was progressively increasing in intensity, radiating to the right lower limb and back, increased on movements and associated with tingling sensation since last 3 months.

The patient had become quite incapacitated due to painful restricted movements. Her past history showed that at 22 years of age, she had presented with a large abdominal mass. Her CT at that time showed a multicystic lesion measuring 18.0 × 9.8 × 7.6 cm in the right abdomen, which appeared to be arising from the right ovary. The liver and other organs, including the uterus, kidneys, and left ovary, were normal. Her lung x-ray at that time was normal. Thus, with a clinical diagnosis of a right ovarian tumour, she underwent surgery which showed a hydatid cyst which was confirmed on histopathology. Peroperatively her ovaries were normal with presence of paraovarian cystic masses which were densely adherent to the right ovary.

After remaining asymptomatic for 3 years, in 2007, she again gradually developed pain in the right pelvic region. This time MRI showed a large solid cystic mass measuring 10 × 6.3 cm in the right iliac fossa and right gluteal region. It was arising from the right iliac bone, involving right sacroiliac joint and adjacent marrow of the sacrum. All other pelvic organs were unremarkable. With a clinical possibility of tumour or tuberculosis, a diagnostic laparotomy was planned. Peroperatively, multiple cysts in the iliac bone with osteolysis were seen. Two cystic pieces were removed which were diagnosed as hydatid cyst. In view of the complicated nature of cysts and location it could not be completely excised.

The patient continued with the pelvic pain although post-operative MRI showed reduction in size of the lesion along the right iliac bone and sacroiliac joint. No new lesion was, however, seen. The x-ray of the pelvis and hips revealed cortical ir-

•Received 19 July 2011, revised 10 August 2011, accepted 10 August 2011.

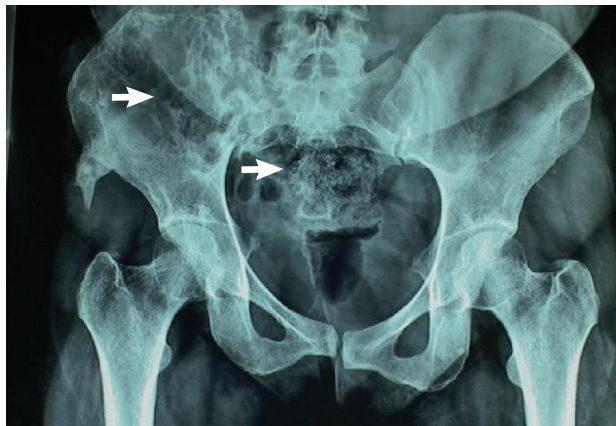
\*Corresponding author (S. Isha19@rediffmail.com)

© 2011, Korean Society for Parasitology

This is an Open Access article distributed under the terms of the Creative Commons Attribution Non-Commercial License (<http://creativecommons.org/licenses/by-nc/3.0>) which permits unrestricted non-commercial use, distribution, and reproduction in any medium, provided the original work is properly cited.

regularity with ill defined lytic defects and linear areas of patchy sclerosis along the right iliac blade (Fig. 1). She continued with pain and follow-up CT reviewed after 8 months revealed extension of the disease. The patient was then referred to our hospital. On physical examination, local tenderness was present on the back of the right limb and hip. The range of motion of the right hip was painful and restricted. No distal neurovascular deficits were present. Blood investigations were within normal range. Surgery was planned for removal of the residual disease. The preoperative MRI and CT showed progression of the disease. The CT showed a multiloculated cystic lesion (Fig. 2) involving the medullary cavity of the right iliac bone resulting in irregular lytic destruction and extending across the right sacroiliac joint into the right half of the sacrum, right sacral foramina, and adjacent soft tissues. Resection of the hydatid cyst of sacroiliac region with allograft and autograft (rib graft) with lumbosacroiliac fixation was done.

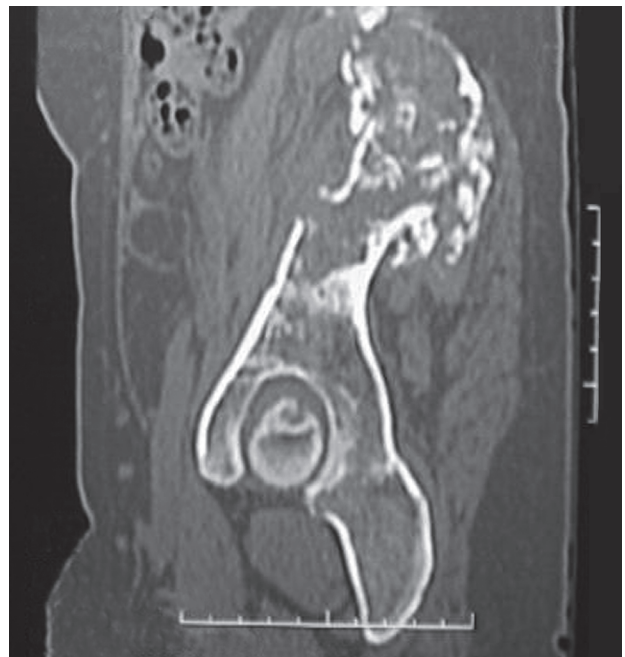
Histopathology results revealed hydatid cysts of the bone. Fragments of the osseous tissue with hyaline and laminated membranes of hydatid cysts were seen admixed with lymphocytes and monocytes (Fig. 3). Focal areas of necrosis, calcification, palisading histiocytes, and numerous foreign body granulomas were observed in the intertrabecular spaces. The serological and molecular identification of the parasite, however, could not be performed due to non-availability of the facility in the hospital. She was also put on a medical treatment with albendazole for 1 month. The postoperative period was uneventful and patient was discharged on the 10th day of surgery. The follow-up of the patient at 6 months showed no detectable abnormality on radiology, and she was doing well.



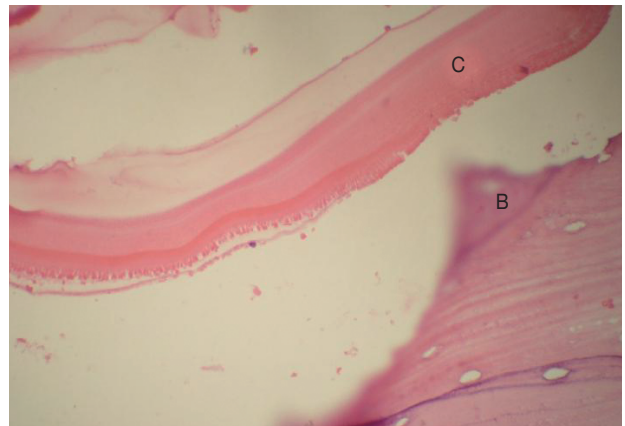
**Fig. 1.** X-ray of pelvis and hips revealed ill-defined lytic defects and linear areas of patchy sclerosis along the right iliac blade (arrows).

## DISCUSSION

Cystic echinococcosis is caused by a parasitic tapeworm, echinococcus. In humans, 3 forms of echinococcosis are known to occur; cystic echinococcosis (CE), caused by *Echinococcus granulosus*, alveolar echinococcosis (AE), caused by *Echinococcus multilocularis*, and polycystic echinococcosis (PE), due to *Echinococcus vogeli* or *Echinococcus oligarthrus*. The liver and lung in-



**Fig. 2.** CT revealed a multiloculated cystic SOL involving the medullary cavity of the right iliac bone and causing irregular lytic destruction extending into the right SI joint, right half of the sacrum, and right sacral foramina.



**Fig. 3.** Hydatid cyst wall fragments (C) interspersed within the bone (B) (H-E,  $\times 400$ ).

volvement together account for at least 90% of the cysts. Other organs, which may rarely be infected, are the kidney, spleen, muscles and skin, and bones [2].

Bone involvement of echinococcosis rarely occurs. Common reported sites of bone involvement were the vertebra, femur, and pelvis [3,4]. Occasional cases have been reported in the rib and humerus. The disease in the bone starts when scolices settle there. Skeletal cystic echinococcosis lesions may be single or multiple. Most of the patients become symptomatic at an advanced stage with symptoms of pain and tenderness at the affected site and rarely with fracture. The disease slowly destroys the bone with trabecular resorption.

Bone hydatidosis is usually diagnosed by roentgenographic studies [5]. MRI is the most helpful of all the imaging modalities and should be done to evaluate the extent of the disease and planning of the treatment [5]. Immunological studies are not much helpful. At times, however, radiology may mimic a variety of benign and malignant lesions of the bone. In all these cases, histopathology gives the correct diagnosis. The principal treatment of cystic echinococcosis of the bone is surgery with wide excision followed by mebendazole therapy. Chemotherapy is more useful for inoperable cases.

Bone hydatidosis commonly present with recurrences as was seen in the present case leading to high morbidity. The results of treatment of osseous hydatidosis are satisfactory only in locations where complete and wide excision is possible. In the pelvis and hip, where radical surgery is almost impossible, the results are disappointing even after aggressive treatments, hence,

they present with frequent recurrences [6,7] and a long term follow-up is therefore recommended.

The purpose of this study is to be aware of this disease at this rare location. This will help early diagnosis and planning of the treatment. It also highlights that a more aggressive treatment is needed to minimize recurrences in bone involvement by cystic echinococcosis and a long-term follow-up of these patients needs to be done.

## REFERENCES

1. Sapkas GS, Stathakopoulos DP, Babis GC, Tsarouchas JK. Hydatid disease of bones and joints. 8 cases followed for 4-16 years. *Acta Orthop Scand* 1998; 69: 89-94.
2. World Health Organization. WHO/OIE Manual on Echinococcosis in Humans and Animals: A Public Health Problem of Global Concern. Eckert J et al. (eds.). 2001.
3. Siwach R, Singh R, Kadian VK, Singh Z, Jain M, Madan H, Singh S. Extensive hydatidosis of the femur and pelvis with pathological fracture: A case report. *Int J Infect Dis* 2009; 13: e480-2.
4. Stavrev VP, Poryazova EG, Chonova EV. A case of pelvic bone hydatidosis-diagnosis and treatment. *Folia Med (Plovdiv)* 2006; 48: 60-63.
5. Edeiken J, Dalinka M, Karasick D. Edeiken, Roentgen Diagnosis of Disease of Bone. Vol. 1 (4th ed). Baltimore, Maryland, USA, William and Wilkins. 1990.
6. Herrera A, Martínez AA. Extraspinal bone hydatidosis. *J Bone Joint Surg Am* 2003; 85-A(9): 1790-1794.
7. Massè A, Parola PG, Brach del Prever EM, Gallinaro P. Hydatidosis of the pelvis: A case report with a 25-year follow-up. *Arch Orthop Trauma Surg* 2004; 124: 203-205.

