

# A case of repetitive myocardial infarction with unobstructed coronaries due to Churg–Strauss syndrome

Ying X. Gue<sup>1,2</sup>, Sanjay Prasad<sup>3,4</sup>, David Isenberg<sup>5</sup>, and Diana A. Gorog<sup>1,2,4\*</sup>

<sup>1</sup>Department of Cardiology, Lister Hospital, East and North Hertfordshire NHS Trust, Stevenage, UK; <sup>2</sup>Department of Postgraduate Medicine, University of Hertfordshire, Hertfordshire, UK; <sup>3</sup>Royal Brompton Hospital, Royal Brompton & Harefield NHS Foundation Trust, London, UK; <sup>4</sup>National Heart & Lung Institute, Imperial College, Dovehouse Street, London SW36LY, UK; and <sup>5</sup>University College Hospital, University College London Hospitals NHS Foundation Trust, London, UK

Received 6 July 2018; accepted 3 April 2019; online publish-ahead-of-print 24 April 2019

## Background

Myocardial infarction is most commonly caused by thrombosis occurring on a background of coronary atherosclerosis, resulting in reduced coronary flow. Less often, myocardial infarction can occur in the absence of coronary disease. The pathomechanism of myocardial infarction in such patients is heterogeneous and more challenging to diagnose and treat. European Society of Cardiology published a position paper on myocardial infarction in patients with non-obstructive coronary disease, with definitions and recommendations for investigations, in what has hitherto been an under-recognized and under-investigated Cinderella-like condition. However, the importance of obtaining a diagnosis is all the more important, since one treatment approach with revascularization and antithrombotic treatment does not 'fit all'.

## Case summary

A 70-year-old male patient presented with chest pain at rest, associated with rise in troponin and without ECG changes. A diagnosis of non-ST elevation myocardial infarction was made. Coronary angiography showed a smooth stenosis which resolved with administration of intracoronary nitrate. A diagnosis of coronary artery spasm was made, and treatment initiated. After 18 months, the patient had recurrent chest pains at rest, unresponsive to glyceryl trinitrate (GTN). Cardiac magnetic resonance revealed extension of subendocardial infarction, without inducible ischaemia. CT coronary angiogram (CTCA) showed non-obstructive coronaries. Blood tests showed significant eosinophilia, raised troponin, and C-reactive protein (CRP) that fluctuated without correlation with symptoms or any ECG changes. A diagnosis of Churg–Strauss syndrome was made, and immunosuppression commenced.

## Discussion

Churg–Strauss syndrome is an autoimmune vasculitis in patients with history of atopy or late-onset asthma which when involving coronary arteries can lead to myocardial injury mimicking acute coronary syndrome (ACS). Identification is important to allow initiation of immunosuppression which can prevent development or progression.

## Keywords

Case report • Myocardial infarction • Churg–Strauss Syndrome • Normal coronary arteries • MINOCA

\* Corresponding author. Tel: +44(0)1707 247512, Email: [d.gorog@imperial.ac.uk](mailto:d.gorog@imperial.ac.uk)

Handling Editor: Vijay Kunadian

Peer-reviewers: Sameh Shaheen and Dean Milasinovic

Compliance Editor: Christian Fielder Camm

Supplementary Material Editor: Peysh A Patel

© The Author(s) 2019. Published by Oxford University Press on behalf of the European Society of Cardiology.

This is an Open Access article distributed under the terms of the Creative Commons Attribution Non-Commercial License (<http://creativecommons.org/licenses/by-nc/4.0/>), which permits non-commercial re-use, distribution, and reproduction in any medium, provided the original work is properly cited. For commercial re-use, please contact [journals.permissions@oup.com](mailto:journals.permissions@oup.com)

## Learning points

- Myocardial infarction with non-obstructive coronary arteries is a working diagnosis—further investigations should be performed to determine the underlying cause so appropriate treatment can be initiated.
- The lack of correlation between the extent of epicardial coronary disease and cardiac magnetic resonance findings should point to systemic causes.
- The history of myocardial infarction, late-onset asthma combined with eosinophilia is highly suggestive of Churg–Strauss syndrome (eosinophilic granulomatosis with polyangiitis) with cardiac involvement.
- This is an important diagnosis to make, as without immunosuppression, ongoing myocardial infarction and loss of myocardium may ensue, which can be halted by immunosuppression.

## Introduction

Myocardial infarction is most commonly caused by thrombus formation superimposed on coronary artery narrowing resulting from atherosclerosis. Recently, a new term of interest has been coined by researchers to describe a different group of patients who has myocardial infarction that are not associated with significant coronary artery disease—myocardial infarction with non-obstructive coronary arteries (MINOCA). A recent European Society of Cardiology (ESC) working group position paper<sup>1</sup> has provided clinicians with good guidance on how to further investigate so as to appropriately manage this group of patients.

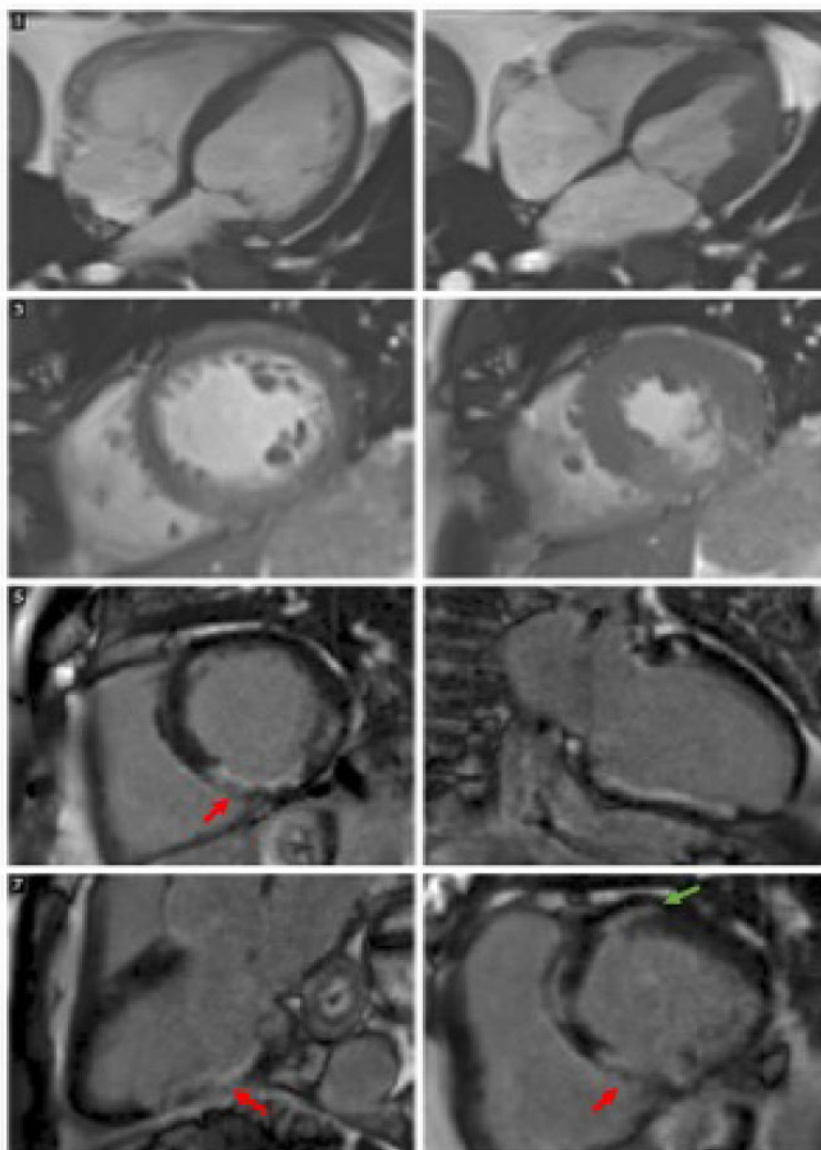
## Timeline

First presentation December 2013	<ul style="list-style-type: none"> <li>• Admission with chest pain, normal ECG with troponin rise treated as non-ST-segment elevation myocardial infarction</li> <li>• Coronary angiogram showing no obstructive lesion but tendency to severe coronary spasm</li> <li>• Outpatient cardiac magnetic resonance (CMR) showed subendocardial infarction in inferoseptal and anteroseptal areas</li> <li>• Treated as coronary artery vasospasm</li> </ul>
2 years later November 2015– November 2017	<ul style="list-style-type: none"> <li>• Further episodes of chest pain and raised troponin</li> <li>• Repeat CMR (prior to clinic) showed extension of subendocardial infarction</li> <li>• CT coronary angiogram (CTCA) showed no obstructive coronary disease</li> <li>• Significant eosinophilia noted with raised C-reactive protein (CRP)</li> <li>• Referral to rheumatology</li> </ul>
2 months later January 2018	<ul style="list-style-type: none"> <li>• Churg–Strauss syndrome diagnosed clinically</li> <li>• Started on immunosuppression with steroids</li> </ul>
9 months later October 2018	<ul style="list-style-type: none"> <li>• Reduced requirement for glyceryl trinitrate (GTN) spray</li> <li>• Troponin and eosinophil levels returned to normal</li> <li>• Symptom free since start of treatment</li> </ul>

## Case presentation

A 70-year-old male patient with a previous history of multiple sclerosis, previously successfully resected colon cancer 10 years earlier and late-onset asthma (age of 62 years) presented with retrosternal chest pain, small troponin rise, and without ECG changes. Physical examination revealed no abnormalities of the cardiovascular and respiratory system. Echocardiography showed normal left ventricular function with no regional wall motion abnormality and no valvular disease. A diagnosis of non-ST elevation myocardial infarction was made, and diagnostic coronary angiography showed a smooth stenosis in the right coronary artery (RCA) and unobstructed left coronary artery ([Supplementary material online, Videos S1 and S2](#)). He was listed for angioplasty to the RCA but upon reimaging, the RCA looked smooth and unobstructed. However, the mid-circumflex artery now had a smooth stenosis which resolved with administration of intracoronary isosorbide dinitrate ([Supplementary material online, Videos S3 and S4](#)). A diagnosis of coronary artery spasm was made, and the patient was treated with aspirin and he was started on oral isosorbide mononitrate. A month later he was admitted with anterior ST-segment elevation which completely resolved with administration of sublingual glyceryl trinitrate in the emergency room. The chest pains continued intermittently at rest and diltiazem and nicorandil were added in stepwise fashion to try and settle ongoing symptoms. Cardiac magnetic resonance (CMR) imaging revealed small areas of myocardial infarction in both the RCA and the LAD territories. Due to concern over possible ongoing infarction due to spasm, clopidogrel 75 mg o.d. was added and continued long-term. Over the next 18 months, the patient remained stable, with minimal symptoms and no changes on serial CMR scans at 6 monthly intervals. He was continued on maximal antianginal therapy, dual antiplatelet therapy, and advised to avoid beta-blockers and phosphodiesterase 5 inhibitors.

He subsequently represented with further episodes of atypical chest pain at rest, unresponsive to glyceryl trinitrate (GTN) and



**Figure 1** Cardiac magnetic resonance imaging showing late gadolinium enhancement in basal to apical inferior/inferoseptal wall (red arrow) and basal anterior wall (green arrow).

associated marked troponin rise (troponin I  $> 400$  ng/L [normal range  $< 16$  ng/L]), that fluctuated over a couple of months with no correlation with symptoms or any ECG changes. Full blood count was normal apart from raised eosinophils ( $4.3 \times 10^9/L$  [normal range  $0.02$ – $0.5 \times 10^9/L$ ]) with normal renal and liver function tests. Erythrocyte sedimentation rate (ESR) was normal ( $< 5$  mm/h) and C-reactive protein (CRP) 5.7 mg/L. Over the next few weeks, CRP rose to 28 and troponin fluctuated, albeit markedly elevated, with no correlation with symptoms. Coronary anatomy was revisited with a CT coronary angiography which showed a calcium score of 202 with no obstructive lesions.

Repeat CMR (Figure 1) revealed normal right and left ventricular volumes and function. In the late gadolinium phase, there were two

separate regions of infarction. There was infarction in the inferior/inferoseptal wall from the basal to apical level. This was predominantly transmural ( $> 50\%$ ) in the inferior and inferoseptal wall at the basal to mid-level. There was some new extension into the basal inferolateral wall not seen on the previous scan that was also transmural. Separately, there was localized infarction ( $> 50\%$  transmural) in the basal anterior wall.

Given the presence of eosinophilia, recurrent episodic myocardial infarction and the lack of correlation between the extent of epicardial coronary disease and CMR findings, combined with the suspicious history of late-onset asthma, a diagnosis of Churg–Strauss syndrome was postulated. The patient was treated with prednisolone 30 mg o.d. and azathioprine 50 mg t.d.s. Following immunosuppressive

therapy, the chest pains resolved with corresponding normalization of eosinophil and troponin levels. antineutrophil cytoplasmic antibody (ANCA) levels checked in the non-acute phase was normal with myeloperoxidase (MPO) <0.3 (normal range < 3.5 IU/mL) and PR3 < 0.7 (normal range < 2.0 IU/mL). Nine months after treatment began, his medication has been gradually weaned to prednisolone 5 mg o.d. and azathioprine 50 mg o.d. with a plan for slow ongoing tapering of both.

## Discussion

The vast majority of patients presenting with myocardial infarction have underlying coronary artery disease. Myocardial infarction with non-obstructive coronary arteries is a new nomenclature devised for an often-overlooked group of patients, namely those with myocardial infarction despite the absence of significant obstructive coronary disease. The European Society of Cardiology Working Group Position Paper on Myocardial Infarction with Non-obstructive Coronary Arteries<sup>1</sup> has highlighted that this is a very heterogeneous group of patients with varied pathomechanism of myocardial infarction, although some 33% are reportedly attributed to myocarditis.<sup>2</sup> Some 25% of patients with MINOCA continue to experience angina 12 months after the index infarction<sup>3</sup> presumably at least in part because of challenges identifying the underlying cause. Making the correct diagnosis is essential, in order to successfully treat the underlying condition and prevent recurrent infarction and loss of myocardium.

In this case, the presence of a constellation of late-onset asthma, eosinophilia, rise in troponin, and inflammatory markers unrelated to symptoms, with recurrent symptoms at rest despite maximal anti-anginal and dual antiplatelet therapy pointed towards a systemic cause which ultimately led to a diagnosis of Churg–Strauss syndrome with cardiac involvement.

Churg–Strauss syndrome, recently renamed eosinophilic granulomatosis with polyangiitis (EGPA) is an autoimmune vasculitis affecting medium to small vessel and should be suspected in patients with a history of atopy or late-onset asthma. Two of the most commonly used classifications include the American College of Rheumatology (ACR)<sup>4</sup> which has developed six diagnostic criteria for Churg–Strauss syndrome which includes asthma, eosinophilia greater than 10% on differential white blood cell (WBC) count, mononeuropathy (including multiplex) or polyneuropathy, non-fixed pulmonary infiltrates on roentgenography, paranasal sinus abnormality, and biopsy containing a blood vessel with extravascular eosinophils and the Lanham criteria<sup>5</sup> which includes asthma, eosinophils > 1500 cells/ $\mu$ L, and systemic vasculitis involving two or more extra-pulmonary organs. In our case, the patient fits two out of the six ACR diagnostic criteria and two out of three of the Lanham criteria. Although neuropathy, pulmonary infiltrates and positive biopsy were not available, these are not strictly required for the diagnosis. The ACR definition paper states that the combination of only two criteria, namely a history of asthma together with eosinophilia >10% on a WBC differential correctly classified 90% of Churg–Strauss syndrome cases and has a sensitivity of 90% and a specificity of 99.7%.<sup>4</sup>

Approximately 60% of patients with Churg–Strauss have cardiac involvement which includes vasculitic lesions in myocardium and coronary vessels.<sup>6</sup> It can result in myocardial infarction, heart failure,

pericarditis, and myocarditis. Presence of cardiac involvement is associated with an increased risk of mortality.<sup>7</sup> There have been a few cases describing coronary vasospasm in the context of Churg–Strauss,<sup>8–10</sup> but its pathophysiology remains unclear. There are probable links between allergic diseases and coronary vasospasm—local inflammatory response inducing arterial wall hyper-reactivity.<sup>11</sup> In our case, given that the absence of correlation between the infarcted areas and coronary anatomy, the cause of his presentation might be due to multiple factors i.e. coronary vasospasm, vasculitis, and even myocarditis.

The mainstay of treatment is immunosuppression with corticosteroids.<sup>12</sup> The use of additional cytotoxic drugs like cyclophosphamide is normally reserved for patients with life or organ threatening disease manifestations which can be used to induce remission with azathioprine or methotrexate being recommended as maintenance therapy.<sup>12</sup>

This case illustrates non-atheromatous cause of myocardial infarction that is rare and challenging to diagnose. It also emphasizes the importance of ongoing tests in patients with unexplained chest pain and troponin rise, to ensure appropriate treatment, to reduce the risk of recurrent infarction, prevent loss of myocardium, and improve prognosis.

## Lead author biography



Dr Ying Gue is a graduate from University of Dundee, Scotland. He completed his medical training in Scotland in 2016 and moved to Stevenage where is currently working as a cardiology research fellow part-time whilst completing his MD research degree in University of Hertfordshire. He is passionate about cardiology and hopes to go on towards training in cardiology as a speciality.

## Supplementary material

**Supplementary material** is available at *European Heart Journal - Case Reports* online.

**Slide sets:** A fully edited slide set detailing this case and suitable for local presentation is available online as [Supplementary data](#).

**Consent:** The author/s confirm that written consent for submission and publication of this case report including image(s) and associated text has been obtained from the patient in line with COPE guidance.

**Conflict of interest:** none declared.

## References

- Agewall S, Beltrame JF, Reynolds HR, Niessner A, Rosano G, Caforio AL, De Caterina R, Zimarino M, Roffi M, Kjeldsen K, Atar D, Kaski JC, Sechtem U, Tornvall P; WG on Cardiovascular Pharmacotherapy. ESC working group position paper on myocardial infarction with non-obstructive coronary arteries. *Eur Heart J* 2016;**38**:143–153.
- Tornvall P, Gerbaud E, Behaghel A, Chopard R, Collste O, Laraudogoitia E, Leurent G, Meneveau N, Montaudon M, Perez-David E, Sörensson P, Agewall S. Myocarditis or “true” infarction by cardiac magnetic resonance in patients with a clinical diagnosis of myocardial infarction without obstructive coronary disease: a meta-analysis of individual patient data. *Atherosclerosis* 2015;**241**:87–91.

3. Grodzinsky A, Arnold SV, Gosch K, Spertus JA, Foody JM, Beltrame J, Maddox TM, Parashar S, Kosiborod M. Angina frequency after acute myocardial infarction in patients without obstructive coronary artery disease. *Eur Heart J Qual Care Clin Outcomes* 2015;**1**:92–99.
4. Masi AT, Hunder GG, Lie JT, Michel BA, Bloch DA, Arend WP, Calabrese LH, Edworthy SM, Fauci AS, Leavitt RY. The American College of Rheumatology 1990 criteria for the classification of Churg-Strauss syndrome (allergic granulomatosis and angiitis). *Arthritis Rheum* 1990;**33**:1094–1100.
5. Lanham JG, Elkon KB, Pusey CD, Hughes GR. Systemic vasculitis with asthma and eosinophilia: a clinical approach to the Churg-Strauss syndrome. *Medicine (Baltimore)* 1984;**63**:65–81.
6. Dennert RM, van Paassen P, Schalla S, Kuznetsova T, Alzand BS, Staessen JA, Velthuis S, Crijns HJ, Tervaert JW, Heymans S. Cardiac involvement in Churg-Strauss syndrome. *Arthritis Rheum* 2010;**62**:627–634.
7. Mukhtyar C, Flossmann O, Hellmich B, Bacon P, Cid M, Cohen-Tervaert JW, Gross WL, Guillevin L, Jayne D, Mahr A, Merkel PA, Raspe H, Scott D, Witter J, Yazici H, Luqmani RA. Outcomes from studies of antineutrophil cytoplasm antibody associated vasculitis: a systematic review by the European League Against Rheumatism systemic vasculitis task force. *Ann Rheum Dis* 2008;**67**:1004–1010.
8. Fatima ZR, Hara L, Ouazzani AE, Berroho O, Doghmi N, Zarzur J, et al. Rare manifestation of Churg-Strauss syndrome: coronary artery vasospasm complicated by myocardial infarction. *Int Arch Med* 2016;**9**: doi: 10.3823/2248.
9. Benallegue N, Lozach P, Belizna C, Lavigne C, Urbanski G. Acute coronary vasospasm in a patient with eosinophilic granulomatosis with polyangiitis following NSAID administration: a case report. *Medicine (Baltimore)* 2016;**95**: e5259.
10. Trivedi S, Suan D, Tanous D. Coronary artery vasospasm in a patient with probable Churg-Strauss syndrome. *Heart Lung Circ* 2017;**26**:S293.
11. Takagi S, Goto Y, Hirose E, Terashima M, Sakuragi S, Suzuki S, Tsutsumi Y, Miyazaki S, Nonogi H. Successful treatment of refractory vasospastic angina with corticosteroids. *Circ J* 2004;**68**:17–22.
12. Groh M, Pagnoux C, Baldini C, Bel E, Bottero P, Cottin V, Dalhoff K, Dunogué B, Gross W, Holle J, Humbert M, Jayne D, Jennette JC, Lazor R, Mahr A, Merkel PA, Mouthon L, Sinico RA, Specks U, Vaglio A, Wechsler ME, Cordier J-F, Guillevin L. Eosinophilic granulomatosis with polyangiitis (Churg–Strauss) (EGPA) Consensus Task Force recommendations for evaluation and management. *Eur J Intern Med* 2015;**26**:545–553.