

Teaching Point
(Section Editor: A. Meyrier)

Oxaliplatin-induced acute renal failure presenting clinically as thrombotic microangiopathy: think of acute tubular necrosis

Nga Thuy Phan¹, Anne Elisabeth Heng¹, Alexandre Lautrette^{1,2}, Jean Louis Kémény^{2,3} and Bertrand Souweine^{1,2}

¹CHU Clermont-Ferrand, Hôpital Gabriel Montpied, Service de Néphrologie Réanimation Médicale, Pole REUNNIRH, Clermont-Ferrand, F-63003, France, ²Univ Clermont 1, UFR Médecine, Clermont-Ferrand, F-63001 and ³CHU Clermont-Ferrand, Hôpital Gabriel Montpied, Service de Pathologie Médicale, Clermont-Ferrand, F-63003, France

Keywords: acute renal failure; acute tubular necrosis; microangiopathy; oxaliplatin; thrombocytopenia

Introduction

Oxaliplatin (OXP) has been implicated in isolated cases of immune cytopenia [1–5] and in two reports of acute tubular necrosis (ATN) [6,7]. We describe an original observation of OXP-induced ATN mimicking thrombotic microangiopathy (TMA).

Case

A 65-year-old male with advanced colorectal cancer treated by sigmoidectomy and FOLFOX 6 regimen was admitted to the ICU after five cycles because of anuric acute renal failure (ARF) and thrombocytopenia (Table 1). Chemotherapy consisted in a combination of OXP, 5-fluorouracil (5-FU) and folinic acid. He had received a total dosage of 470 mg of OXP when shortly after the last infusion he complained of intense lower back pain and developed oliguria with dark urine. On ICU admission, physical examination was unremarkable. Renal ultrasonography findings including Doppler assessment of artery flow were normal. Bone-marrow aspiration finding was consistent with peripheral thrombocytopenia. Because of hyperkalaemia, emergency intermittent haemodialysis was started.

A direct anti-globulin test was negative (eluate assay was not performed). There were no anti-HLA antibodies. Low levels of circulating platelet antibodies were observed, but detection of OXP-dependent anti-platelet antibodies was not performed. Blood cultures were sterile.

Correspondence and offprint requests to: Bertrand Souweine, CHU Clermont-Ferrand, Service de Néphrologie Réanimation Médicale, Pole REUNNIRH, Clermont-Ferrand, F-63003, France. Tel: +334-7375-1425; Fax: +334-7375-1183; E-mail: bsouweine@chu-clermontferrand.fr

Table 1. Results of laboratory tests

Variable	17 December ^a	21 December ^b	8 February ^c
Haemoglobin (g/dl)	14.2	10.7	10.4
WBC ($\times 10^3$ cells/l)	3.8	2.9	4.2
Platelet count ($\times 10^3$ cells/l)	122	24	159
APTT ratio patient/control	1.03	0.94	ND
PT (%)	100	88	ND
Fibrinogen (g/l)	3.5	4.1	ND
Schizocytosis (%)	ND	<1	ND
Serum creatinine (μ mol/l)	68	1078	120
Serum urea (mmol/l)	5	43	6
Serum potassium (mmol/l)	4.4	6.3	4.5
LDH (IU/l)	ND	882	ND
Bilirubin, total	ND	7	8
Haptoglobin ^d (g/l)	ND	0.6	ND

^aBefore the fifth cycle.

^bOn ICU admission.

^cOn hospital discharge.

^dMeasured after the first dialysis session.

APTT, activated partial thromboplastin time; LDH, lactate dehydrogenase; ND, not done; PT, prothrombin time; WBC, white blood-cell count.

Serological tests for HIV, cytomegalovirus, hepatitis B, hepatitis C and parvovirus B19 infection were negative. A low level of serum monoclonal immunoglobulin G was transiently detected. Anti-nuclear antibodies, rheumatoid factor, neutrophil polynuclear anti-cytoplasmic antibodies, anti-cardiolipin antibodies, anti-beta2-glycoprotein I antibodies, anti-glomerular basement membrane antibodies and cryoglobulinaemia were negative. The serum levels of Willebrand factor-cleaving protease (ADAMTS13) and of complement components, including C3C, C4, factor H and factor I, were normal.

A percutaneous renal biopsy was carried out 7 days after ICU admission. To prevent haemorrhagic complications, platelet transfusion was performed. The renal biopsy showed a desquamation of individual tubular epithelial cells with denudation of tubular basement membranes and mild cellular infiltration in the interstitium. No glomerular capillary thrombosis was observed (Figures 1 and 2). Perl's

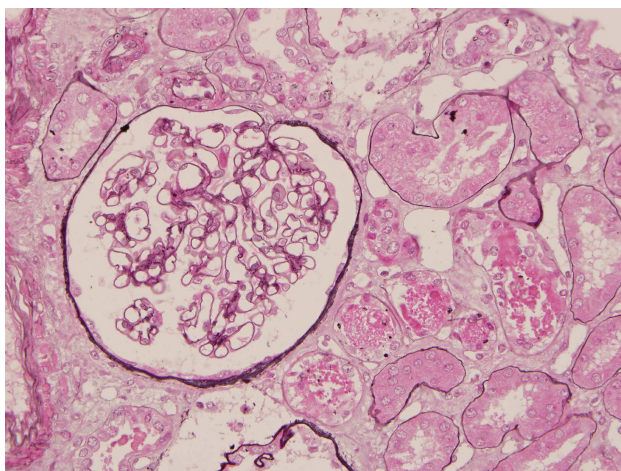


Fig. 1. Renal biopsy showing a normal glomerulus and lesions of acute tubular necrosis (silver stain $\times 40$).

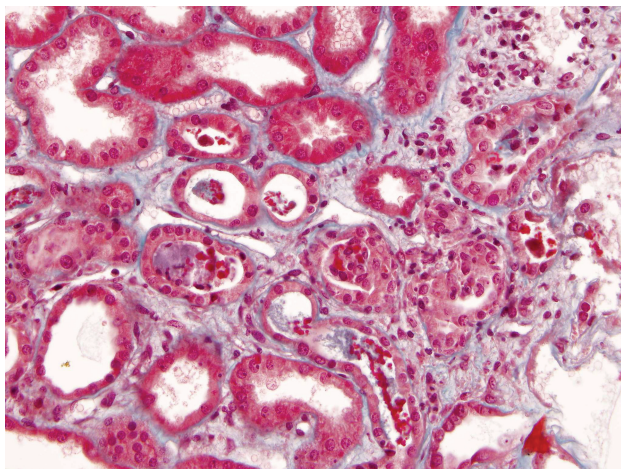


Fig. 2. Acute tubular necrosis (trichrome $\times 40$).

staining yielded no evidence of haemosiderin pigment in renal sections. Immunofluorescence analysis showed no specific deposits.

The patient recovered from ARF after nine haemodialysis sessions. He was subsequently treated with 5-FU, leucovorin and irinotecan without recurrence of thrombocytopenia or ARF.

Discussion

OXP was partly developed to overcome cisplatin nephrotoxicity. The pharmacokinetics of OXP, in contrast to that of cisplatin, is characterized by low-plasma accumulation and renal elimination via simple glomerular filtration out tubular metabolism [8]. OXP storage in erythrocytes could play a critical role in OXP-induced anaemia. In the previous reported cases of OXP-induced ATN, ARF developed after higher doses of OXP (850 and 1150 mg/m²) [6,7].

In our patient, the time course of ARF after chemotherapy without signs of sepsis, dehydration and with no exposure to other nephrotoxic agents suggests that ARF resulted from

OXP infusion. 5-FU is unlikely to be involved in the development of ARF since it is not nephrotoxic and because ARF did not recur after re-administration. In the previous observations of OXP-induced ATN, ARF was associated with macroscopic haematuria in one case [6] and with thrombocytopenia in the other [7]. In our patient, acute onset of back pain, dark urine, oliguria, elevated lacticodeshydrogenase (LDH) and low haptoglobin and the presence of fragmented red blood cells (schizocytes) in peripheral smear analysis prompted the diagnosis of haemolysis, which because of the haemoglobin level was probably only mild. The absence of haemosiderin deposit on renal histology strongly suggests that haemolysis did not directly contribute to ARF. In our patient, immune thrombocytopenia was evidenced by the presence of circulating anti-platelet antibodies.

A recent report described a case of TMA attributed to OXP [9]. However, the authors did not perform renal histology and their diagnosis therefore remains speculative. They excluded the possibility of immune cytopenia but did not perform the detection of OXP-dependent antibodies against erythrocyte and platelets. In our patient, although the combination of haemolysis, peripheral thrombocytopenia and ARF suggested TMA, the diagnosis was ruled out on the basis of renal histology.

OXP-induced ARF due to ATN can develop in combination with haematologic abnormalities. This may lead to the mistaken diagnosis of TMA and subsequent inappropriate plasma transfusion [9].

Teaching points

- (i) ARF occurs rarely during OXP treatment and, while potentially severe, is in theory reversible.
- (ii) OXP treatment can lead to haematological abnormalities (leukopenia, thrombocytopenia and haemolysis), sometimes immunologically mediated.
- (iii) After OXP treatment, haematological abnormalities may occur during ARF and mimic TMA. Physicians should be aware of this possibility, since in addition to the supportive therapy of ARF, the treatment of acute episodes of TMA requires plasma exchanges with plasma transfusion, which are not appropriate in cases of organoplatin-induced ATN.
- (iv) When the clinical picture of ARF is atypical, a renal biopsy should be performed to evidence histological lesions. Histological findings can suggest the mechanism or even the aetiology of the disorder. They would also make it possible to establish prognosis and, in most cases, to decide on therapeutic management.

Acknowledgements. The authors thank Jeffrey Watts for his help in preparing the manuscript.

Conflict of interest statement. None declared.

References

1. Desrame J, Broustet H, Darodes de Tailly P *et al.* Oxaliplatin-induced haemolytic anaemia. *Lancet* 1999; 354: 1179–1180

2. Earle CC, Chen WY, Ryan DP *et al.* Oxaliplatin-induced Evan's syndrome. *Br J Cancer* 2001; 84: 441
3. Sørbye H, Bruserud Y, Dahl O. Oxaliplatin-induced haematological emergency with an immediate severe thrombocytopenia and haemolysis. *Acta Oncol* 2001; 40: 882–883
4. Chen VM, Thrift KM, Morel-Kopp MC *et al.* An immediate hemolytic reaction induced by repeated administration of oxaliplatin. *Transfusion* 2004; 44: 838–843
5. Curtis BR, Kaliszewski J, Marques MB *et al.* Immune-mediated thrombocytopenia resulting from sensitivity to oxaliplatin. *Am J Hematol* 2006; 81: 193–198
6. Pinotti G, Martinelli B. A case of acute tubular necrosis due to oxaliplatin. *Ann Oncol* 2002; 13: 1951–1952
7. Labaye J, Sarret D, Duvic C *et al.* Renal toxicity of oxaliplatin. *Nephrol Dial Transplant* 2005; 20: 1275–1276
8. Launay-Vacher V, Rey JB, Isnard-Bagnis C *et al.* European Society of Clinical Pharmacy Special Interest Group on Cancer Care. Prevention of cisplatin nephrotoxicity: state of the art and recommendations from the European Society of Clinical Pharmacy Special Interest Group on Cancer Care. *Cancer Chemother Pharmacol* 2008; 61: 903–909
9. Dahabreh I, Tsoutsos G, Tseligas D *et al.* Hemolytic uremic syndrome following the infusion of oxaliplatin: case report. *BMC Clin Pharmacol* 2006; 6: 5

Received for publication: 18.11.08; Accepted in revised form: 7.1.09