



Minimally invasive endoscopic management of buried bumper syndrome by use of a novel dedicated resection device

Deborah Costa, MD, Edward J. Despott, MD, FRCP, FEBGH, FASGE, Nikolaos Lazaridis, MD, PhD, Nikolaos Koukias, MD, Alberto Murino, MD

Buried bumper syndrome (BBS) is an uncommon adverse event of PEG placement; its incidence is 1%.^{1,2} Several techniques for endoscopic management of BBS have been described, given the absence of a dedicated device to date.^{3,4}

A 94-year-old man was admitted to our emergency department with fever and PEG tube obstruction. A button-type PEG had been placed in June 2014 for enteral feeding in the context of neurologic dysphagia,

secondary to Parkinson disease. In December 2018 the cutaneous side of the PEG tract appeared erythematous and edematous, with seepage of purulent mucus. Any attempt to rotate or mobilize the PEG tube through external manipulation proved futile. A CT scan confirmed findings in keeping with the suspected diagnosis of BBS (Fig. 1).

At upper-GI endoscopy, a 4-cm elevated area of granulatous tissue with a central depression was identified,

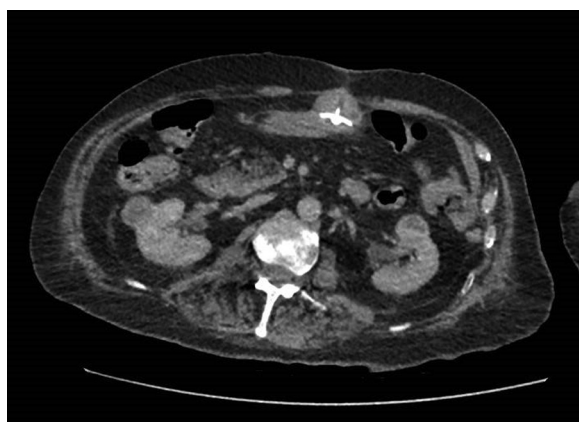


Figure 1. Buried bumper at CT.

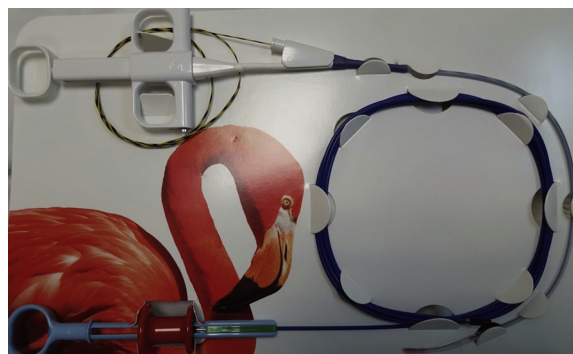

Figure 3. The Flamingo set containing the Flamingo device, a 35-gauge guidewire (6/10 mm), and a foreign body removal forceps.

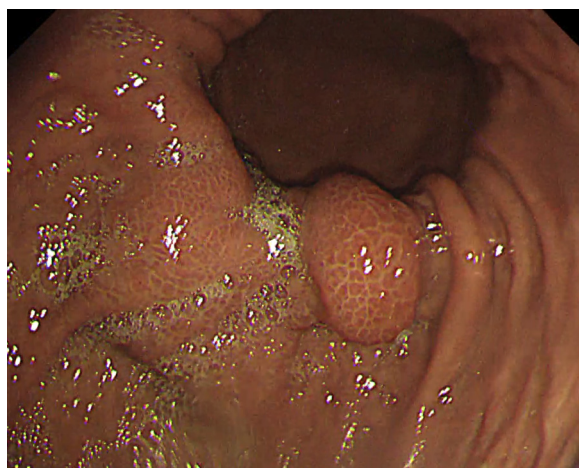

Figure 2. Buried bumper appearance at EGD, located in the proximal anterior wall of the gastric antrum.

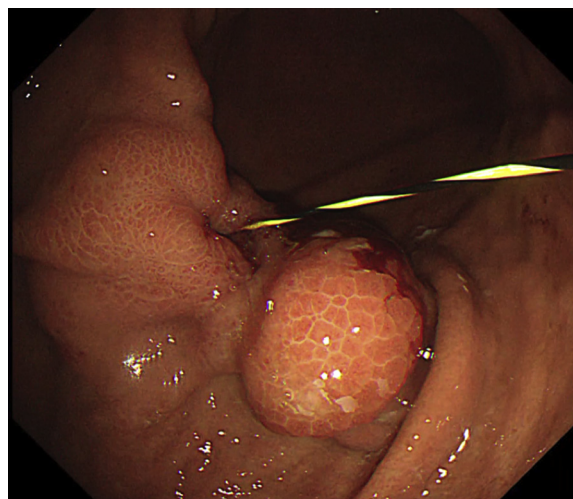


Figure 4. Intragastric passage of a 35-gauge guidewire, pushed through the cutaneous aspect of the PEG tract.

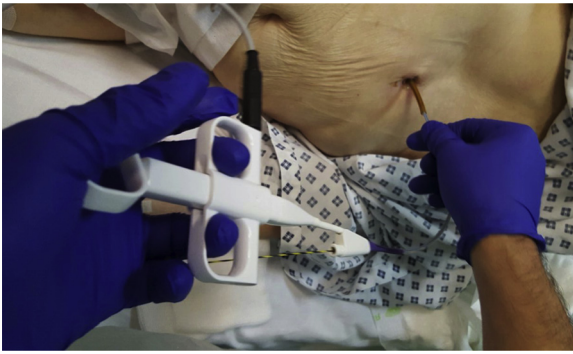

Figure 5. External manipulation of the Flamingo device. The assistant externally controls the Flamingo device with 2 hands. One hand regulates the flexion of the cutting wire through the handle, and the other hand manipulates the shield of the Flamingo device regulating the push-and-pull movements and the rotation movements.

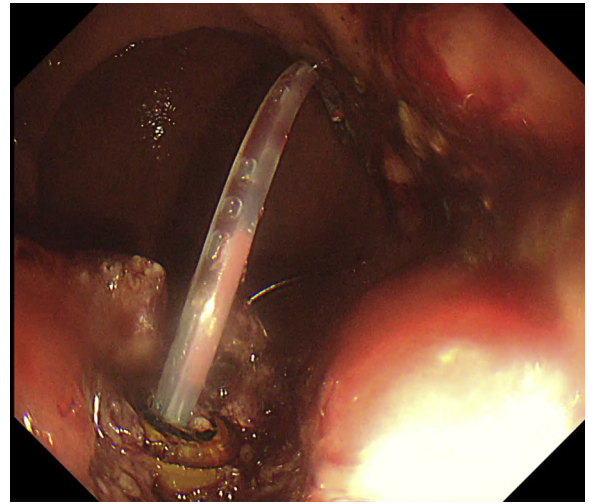


Figure 7. Initial exposure of the PEG plastic bumper.

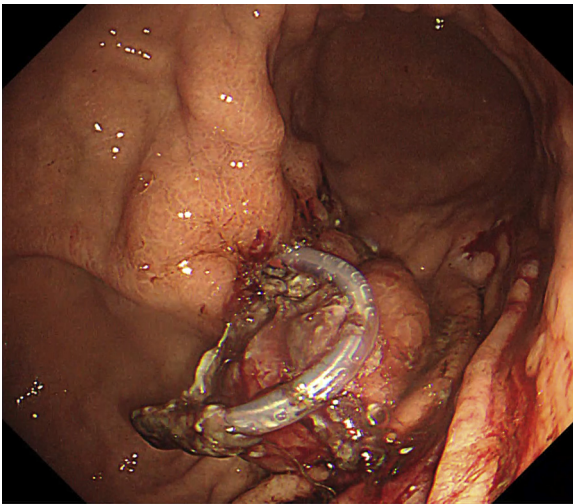


Figure 6. Flamingo device with its cutting wire, flexed by 180°.

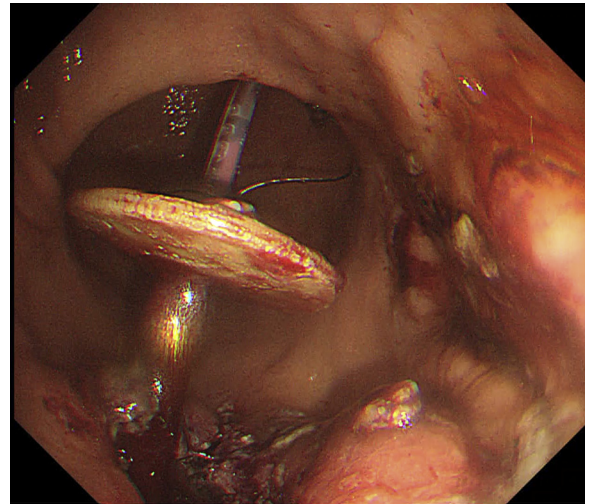


Figure 8. Release of the PEG bumper into the gastric lumen.

confirming BBS (Fig. 2). This was located on the proximal anterior wall of the gastric antrum.

A novel, sphincterotome-like, single-use, dedicated device, designed for radial incision of BBS-related intragastric granulomatous tissue (Flamingo Set; Medwork, Höchststadt, Germany) was then applied. The Flamingo set contains the Flamingo device, which is 30 cm long; a 35-gauge guidewire (6/10 mm) and foreign body removal forceps (Fig. 3).

A 35-gauge guidewire was inserted through the PEG tube, but despite multiple attempts, it was not possible to advance it through the granulomatous tissue covering the buried bumper. A 2.5-mm ball-tipped needle-type knife (Flush knife BT; Fujifilm, Tokyo, Japan) was, therefore, used to incise the granulomatous tissue. The guidewire was subsequently pushed manually through the PEG and successfully advanced in the gastric lumen (Fig. 4).

The Flamingo was inserted over the guidewire into the stomach, through the external aspect of the partially cut PEG tube, by use of a Seldinger technique. The guidewire was subsequently withdrawn, and the distal part of the Flamingo device was flexed to 180° by an assistant using its dedicated handle (Fig. 5), exposing the bowstring, sphincterotome-like cutting wire (Fig. 6). External traction by the assistant was then applied to the Flamingo device from the cutaneous side of the PEG tract, pulling the flexed cutting wire toward the granulomatous tissue through direct endoscopic visualization, until apposition was achieved. The overgrown tissue was then incised with Endocut-Q diathermy current (Erbe VIO200D; Erbe Elektromedizin, Tübingen, Germany) according to the

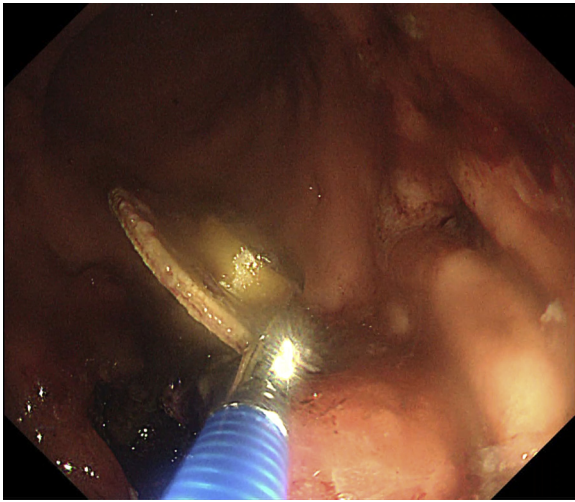


Figure 9. Remnant PEG tube and bumper retrieved by use of grasping forceps.

manufacturer's recommendations (Endocut-Q effect 3, cut duration 2, cut interval 5). After the first incision, the device was manually pushed away from the granulomatous tissue and slightly rotated with gentle external manipulation, and a second incision was then performed. This sequence was replicated several times to achieve a stellate incision until the plastic bumper was exposed (Fig. 7). The PEG bumper and remnant of the externally cut PEG tube were then released into the gastric lumen through external manipulation (Fig. 8) and endoscopically retrieved using a grasping forceps (Fig. 9). As a precautionary measure, the excision site was partially closed by deployment of through-the-scope endoclips (Resolution Clip; Boston Scientific, Mass, USA). The whole procedure was performed with the patient under conscious sedation (with midazolam and fentanyl) and broad-spectrum, intravenous antibiotic cover; no immediate, early, or late adverse events were encountered. A new PEG insertion for recommencement of enteral feeding was successfully and safely achieved at an alternative site 2 weeks later.

Through our preliminary experience and that of Hindryckx et al,⁵ this novel, dedicated device appears to be user-friendly, safe, quick, and effective for minimally invasive endoscopic management of BBS and warrants further study (Video 1, available online at www.VideoGIE.org).

DISCLOSURE

Dr Despott receives research support from Aquilant Medical and Fujifilm and education support from Olympus and Pentax Medical. Dr Murino receives research support from Aquilant Medical and Fujifilm and education support from Olympus and Pentax Medical.

All other authors disclosed no financial relationships relevant to this publication.

Abbreviation: BBS, buried bumper syndrome.

REFERENCES

1. Cyran J, Rejchrt S, Kopacova M, et al. Buried bumper syndrome: a complication of percutaneous endoscopic gastrostomy. *World J Gastroenterol* 2016;22:618-27.
2. Blumenstein I, Shastri YM, Stein J. Gastroenteric tube feeding: techniques, problems and solutions. *World J Gastroenterol* 2014;20:8505-24.
3. Mueller-Gerbes D, Hartmann B, Lima JP, et al. Comparison of removal techniques in the management of buried bumper syndrome: a retrospective cohort study of 82 patients. *Endosc Int Open* 2017;5:E603-7.
4. Cyran J, Repak R, Douda T, et al. Cannulotome introduced via a percutaneous endoscopic gastrostomy (PEG) tube: new technique for release of a buried bumper. *Endoscopy* 2012;44:E422-3.
5. Hindryckx P, Dhoghe B, Wannhoff A. A novel device for the endoscopic management of buried bumper syndrome. *Endoscopy* 2019;51:689-93.

Royal Free Unit for Endoscopy, The Royal Free Hospital and University College London Institute for Liver and Digestive Health, Hampstead, London, UK.

Copyright © 2019 American Society for Gastrointestinal Endoscopy. Published by Elsevier Inc. This is an open access article under the CC BY-NC-ND license (<http://creativecommons.org/licenses/by-nc-nd/4.0/>).

<https://doi.org/10.1016/j.vgie.2019.04.007>