

Anagen Effluvium: A Trichoscopic Analysis

Dear Sir,

A 21-year-old woman presented with rapidly progressive non-segmental vitiligo and was started on NBUVB and azathioprine 2 mg/kg/day. One week later, she complained of sudden onset excessive hair loss associated with marked weakness. On examination, there was diffuse non-scarring alopecia over the scalp, more prominent over the vertex and frontal region [Figure 1a]. Hair pull test was positive and hair microscopy showed multiple telogen hair [Figure 1b]. Trichoscopy of the vertex region with DermLite™ DL4 (3 Gen, San Juan Capistrano, CA, USA) showed coudability hair/Pohl-Pinkus constrictions, black dots, exclamation hair, multiple hair shaft residues, and regrowing hair [Figure 1c]. This hair loss was accompanied by severe myelosuppression with a reduction in hemoglobin from 12.5 g/dl to 9 g/dl and total leucocytes count from 5760 cells/ μ l to 1140 cells/ μ l. A diagnosis of azathioprine-induced anagen effluvium was made and azathioprine was discontinued with slow spontaneous improvement in blood count and hair loss. Complete regrowth of hair was seen at 3-month follow-up visit [Figure 1d].

Anagen effluvium is the abrupt loss of anagen hair due to impaired mitotic activity of the hair follicle, commonly caused by chemotherapeutic agents and other causes like radiation or toxin exposure. As most hair follicles are in the anagen phase at a given time, it clinically manifests as diffuse alopecia of sudden onset.

Azathioprine is an anti-metabolite that interferes with cellular DNA synthesis which is used as an immunosuppressive in various autoimmune disorders. There is limited published literature on trichoscopic

findings in azathioprine-induced anagen effluvium. Proximal hair shaft tapering (exclamation hair) and acute constrictions corresponding to the successive courses of chemotherapy have been described.^[1] In chemotherapy-induced anagen effluvium, tapering hair result from the effect of cytotoxic drugs leading to apoptosis, a progressive decreased cellular output from the hair matrix, and the premature entry of the follicle into telogen.^[2] Black dots are indicative of sudden cessation of mitotic activity of the hair shaft, resulting in focal thinning of hair shaft and breakage at the thinned point. Thinning of hair at proximal end is seen, known as Pohl-Pinkus constriction and coudability hair. Pigtail hair are the multiple regrowing hair. Hair pull test in the late stages of the disease shows exclusively the spared telogen hair.^[3] Azathioprine-induced anagen effluvium has been considered to be an early marker of its myelotoxicity.^[4]

Trichoscopic findings represent the ways in which hair follicle unit responds to the initial insult leading to alopecia and are not just disease specific.^[5] For example, exclamation hair, black dots, coudability hair, and regrowing pigtail hair are believed to be pathognomonic for alopecia areata but there is enough evidence to suggest that these findings are seen in other diseases as well. The history of sudden onset alopecia after intake of azathioprine provides clue to diagnosis, emphasizing the importance of interpretation of trichoscopic findings based on the underlying pathomechanism resulting in hair loss. In contrast, female pattered hair loss wherein there is follicular miniaturization in a patterned distribution shows features including hair shaft diameter variability, yellow dots, single hair containing hair follicular

**Savera Gupta,
Sujay Khandpur,
Neetu Bhari**

Department of Dermatology and Venereology, All India Institute of Medical Sciences, New Delhi, India

Address for correspondence:

*Dr. Neetu Bhari,
Dermatology and Venereology,
All India Institute of Medical
Sciences, New Delhi - 110 029,
India.*

E-mail: drntbhari@gmail.com

Access this article online

Website: www.idoj.in

DOI: 10.4103/idoj.IDOJ_18_20

Quick Response Code:



How to cite this article: Gupta S, Khandpur S, Bhari N. Anagen effluvium: A trichoscopic analysis. *Indian Dermatol Online J* 2021;12:786-7.

Received: 10-Mar-2020. **Revised:** 20-Mar-2020.
Accepted: 17-Apr-2020. **Published:** 19-Sep-2020.

This is an open access journal, and articles are distributed under the terms of the Creative Commons Attribution-NonCommercial-ShareAlike 4.0 License, which allows others to remix, tweak, and build upon the work non-commercially, as long as appropriate credit is given and the new creations are licensed under the identical terms.

For reprints contact: WKHLRPMedknow_reprints@wolterskluwer.com

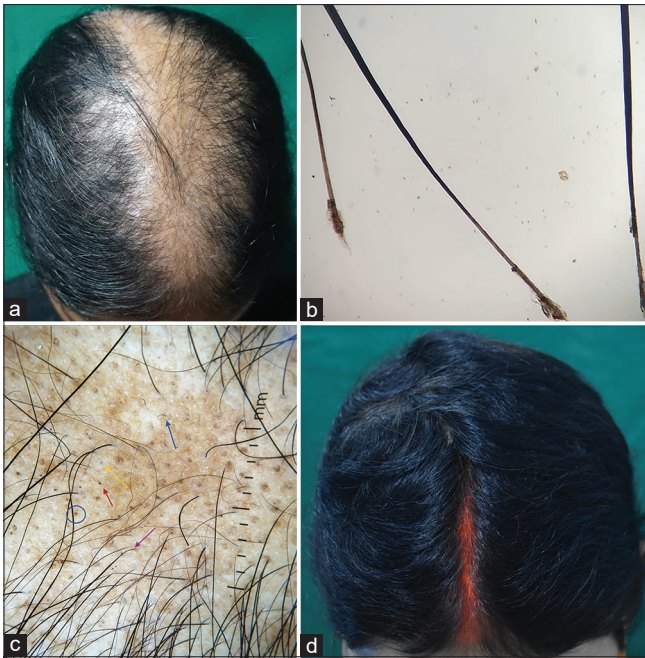


Figure 1: (a) Diffuse non-cicatricial alopecia involving the middle one-third of scalp, extending from the frontal region to the vertex. (b) Hair microscopy (40x) showing telogen hair roots. (c) Trichoscopy (10x, polarized mode) showing thinning of hair at proximal end known as Pohl-Pinkus constriction, coudability hair (pink arrow) with broken hair shafts at thinned point (red arrow, black dot) (exclamation mark hair, yellow arrow), multiple hair shaft residue (blue circle) and regrowing hair (blue arrow, pigtail appearance). (d) Complete regrowth of hair seen at 3-months follow-up

unit, and peripilar sign. Thus, trichoscopic findings may help in early diagnosis of anagen effluvium in the given context which may also serve as an early indicator of myelotoxicity of azathioprine.

Declaration of patient consent

The authors certify that they have obtained all appropriate patient consent forms. In the form the patient(s) has/have given his/her/their consent for his/her/their images and other clinical information to be reported in the journal. The patients understand that their names and initials will not be published and due efforts will be made to conceal their identity, but anonymity cannot be guaranteed.

Financial support and sponsorship

Nil.

Conflicts of interest

There are no conflicts of interest.

References

1. Crouse RG, Van Scott EJ. Changes in scalp hair roots as a measure of toxicity from cancer chemotherapeutic drugs. *J Invest Dermatol* 1960;35:83-9.
2. Bleiker TO, Nicolaou N, Traulsen J, Hutchinson PE. 'Atrophic telogen effluvium' from cytotoxic drugs and a randomized controlled trial to investigate the possible protective effect of pretreatment with a topical vitamin D3 analogue in humans. *Br J Dermatol* 2005;153:103-12.
3. Sperling LC. Evaluation of hair loss. *Curr Probl Dermatol* 1996;8:97.
4. Bhokare AB. Azathioprine-induced alopecia as an early clinical marker of its myelotoxicity. *Indian J Drugs Dermatol* 2017;3:40-1.
5. Pirmez R, Tosti A. Trichoscopy tips. *Dermatol Clin* 2018;36:413-20.