

Return to Play After Open Calcaneoplasty for Insertional Achilles Tendinopathy With Haglund Deformity in Competitive Professional Athletes

Kyung Tai Lee,* MD, PhD, Jegal Hyuk,[†] MD, and Sung Jae Kim,^{‡§} MD, PhD

Investigation performed at Hallym University Dongtan Sacred Heart Hospital, Gyeonggi, Republic of Korea

Background: Surgical treatment of insertional Achilles tendinopathy with Haglund deformity in highly competitive professional athletes has not been previously investigated.

Purpose: To assess clinical outcomes, including return to play (RTP), after surgical treatment of insertional Achilles tendinopathy in professional athletes.

Study Design: Case-control study; Level of evidence, 3.

Methods: This retrospective study included 20 professional athletes who were surgically treated for insertional Achilles tendinopathy and had at least 2 years of follow-up. An open longitudinal lateral approach was used for the operation, without violation of the Achilles tendon. Outcome evaluation included American Orthopaedic Foot and Ankle Society (AOFAS) hindfoot score, subjective patient satisfaction, mean time of return to competition (RTC), and rate of RTP. We defined RTC as return to an official match for at least 1 minute and RTP rate as the percentage of patients who were able to participate in at least 2 full seasons. A subgroup analysis was performed to compare the RTP and no-RTP groups.

Results: The AOFAS score improved significantly from preoperatively to the final follow-up (from 65.1 to 88.4; $P < .001$), and 75% of the patients reported good to excellent satisfaction. The mean time of RTC was 7.45 months (range, 4-18 months), and the rate of RTP was 60%. The RTP group had a significantly lower mean body mass index than did the no-RTP group (22.03 vs 23.86, respectively; $P = .005$) and faster mean RTC (5.0 vs 11.1 months, respectively; $P < .001$).

Conclusion: Open calcaneoplasty for surgical treatment of insertional Achilles tendinopathy with Haglund deformity in highly competitive professional athletes should be approached cautiously. Our patients had a 7.5-month recovery period before return to their first official match, and only 60% of the patients returned to their sports activity and participated in at least 2 full seasons. Lower body mass index and a faster RTC after surgery were related to longer functional maintenance.

Keywords: insertional Achilles tendinopathy; Haglund deformity; athletes; open calcaneoplasty; return to play

Insertional Achilles tendinopathy is a common cause of posterior heel pain and can be accompanied by a poster-superior calcaneal bony prominence (Haglund deformity), inflammation of the retrocalcaneal bursa, and pretendinous Achilles bursitis.²² Repetitive attrition between the Achilles tendon and Haglund deformity of the calcaneus results in retrocalcaneal bursitis and attritional tendinopathy of the Achilles tendon.^{12,21,23} Haglund deformity of the calcaneus has been called a “pump bump” because pump-style shoes could cause a painful prominence on the posterior tubercle of the calcaneus.¹⁰

Treatment of insertional Achilles tendinopathy should begin with nonoperative modalities, including nonsteroidal anti-inflammatory medication, activity modification, custom orthosis, shoe modification, eccentric Achilles stretching, and extracorporeal shockwave therapy.^{17,23} Surgical management can be indicated if nonoperative therapy lasting several months is deemed a failure.^{16,17,23} Various operative treatments are available for insertional Achilles tendinopathy, such as open Achilles tendon detachment or central splitting approaches for calcaneal ostectomy, decompressive osteotomy, or retrocalcaneal bursa excision.¹² Open surgery without detachment or splitting of the Achilles tendon and endoscopic approaches have also been introduced.^{1,2,6,8,13,16,19,23}

Previous reports^{1,2,8,10,24} have demonstrated favorable outcomes after the operative treatment of insertional

The Orthopaedic Journal of Sports Medicine, 9(6), 23259671211009820

DOI: 10.1177/23259671211009820

© The Author(s) 2021

This open-access article is published and distributed under the Creative Commons Attribution - NonCommercial - No Derivatives License (<https://creativecommons.org/licenses/by-nc-nd/4.0/>), which permits the noncommercial use, distribution, and reproduction of the article in any medium, provided the original author and source are credited. You may not alter, transform, or build upon this article without the permission of the Author(s). For article reuse guidelines, please visit SAGE's website at <http://www.sagepub.com/journals-permissions>.

Achilles tendinopathy; however, evaluations that focus on the professional athlete's heel have yet to be conducted. Postoperative clinical outcomes should be evaluated differently for professional athletes versus nonathletes. Commonly used orthopaedic foot and ankle performance scores assess patients' performance for only activities of daily living. The time to return to play (RTP) after treatment should be considered in the assessment of athletes' treatment outcomes.^{4,7,11} The purpose of this study was to investigate surgical outcomes including time and rate of RTP after open calcaneoplasty for the treatment of insertional Achilles tendinopathy with Haglund deformity in highly competitive professional athletes. The hypothesis was that most patients would be able to RTP after open calcaneoplasty for insertional Achilles tendinopathy with Haglund deformity.

METHODS

Study Population

The institutional review board of our institute approved this study. All surgical records for professional athletes who underwent treatment of insertional Achilles tendinopathy at the institution of the senior author (K.T.L.) between January 2006 and January 2016 were identified from a database. Professional athletes surgically treated for insertional Achilles tendinopathy with a follow-up period of ≥ 2 years were included. Exclusion criteria were previous surgery on the ipsilateral foot and ankle joint, systemic diseases such as rheumatoid arthritis, ankylosing spondylitis, additional surgical procedures not for insertional Achilles tendinopathy during the index procedure, or follow-up < 2 years. A total of 27 athletes were identified. Of these, 7 patients were excluded: 3 patients had undergone previous surgery on the ipsilateral foot and ankle joint, 1 patient had ankylosing spondylitis, 1 patient underwent a modified Broström procedure for chronic lateral instability during the index procedure, and 2 patients had insufficient follow-up. Thus, 20 patients were included in the current study.

Clinical Evaluation

Outcome assessment was performed using the American Orthopaedic Foot and Ankle Society (AOFAS) hindfoot score evaluated preoperatively and at the last follow-up. In addition, at the final follow-up, patients were asked to provide a subjective satisfaction rating (*excellent*, *good*,

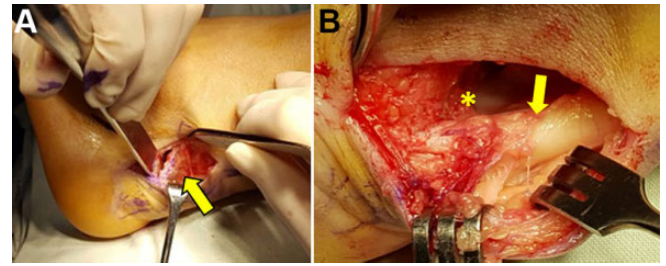


Figure 1. (A) The posterosuperior protuberance (arrow) of the calcaneus was resected using an osteotome. (B) The retrocalcaneal recess (asterisk) between the calcaneus and Achilles tendon (arrow) was decompressed after resection.

fair, or *poor*). Various definitions have been used for RTP in previous research.^{4,9,25} Zellers et al²⁵ noted that most previous studies had defined RTP as a return to preinjury level of sports. Recently, Grassi et al⁹ used the terms “return to competition (RTC)” and “return to previous level of play (RTP)” to evaluate the postoperative outcome for ruptured Achilles tendon. RTC implies measuring how quickly the injured athlete can return to official match play after injury, and RTP implies measuring the longevity of performance after recovery. We defined RTC and RTP as follows:

- RTC: Time (in months) to return to at least 1 minute of official match play postoperatively²⁵
- RTP: Rate of athlete participation in at least 2 full seasons postoperatively^{4,9}

Surgical Technique and Rehabilitation

For surgery, patients were placed in a semilateral position. A 4- to 5-cm curvilinear skin incision was made on the lateral aspect of the calcaneus just anterior to the Achilles tendon, with care taken to avoid sural nerve injury, similar to the technique introduced by Natarajan and Narayanan.¹⁴ The insertion of the Achilles tendon and the prominent posterior calcaneal tubercle were identified. The posterosuperior protuberance of the calcaneus was resected using an osteotome while protecting the Achilles tendon (Figure 1). The resection was performed to the extent that sufficient decompression of the retrocalcaneal recess was achieved with full dorsiflexion of the ankle joint. We also checked for the presence of retrocalcaneal bursitis or degenerative Achilles paratenonitis, and debridement was performed if needed.

[§]Address correspondence to Sung Jae Kim, MD, PhD, Department of Orthopaedic Surgery, Dongtan Sacred Hospital, Hallym University, College of Medicine, Hwaseong, Republic of Korea (email: sung1383@hanmail.net).

*Foot and Ankle Service, KT Lee's Orthopedic Hospital, Seoul, Republic of Korea.

[†]Bonebone Orthopedic Surgery Clinic, Seoul, Republic of Korea.

[‡]Department of Orthopaedic Surgery, Dongtan Sacred Heart Hospital, Hallym University, Hwaseong, Republic of Korea.

Final revision submitted November 24, 2020; accepted January 05, 2021.

One or more of the authors has declared the following potential conflict of interest or source of funding: This work was supported by the Hallym University Academic Research Fund 2020 (HURF-2020-36). AOSSM checks author disclosures against the Open Payments Database (OPD). AOSSM has not conducted an independent investigation on the OPD and disclaims any liability or responsibility relating thereto.

Ethical approval for this study was obtained from Dongtan Sacred Heart Hospital (ref No. 2019-10-016).

We were careful to avoid injury to the Achilles tendon during debridement to avoid a delayed rehabilitation. No patient had intratendinous calcifications that required debridement, and there was no need for partial detachment with reinsertion of the Achilles tendon. A subcutaneous suture was placed, and the skin was closed using a nonabsorbable suture (4-0, Prolene, Ethicon). A drain was inserted using neutral pressure and removed 1 day after surgery. A short leg splint was applied postoperatively, and range of motion exercise was started 2 weeks after surgery to ensure adequate healing of the surgical wound. Patients

were nonweightbearing for the first 3 postoperative weeks. Then, a walking boot orthosis was applied, and participants began a strict rehabilitation program for range of motion and Achilles tendon strengthening. Eccentric stretching of the Achilles tendon began 4 weeks after surgery. Pre- and postoperative radiographic findings are described in Figure 2.

Statistical Analysis

Descriptive statistics were used to summarize the patient characteristics. The mean preoperative and final AOFAS hindfoot scores were compared via a paired *t* test. The mean time to RTC and rate of RTP were calculated. A subgroup analysis was performed to compare patients who achieved RTP (RTP group) versus those who did not (no-RTP group). The Kolmogorov-Smirnov test and the Shapiro-Wilk test were performed to check the normality of the data. The Student *t* test was performed to compare parametric data, and the Mann-Whitney test was used for nonparametric data. The significance level for all statistical analyses was set at .05. Data were analyzed using SPSS (Version 18.0; IBM Corp).

RESULTS

The mean ± standard deviation (SD) follow-up was 31.3 ± 8.95 months (range, 24-53 months). Characteristic data of all patients are summarized in Table 1. The mean ± SD age

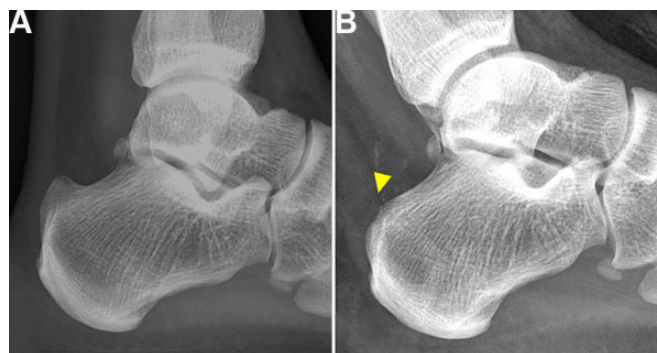


Figure 2. (A) Preoperative simple lateral-view radiograph showing a prominent posterosuperior calcaneus. (B) Postoperative radiograph showing resected calcaneal tubercle and decompression of retrocalcaneal recess (arrowhead).

TABLE 1
Patient Characteristics^a

Patient	Age, y	Sex	Height, cm	BMI	Sport	Symptom Duration, y ^b	Surgery	AOFAS Hindfoot Score				
								Preoperative	Final	Satisfaction	RTC, mo	RTP
1	16	M	181	19.84	Soccer	2	O, T	76	90	Excellent	4	Yes
2	18	M	179	23.10	Skating	1	O	67	95	Excellent	4	Yes
3	17	M	180	21.60	Soccer	2	O	63	92	Excellent	5	Yes
4	16	M	177	21.71	Soccer	2	O	72	93	Excellent	4	Yes
5	17	M	172	21.30	Soccer	2	O	64	89	Excellent	5	Yes
6	35	M	176	25.83	Soccer	3	O	54	76	Poor	12	No
7	29	M	178	22.41	Soccer	7	O, T	54	88	Fair	8	No
8	18	M	172	21.97	Soccer	3	O	68	92	Good	4	Yes
9	24	F	NA	NA	Taekwondo	2	O	57	92	Good	9	Yes
10	23	M	181	25.34	Soccer	3	O	73	89	Fair	6	Yes
11	20	M	177	24.26	Soccer	2	O	73	93	Fair	10	No
12	15	M	169	23.11	Swimming	3	O	52	72	Poor	18	No
13	16	M	177	24.26	Ice skating	2	O	64	89	Good	11	No
14	18	M	175	24.16	Soccer	2	O, T	64	89	Good	9	No
15	21	M	179	21.85	Soccer	2	O, T	67	90	Excellent	4	Yes
16	22	M	173	24.06	Skating	3	O, T	73	90	Good	11	No
17	19	M	179	21.85	Taekwondo	1	O	64	88	Fair	5	Yes
18	16	M	179	22.16	Soccer	2	O, T	68	88	Excellent	5	Yes
19	18	M	176	21.63	Soccer	2	O	64	89	Good	5	Yes
20	20	M	173	24.06	Skating	1	O	64	85	Good	10	No

^aAOFAS, American Orthopaedic Foot and Ankle Society; BMI, body mass index; F, female; M, male; NA, not available; O, calcaneal osteotomy; RTC, return to competition; RTP, return to play; T, bursectomy or debridement.

^bTime from initial symptoms to surgery.

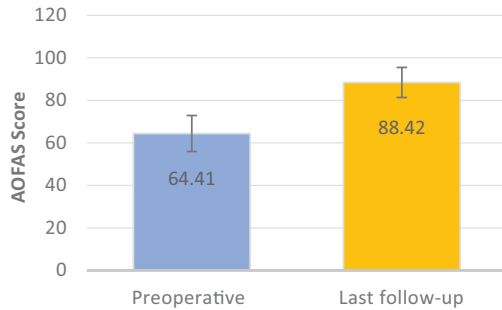


Figure 3. Outcome evaluation using the American Orthopaedic Foot and Ankle Society (AOFAS) hindfoot score. The scores were significantly greater at the final follow-up compared with preoperatively ($P < .001$).

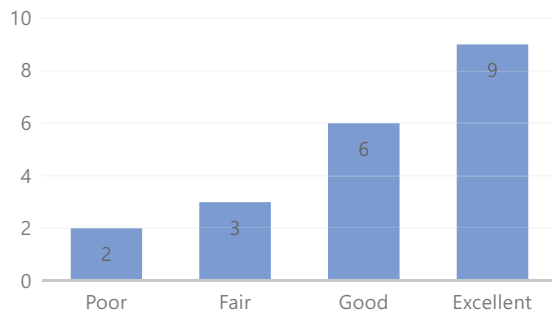


Figure 4. Subjective satisfaction of patients.

of the patients was 19.9 ± 4.92 years (range, 15-35 years). Of the 20 patients, 13 patients were professional soccer players. A total of 14 patients underwent calcaneal osteotomy only, whereas 6 patients had additional retrocalcaneal bursectomy or paratenonitis debridement combined with calcaneal osteotomy.

Postoperative Outcomes

The mean \pm SD AOFAS hindfoot score significantly improved from preoperative assessment to the final follow-up (65.1 ± 8.46 vs 88.4 ± 7.08 , respectively; $P < .001$) (Figure 3). The patient satisfaction scores are depicted in Figure 4. Of the total 20 patients, 15 patients (75%) reported good to excellent results. The time of RTC ranged from 4 to 18 months after surgery, with a mean time of 7.45 months; the rate of RTP was 60%.

The results of the subgroup analysis are summarized in Table 2. The RTP group had a significantly lower body mass index (BMI) than did the no-RTP group (22.03 vs 23.86 , respectively; $P = .005$) and a significantly faster RTC time (5.0 vs 11.1 months, respectively; $P < .001$).

Sample Size Calculation

We performed a post hoc power analysis because there were no previous studies evaluating the operative outcome of insertional Achilles tendinopathy in professional athletes.

TABLE 2
Subgroup Analysis^a

	RTP Group (n = 12)	No-RTP Group (n = 8)	P
Age, y	18.6 ± 2.71	21.9 ± 6.83	.229
Body mass index	22.03 ± 1.34	23.86 ± 1.04	.005
Preoperative AOFAS score	66.9 ± 5.11	62.3 ± 8.30	.135
Final AOFAS score	90.6 ± 2.19	85.1 ± 7.28	.074
Time of RTC, mo	5.0 ± 1.41	11.1 ± 3.04	<.001

^aData are presented as mean \pm SD. Bolding indicates statistically significant differences ($P < .05$). AOFAS, American Orthopaedic Foot and Ankle Society; RTC, return to competition; RTP, return to play.

With RTC as the primary study outcome, the mean \pm SD times to RTC in the RTP and no-RTP groups were 5.0 ± 1.41 and 11.1 ± 3.04 months, respectively. The pooled SD of the groups was calculated as 2.37, and the effect size was 2.57. With the statistical model of 2-tailed independent Student *t* test, the sample sizes of both groups as 12 (RTP) and 8 (no-RTP), and a significance level of .05, the power of this study was calculated to be 99%.

DISCUSSION

The current study evaluated the clinical outcomes of open calcaneoplasty for treatment of insertional Achilles tendinopathy with Haglund deformity in highly competitive professional athletes. The AOFAS hindfoot score was significantly improved at the final follow-up (65.1 ± 8.46 preoperatively vs 88.4 ± 7.08 at the final follow-up; $P < .001$). However, in terms of the subjective satisfaction of patients, only 75% of the patients reported good to excellent satisfaction for their treatment outcome. Moreover, the mean time to RTC after surgery was 7.45 months. Long absences from official matches could jeopardize an athlete's career as a professional player. In addition, only 60% of the patients maintained their preinjury level of sports activity at least 2 full seasons after surgical treatment.

Several studies have investigated the source of pain in insertional Achilles tendinopathy. Bone edema of the posterolateral calcaneus, caused by repetitive impingement with the anterior surface of the Achilles tendon, is considered a source of heel pain. Previous research⁵ has noted that the posterior wall of the calcaneus is composed of articular cartilage. Degenerative arthritic changes on the cartilage have been proven histologically, and the severity of such arthritic changes showed a direct correlation with symptoms.¹⁸ Retrocalcaneal bursitis can also be a source of pain. A recent anatomic study revealed communication between the retrocalcaneal bursa and the anterior surface of the Achilles tendon, showing that this factor can cause insertional Achilles tendinitis with repetitive attrition.¹⁸ Continuous mechanical and chemical irritation between the retrocalcaneal bursa and the Achilles tendon can cause degeneration of the tendon and eventually result in

intrasubstance calcific deposition in the tendon.¹⁸ Superficial Achilles tendon bursitis can also occur in insertional Achilles tendinopathy.¹⁹ Immunohistochemical findings have shown that the subcutaneous bursa had the highest degree of innervation.³ Thus, the pain associated with insertional Achilles tendinopathy could be due to bone edema, arthritic changes on the posterior wall of the calcaneus, retrocalcaneal bursitis, insertional Achilles tendinitis, and superficial Achilles tendon bursitis.³

In the past, surgical treatment of insertional Achilles tendinopathy was not recommended in the literature. Schneider et al²⁰ described 49 patients who had open surgical treatment for insertional Achilles tendinopathy; only 69.4% of those patients were satisfied after surgery, and 14.3% of the patients reported worsening symptoms. However, recent literature has noted favorable outcomes of operative procedures for insertional Achilles tendinopathy. Ahn et al¹ performed open surgical treatment using a central Achilles tendon-splitting approach in 15 patients. The investigators noted that this approach was a safe and satisfactory procedure for intractable insertional Achilles tendinopathy, with a mean AOFAS hindfoot score of 92.5 at the final follow-up. Jiang et al¹⁰ introduced an open operative technique using double-row suture. They reported that open excision of the calcaneal prominence with complete detachment of the Achilles tendon and subsequent reattachment of the Achilles tendon using a double-row suture technique can be a better option for insertional Achilles tendinopathy. Endoscopic procedures have also been introduced. Ortmann and McBryde¹⁶ described endoscopic decompression of the retrocalcaneal space for insertional Achilles tendinopathy and reported a final AOFAS hindfoot score of 97 points. Those investigators noted that the endoscopic technique can be a safe procedure with sufficient exposure of the pathologic calcaneal prominence and the Achilles tendon. Vega et al²³ described favorable outcomes after using an endoscopic procedure with augmentation with suture anchor.

Although several recent reports have described good outcomes for the surgical treatment of insertional Achilles tendinopathy, those studies were conducted on nonathletes. Returning to their jobs as professional sports players is a critical outcome for athletes.⁴ Thus, the concept of RTP should be addressed in outcome evaluation. However, the concept of RTP lacks a uniform definition and method of evaluation in literature.²⁵ A standardized evaluation of RTP could provide a solid basis for comparison.²⁵ The possibility of returning to a previous sports career and the longevity of sports activity after this return seem to be considered differently. In reviewing literature, we found that the 2 concepts are often confused. The time of RTP can be defined as the time when an athlete first returns to play in an official match; however, this definition of RTP does not imply that the sports activity can be maintained for long period. Therefore, another aspect of return to sports, its longevity, should be defined. Grassi et al⁹ defined RTC as at least 1 minute of participation in an official match after surgery and RTP as participation in at least 2 entire seasons in the same division in which the athlete played before injury.⁹ RTC measures how fast an injured athlete can

return to official match play, and RTP measures the rate at which injured athletes maintain extended function in their sports activity.

We found that the players' BMI and the time of RTC displayed significant differences between the RTP and non-RTP groups. The RTP group showed a significantly shorter time of RTC. Aggressive rehabilitation for fast recovery after surgery may be emphasized for athletic patients to maintain their extended sports function. Olsson et al¹⁵ emphasized the importance of early functional recovery, noting that minor improvements occurred between postoperative years 1 and 2. Thus, to enhance the final outcome, rehabilitation should focus on improvements within the first year.¹⁵ Although older age seems related to inability to RTP, we did not find statistical significance for age in the current study. Our patients included a 35-year-old and a 29-year-old, neither of whom could continue their careers for at least 2 full seasons after surgery. This should have worked as a confounder in evaluating the effect of age on RTP. A study with more patients that can calculate odds for each variable may be able to reveal a more definitive conclusion regarding this issue.

The advantage of the current study is that it is the first study to assess the surgical outcomes of insertional Achilles tendinopathy in highly competitive professional athletes. We used specific concepts of RTC and RTP for outcome evaluation.

The current study has limitations. First, this is retrospective study with a small sample size. Although older age seems to have a negative effect on RTP, we could not find statistical significance with the given sample size. A larger number of patients would be needed to allow for a logistic regression analysis for multiple variables affecting RTP and thus would produce more clinically meaningful results. However, this is the first research concerning the surgical treatment of insertional Achilles tendinopathy in highly competitive professional athletes. Second, we did not perform endoscopic surgery. If the results of endoscopic surgery for insertional Achilles tendinopathy in athletes could be used as a comparison group, more insight into surgical treatment of insertional Achilles tendinopathy in athletes could be provided. Third, we used a heterogeneous group of sports for statistical analysis; only 1 patient was a swimmer, and 2 patients participated in taekwondo (martial arts). Such a small number of patients in specific sports can act as a confounder for analysis of results. Fourth, if we had gathered functional outcome scores at each year, our study would have more detailed clinical information regarding the rate of improvement after surgery with time. Future research in sports medicine regarding RTP after treatment should include this concept for deeper clinical insight.

CONCLUSION

Open calcaneoplasty for treatment of insertional Achilles tendinopathy with Haglund deformity in highly competitive professional athletes should be approached with caution. Results of previous clinical research involving nonathletes may not be applicable to professional athletes in terms of

managing insertional Achilles tendinopathy. Lengthy post-operative recovery time can be a problem. Moreover, the extended maintenance of sports activity seems to be difficult in a meaningful proportion of patients.

REFERENCES

- Ahn JH, Ahn CY, Byun CH, Kim YC. Operative treatment of Haglund syndrome with central Achilles tendon-splitting approach. *J Foot Ankle Surg.* 2015;54(6):1053-1056.
- Anderson JA, Suero E, O'Loughlin PF, Kennedy JG. Surgery for retrocalcaneal bursitis: a tendon-splitting versus a lateral approach. *Clin Orthop Relat Res.* 2008;466(7):1678-1682.
- Andersson G, Backman LJ, Christensen J, Alfredson H. Nerve distributions in insertional Achilles tendinopathy—a comparison of bone, bursae and tendon. *Histol Histopathol.* 2017;32(3):263-270.
- Aune KT, Andrews JR, Dugas JR, Cain EL Jr. Return to play after partial lateral meniscectomy in National Football League athletes. *Am J Sports Med.* 2014;42(8):1865-1872.
- Bullock MJ, Mourelatos J, Mar A. Achilles impingement tendinopathy on magnetic resonance imaging. *J Foot Ankle Surg.* 2017;56(3):555-563.
- Chimenti RL, Cychosz CC, Hall MM, Phisitkul P. Current concepts review update: insertional Achilles tendinopathy. *Foot Ankle Int.* 2017;38(10):1160-1169.
- Garrett WE Jr, Swiontkowski MF, Weinstein JN, et al. American Board of Orthopaedic Surgery practice of the orthopaedic surgeon, part II: certification examination case mix. *J Bone Joint Surg Am.* 2006;88(3):660-667.
- Gillis CT, Lin JS. Use of a central splitting approach and near complete detachment for insertional calcific Achilles tendinopathy repaired with an Achilles bridging suture. *J Foot Ankle Surg.* 2016;55(2):235-239.
- Grassi A, Rossi G, D'Hooghe P, et al. Eighty-two per cent of male professional football (soccer) players return to play at the previous level two seasons after Achilles tendon rupture treated with surgical repair. *Br J Sports Med.* 2020;54(8):480-486.
- Jiang Y, Li Y, Tao T, et al. The double-row suture technique: a better option for the treatment of Haglund syndrome. *Biomed Res Int.* 2016;2016:1895948.
- Lareau CR, Hsu AR, Anderson RB. Return to play in National Football League players after operative Jones fracture treatment. *Foot Ankle Int.* 2016;37(1):8-16.
- Lui TH, Lo CY, Siu YC. Minimally invasive and endoscopic treatment of Haglund syndrome. *Foot Ankle Clin.* 2019;24(3):515-531.
- McAlister JE, Hyer CF. Safety of Achilles detachment and reattachment using a standard midline approach to insertional enthesophytes. *J Foot Ankle Surg.* 2015;54(2):214-219.
- Natarajan S, Narayanan VL. Haglund deformity—surgical resection by the lateral approach. *Malays Orthop J.* 2015;9(1):1-3.
- Olsson N, Nilsson-Helander K, Karlsson J, et al. Major functional deficits persist 2 years after acute Achilles tendon rupture. *Knee Surg Sports Traumatol Arthrosc.* 2011;19(8):1385-1393.
- Ortmann FW, McBryde AM. Endoscopic bony and soft-tissue decompression of the retrocalcaneal space for the treatment of Haglund deformity and retrocalcaneal bursitis. *Foot Ankle Int.* 2007;28(2):149-153.
- Paavola M, Kannus P, Järvinen TA, Khan K, Józsa L, Järvinen M. Achilles tendinopathy. *J Bone Joint Surg Am.* 2002;84(11):2062-2076.
- Palmanovich E, Oshri Y, Brin YS, Edelshtein E, Nyska M, Hetsroni I. Insertional Achilles tendinopathy is associated with arthritic changes of the posterior calcaneal cartilage: a retrospective study. *J Foot Ankle Res.* 2015;8:44.
- Phisitkul P. Endoscopic surgery of the Achilles tendon. *Curr Rev Musculoskelet Med.* 2012;5(2):156-163.
- Schneider W, Niehus W, Knahr K. Haglund's syndrome: disappointing results following surgery—a clinical and radiographic analysis. *Foot Ankle Int.* 21(1):26-30.
- Schweitzer ME, Karasick D. MR imaging of disorders of the Achilles tendon. *AJR Am J Roentgenol.* 2000;175(3):613-625.
- van Dijk CN, van Sterkenburg MN, Wiegerinck JI, Karlsson J, Maffulli N. Terminology for Achilles tendon related disorders. *Knee Surg Sports Traumatol Arthrosc.* 2011;19(5):835-841.
- Vega J, Baduell A, Malagelada F, Allmendinger J, Dalmau-Pastor M. Endoscopic Achilles tendon augmentation with suture anchors after calcaneal exostectomy in Haglund syndrome. *Foot Ankle Int.* 2018;39(5):551-559.
- Watson AD, Anderson RB, Davis WH. Comparison of results of retrocalcaneal decompression for retrocalcaneal bursitis and insertional Achilles tendinosis with calcific spur. *Foot Ankle Int.* 2000;21(8):638-642.
- Zellers JA, Carmont MR, Grävare Silbernagel K. Return to play post-Achilles tendon rupture: a systematic review and meta-analysis of rate and measures of return to play. *Br J Sports Med.* 2016;50(21):1325-1332.