

Available online at [www.sciencedirect.com](http://www.sciencedirect.com)

ScienceDirect

journal homepage: [www.elsevier.com/locate/radcr](http://www.elsevier.com/locate/radcr)

## Case report

# Primary diffuse leptomeningeal atypical teratoid rhabdoid tumor (AT/RT) demonstrating atypical imaging findings in an adolescent patient <sup>☆</sup>

Amiko Kayo, MD<sup>a,b</sup>, Akira Yogi, MD, PhD<sup>a,\*</sup>, Satoru Hamada, MD, PhD<sup>c</sup>, Koichi Nakanishi, MD, PhD<sup>c</sup>, Shota Kinjo, MD<sup>a</sup>, Kenichi Sugawara, MD, PhD<sup>d</sup>, Shogo Ishiuchi, MD, PhD<sup>d</sup>, Akihiro Nishie, MD, PhD<sup>a</sup>

<sup>a</sup>Department of Radiology, Graduate School of Medical Science, University of the Ryukyus, 207 Uehara, Nishihara, Okinawa 903-0215, Japan

<sup>b</sup>Department of Radiology, Naha City Hospital, Naha, Okinawa, Japan

<sup>c</sup>Department of Child Health and Welfare (Pediatrics), Graduate School of Medicine, University of the Ryukyus, Nishihara, Okinawa, Japan

<sup>d</sup>Department of Neurosurgery, Graduate School of Medical Science, University of the Ryukyus, Nishihara, Okinawa, Japan

## ARTICLE INFO

## Article history:

Received 19 October 2021

Revised 8 November 2021

Accepted 10 November 2021

## Keywords:

AT/RT

Leptomeninges

Adolescent

CT

MRI

FDG-PET

## ABSTRACT

Atypical teratoid rhabdoid tumor (AT/RT) is a highly malignant central nervous system embryonal tumor, which typically affects the posterior fossa of young children. Primary diffuse leptomeningeal AT/RT, affecting the leptomeninges without any intraparenchymal mass in the brain and spinal cord, is an extremely rare form of AT/RT. Only 5 such cases have been reported previously, none of which underwent Fluorine-18-Fluorodeoxyglucose Positron Emission Tomography (FDG-PET). We herein report a case of primary leptomeningeal AT/RT in an adolescent patient who underwent computed tomography, magnetic resonance imaging and FDG-PET. The computed tomography and magnetic resonance imaging indicated diffusely thickened leptomeninges without any intraparenchymal masses in the head and spine. Furthermore, there were multiple nodules on the thickened leptomeninges. On FDG-PET, the thickened leptomeninges and nodules demonstrated a lower standardized uptake value than that of the normal cerebral cortex. Biopsy and histopathological studies confirmed the diagnosis of AT/RT. Despite its rare occurrence, it is important to recognize primary diffuse leptomeningeal AT/RT for correct diagnosis and management of patients.

© 2021 The Authors. Published by Elsevier Inc. on behalf of University of Washington.

This is an open access article under the CC BY-NC-ND license (<http://creativecommons.org/licenses/by-nc-nd/4.0/>)

<sup>☆</sup> Competing Interests: The authors declare that they have no known competing financial interests or personal relationships that could have appeared to influence the work reported in this paper.

\* Corresponding author. A. Yogi.

E-mail address: [ayogi@med.u-ryukyu.ac.jp](mailto:ayogi@med.u-ryukyu.ac.jp) (A. Yogi).

<https://doi.org/10.1016/j.radcr.2021.11.026>

1930-0433/© 2021 The Authors. Published by Elsevier Inc. on behalf of University of Washington. This is an open access article under the CC BY-NC-ND license (<http://creativecommons.org/licenses/by-nc-nd/4.0/>)

## Introduction

Atypical teratoid rhabdoid tumor (AT/RT) is a highly malignant central nervous system (CNS) embryonal tumor, classified as grade IV in the fourth edition of the WHO classification for CNS tumors [1]. A loss of switch/sucrose non-fermentable (SWI/SNF)-related matrix-associated actin-dependent regulator of chromatin subfamily B member 1 (SMARCB1) expression follows the loss of nuclear Integrase Interactor 1 (INI1) activity, resulting in AT/RT occurrence [2]. Characteristic histological findings include varying proportions of rhabdoid cells, which are negative for INI1 immunohistochemical staining [2]. It typically affects children younger than 3 years old [3], and rarely occurs in adolescents and adults, of which only 75 cases have been reported previously [4].

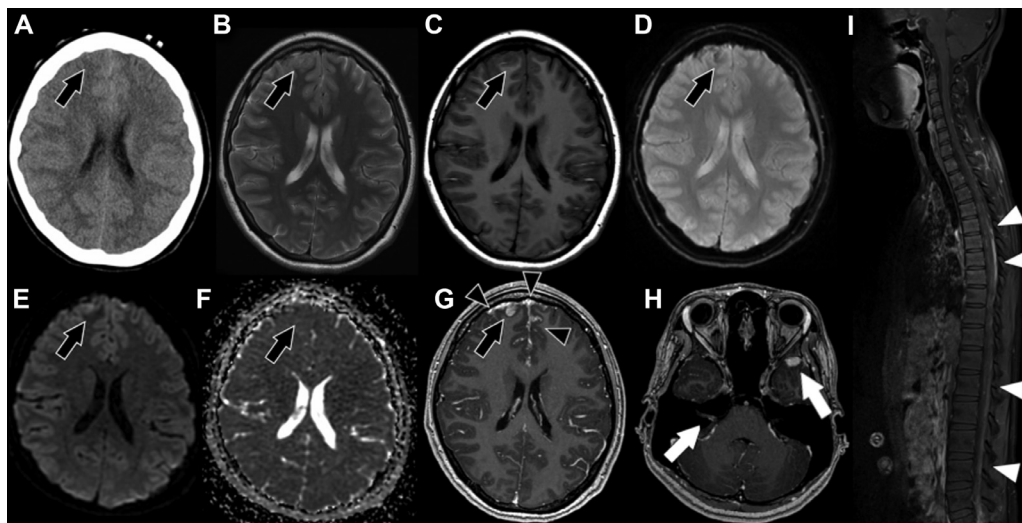
Common sites for typical AT/RT include the cerebellar hemispheres, brainstem and cerebellopontine angle, whereas the sellar region and cerebral hemispheres are common for the AT/RT in adults [4,5]. Leptomeningeal dissemination is common in typical AT/RT, initially confirmed in one third of AT/RT patients [6]. However, it is extremely rare for AT/RT to primarily affect the leptomeninges. This is termed as *primary diffuse leptomeningeal AT/RT*. There have been only 5 previously reported cases of primary diffuse leptomeningeal AT/RT [2,3,7,8].

We herein present a case of primary diffuse leptomeningeal AT/RT in an adolescent patient with the imaging findings of computed tomography (CT), magnetic resonance imaging (MRI) and Fluorine-18-Fluorodeoxyglucose Positron Emission Tomography (FDG-PET).

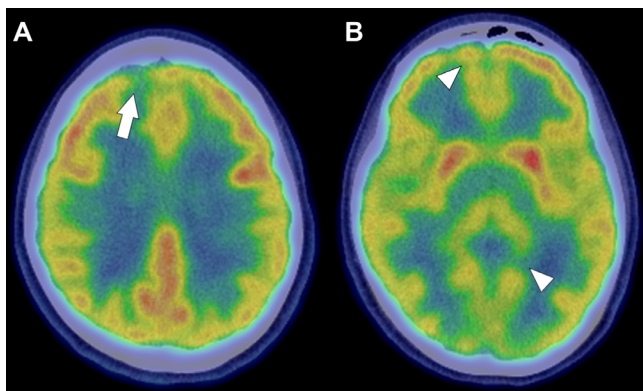
## Case presentation

A 16-year-old female with no significant medical or family history presented with dizziness, frequent vomiting, and weight loss. After right hearing loss and blurred vision appeared 4 months after the onset of symptoms, she was referred to our hospital for a thorough examination. The neurological examination revealed a right-dominant, resting horizontal nystagmus, right facial nerve palsy, and right hearing loss. She also complained of a headache with head motion. Neck stiffness was not apparent.

The non-contrast enhanced cerebral CT showed an iso- or slightly hypodense nodule in the right frontal cortex, which contained a highly attenuated focal region, suggesting the presence of hemorrhage or calcification (Fig. 1A). The size of the nodule was  $7 \times 5$  mm. On the cerebral MRI (Figs. 1B–H), contrast enhanced T1 weighted imaging (T1WI) demonstrated thickened leptomeninges with strong enhancement in the bilateral cerebral and cerebellar hemispheres. The nodule in the right frontal lobe was in the leptomeninges, protruding into the brain parenchyma. In addition, there were multiple contrast-enhanced nodules in the thickened leptomeninges, including in the right internal auditory canal. The nodule protruding into the right frontal lobe demonstrated heterogeneous hyperintensity on T2 weighted imaging (T2WI), hypointensity on T1WI, and dense hypointensity on T2\* weighted imaging (T2\*WI), due to hemosiderin deposition. Diffusion-weighted imaging (DWI) showed heterogeneously restricted diffusion with a mean apparent diffusion coefficient (ADC) value of  $0.9 \times 10^{-3}$  mm<sup>2</sup>/sec, indicating high



**Fig. 1 – (A)** The non-contrast enhanced CT demonstrates an iso- or slightly hypodense area within the cortex of the right frontal lobe (black arrow). **(B, C)** The right frontal lobe demonstrates heterogeneous signal changes with iso- and slight hyperintensity on T2WI and slight hypointensity on T1WI (black arrow). **(D)** There is hypointensity within the lesion, indicating hemosiderin deposition on T2\*WI (black arrow). **(E, F)** DWI and the ADC map demonstrate heterogeneously restricted diffusion, indicating mixed cellularity (black arrow). **(G, H)** Contrast-enhanced T1WI demonstrates the diffusely thickened leptomeninges with multiple contrast-enhanced nodules (black arrowheads). The nodule in the right frontal lobe is also on the thickened leptomeninges, protruding into the brain parenchyma (black arrow). The contrast-enhanced nodule is also in the right auditory canal and the left sphenoid ridge (white arrows). **(I)** Contrast-enhanced Spinal MRI demonstrates a diffusely and irregularly thickened leptomeninges (white arrowheads).



**Fig. 2 – (A, B) The fusion images of FDG-PET and the head CT demonstrate a slightly lower FDG uptake compared to that of normal cerebral cortex, with a mean SUV of 3.51 (white arrow). There are other lower FDG uptakes, due to thickened leptomeninges (white arrowheads).**

cellularity within the nodule. The adjacent cortex was hypertrophic and showed slight hypointensity on T1WI and slight hyperintensity on T2WI. The spinal MRI also demonstrated diffuse meningeal thickness with a slight irregularity in the spinal cord (Fig. 1). There were no intraparenchymal abnormalities in the brain or spinal cord.

On FDG-PET, the mean standardized uptake value (SUV) of the nodule protruding into the right frontal lobe was 3.51, which was lower than that of normal cortex (Fig. 2). There were no findings suspicious for malignancy in the other sites.

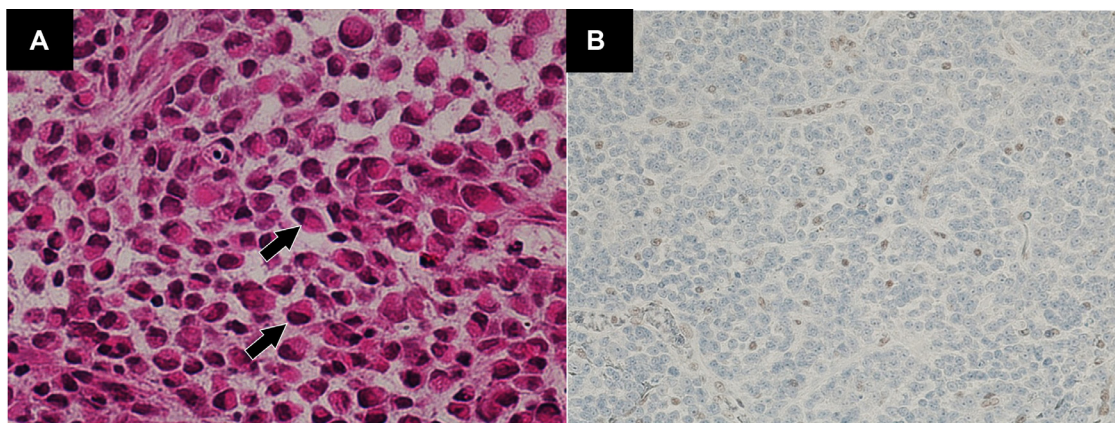
We initially considered the possibility of infectious meningitis due to fungus or mycobacterium tuberculosis, lymphoproliferative diseases, including sarcoidosis or malignant lymphoma, autoimmune diseases, diffuse leptomeningeal glioneuronal tumor or metastatic tumor as a differential diagnosis. No evidence of infectious or autoimmune disease was found by a detailed blood test. Seven days after the patient's arrival, we performed a biopsy on the nodule protruding into the right frontal lobe by a partial craniectomy. Histological ex-

amination revealed marked leptomeningeal plaque-like infiltration by rhabdoid cells containing eosinophilic cytoplasm and prominent nucleoli. Immunohistochemical staining revealed a loss of INI1 expression in the nuclei, resulting in a diagnosis of AT/RT (Fig. 3). In addition, most tumor cells were strongly positive for vimentin,  $\alpha$ -smooth muscle actin ( $\alpha$ SMA), and epithelial membrane antigen (EMA). A small number of tumor cells expressed neurofilament protein. Glial fibrillary acidic protein (GFAP), NeuN, and synaptophysin showed no immunoreactivity.

Remission induction therapy was started including Methotrexate, Vincristine, Cyclophosphamide, and Etoposide. However, on the sixth day after the start of treatment, the patient had status epilepticus and treatment was discontinued.

## Discussion

Primary diffuse leptomeningeal AT/RT affects the leptomeninges without an obvious intraparenchymal primary lesion. There have been only 5 reported cases, based on the literature search using the term of “primary diffuse leptomeningeal atypical teratoid/rhabdoid tumor” in PubMed without any language settings. The common imaging findings of the previously reported 5 primary diffuse leptomeningeal AT/RT cases was a smoothly thickened leptomeninges [2,3,7,8]. However, in the present case, there was not only thickened leptomeninges, but also multiple nodules on it. Thus, to the best of our knowledge, this is the first case of diffuse primary leptomeningeal AT/RT with multiple nodular lesions. Furthermore, the nodule protruding into the right frontal lobe, on which the biopsy was performed, demonstrated CT and MRI findings similar to those of common AT/RT. The heterogeneously mixed density and signal changes on CT and MRI, reflected solid components with high cellularity, cystic degenerations, hemorrhages and calcifications [6,9,10]. It is unclear whether the nodular lesions were derived from the thickened leptomeninges or a progressed form of primary diffuse leptomeningeal AT/RT. More cases are needed to elucidate the mechanism.



**Fig. 3 – (A) Hematoxylin/Eosin (original magnification  $\times 400$ ) demonstrates that the tumor consisted of rhabdoid cells with eosinophilic cytoplasm and prominent nucleoli (black arrows). (B) Immunostaining (original magnification  $\times 400$ ) demonstrated a diffuse loss of nuclear INI1 expression in tumor cells, indicating a diagnosis of AT/RT.**



In addition on FDG-PET, the nodule protruding into the right frontal lobe demonstrated lower FDG uptake than that of the adjacent normal cerebral cortex with the mean SUV of 3.51. To the best of our knowledge, this is also the first case of primary diffuse leptomeningeal AT/RT, with FDG-PET imaging findings. There has been only 1 previously reported AT/RT case with FDG-PET, where the AT/RT formed a large intraparenchymal mass in the right frontal lobe, and demonstrated much higher FDG uptake than that of the normal cerebral cortex [11]. Although, the lower SUV in our case might be underestimated due to only a thickened leptomeninges with multiple nodules. Therefore, we cannot determine whether or not the lower FDG uptake in primary diffuse leptomeningeal case is typical findings.

AT/RT is rare in adolescents and adults, and the common locations are the sellar region and cerebral hemispheres [4,5,12,13]. It is interesting that the ages of primary diffuse leptomeningeal AT/RT patients, including the present case, were 2, 1, 2, 17, 15 and 16 years old, a half of which are adolescent patients [7,8,3,2]. The median age is 8.5 years old, which is higher than that of typical AT/RT [1]. Therefore, the leptomeninges could be a characteristic site of occurrence for AT/RT in adolescents, in addition to the sellar region and cerebral hemispheres. As a patient ages, a greater variety of CNS diseases are considered as a differential diagnosis, when we find a thickened leptomeninges. Thus, recognition of this rare AT/RT type is clinically important to avoid misdiagnosis and guide the appropriate clinical management.

## Conclusion

Here, we present a case of primary diffuse leptomeningeal AT/RT in an adolescent patient. MRI demonstrated not only a thickened leptomeninges, as previously reported, but also multiple nodular lesions. A nodule protruding into the right frontal lobe demonstrated CT and MRI findings similar to those of typical intraparenchymal AT/RT, but with a lower SUV than that of the adjacent cerebral cortex on FDG-PET. Despite its rare entity, it is important to recognize primary diffuse leptomeningeal AT/RT to avoid misdiagnosis and guide the appropriate clinical management.

## Patient consent

Informed consent was obtained from the patient featured in this case report.

## REFERENCE

- [1] Kristensen BW, Priesterbach-Ackley LP, Petersen JK, Wesseling P. Molecular pathology of tumors of the central nervous system. *Ann Oncol* 2019;30:1265–78.
- [2] Tomomasa R, Nakata S, Nobusawa S, Horiguchi K, Matsumura N, Ikota H, et al. Primary diffuse leptomeningeal atypical teratoid/rhabdoid tumor diagnosed by cerebrospinal fluid cytology: case report with molecular genetic analysis. *Hum Pathol* 2018;77:116–20.
- [3] Livermore LJ, Dabbous B, Hofer M, Kueker W, Jayamohan J, Wimalaratna S. Primary diffuse leptomeningeal atypical teratoid/rhabdoid tumour in an adolescent. *Clin Neurol Neurosurg* 2013;115:2170–3.
- [4] Peng AJ, Fan SC, Chen YX, Huang JH, Cao Y, Zhou LX, et al. Atypical teratoid/rhabdoid tumor in adult: case series and an integrated survival analysis. *Br J Neurosurg* 2021;17:1–16.
- [5] Chan V, Marro A, Findlay JM, Schmitt LM, Das S. A systematic review of atypical teratoid rhabdoid tumor in adults. *Front Oncol* 2018;8:567.
- [6] Han L, Qiu Y, Xie C, Zhang J, Lv X, Xiong W, et al. Atypical teratoid/rhabdoid tumors in adult patients: CT and MR imaging features. *Am J Neuroradiol* 2011;32:103–8.
- [7] El-Nabbout B, Shbarou R, Glasier CM, Saad AG. Primary diffuse cerebral leptomeningeal atypical teratoid rhabdoid tumor: report of the first case. *J Neurooncol* 2010;98:431–4.
- [8] Gauvain KM, Durham BH, McHugh M, Geller TJ. Rapidly progressive primary leptomeningeal atypical teratoid/rhabdoid tumor: a report of 2 cases. *J Child Neurol* 2012;27:1597–601.
- [9] Kanoto M, Toyoguchi Y, Hosoya T, Kuchiki M, Sugai Y. Radiological image features of the atypical teratoid/rhabdoid tumor in adults: a systematic review. *Clin Neuroradiol* 2015;25:55–60.
- [10] Kawaguchi T, Kumabe T, Watanabe M, Tominaga T. Atypical teratoid/rhabdoid tumour with leptomeningeal dissemination in an adult. *Acta Neurochir (Wien)* 2004;146:1033–8 discussion 1038.
- [11] Sasajima T, Oda M, Kinouchi H, Hatazawa J, Mizoi K. [Frontal atypical teratoid/rhabdoid tumor evaluated by single-photon emission computerized tomography and positron emission tomography]. *No Shinkei Geka* 2002;30:639–45.
- [12] Samaras V, Stamatelli A, Samaras E, Stegiou I, Konstantopoulou P, Varsos V, et al. Atypical teratoid/rhabdoid tumor of the central nervous system in an 18-year-old patient. *Clin Neuropathol* 2009;28:1–10.
- [13] Ostrom QT, Chen Y, De Blank PM, Ondracek A, Farah P, Gittleman H, et al. The descriptive epidemiology of atypical teratoid/rhabdoid tumors in the United States, 2001–2010. *Neuro Oncol* 2014;16:1392–9.