

Magnetic Resonance Angiography Detection of Abnormal Carotid Artery Plaque in Patients With Cryptogenic Stroke

Ajay Gupta, MD; Gino Gialdini, MD; Michael P. Lerario, MD; Hedyeh Baradaran, MD; Ashley Giambrone, PhD; Babak B. Navi, MD, MS; Randolph S. Marshall, MD, MS; Costantino Iadecola, MD; Hooman Kamel, MD

Background—Magnetic resonance imaging of carotid plaque can aid in stroke risk stratification in patients with carotid stenosis. However, the prevalence of complicated carotid plaque in patients with cryptogenic stroke is uncertain, especially as assessed by plaque imaging techniques routinely included in acute stroke magnetic resonance imaging protocols. We assessed whether the magnetic resonance angiography–defined presence of intraplaque high-intensity signal (IHIS), a marker of intraplaque hemorrhage, is associated with ipsilateral cryptogenic stroke.

Methods and Results—Cryptogenic stroke patients with magnetic resonance imaging evidence of unilateral anterior circulation infarction and without hemodynamically significant ($\geq 50\%$) stenosis of the cervical carotid artery were identified from a prospective stroke registry at a tertiary-care hospital. High-risk plaque was assessed by evaluating for IHIS on routine magnetic resonance angiography source images using a validated technique. To compare the presence of IHIS on the ipsilateral versus contralateral side within individual patients, we used McNemar's test for correlated proportions. A total of 54 carotid arteries in 27 unique patients were included. A total of 6 patients (22.2%) had IHIS-positive nonstenosing carotid plaque ipsilateral to the side of ischemic stroke compared to 0 patients who had IHIS-positive carotid plaques contralateral to the side of stroke ($P=0.01$). Stroke severity measures, diagnostic evaluations, and prevalence of vascular risk factors were not different between the IHIS-positive and IHIS-negative groups.

Conclusions—Our findings suggest that a proportion of strokes classified as cryptogenic may be mechanistically related to complicated, nonhemodynamically significant cervical carotid artery plaque that can easily be detected by routine magnetic resonance imaging/magnetic resonance angiography acute stroke protocols. (*J Am Heart Assoc.* 2015;4:e002012 doi: 10.1161/JAHA.115.002012)

Key Words: carotid artery • cryptogenic stroke • magnetic resonance angiography • magnetic resonance imaging • risk factor • stroke

Atherosclerosis of the extracranial carotid arteries is a well-known etiology of ischemic stroke, with a large body of evidence demonstrating that increasing carotid artery luminal stenosis is strongly associated with stroke risk.^{1,2} The Trial of Org 10172 in Acute Stroke Treatment (TOAST) classification scheme requires angiographic luminal stenosis of at least 50% in order to attribute a stroke to large-artery atherosclerosis.³ Stroke patients with carotid stenosis <50%

and no other identified mechanism of stroke would be identified as cryptogenic by TOAST classification. Unfortunately, up to one third of ischemic stroke patients fall into this category, with no definite stroke etiology identified despite exhaustive diagnostic evaluation.^{1,2} There is emerging evidence, however, that luminal stenosis alone does not accurately predict those carotid artery plaques most likely to embolize and cause ischemic symptoms.^{3,4} In particular, recent improvements in carotid plaque magnetic resonance imaging (MRI) have allowed for in vivo detection of the specific atherosclerotic plaque elements that are most likely to cause ipsilateral ischemic symptoms, including in patients traditionally classified as having cryptogenic stroke.^{5–7} For example, in a recent study of cryptogenic stroke patients imaged ≈ 1 week after presentation, investigators used a detailed, multisequence MRI study of carotid plaque with a dedicated carotid coil to show a strong correlation between the presence of Type VI American Heart Association (AHA) carotid atherosclerotic plaque and ipsilateral ischemic stroke.⁸

Though such multisequence MRI studies of carotid plaque provide highly detailed plaque characterization, their value in

From the Departments of Radiology (A. Gupta, H.B.), Neurology (M.P.L., B.B.N., C.I., H.K.), and Healthcare Policy and Research (A. Giambrone) and Feil Family Brain and Mind Research Institute (A. Gupta, G.G., B.B.N., C.I., H.K.), Weill Cornell Medical College (WCMC), New York, NY; Department of Neurology, Columbia University Medical Center, New York, NY (R.S.M.).

Correspondence to: Ajay Gupta, MD, 525 East 68th Street, Starr 8A, Box 141, New York, NY 10065. E-mail: ajg9004@med.cornell.edu

Received March 11, 2015; accepted May 6, 2015.

© 2015 The Authors. Published on behalf of the American Heart Association, Inc., by Wiley Blackwell. This is an open access article under the terms of the Creative Commons Attribution-NonCommercial License, which permits use, distribution and reproduction in any medium, provided the original work is properly cited and is not used for commercial purposes.

the imaging workup of suspected acute stroke is limited, given that such examinations require specialized MRI hardware (carotid artery coils), gadolinium injection, \approx 20 minutes of imaging time, and significant additional training and time to interpret. Therefore, we assessed whether a routine, 3-minute MR angiographic imaging study of the extracranial neck vessels, already widely performed to evaluate for luminal stenosis, might also contain plaque vulnerability information that could provide mechanistic insight into ischemic strokes of unknown etiology. Specifically, our objective was to assess whether noncontrast 3-dimensional (3D)-time-of-flight (TOF) MR angiography (MRA) of the neck can detect high-risk atherosclerotic plaque elements in patients with nonhemodynamically significant carotid plaque who present with stroke of undetermined source.

Methods

Subjects and Clinical Data Collection

Subjects for this study were identified from an Institutional Review Board–approved clinical registry of all ischemic strokes at the New York-Presbyterian Hospital/Weill Cornell Medical Center, a tertiary-care hospital and certified primary stroke center. All patients admitted to our hospital's stroke service with ischemic stroke during 2013 were prospectively included in a database that is part of the AHA's Get With the Guidelines Stroke national registry.⁹ The Get With the Guidelines data collection was performed using a standardized template to collect clinical data on consecutively admitted stroke patients.⁹ Ischemic stroke was determined by inpatient vascular neurologists using the AHA's definition¹⁰ of an episode of neurologic dysfunction caused by focal brain ischemia, based on either imaging evidence of infarction in a defined vascular distribution or clinical symptoms persisting $>$ 24 hours. Trained hospital personnel collected information about the National Institutes of Health stroke scale upon presentation, prior stroke history, inpatient hospital diagnostic studies performed, and demographic characteristics. In addition, the presence of the following vascular risk factors was also recorded: active tobacco use, diabetes (defined as a hemoglobin A1C of $>$ 6.5% or on diabetes medication), insulin use, hypertension (blood pressure $>$ 140/90 mm Hg or on antihypertensive medication), atrial fibrillation, dyslipidemia (low-density lipoprotein $>$ 100 mg/dL or on statin therapy), coronary heart disease, and cardiac valvular disease.

For subjects included in this prospective registry, 2 vascular neurologists, using all available medical data, independently assigned stroke etiology using the TOAST classification scheme.¹¹ Disagreements in subjects' stroke subtype classification were adjudicated by a third vascular neurologist. Once this cohort of ischemic stroke patients was identified,

the following additional inclusion criteria were applied: (1) ischemic stroke of undetermined source per the TOAST classification, (2) MRI of the brain and MRA of the neck (including 3D and 2D TOF sequences) performed during the inpatient admission, and (3) MRI evidence of diffusion-weighted imaging (DWI)-positive, unilateral anterior circulation infarct(s). We also applied the following exclusion criteria: (1) bilateral or posterior circulation acute, DWI-positive infarcts on MRI; and (2) evidence of carotid artery stenosis $>$ 50% on sonography, computed tomography angiography, or MRA as per North American Symptomatic Carotid Endarterectomy Trial criteria.¹ In a sensitivity analysis, we additionally excluded patients who were classified as having a stroke of undetermined source because of the presence of 2 or more potential stroke causes, thereby focusing on patients with truly cryptogenic stroke.

Imaging Technique

All neck MRA studies were performed on either 1.5 or 3.0 T Signa (General Electric) scanners using standard quadrature neck array coils. Of note, neither high-resolution surface carotid coils nor gadolinium were used for these examinations, which were performed during the acute stroke workup. The \approx 3-minute 3D-TOF acquisition involved a 20-cm field-of-view centered at the carotid artery bifurcation and included a 1.4-mm slice thickness and matrix of 320×192 and 320×224 on 1.5 and 3 T, respectively, yielding pixel sizes of \approx 0.6 mm. Because we aimed to assess the generalizability of this technique to routine clinical practice, no studies were excluded for patient motion artifact, and all studies with image quality sufficient to generate a clinical interpretation at the time of original image acquisition were included in our analysis.

Imaging Data Assessment

Brain MRI studies were examined and the location of DWI-positive lesions recorded. DWI-positive lesions were also categorized in terms of whether the cerebral cortex was involved. Intraplaque high-intensity signal (IHIS) on axial 3D-TOF images was used as a presumed marker for intraplaque hemorrhage.^{12,13} We used a previously published method^{12,14–16} in which hyperintense signal intensity in carotid plaque is assessed using region-of-interest analysis compared to background sternocleidomastoid muscle signal intensity. In those patients with visible nonhemodynamically stenosing plaque on TOF images, we used a quantitative cutoff of signal intensity 50% greater than skeletal muscle based on region-of-interest analysis in the area of suspected IHIS.^{14–16} We took care to clearly delineate IHIS from perivascular fat outside of the vessel by classifying a case as IHIS-positive

only when high signal occurred specifically at the site of a presumed atherosclerotic plaque, which we required to be detectable as a region of focal eccentric luminal narrowing seen on contiguous axial images. Such an effort minimized the chance that high-signal fat outside of the vessel would be mistaken for the intraplaque hemorrhage for which IHIS is a surrogate.¹⁴ Furthermore, we made an effort to avoid misclassifying plaque ulcers as IHIS by keeping in mind that ulcers (rather than IHIS associated with intraplaque hemorrhage) typically demonstrate focal outpouching of flow-related enhancement with a narrow neck into a region of atherosclerotic plaque.

IHIS assessments were made blinded to clinical data and brain MRI data by a board-certified neuroradiologist. Reproducibility of these plaque assessments was made by a second independent radiologist who reviewed all MRA studies blinded to clinical data, the brain MRI findings, and the primary reader's interpretations. Since our acquisition also involves a larger field-of-view 2D-TOF acquisition (matrix size 320×192 on 3 T, 256×160 on 1.5 T, 22-cm field-of-view, slice thickness 1.6 mm, pixel size ≈0.8 mm) from the aortic arch to the skull base, these images were used for determination of the distal internal carotid artery as the denominator for North American Symptomatic Carotid Endarterectomy Trial (NASCET) stenosis. We calculated NASCET vessel narrowing by measuring the smallest luminal diameter relative to the caliber of normal-appearing distal internal carotid artery on axial source images. We also used the 3D maximum intensity projection images to corroborate whether the stenosis measurements derived from axial images were consistent with the overall impression of luminal narrowing severity provided by the interpretation of the maximum intensity projection images. Given the known relative imprecision of TOF imaging compared to contrast-enhanced techniques or catheter angiography in assessing stenosis severity, we dichotomized our stenosis severities into the more general 0% to 29% and 30% to 49% categories.

Statistical Analysis

Categorical variables are presented as absolute and relative frequencies. Continuous variables are presented as mean±SD or median and interquartile range, where appropriate. Our primary question was whether, in patients with ischemic stroke of undetermined source, there was a higher prevalence of IHIS ipsilateral to the infarct compared to the contralateral side. To compare the presence of IHIS on the ipsilateral versus contralateral side within individual patients, we used McNemar's test for correlated proportions. Because we studied patients with unilateral anterior circulation infarction, this approach allowed us to use each subject's contralateral

carotid artery as an internal control, thereby minimizing the impact of individual-level confounding bias since systemic vascular risk factors would presumably influence the cerebral hemispheres equally and differences due to unilateral abnormal carotid plaque could still be detected. Comparison of clinical characteristics between individual IHIS-positive and IHIS-negative patients was performed using either Fisher exact test or the Wilcoxon-Mann-Whitney test as appropriate. Interobserver variability in IHIS assessment was performed using both inter-rater agreement percentage and a Cohen κ statistic. To see whether IHIS is suboptimally detected on lower magnetic field strength MRI, a post-hoc sensitivity analysis limited to test data from 1.5 T MRI was performed. All P values >0.05 were considered statistically significant. All analyses were performed using SAS v9.3 (SAS Institute, Cary, NC).

Results

Baseline Patient Characteristics

Among 337 ischemic strokes in our institution's 2013 Get With the Guidelines Stroke registry, 119 subjects (35.3%) were classified as having stroke of undetermined source. After applying our additional inclusion and exclusion criteria, a total of 54 unique internal carotid arteries in 27 subjects (48.2% female, mean age 71.0±14.7 years) formed the sample that was analyzed in this study (Table 1).

MRI Results

All brain and MRA neck images of this cohort were included for analysis, with no studies excluded for technical reasons. The median interval days between the MRI brain showing DWI-positive lesions and the MRA neck was 0, with a mean of 1.7 days, as most patients had MRI of the brain performed concurrently during the same testing session as the neck MRA. Similarly, the median interval days between stroke onset and neck MRA was 1, with a mean of 2.6 days. A total of 21 of 27 subjects (77.8%) had MRI performed on a 1.5 T machine, with the remainder scanned on a 3 T machine. The mean NASCET degree of vessel narrowing was not significantly different between carotid arteries ipsilateral and contralateral to the side of stroke (10.5%±SD 16.3% ipsilateral to the side of stroke versus 8.6%±SD 15.9% contralateral to the side of stroke; $P=0.52$).

A total of 6 of 27 patients (22.2%) had nonhemodynamically stenosing carotid plaque positive for IHIS ipsilateral to the DWI-positive lesion compared to 0 of 27 patients with IHIS-positive plaques contralateral to the side of the infarction ($P=0.01$). Interobserver reproducibility of IHIS assessment was excellent, with an inter-rater agreement of 98%, and a κ

Table 1. Cohort Baseline Characteristics Stratified by the Presence of Intraplaque High-Signal Intensity in the Ipsilateral Internal Carotid Artery on MR Angiography of the Neck

	Overall (N=27)	Abnormal High Signal in Plaque (N=6)	No Abnormal Signal in Plaque (N=21)	P Value
Age, mean±SD	71.0±14.7	82.0±6.2	67.9±15.0	0.021
Female, n (%)	13 (48.2)	2 (33.3)	11 (52.4)	0.648
Race, n (%)				0.115
White	24 (88.9)	4 (66.7)	20 (95.2)	
Black	2 (7.4)	1 (16.7)	1 (4.8)	
Other	1 (3.7)	1 (16.7)	0 (0)	
Onset to arrival time (hours), mean±SD Median (IQR)	31.0±51.0 13.6 (1.4, 36.0)	15.5±16.39 5.9 (4, 29.6)	35.6±57.0 16.9 (1.4, 36.0)	0.695
Length of stay (days), mean±SD Median (IQR)	6.7±18.1 2 (1, 4)	4.3±2.6 3.5 (2, 7)	7.4±20.5 2 (1, 4)	0.180
IV TPA administered, n (%)				1.000
Yes	2 (7.4)	0 (0)	2 (9.5)	
No	25 (92.6)	6 (100.0)	19 (90.5)	
Arrival by ambulance, n (%)				1.000
Yes	10 (37.0)	2 (33.3)	8 (38.1)	
No	17 (63.0)	4 (66.7)	13 (61.9)	
NIH Stroke Scale, median (IQR)	2 (0, 4)	4 (3, 4)	2 (0, 3)	0.081
Ambulatory status at discharge, n (%)				1.000
Not walking	3 (12.5)	1 (20.0)	2 (10.5)	
Walking with assistance	2 (8.3)	0 (0)	2 (10.5)	
Walking independently	19 (79.2)	4 (80.0)	15 (79.0)	
Insurance, n (%)				0.075
Commercial	7 (28.0)	0 (0)	7 (35.0)	
Medicare	12 (48.0)	2 (40.0)	10 (50.0)	
Medicaid	6 (24.0)	3 (60.0)	3 (15.0)	
Stroke severity				
NIH Stroke Scale, median (IQR)	2 (0, 4)	4 (3, 4)	2 (0, 3)	0.081
Vascular risk factor comorbidities				
Atrial fibrillation	2 (7.4)	1 (16.7)	1 (4.8)	0.402
Diabetes	6 (22.2)	2 (33.3)	4 (19.1)	0.586
Hypertension	21 (77.8)	6 (100.0)	15 (71.4)	0.284
Coronary artery disease	3 (11.1)	1 (16.7)	2 (9.5)	0.545
Dyslipidemia	15 (55.6)	3 (50.0)	12 (57.1)	1.000
Prior stroke	4 (14.8)	1 (16.7)	3 (14.3)	1.000
Valvular disease	0 (0)	0 (0)	0 (0)	n/a
Peripheral vascular disease	0 (0)	0 (0)	0 (0)	n/a
Active tobacco use	1 (3.7)	1 (16.7)	0 (0)	0.222
Insulin use	1 (3.7)	0 (0)	1 (4.8)	1.000
Ipsilateral carotid stenosis				0.101
0% to 29%	21 (77.8)	3 (50.0)	18 (85.7)	
30% to 49%	6 (22.2)	3 (50.0)	3 (14.3)	

Continued

Table 1. Continued

	Overall (N=27)	Abnormal High Signal in Plaque (N=6)	No Abnormal Signal in Plaque (N=21)	P Value
Contralateral carotid stenosis				1.000
0% to 29%	23 (85.2)	5 (83.3)	18 (85.7)	
30% to 49%	4 (14.8)	1 (16.7)	3 (14.3)	

P value by Fisher exact test or Wilcoxon-Mann-Whitney as appropriate. Numbers in parentheses are percentages. IQR indicates interquartile range; IV TPA, intravenous tissue plasminogen activator; MR, magnetic resonance; NIH, National Institutes of Health.

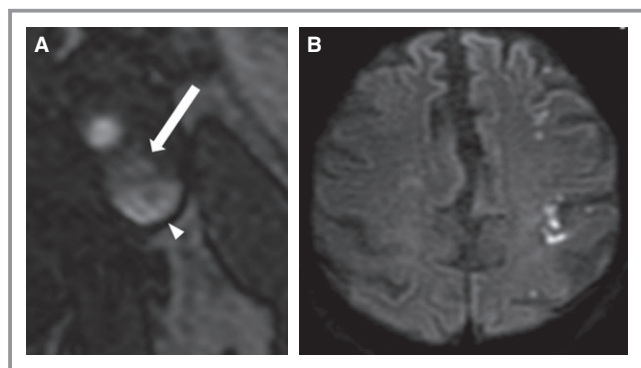


Figure. A, Axial 3D-time-of-flight source image demonstrates signal hyperintensity in the plaque (arrow) of a nonstenosing left-sided carotid artery plaque. The patent lumen (arrowhead) is clearly discriminated from the extraluminal high-intensity plaque on this and adjacent contiguous axial images. B, Axial diffusion-weighted imaging image shows evidence of high left-sided frontal and parietal acute infarctions in the same patient, including involvement of the cerebral cortex.

coefficient of 0.90 (95% CI: 0.70 to 1.00) (representative neck and brain images are shown in Figure). All 6 patients with IHIS-positive plaques had DWI-positive lesions involving the ipsilateral cerebral cortex, compared to 12 of the 21 patients (57.1%) without evidence of IHIS-positive plaque ($P=0.07$). Patients with IHIS-positive plaques were on average older than the cohort with IHIS-negative plaques (Table 1). Stroke severity measures, completeness of diagnostic evaluations, type of diagnostic evaluation, the prevalence of vascular risk factors, and the degree of ipsilateral and contralateral carotid stenosis did not differ between the IHIS-positive and IHIS-negative groups (Table 2).

In a sensitivity analysis excluding 2 subjects who had atrial fibrillation and therefore 2 or more potential causes of stroke, the prevalence of IHIS-positive plaque ipsilateral to stroke remained significantly higher than the prevalence contralateral to the side of stroke ($P=0.02$). Similarly, in a sensitivity analysis excluding the 6 cases performed on the 3 T magnet, the prevalence of IHIS-positive plaque ipsilateral to stroke remained significantly higher than in IHIS-negative plaque ($P=0.03$).

Discussion

Using data from a prospective inpatient ischemic stroke registry, we found that a MRA-defined plaque risk marker in nonhemodynamically stenosing carotid artery plaque (IHIS) was significantly more prevalent ipsilateral to the side of cryptogenic stroke compared to the side contralateral to the stroke. Those patients with and without plaque IHIS were not significantly different in terms of stroke severity, stroke diagnostic workups, or vascular risk factors. However, patients with plaque IHIS were older than those without IHIS, consistent with population-based epidemiologic data suggesting that complex atherosclerotic plaque elements increase in prevalence with age.^{17,18} Additionally, the NASCET degree of luminal narrowing was not significantly different between the ipsilateral and contralateral sides. Taken together, our data suggest that a subset of cryptogenic strokes may be caused by vulnerable carotid artery plaque in patients with plaque burden considered to be insignificant based on traditional luminal stenosis severity measures. In other words, embolization from large-artery atherosclerosis may occur even in the absence of hemodynamically significant internal carotid artery stenosis. Our data suggest that vulnerable carotid plaques likely cause some proportion of cryptogenic strokes, because current classification of stroke subtypes requires luminal stenosis of at least 50% in order to classify a stroke as being caused by large-artery atherosclerosis.

Our study's results are consistent with a prior report of carotid artery plaque composition specifically in cryptogenic stroke. In this study,⁸ investigators used a gadolinium-enhanced, multisequence protocol with a dedicated carotid coil and found that the presence of AHA type VI plaque in nonstenosing carotid artery plaque was significantly more prevalent on the side ipsilateral to the infarct in patients with cryptogenic stroke. It is interesting to note that when the ≈ 60 strokes of undetermined source in both studies are considered together, neither we nor Freilinger et al found a single case in which complicated nonhemodynamically stenosing carotid plaque was found contralateral to the side of cryptogenic stroke. Despite the consistency of our main

Table 2. Diagnostic Stroke Workups Stratified by the Presence of Intraplaque High-Signal Intensity in the Ipsilateral Internal Carotid Artery on MRA of the Neck

	Overall (N=27)	Abnormal High Signal in Plaque (N=6)	No Abnormal Signal in Plaque (N=21)	P Value
Echocardiogram obtained				1.000
Yes	25 (92.6)	6 (100.0)	19 (90.5)	
No	2 (7.4)	0 (0)	2 (9.5)	
Echocardiogram type				1.000
TTE	21 (87.5)	5 (100.0)	16 (84.2)	
TEE	3 (12.5)	0 (0)	3 (15.8)	
Intracranial and cervical cross-sectional (CTA or MRA) vascular imaging performed	27 (100.0)	6 (100.0)	21 (100.0)	1.000
Standard stroke labs obtained	27 (100.0)	6 (100.0)	21 (100.0)	1.000
>24 hours inpatient cardiac telemetry	27 (100.0)	6 (100.0)	21 (100.0)	1.000

P value by Fisher exact test. Numbers in parentheses are percentages. CTA indicates computed tomography angiography; MRA, magnetic resonance angiography; TEE, transesophageal echocardiogram; TTE, transthoracic echocardiogram.

findings, it is important to note that the Freilinger et al study evaluated features such as fibrous plaque rupture and luminal thrombus in addition to intraplaque hemorrhage. Though our plaque imaging technique may provide less detailed plaque characterization, there are several reasons why our approach might be more practical to implement in acute stroke patients: (1) our methodology does not require specialized MRI hardware (a carotid coil) and therefore can occur as part of the routine initial acute stroke workup rather than at a separate dedicated carotid plaque imaging session after stroke diagnosis is confirmed; (2) our assessment of IHIS can occur without the necessity of gadolinium injection and takes 3 minutes compared to \approx 18 minutes in the Freilinger et al multisequence protocol; (3) our risk marker is rapidly detectable on imaging (either present or absent) and does not require the more time-consuming assessment of multiple plaque tissue types; and (4) our method can be performed in all MRA studies, without any exclusions related to motion or other technically suboptimal studies, which are unavoidable in the imaging of acute stroke patients and can limit interpretability of multisequence high-resolution plaque imaging.

Given that many patients with known or suspected stroke are imaged at the time of presentation to the emergency department or other acute care setting, our study is particularly informative as it demonstrates that a simple MRA neck sequence historically used to assess for luminal stenosis also contains plaque risk information. Moreover, our plaque classification system (IHIS present or not) is highly reproducible with an inter-rater agreement of 98% and κ of 0.90 (95% CI, 0.70 to 1.00). Our interobserver reproducibility was higher in the current study compared to previous similar work in patients with high-grade carotid stenosis.¹⁴ One

possible reason for this difference in reproducibility is that there may be a lower prevalence of other advanced atherosclerotic features in 0% to 49% stenosis plaque compared with higher-grade stenosis, thereby potentially simplifying image analysis and reducing the risk of the false-positive assessments more likely to occur in the presence of ulceration, lipid, and other complicated plaque features. Similarly, an added benefit of this approach is that such a system does not require the more detailed plaque element assessment necessary in AHA plaque subtype classification for which fibrous cap rupture, intraplaque hemorrhage, or juxtaluminal hemorrhage/mural thrombus must be characterized.¹⁹ Our findings have face validity because extracting plaque information from 3D-TOF MRA source images has been shown in prior studies to be potentially useful in providing plaque risk stratification in patients with more substantial plaque burden.¹⁴ For example, in patients with high-grade proximal internal carotid artery stenosis, those with IHIS on routine MRA source images were 14 times more likely to have had symptomatic disease compared to those with high-grade stenosis and no IHIS.¹⁴

The dominant plaque element present in areas of IHIS on MRA images is most likely intraplaque hemorrhage, as several prior studies have shown a high correlation between high signal on MRA source images and intraplaque hemorrhage on histopathologic analysis.^{5,12,13} Such intramural hemorrhage likely induces a prothrombotic environment that may promote embolism formation.²⁰ The detection of intraplaque hemorrhage on MRI is possible with a wide range of techniques. The use of a dedicated carotid coil with a multisequence MRI test is one such approach, which has the advantages of excellent spatial resolution and a high signal-to-noise ratio.^{5,13} The

disadvantages of this method include the need for specialized equipment and extra time required for imaging and interpretation. An alternative strategy, which we used in our study, is based on the principle that intraplaque hemorrhage demonstrates hyperintensity greater than background skeletal muscle on T1-weighted images or images dependent on a tissue's T1 characteristics, such as TOF imaging.^{15,16,21} Using this principle, some studies have utilized a large field-of-view coronal gradient echo T1-weighted acquisition such as a 3D-magnetization prepared rapid acquisition gradient-echo sequences, which can allow for black blood imaging and can therefore provide increased conspicuity of plaque hemorrhage adjacent to the carotid lumen. Such an approach requires an extra ≈ 5 minutes of imaging time in addition to the sequences typically performed to characterize luminal stenosis. In our study, we extracted IHIS data (a surrogate for intraplaque hemorrhage) using 3D-TOF images alone and therefore used only imaging data that are commonly obtained at stroke care facilities that use extracranial MRA to evaluate acute stroke patients. The general benefit of this simpler approach is that plaque hemorrhage can be detected rapidly using larger field-of-view imaging without specialized equipment. Furthermore, studies have shown that such rapid techniques of plaque hemorrhage detection can predict future ischemic events with the same predictive strength as hemorrhage detected via the more detailed, carotid-coil-dependent techniques.^{5,6} Disadvantages of these simpler techniques, especially those without dedicated fat-suppression, is that the resulting decreased tissue discrimination and spatial resolution can make it more challenging to distinguish plaque hemorrhage from other high-risk plaque elements, perivascular fat, or small plaque ulcers.

Since our simplified plaque characterization technique lacks the specificity of a multisequence approach with dedicated MRI hardware, it is possible that IHIS may represent lipid-rich necrotic core, another component of complicated carotid atherosclerotic plaque that can demonstrate T1 shortening.²⁰ However, differentiating between intraplaque hemorrhage and lipid-rich necrotic core via carotid plaque imaging may not be clinically significant. For example, a recent meta-analysis showed that the presence of intraplaque hemorrhage or lipid-rich necrotic core as determined by carotid plaque MRI conferred similar future risk of ipsilateral stroke (≈ 3 - to 5-fold increased risk) in patients with carotid stenosis.⁵ Future studies may be helpful to assess whether multisequence carotid-coil-dependent plaque imaging adds additional information over standard MRA techniques that are more practical to perform in an acute stroke evaluation.

Our study has several limitations. First, although our clinical data collection was prospective, our classification of TOAST stroke subtypes was made retrospectively. We

attempted to minimize misclassification by relying on a team adjudication process by 3 vascular neurologists. Additionally, reviewing records after hospital discharge allowed for an assessment of TOAST subtype using more complete diagnostic evaluations, which continued into the outpatient setting. Second, in a small ($n=2$) subset of patients, more than 1 plausible cause of stroke was present, thereby limiting our ability to infer that stroke had occurred directly as a consequence of nonhemodynamically stenosing carotid plaque. However, our results were unchanged even after excluding these patients in sensitivity analysis. Third, the MRA neck studies that demonstrated complicated carotid plaque were performed after the index stroke and were read retrospectively by a blinded neuroradiologist. However, nearly all of our MRA neck studies occurred on the day of the acute infarction, and it is unlikely that plaque characteristics changed significantly in such a short interval of time, especially in light of epidemiologic data showing that in most patients, carotid plaque morphology does not significantly change over a 1-year period.²² Fourth, though we attempted to minimize the mischaracterization of perivascular fat and plaque ulcers as IHIS, further studies using black blood MRA techniques, which do not require a carotid coil, would be informative to assess whether alternative MRA techniques will yield similar results to our study and the Freilinger et al studies. Finally, our study has a small absolute sample size for which a formal power calculation was not performed in advance. Despite this, it is unlikely that the association between IHIS-positive plaques and cryptogenic stroke was due to chance ($P=0.01$). It is important to note that plaque hemorrhage is present in asymptomatic subjects, and that as a result, the association between IHIS-positive carotid plaque and ipsilateral infarcts does not prove that an IHIS-positive carotid plaque in a given patient is necessarily the cause of that patient's stroke. Future, appropriately powered prospective studies are now warranted to confirm our results and also to study the issue of stroke recurrence in this patient group. Furthermore, future research is necessary to assess whether careful patient selection using evaluation for high-risk carotid plaques would impart benefit to revascularization procedures in patients who are traditionally medically managed based on degree of luminal stenosis.²³

Conclusions

We have demonstrated that a simple, commonly performed, 3-minute MRA neck 3D-TOF imaging test can detect the presence of complicated but nonhemodynamically stenosing atherosclerotic plaque, which may explain the mechanism of some strokes currently classified as cryptogenic. Our results suggest that the routine assessment of plaque vulnerability is

possible using existing acute stroke MRI protocols and that such information might prospectively improve our ability to classify stroke etiology at the time of patient presentation.

Sources of Funding

Dr Gupta's effort was supported by an Association of University Radiologists-General Electric Radiology Research Award Fellowship and the Foundation of the American Society of Neuroradiology Scholar Award. Dr Kamel's effort was supported by grant K23NS082367 from the National Institute of Neurological Disorders and Stroke.

Disclosures

The authors report no disclosures pertaining to the work under consideration. Outside this work, Dr Kamel reports serving as a lecturer for Genentech on the subject of alteplase for acute ischemic stroke.

References

- North American Symptomatic Carotid Endarterectomy Trial Collaborators. Beneficial effect of carotid endarterectomy in symptomatic patients with high-grade carotid stenosis. *N Engl J Med*. 1991;325:445–453.
- Halliday A, Mansfield A, Marro J, Peto C, Peto R, Potter J, Thomas D; Group MRCACSTC. Prevention of disabling and fatal strokes by successful carotid endarterectomy in patients without recent neurological symptoms: randomised controlled trial. *Lancet*. 2004;363:1491–1502.
- Abbott AL. Medical (nonsurgical) intervention alone is now best for prevention of stroke associated with asymptomatic severe carotid stenosis: results of a systematic review and analysis. *Stroke*. 2009;40:e573–e583.
- Hirt LS. Progression rate and ipsilateral neurological events in asymptomatic carotid stenosis. *Stroke*. 2014;45:702–706.
- Gupta A, Baradaran H, Schweitzer AD, Kamel H, Pandya A, Delgado D, Dunning A, Mushlin AI, Sanelli PC. Carotid plaque MRI and stroke risk: a systematic review and meta-analysis. *Stroke*. 2013;44:3071–3077.
- Saam T, Hetterich H, Hoffmann V, Yuan C, Dichgans M, Poppert H, Koeppel T, Hoffmann U, Reiser MF, Bamberg F. Meta-analysis and systematic review of the predictive value of carotid plaque hemorrhage on cerebrovascular events by magnetic resonance imaging. *J Am Coll Cardiol*. 2013;62:1081–1091.
- Parmar JP, Rogers WJ, Mugler JP III, Baskurt E, Altes TA, Nandalur KR, Stukenborg GJ, Phillips CD, Hagspiel KD, Matsumoto AH, Dake MD, Kramer CM. Magnetic resonance imaging of carotid atherosclerotic plaque in clinically suspected acute transient ischemic attack and acute ischemic stroke. *Circulation*. 2010;122:2031–2038.
- Freilinger TM, Schindler A, Schmidt C, Grimm J, Cyran C, Schwarz F, Bamberg F, Linn J, Reiser M, Yuan C, Nikolaou K, Dichgans M, Saam T. Prevalence of nonstenosing, complicated atherosclerotic plaques in cryptogenic stroke. *JACC Cardiovasc Imaging*. 2012;5:397–405.
- Saver JL, Fonarow GC, Smith EE, Reeves MJ, Grau-Sepulveda MV, Pan W, Olson DM, Hernandez AF, Peterson ED, Schwamm LH. Time to treatment with intravenous tissue plasminogen activator and outcome from acute ischemic stroke. *JAMA*. 2013;309:2480–2488.
- Sacco RL, Kasner SE, Broderick JP, Caplan LR, Connors JJ, Culebras A, Elkind MS, George MG, Hamdan AD, Higashida RT, Hoh BL, Janis LS, Kase CS, Kleindorfer DO, Lee JM, Moseley ME, Peterson ED, Turan TN, Valderrama AL, Vinters HV. An updated definition of stroke for the 21st century: a statement for healthcare professionals from the American Heart Association/American Stroke Association. *Stroke*. 2013;44:2064–2089.
- Adams HP Jr, Bendixen BH, Kappelle LJ, Biller J, Love BB, Gordon DL, Marsh EE III. Classification of subtype of acute ischemic stroke: definitions for use in a multicenter clinical trial. TOAST. Trial of Org 10172 in Acute Stroke Treatment. *Stroke*. 1993;24:35–41.
- Qiao Y, Etesami M, Malhotra S, Astor BC, Virmani R, Kolodgie FD, Trout HH III, Wasserman BA. Identification of intraplaque hemorrhage on MR angiography images: a comparison of contrast-enhanced mask and time-of-flight techniques. *AJNR Am J Neuroradiol*. 2011;32:454–459.
- den Hartog AG, Bovens SM, Koning W, Hendrikse J, Luijten PR, Moll FL, Pasterkamp G, de Borst GJ. Current status of clinical magnetic resonance imaging for plaque characterisation in patients with carotid artery stenosis. *Eur J Vasc Endovasc Surg*. 2013;45:7–21.
- Gupta A, Baradaran H, Kamel H, Mangla A, Pandya A, Fodera V, Dunning A, Sanelli PC. Intraplaque high-intensity signal on 3D time-of-flight MR angiography is strongly associated with symptomatic carotid artery stenosis. *AJNR Am J Neuroradiol*. 2014;35:557–561.
- Hosseini AA, Kandiyil N, Macsweeney ST, Altaf N, Auer DP. Carotid plaque hemorrhage on MRI strongly predicts recurrent ischemia and stroke. *Ann Neurol*. 2013;73:774–784.
- Singh N, Moody AR, Gladstone DJ, Leung G, Ravikumar R, Zhan J, Maggisano R. Moderate carotid artery stenosis: MR imaging-depicted intraplaque hemorrhage predicts risk of cerebrovascular ischemic events in asymptomatic men. *Radiology*. 2009;252:502–508.
- van den Bouwhuijsen OJ, Vernooij MW, Hofman A, Krestin GP, van der Lugt A, Witteman JC. Determinants of magnetic resonance imaging detected carotid plaque components: the Rotterdam Study. *Eur Heart J*. 2012;33:221–229.
- Zhao XQ, Hatsukami TS, Hippe DS, Sun J, Balu N, Isquith DA, Crouse JR III, Anderson T, Huston J III, Polissar N, O'Brien K, Yuan C. Clinical factors associated with high-risk carotid plaque features as assessed by magnetic resonance imaging in patients with established vascular disease (from the AIM-HIGH Study). *Am J Cardiol*. 2014;114:1412–1419.
- Cai JM, Hatsukami TS, Ferguson MS, Small R, Polissar NL, Yuan C. Classification of human carotid atherosclerotic lesions with in vivo multicontrast magnetic resonance imaging. *Circulation*. 2002;106:1368–1373.
- Sary HC, Chandler AB, Dinsmore RE, Fuster V, Glagov S, Insull W Jr, Rosenfeld ME, Schwartz CJ, Wagner WD, Wissler RW. A definition of advanced types of atherosclerotic lesions and a histological classification of atherosclerosis: a report from the Committee on Vascular Lesions of the Council on Arteriosclerosis, American Heart Association. *Circulation*. 1995;92:1355–1374.
- Altaf N, MacSweeney ST, Gladman J, Auer DP. Carotid intraplaque hemorrhage predicts recurrent symptoms in patients with high-grade carotid stenosis. *Stroke*. 2007;38:1633–1635.
- Kwee RM, Truijman MT, van Oostenbrugge RJ, Mess WH, Prins MH, Franke CL, Korten AG, Wildberger JE, Kooi ME. Longitudinal MRI study on the natural history of carotid artery plaques in symptomatic patients. *PLoS One*. 2012;7:e42472.
- Barnett HJ, Taylor DW, Eliasziw M, Fox AJ, Ferguson GG, Haynes RB, Rankin RN, Clagett GP, Hachinski VC, Sackett DL, Thorpe KE, Meldrum HE, Spence JD. Benefit of carotid endarterectomy in patients with symptomatic moderate or severe stenosis: North American Symptomatic Carotid Endarterectomy Trial Collaborators. *N Engl J Med*. 1998;339:1415–1425.