

Original Article

Differential Expression of Ki-67 and P27 in Cholesteatoma Compared to Skin Tissue Predicts the Prognosis of Adult Acquired Cholesteatoma

Serkan Türkili¹, Kemal Görür², Onur İsmi², Ebru Serinsöz Linke³, Yusuf Vayisoğlu², Cengiz Özcan²

¹Clinic of Otorhinolaryngology, Mersin State Hospital, Mersin, Turkey

²Department of Otorhinolaryngology, Mersin University School of Medicine, Mersin, Turkey

³Department of Medical Pathology, Pathology and Molecular Diagnostic Institution, Augsburg, Germany

ORCID IDs of the authors: S.T. 0000-0001-7731-4583; K.G. 0000-0002-2147-4673; O.I. 0000-0001-5061-8907; E.S.L. 0000-0002-4216-5773; Y.V. 0000-0002-7132-1317; C.Ö. 0000-0001-7649-9782

Cite this article as: Türkili S, Görür K, İsmi O, Serinsöz Linke E, Vayisoğlu Y, Özcan C. Differential expression of Ki-67 and P27 in cholesteatoma compared to skin tissue predicts the prognosis of adult acquired cholesteatoma. *J Int Adv Otol*. 2021; 17(4): 306–312.

BACKGROUND: The aim of this study was to compare the differential Ki-67 and p27 staining properties of acquired cholesteatoma in adult patients for prognostic analysis.

METHODS: Forty-two adult patients with acquired cholesteatoma were enrolled. The cholesteatoma and matched meatal skin tissues of the patients were immunostained with Ki-67 and p27 antibodies. Canal wall down mastoidectomy was performed in all patients. The differential staining properties—positive staining in the cholesteatoma and negative staining in the skin tissue (C+S-), negative staining in the cholesteatoma and positive staining in the skin tissue (C-S+)—were compared for bone erosion scores (BES), stage, and recurrence rates.

RESULTS: Isolated findings in the cholesteatoma tissues, without matching with the skin tissues, demonstrated that stage and recurrence rates were not related to findings in the cholesteatoma tissues ($P > .05$). However, C+S- for Ki-67 and C-S+ for p27 are risk factors for worse prognosis including advanced stage ($P < .001$ for Ki-67 and $P = .008$ for p27), BES values ($P < .001$ for Ki-67 and $P = .001$ for p27), and recurrence rates ($P < .001$ for Ki-67 and $P = .037$ for p27).

CONCLUSION: This is the first paper assessing the cholesteatoma prognosis according to the differential Ki-67 and p27 staining properties of cholesteatoma and healthy skin tissues. Cellular proliferation rate in the cholesteatoma is important but insufficient by itself for predicting the prognosis of cholesteatoma patients. Patients having lower basal levels of cellular proliferation rate and higher cellular activity in the cholesteatoma tissue are prone to worse prognosis with increased stage, recurrence rates, and degree of bone erosion.

KEYWORDS: Cholesteatoma, Ki-67, p27, cellular proliferation, prognosis, stage, recurrence, bone erosion score

INTRODUCTION

Cholesteatoma is a progressive hyperplastic keratinized squamous epithelium of the temporal bone characterized by osteoclastic activity and bone resorption. It is composed of 3 compartments: a cystic part, a matrix, and a perimatrix. The central cystic part contains dead keratinocytes. It is surrounded by the matrix, and the most external compartment is the perimatrix. The active part of the cholesteatoma is the matrix, which harbors continuous proliferating undifferentiated keratinocytes. The perimatrix consists of fibroblasts and granulation tissue. As the central cystic part expands with continuous desquamation of the dead keratinocytes from the matrix, osteoclastic cascade reactions result in bone erosion. The bone erosion capability of the cholesteatoma can trigger extensive expansion and complications such as hearing loss, vestibular involvement, facial nerve paralysis, and even brain abscess and death.^{1,2} To date, the only definitive treatment of the cholesteatoma is surgery. Despite developing technology and the widespread use of endoscopes, recurrence and recidivism after surgery still exist as a major problem and various studies report rates of 0–70%.³

The underlying pathogenesis and molecular mechanisms of cholesteatoma have not been fully understood. Inflammatory cytokines including interleukin (IL)-1, IL-6, TNF- α , matrix metalloproteinases, imbalance between keratinocyte proliferation and apoptosis, Rho kinase pathway, genetic susceptibility, angiogenetic growth factors, platelet-derived growth factor, and chronic proceeding infections have all been reported to have a role in the cholesteatoma development.^{1,2,4,5} Nuclear antigen Ki-67 is a protein that is expressed in proliferating cells; thus, it is commonly used as a mitotic index for tumor grading.³ Increased Ki-67 expression in the basal and spinous layers of the cholesteatoma was also reported as showing the high proliferation property of keratinocytes in the cholesteatoma.⁶ Few studies^{3,7-15} have also investigated the Ki-67 labeling index for predicting the prognostic features of cholesteatoma. However, there is such a wide range of Ki-67 labeling indexes among healthy skin tissues of cholesteatoma patients, ranging from 0.9% to 24%.^{10,16} Moreover, a stronger expression of Ki-67 was also reported in the healthy skin tissue compared to the cholesteatoma tissue.¹⁵ Nonetheless, all these studies^{3,7-15} compared the Ki-67 labeling index of the cholesteatoma tissues obtained from different patients without matching the results with the healthy skin tissue (control group) of the same patient during comparison to predict the role of Ki-67 on the cholesteatoma prognosis.

Cyclin-dependent kinases are also involved in cell cycle and activate cellular proliferation, similar to Ki-67. P27 is the novel cyclin-dependent kinase inhibitor that acts as a tumor suppressor gene, arrests the cell cycle in phase G1, and stops cellular proliferation.^{17,18} A limited number of studies have focused on the effect of p27 on the cholesteatoma pathogenesis with conflicting results.¹⁶⁻¹⁸ Only one study¹⁸ investigated the role of p27 on recurrence of the cholesteatoma without matching the results with the skin tissue of the same patient. Additionally, to the best of the authors' knowledge, the role of p27 on extensiveness and bone erosion degree of the cholesteatoma has not been evaluated, yet.

In this study, we investigated the effect of Ki-67 and p27 on the extensiveness (stage), recurrence rate, and bone erosion score of adults' acquired cholesteatoma by matching the staining status of the markers in the cholesteatoma and healthy skin tissues of the same patients, immunohistochemically.

MATERIALS AND METHODS

Local ethical committee approval was acquired for this prospective study. The power analysis of the study was performed according to the previously published articles investigating the role of Ki-67 on the cholesteatoma pathogenesis. The result of the power analysis was 12 individuals in each group. Forty-two adults (>18 years old) patients with acquired cholesteatoma were enrolled. The diagnosis of the cholesteatoma was made by intraoperative and histopathological findings. All patients were operated under general anesthesia with a canal wall down mastoidectomy technique. Patients having recurrent disease at first admission and patients who had been operated with a canal wall-up technique were excluded. The cholesteatoma tissue and healthy meatal skin tissue (3 × 3 mm.) away from the cholesteatoma were obtained from all patients during the surgery. Healthy skin tissue was obtained as the control group for each patient.

Staging

According to the intraoperative and computerized tomography (CT) findings, all patients were staged according to the 2017 EAONO/JOS cholesteatoma staging system.¹⁹

Bone Erosion Score (BES)

The erosion status of the middle ear ossicles, scutum, facial nerve canal, tegmen tympani, and otic capsule were noted. Each patient was scored with a bone erosion score ranging from 0 to 12.⁷

Recurrence Rate

All patients were followed-up for a minimum of 5 years. Patients were examined in the third month, sixth month, and first year visits. Afterward, all patients were routinely examined at each 6-month interval for mastoid cavity control. Patients having perforation of the grafts, unexplained decrement in hearing, persistent otorrhea despite appropriate antibiotic usage, having and diffusion restriction on non-echo-planar diffusion-weighted magnetic resonance imaging were re-operated. According to the intraoperative findings and postsurgical histopathological evaluation results, the recurrence status of the patients was noted.

Immunohistochemistry

Paraffin-embedded cholesteatoma and meatal skin tissues were fixed with 10% formalin. Slices of 5 μ m thickness were prepared for immunohistochemical analysis. Deparaffinization of the slices was performed by xylene and alcohol solution washouts after overnight incubation at 37°C. Afterward, the slices were immunostained using Ki-67 monoclonal antibody and p27 antibody (Abcam® Ki-67 antibody, ab15580, Abcam® p27 antibody, ab193379).

The pathologist examined the cholesteatoma and skin tissues under the light microscope (Olympus BX53®, Olympus, Tokyo, Japan). A result of >25 of nuclear positively staining cells in the epithelium among 500 total cells (>5%) was regarded as positive staining^{15,17,18,20} (Figures 1 and 2).

Comparison of the Staining Properties of the Tissues

Firstly, the number of patients having positive and negative staining with Ki-67 and p27 in the cholesteatoma and skin tissues were compared among all patients. Secondly, only the cholesteatoma tissues of the patients were compared regarding the labeling status according to the subgroup of the patients (stage categories, recurrence rate status, and bone erosion scores). Thirdly, different from the previous studies, the differential staining properties of the patients were also considered by matching the cholesteatoma results with the results of the healthy skin tissues of the same patients.

Differential Staining Properties of the Patients

Each patient was classified into one of the 4 categories according to the staining by Ki-67 and p27 antibodies:

- Cholesteatoma-positive and skin-negative (C(+)/S(-)): Patient had positive staining in the cholesteatoma and negative staining in the skin tissue.
- Cholesteatoma-negative and skin-positive (C(-)/S(+)): Patient had negative staining in the cholesteatoma and positive staining in the skin tissue.

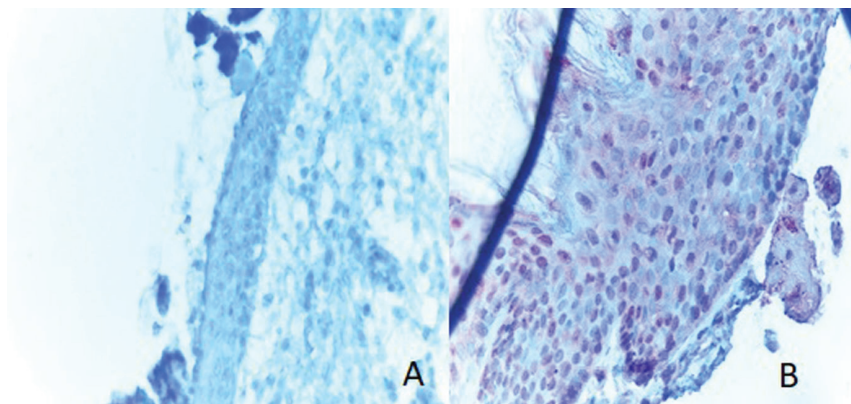


Figure 1. (A) The negative immunostaining by p27 in cholesteatoma (p27, $\times 400$). (B) The positive immunostaining by p27 in the meatal skin tissue (p27, $\times 400$).

- c. Cholesteatoma-positive and skin-positive (C(+)/S(+)): Patient had positive staining in both the cholesteatoma and the skin tissues.
- d. Cholesteatoma-negative and skin-negative (C(-)/S(-)): Patient had negative staining in both the cholesteatoma and the skin tissues.

Statistical Analysis

Statistical analysis was performed using SPSS Version 24.0 (IBM SPSS, New York, USA, 2016). Data were shown as mean \pm standard deviation for continuous variables and the number of cases was used for categorical variables. Data were controlled for normal distribution using the Shapiro–Wilk test. The chi-square test was employed for the comparison of the number of positive- and negative- staining tissues between patient groups. The Z test was used to compare the proportions of the number of patients according to the differential staining properties. In addition, the Mann–Whitney *U*-test was used to compare the mean BES of positive- and negative staining in the patients' cholesteatoma tissues. One-way analysis of variance test was used to compare the mean BES of the patients according to the differential staining status. A *P* value of $< .05$ was regarded as statistically significant.

RESULTS

There were 42 patients in the study group, of whom 27 (64.3%) were male and 15 (35.7%) were female. The mean age of the patients

was 40.73 ± 15.28 (min = 18, max = 65). The mean follow-up period was 66.69 ± 8.11 (min = 60, max = 96) months. Eight (19.04%) of the patients had cholesteatoma recurrence during the follow-up period. Ten (23.9%) patients had stage 1, 29 (69%) patients had stage 2, and 3 (7.1%) patients had stage 3 cholesteatoma, according to the intra-operative and CT findings. One patient had lateral semicircular canal fistula and 2 patients had facial nerve paralysis as intratemporal complications (stage 3). None of the patients had intracranial complications (stage 4 cholesteatoma).

Ki-67

Thirty-nine (92.8%) of the patients had Ki-67-positive staining in the cholesteatoma tissue, and 37 (88.1%) of the patients had Ki-67-positive staining in the meatal skin tissue. There was no statistically significant difference between cholesteatoma and skin tissues regarding the number of patients having Ki-67-positive staining ($P = .323$) (Figure 3).

There was no statistically significant difference between recurrent and non-recurrent patients regarding the number of

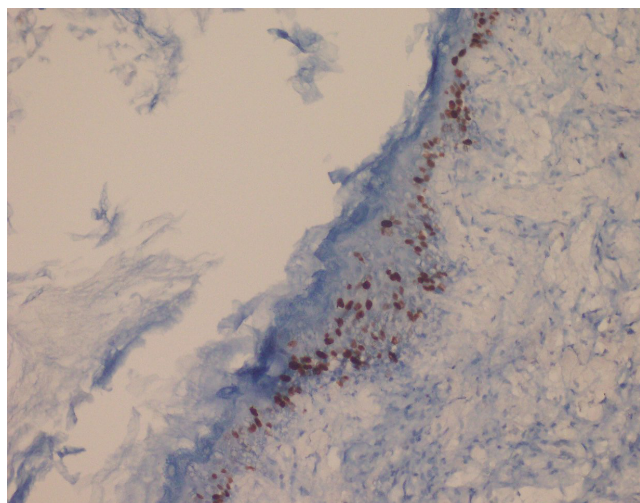


Figure 2. The positive immunostaining by Ki67 in the cholesteatoma (Ki67, $\times 400$).

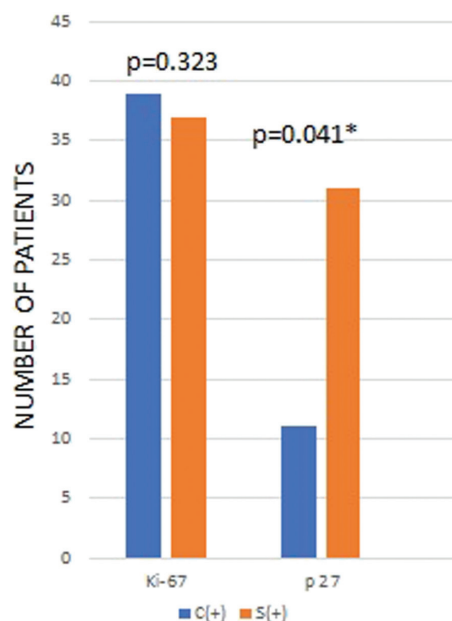


Figure 3. Comparison of the number of patients having positive staining with Ki-67 and p27 antibodies in the cholesteatoma and skin tissues. *Statistically significant. C, cholesteatoma; S, Skin tissue.

Table 1. Comparison of Differential Ki-67 Staining Properties of the Tissues According to the Recurrence Status

Recurrence Status	Differential Staining Properties of the Tissues				Total, n (%)	P
	C(+)/S(–), n (%)	C(+)/S(+), n (%)	C(–)/S(+), n (%)	C(–)/S(–), n (%)		
Recurrence (+)	4 (50)	4 (50)	0	0	8 (100)	<.01*
Recurrence (–)	0 (0)	31 (91.2)	2 (5.9)	1 (2.9)	34 (100)	

*Statistically significant.

C(+)/S(–), positive staining in the cholesteatoma tissue and negative staining in the skin tissue; C(+)/S(+), positive staining in the cholesteatoma and skin tissues; C(–)/S(+), negative staining in the cholesteatoma tissue and positive staining in the skin tissue; C(–)/S(–), negative staining in the cholesteatoma and skin tissues.

Table 2. Comparison of the Differential Ki-67 Staining Properties of the Tissues According to the Stage Categories

Cholesteatoma Stage	Differential Staining Properties of the Tissues				Total, n (%)	P
	C(+)/S(–), n (%)	C(+)/S(+), n (%)	C(–)/S(+), n (%)	C(–)/S(–), n (%)		
Stage 1	0 (0)	8 (80)	1 (10)	1 (10)	10 (100)	<.01*
Stage 2	1 (3.4)	27 (93.2)	1 (3.4)	0 (0)	29 (100)	
Stage 3	3 (100)	0 (0)	0 (0)	0 (0)	3 (100)	

*Statistically significant.

C(+)/S(–), positive staining in the cholesteatoma tissue and negative staining in the skin tissue; C(+)/S(+), positive staining in the cholesteatoma and skin tissues; C(–)/S(+), negative staining in the cholesteatoma tissue and positive staining in the skin tissue; C(–)/S(–), negative staining in the cholesteatoma and skin tissues.

positive Ki-67 staining in the patients' cholesteatoma tissue ($P = .383$). However, when the differential staining properties of the patients' tissues were further analyzed, there was a statistically significant difference regarding the number of patients according to the differential staining properties for Ki-67 ($P < .001$) (Table 1). The proportion of C(+)/S(–) patients was significantly higher in the recurrent group (4/8) compared to the non-recurrent group (0/34) (z value: 4.3347, $P < .001$).

There was no statistically significant difference among the stage groups regarding the number of patients having Ki-67-positive staining in the cholesteatoma tissue ($P = .19$). However, when the differential staining properties of the patients' tissues were additionally analyzed, there was a statistically significant difference regarding the number of patients according to the differential staining properties for Ki-67 ($P < .001$) (Table 2). The proportion of C(+)/S(–) patients was significantly higher in the stage 3 group (3/3) compared to the stage 1 group (0/10) (z value: 3.6056, $P = .0003$) and stage 2 group (1/29) (z value: 4.8138, $P < .01$).

The mean BES of the patients having positive and negative Ki-67 staining in the cholesteatoma tissue were 2 ± 0 and 2.2 ± 1.15 , respectively. There was no statistically significant mean BES difference between positive and negative Ki-67-staining in the patients' cholesteatoma tissue ($P > .05$). When the differential staining properties of the patients' tissues were further evaluated, the mean BES of C(+)/S(–), C(–)/S(+), C(+)/S(+) and C(–)/S(–) patients were 5 ± 0.81 , 2 ± 0 , 1.88 ± 0.63 and 2 ± 0 , respectively. C(+)/S(–) patients had higher BES values compared to the others ($P < .001$) (Figure 4).

P27

Eleven (26.2%) of the patients had p27-positive staining in the cholesteatoma tissue, and 31 (73.8%) of the patients had p27-positive staining in the meatal skin tissue. The number of patients having p27-positive staining in the meatal skin tissue was significantly higher compared to the number of patients having p27-positive staining in the cholesteatoma tissue ($P = .041$) (Figure 3).

It was observed that there was no statistically significant difference between recurrent and non-recurrent patients regarding the number of patients with positive p27-staining in the cholesteatoma tissue ($P = .657$). However, when the differential staining properties of the patients' tissues were further analyzed, there was a statistically significant difference regarding the number of patients according to the differential staining properties for p27 ($P < .001$) (Table 3). The proportion of C(–)/S(+) patients was significantly higher in the recurrent group (7/8) compared to the non-recurrent group (13/34) (z value: 2.51, $P = .012$).

There was no statistically significant difference among the stage groups regarding the number of patients having p27-positive staining in the cholesteatoma tissue ($P = .108$). However, when the

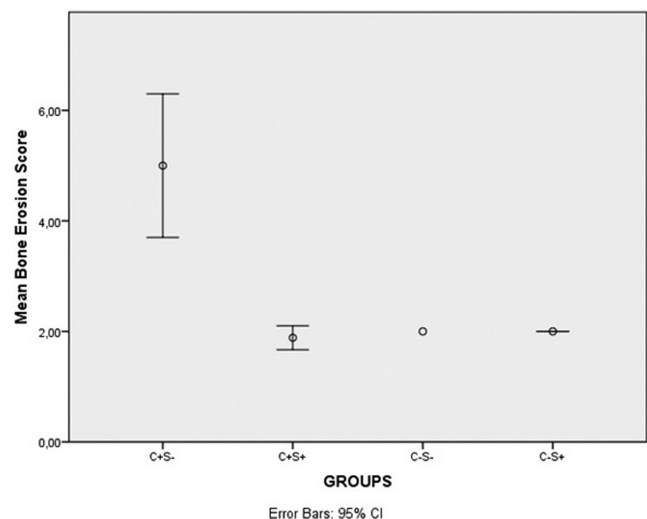


Figure 4. Comparison of bone erosion scores of the patients according to the differential staining properties with Ki-67 antibodies. C+S–, positive staining in the cholesteatoma tissue and negative staining in the skin tissue; C+S+, positive staining in the cholesteatoma and skin tissues; C–S–, negative staining in the cholesteatoma and skin tissues; C–S+, negative staining in the cholesteatoma tissue and positive staining in the skin tissue.

Table 3. Comparison of Differential p27 Staining Properties of the Tissues According to the Recurrence Status

Recurrence Status	Differential Staining Properties of the Tissues				Total, n (%)	P
	C(–)S(+), n (%)	C(+)S(+), n (%)	C(–)S(–), n (%)	C(+)S(–), n (%)		
Recurrence (+)	7 (87.5)	1 (12.5)	0 (0)	0 (0)	8 (100)	.037*
Recurrence (–)	13 (38.2)	10 (29.4)	11 (32.4)	0 (0)	34 (100)	

*Statistically significant.

C(–)S(+), negative staining in the cholesteatoma tissue and positive staining in the skin tissue; C(+)S(+), positive staining in the cholesteatoma and skin tissues; C(–)S(–), negative staining in the cholesteatoma and skin tissues; C(+)S(–), positive staining in the cholesteatoma tissue and negative staining in the skin tissue.

Table 4. Comparison of the Differential p27 Staining Properties of the Tissues According to the Stage Categories

Cholesteatoma Stage	Differential Staining Properties of the Tissues				Total, n (%)	P
	C(–)S(+), n (%)	C(+)S(+), n (%)	C(–)S(–), n (%)	C(+)S(–), n (%)		
Stage 1	0 (0)	5 (50)	5 (50)	0 (10)	10 (100)	.008*
Stage 2	17 (58.6)	6 (20.7)	6 (20.7)	0 (0)	29 (100)	
Stage 3	3 (100)	0 (0)	0 (0)	0 (0)	3 (100)	

*Statistically significant.

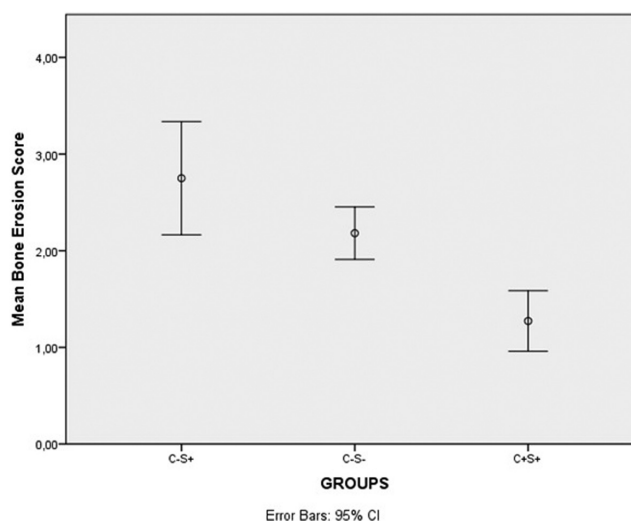
C(–)S(+), negative staining in the cholesteatoma tissue and positive staining in the skin tissue; C(+)S(+), positive staining in the cholesteatoma and skin tissues; C(–)S(–), negative staining in the cholesteatoma and skin tissues; C(+)S(–), positive staining in the cholesteatoma tissue and negative staining in the skin tissue.

differential staining properties of the tissues were analyzed, there was a statistically significant difference regarding the number of patients according to the differential staining properties for p27 ($P < .001$) (Table 4), and the proportion of C(–)S(+) patients was significantly higher in the stage 2 (17/29) (z value: -3.2236 , $P = .0012$) and the stage 3 patient groups (3/3) (z value: -3.6056 , $P = .0003$) compared to the stage 1 patient group (0/10).

The mean BES values of the patients having positive and negative p27 staining in the cholesteatoma tissues were 1.27 ± 0.46 and 2.54 ± 1.05 , respectively. Patients with negative staining had significantly higher BES values than patients with positive staining ($P < .001$). According to the differential staining properties of the patients' tissues, the mean BES values of C(–)S(+), C(–)S(–) and C(+)S(+) patients for p27 staining were 2.75 ± 1.25 , 2.18 ± 0.4 , 1.27 ± 0.46 , respectively. C(–)S(+) patients had significantly higher BES values compared to other groups, and C(–)S(–) patients had significantly higher BES values than C(+)S(+) patients ($P = .001$) (Figure 5).

DISCUSSION

In this study, we found that the number of patients having negative p27 staining in the cholesteatoma tissue was higher than for the staining in the skin tissue, however there was no significant difference with regard to the Ki-67 staining. The recurrence rates, stage, and BES values of the patients were not related to the Ki-67 staining status in the cholesteatoma tissues of the patients. However, differential expression of Ki-67 in the cholesteatoma tissue compared to the healthy skin tissue was related to a worse prognosis with increased recurrence rate, stage, and BES values. It was also observed that, negative p27 staining in the cholesteatoma tissue was only related to the elevated BES values; stage and recurrence rates of the cholesteatoma patients were not related to the p27 staining status in the cholesteatoma tissue. On the other hand, differential non-expression of p27 in the cholesteatoma tissue compared to the skin tissue was related to worse prognosis for cholesteatoma patients, such as increased recurrence rate, stage, and BES values.

**Figure 5.** Comparison of bone erosion scores of the patients according to the differential staining properties with p27 antibodies. C–S+, negative staining in the cholesteatoma tissue and positive staining in the skin tissue; C–S–, negative staining in the cholesteatoma and skin tissues; C+S+, positive staining in the cholesteatoma and skin tissues.

Proliferating undifferentiated keratinocytes in the matrix and activated fibroblasts in the perimatrix are the main cells in the cholesteatoma tissue that enhance progression. Uncontrolled proliferation of the keratinocytes initiates the vicious cycle; proliferating keratinocytes release cytokines that activate the perimatrix fibroblasts. Activated fibroblasts secrete epidermal growth factor and keratinocyte growth factor, which in turn activate the matrix keratinocytes in a vicious cycle. Osteoclastic molecules secreted from the proliferating keratinocytes and activated fibroblasts trigger the bone resorption and in turn the development of complications.^{1,21} Thus, cellular proliferation rate in the cholesteatoma tissue is an important factor for progression of the cholesteatoma.

Ki-67 nuclear antigen was demonstrated to be expressed in proliferating cells in the late G1, S, G2, and M phases of the cellular cycle. This

protein has been widely used as a proliferation marker for tumors and proliferative diseases including cholesteatoma.⁸ Most studies^{8-11,13,16,20,22} reported higher expression levels of Ki-67 protein in the cholesteatoma tissue compared to the healthy skin tissue. However, Kuczkowski et al.⁶ found an insignificant increase in Ki-67 expression in the cholesteatoma, and Kim et al.¹⁵ reported a strongly positive Ki-67 expression in the skin tissue compared to focal staining in the cholesteatoma tissue. Our results were also correlated with Kuczkowski et al.,⁶ with a slightly increased expression of Ki-67 in the cholesteatoma tissue compared to the skin tissue. When the effect of Ki-67 on the prognosis of cholesteatoma was evaluated, challenging results were reported. A higher Ki-67 labeling index in the cholesteatoma tissue was observed to be significantly related to the recurrence rate of the cholesteatomas.^{7,10} On the contrary, some studies^{3,14} could not find such a relationship. The bone erosion capacity of the cholesteatoma is an important prognostic factor that enables extension and complication development. Recently, Araz Server et al.³ found a correlation between the Ki-67 labeling index of cholesteatoma tissue and malleus erosion. Additionally, Hamed et al.⁸ reported a direct correlation between Ki-67 expression in the cholesteatoma and BES. On the other hand, several authors^{7,9,11,15} could not find a correlation between the Ki-67 expression levels in the cholesteatoma tissue and BES or extent of the disease. None of the aforementioned studies considered the Ki-67 skin-labeling status of the patients during prognostic analysis. According to our study results, differential Ki-67 staining in the cholesteatoma tissue compared to the skin tissue (C(+)/S(-)) affected the prognosis (recurrence rate, extensiveness-stage, and bone erosion capacity) rather than the isolated staining status in the cholesteatoma tissue. The controversial outcomes in the previous literature may be attributed to the wide range of basal Ki-67 expression in the skin tissue. Unmatched cholesteatoma-skin expression status might have caused conflicting results regarding the effect of Ki-67 on the cholesteatoma prognosis.

Cyclin-dependent kinase inhibitor p27 blocks cyclin D, E, A, and B-dependent kinases. Thus, the decrease in the levels of p27 is related to the increased cyclin-dependent kinase levels and enables ongoing cellular proliferation.¹⁶ Lower expression levels of p27 in the cholesteatoma tissue compared to the healthy skin tissue were reported as an evidence of higher cellular activity of the cholesteatoma.^{17,18} On the other hand, Chae et al.¹⁶ demonstrated an increased expression level of p27 in the cholesteatoma tissue. Regarding the prognostic value of p27 expression in the cholesteatoma tissue, Kuczkowski et al.¹⁸ reported a lower expression of p27 in the recurrent cases of cholesteatoma than the primary acquired ones, without matching the cholesteatoma-skin values. Additionally, the effect of p27-dependent cellular proliferation on other prognostic factors of cholesteatoma such as extensiveness (stage) and bone erosion levels have not been evaluated, yet. According to our study results, the number of patients having negative p27 staining was greater in the cholesteatoma tissue compared to skin tissue, demonstrating the increased cellular proliferation of the cholesteatoma. Moreover, differential non-expression of p27 in the cholesteatoma tissue compared to skin tissue (C(-)/S(+)) was a prognostic factor for cholesteatoma with increased stage, recurrence rate, and BES values. Combining the results of p27 with Ki-67, we can say that every cholesteatoma patient has a basal cellular proliferation activity rate in the meatal skin. Cellular proliferation rate in the cholesteatoma

is important but not solely enough for predicting the prognosis of cholesteatoma patients. Patients having lower basal levels of cellular proliferation rate and higher cellular activity in the cholesteatoma tissue are prone to worse prognosis with increased stage, recurrence rates, and bone erosion degrees.

The limitation of this study was the limited patient number. Future studies with a higher number of patients should also investigate the role of Ki-67 and p27 on cholesteatoma prognosis by comparing each patient's cholesteatoma results with the healthy skin tissue results. However, we think that our results are meaningful and can lead future studies with our long interval (minimum 60 months) follow-up period for the detection of cholesteatoma recurrence.

In conclusion, the differential expression of Ki-67 and non-expression of p27 in the cholesteatoma tissue compared to the healthy skin tissue were associated with worse prognosis, including increased otitis media, with increased cholesteatoma stage, recurrence rate, and bone erosion degree for the cholesteatoma patients. With upcoming studies, Ki-67- and p27-targeted topical treatment options may be enhanced to prevent the growing and expansion of the cholesteatoma. Considering the future studies that will evaluate the effect of cellular proliferation on cholesteatoma progression, it would be more logical to analyze the basal levels of cellular proliferation rates for each patient and to match the results of cholesteatoma tissues with the healthy skin tissues for predicting the prognosis.

Ethical Committee Approval: Local Ethical committee approval was acquired for the current study.

Informed Consent: Written informed consent was taken from all patients who participated in the study.

Peer-review: Externally peer-reviewed.

Author Contributions: Concept – S.T., K.G., O.İ., E.S.L., Y.V., C.Ö.; Design – S.T., K.G., O.İ., E.S.L., Y.V., C.Ö.; Supervision – S.T., K.G., O.İ., E.S.L., Y.V., C.Ö.; Funding – S.T., K.G., O.İ., E.S.L., Y.V., C.Ö.; Materials – S.T., K.G., O.İ., E.S.L., Y.V., C.Ö.; Data Collection and/or Processing – S.T., K.G., O.İ., E.S.L., Y.V., C.Ö.; Analysis and/or Interpretation – S.T., K.G., O.İ., E.S.L., Y.V., C.Ö.; Literature Review – S.T., K.G., O.İ., E.S.L., Y.V., C.Ö.; Writing – S.T., K.G., O.İ., E.S.L., Y.V., C.Ö.; Critical Review – S.T., K.G., O.İ., E.S.L., Y.V., C.Ö.

Acknowledgments: The authors thank to Rabia Bozdoğan Arpacı for interpretation of the pathological figures.

Conflict of Interest: The authors have no conflict of interest to declare.

Financial Disclosure: The authors declared that this study has received no financial support.

REFERENCES

- Yeşilova M, Görür K, İsmi O, Özcan C, Büyükaşar K. The role of Rho/Rho-kinase pathway in the pathogenesis of cholesteatoma. *Otol Neurotol*. 2017;38(4):516-520.
- İsmi O, Karabulut YY, Bal KK, Vayisoglu Y, Unal M. Single dose intratympanic mesna application inhibits propylene glycol induced cholesteatoma formation. *J Laryngol Otol*. 2017;131(3):215-220.

3. Araz Server E, Kalaycık Ertugay Ç, Baykal Koca S, et al. Predictive role of Ki-67 and Proliferative-cell nuclear antigen (PCNA) in recurrent cholesteatoma. *J Int Adv Otol*. 2019;15(1):38-42.
4. Kuo CL. Etiopathogenesis of acquired cholesteatoma: prominent theories and recent advances in biomolecular research. *Laryngoscope*. 2015;125(1):234-240.
5. Hamed MA, Nakata S, Sayed RH, et al. Pathogenesis and bone resorption in acquired cholesteatoma: current knowledge and future perspectives. *Clin Exp Otorhinolaryngol*. 2016;9(4):298-308.
6. Kuczkowski J, Pawelczyk T, Bakowska A, Narozny W, Mikaszewski B. Expression patterns of Ki-67 and telomerase activity in middle ear cholesteatoma. *Otol Neurotol*. 2007;28(2):204-207.
7. Aslier M, Erdag TK, Sarioglu S, et al. Analysis of histopathological aspects and bone destruction characteristics in acquired middle ear cholesteatoma of pediatric and adult patients. *Int J Pediatr Otorhinolaryngol*. 2016;82:73-77.
8. Hamed MA, Nakata S, Shiogama K, et al. Cytokeratin 13, cytokeratin 17, and Ki-67 expression in human acquired cholesteatoma and their correlation with its destructive capacity. *Clin Exp Otorhinolaryngol*. 2017;10(3):213-220.
9. Lee SH, Jang YH, Tae K, et al. Telomerase activity and cell proliferation index in cholesteatoma. *Acta Otolaryngol*. 2005;125(7):707-712.
10. Yamamoto-Fukuda T, Aoki D, Hishikawa Y, et al. Possible involvement of keratinocyte growth factor and its receptor in enhanced epithelial-cell proliferation and acquired recurrence of middle-ear cholesteatoma. *Lab Invest*. 2003;83(1):123-136.
11. Akdogan V, Yilmaz I, Canpolat T, Ozluoglu LN. Role of Langerhans cells, Ki-67 protein and apoptosis in acquired cholesteatoma: prospective clinical study. *J Laryngol Otol*. 2013;127(3):252-259.
12. Harabagiu OE, Cosgarea M, Mogoantă CA, Leucuța DC, Maniu AA. Keratinocyte growth factor and its receptor expression in chronic otitis media with and without cholesteatoma. *Rom J Morphol Embryol*. 2017;58(4):1333-1338.
13. Albino AP, Reed JA, Bogdany JK, et al. Expression of p53 protein in human middle ear cholesteatomas: pathogenetic implications. *Am J Otol*. 1998;19(1):30-36.
14. Sanlı A, Tezer I, Paksoy M, et al. Evaluation of Ki-67 expression in recurrent cases of cholesteatoma. *Kulak Burun Bogaz Ihtis Derg*. 2007;17(2):65-69.
15. Kim KH, Lim HJ, Kim YJ, et al. The oncoprotein, gankyrin, is up-regulated in middle ear cholesteatoma. *Acta Otolaryngol*. 2014;134(3):238-243.
16. Chae SW, Song JJ, Suh HK, et al. Expression patterns of p27Kip1 and Ki-67 in cholesteatoma epithelium. *Laryngoscope*. 2000;110(11):1898-1901.
17. Bayazıt YA, Karakök M, Uçak R, Kanlıkama M. CyclinE-dependent kinase inhibitor, p27(KIP1), is associated with cholesteatoma. *Laryngoscope*. 2001;111(6):1037-1041.
18. Kuczkowski J, Bakowska A, Pawelczyk T, Narozny W, Mikaszewski B. Cell cycle inhibitory protein p27 in human middle ear cholesteatoma. *ORL J Otorhinolaryngol Relat Spec*. 2006;68(5):296-301.
19. Yung M, Tono T, Olszewska E, et al. EAONO/JOS joint consensus statements on definitions, classification and staging of middle ear cholesteatoma. *J Int Adv Otol*. 2017;13(1):1-8.
20. Ergün S, Zheng X, Carlsöö B. Antigen expression of epithelial markers, collagen IV and Ki67 in middle ear cholesteatoma: an immunohistochemical study. *Acta Otolaryngol*. 1994;114(3):295-302.
21. Kuo CL, Shiao AS, Yung M, et al. Updates and knowledge gaps in cholesteatoma research. *BioMed Res Int*. 2015;2015:854024.
22. Chung JH, Lee SH, Park CW, et al. Expression of apoptotic vs antiapoptotic proteins in middle ear cholesteatoma. *Otolaryngol Head Neck Surg*. 2015;153(6):1024-1030.