



ELSEVIER

Available online at www.sciencedirect.com

ScienceDirect

journal homepage: www.elsevier.com/locate/radcr

Case report

Amyand's hernia: presumptive diagnosis by CT and literature review ☆,☆☆

Georgia Fezoulidi, MD^a, Vasiliki Argyrouli, MD^b, Evaggelos Adamopoulos, MD^c,
Konstantinos G. Makridis, MD, MSc, PhD^{d,*}, Stamatina-Emmanouela Zourntou, MD, MSc^e,
Ioannis V. Fezoulidis, MD, PhD^{b,f}

^a Medical Student, Faculty of Medicine, University of Thrace, Alexandroupolis, Greece

^b Radiologist, Department of Radiology, IASO Thessaly, Larissa, Greece

^c Department of Internal Medicine, IASO Thessaly, Larissa Greece

^d Director of Robotic Orthopedic Surgery, IASO Thessaly, Larissa Greece

^e Resident in General Surgery, General Hospital of Larissa, Greece

^f Faculty of Medicine, University of Thessaly, Larissa, Greece

ARTICLE INFO

Article history:

Received 1 November 2020

Revised 26 January 2021

Accepted 28 January 2021

Keywords:

Amyand's hernia

Inguinal hernia

Computed Tomography

Appendix

ABSTRACT

Amyand's hernia is a rare inguinal hernia containing the appendix presenting mainly in male adults. The clinical presentation is usually without symptoms, however an inflammation can occur leading to strangulation, necrosis or rupture of the appendix. Differential diagnosis may be difficult including orchitis, testicular torsion, inflammation of the ovaries and bowel inflammation.

We present a case of a 61 years old, male patient who was presented with persistent right abdominal pain. There was no medical history of previous hospitalization or surgery of the abdomen. Laboratory tests and radiological investigation with plain radiographs and ultrasound were not clear. A CT scan with contrast imaging was performed to reveal the diagnosis.

Amyand's hernia is difficult to be revealed and a high index of suspicion is needed in order to promptly diagnose the hernia and proceed to the appropriate treatment. CT scan is critical contributing to the accurate depiction and to the classification of the hernia.

© 2021 The Authors. Published by Elsevier Inc. on behalf of University of Washington.

This is an open access article under the CC BY-NC-ND license (<http://creativecommons.org/licenses/by-nc-nd/4.0/>)

☆ This research did not receive any specific grant from funding agencies in the public, commercial, or not-for-profit sectors.

☆☆ Competing Interest: The authors declare no conflict of interest.

* Corresponding author.

E-mail address: kmakrid@yahoo.gr (K.G. Makridis).

<https://doi.org/10.1016/j.radcr.2021.01.057>

1930-0433/© 2021 The Authors. Published by Elsevier Inc. on behalf of University of Washington. This is an open access article under the CC BY-NC-ND license (<http://creativecommons.org/licenses/by-nc-nd/4.0/>)

Introduction

An inguinal hernia containing the vermiform appendix is defined as Amyand's hernia. It was first described in 1735 by Dr. Claudius Amyand who was also the first surgeon to perform appendectomy [1].

Different types have been described classifying the incarcerated appendix as normal, inflamed, or perforated [2]. According to the literature, Amyand's hernia is a rare finding with an incidence of about 0,4% - 1% of inguinal hernias [3], while appendicitis involving an Amyand's hernia accounts for 0,1% of all cases of appendicitis [4].

The clinical presentation is usually without symptoms, however an inflammation can occur leading to strangulation, necrosis or rupture of the appendix. Differential diagnosis may be difficult including orchitis, testicular torsion, inflammation of the ovaries and bowel inflammation. A high index of suspicion is needed to promptly diagnose the hernia using laboratory tests and imaging techniques. Ultrasound of the abdomen is the first option for the diagnostic imaging, however a CT scan can accurately identify the hernia and guide the decision for a conservative or surgical treatment [1,3,5,6].

We present a case of a 61-year-old male patient suffering from a noninflamed Amyand's hernia which was diagnosed using CT scan. We also proceed to a review on the epidemiology, pathophysiology, imaging techniques, and treatment options of this rare entity.

Presentation of the case

A 61-year-old male patient presented to our hospital due to a persistent diffused abdominal pain. According to his medical history, no chronic disease was reported except for a palpable mass located on the right inguinal region which was diagnosed during the last year. Surgical history included only a colorectal polyp that was revealed at routine colonoscopy 2 years ago. Excision was performed and the histological analysis confirmed the absence of malignancy. The professional activities of the patient included heavy – weight lifting daily. The patient had no fever and laboratory tests was normal apart from a slightly elevated erythrocyte sedimentation rate. Physical examination showed a non-reducible right inguinal mass with slight pain during the reduction manoeuvre.

The ultrasound of the abdomen was not clear due to air artifacts, thus a CT scan of the abdomen and pelvis was performed with intravenous administration of iodized contrast agent. The axial, coronal and sagittal views revealed the Amyand hernia with normal appearance of the appendix and with no obvious signs of inflammation (Fig. 1, Fig. 2, Fig. 3). A small left inguinal hernia containing fat was also seen with no pathological signs. CT scan showed no other obvious findings of bowel irritation.

According to the clinical and radiological findings, the Amyand's hernia was classified as type 1 (normal appendix). A conservative treatment was decided with occasional administration of non-steroidal anti-inflammatory drugs and routine

Table 1 – Losanoff and Basson classification of Amyand's hernia.

Type 1	appendix is normal
Type 2	acute appendicitis and limited inflammation within the hernia
Type 3	Big Hernia needing repair
Type 4	acute appendicitis within the inguinal hernia and related or unrelated abdominal pathology

follow-up appointments every 6 months. No further complication was recorded.

A written, informed consent for publication of the case was obtained from the patient.

Discussion

Amyand's hernia is a rare condition characterized by the presence of the appendix within an inguinal hernia sac. The presence of an inflamed appendix inside the inguinal hernia is far rare with an incidence of 0.07%-0.13% [7].

The ideal profile of the patient with an Amyand's hernia is a male subject, over 60 years old with a right sided mass (either palpable or not) [8,9,10]. However, some studies have reported the existence of this type of hernia in children with a prevalence of 1% [2,4]. The patient in our case had all the characteristics of this profile and in his medical history there was no previous pathology of the bowel, intestine or other abdominal organ. The right sided prevalence it is definitely justified by the normal anatomical position of the appendix [9,10], although it has been reported on the literature left sided hernias in cases with anatomical variations such as situs inversus, intestinal malrotation and mobile cecum [11].

The pathophysiology of Amyand's hernia is not clear. Michalinos et al suggested that it may result from the coexistence of a patent vaginal process and a fibrous connection between the appendix and the testis [4]. Congenital laxity of the right colon is another proposed theory [12]. There is no clear causal relationship between appendicitis and Amyand's hernias, although an explanation could be that inflammatory swelling of the appendix may lead to its incarceration [13].

Non-complicated Amyand's hernias are either asymptomatic or present with non-specific symptoms. Right lower quadrant tenderness and inguinal swelling may be present, which usually indicate an inguinal hernia. In the case of an inflamed appendix, the condition might mimic orchitis or testicular torsion [14]. As a result, the diagnosis of the Amyand's hernia is difficult and the definite management either conservative or surgical is challenging. According to the literature, only 1 of 60 of the cases have been diagnosed preoperatively and the majority of them are discovered intraoperatively [15]. Therefore, the accurate diagnosis is important in order to provide the best treatment option and to ensure that a diagnostic laparotomy will not be an unnecessary procedure [14].

In 2007, Losanoff and Basson [9] divided Amyand's hernia into 4 types proposing recommendations for the optimal management [Table 1]. In Type 1, the appendix is normal and her-

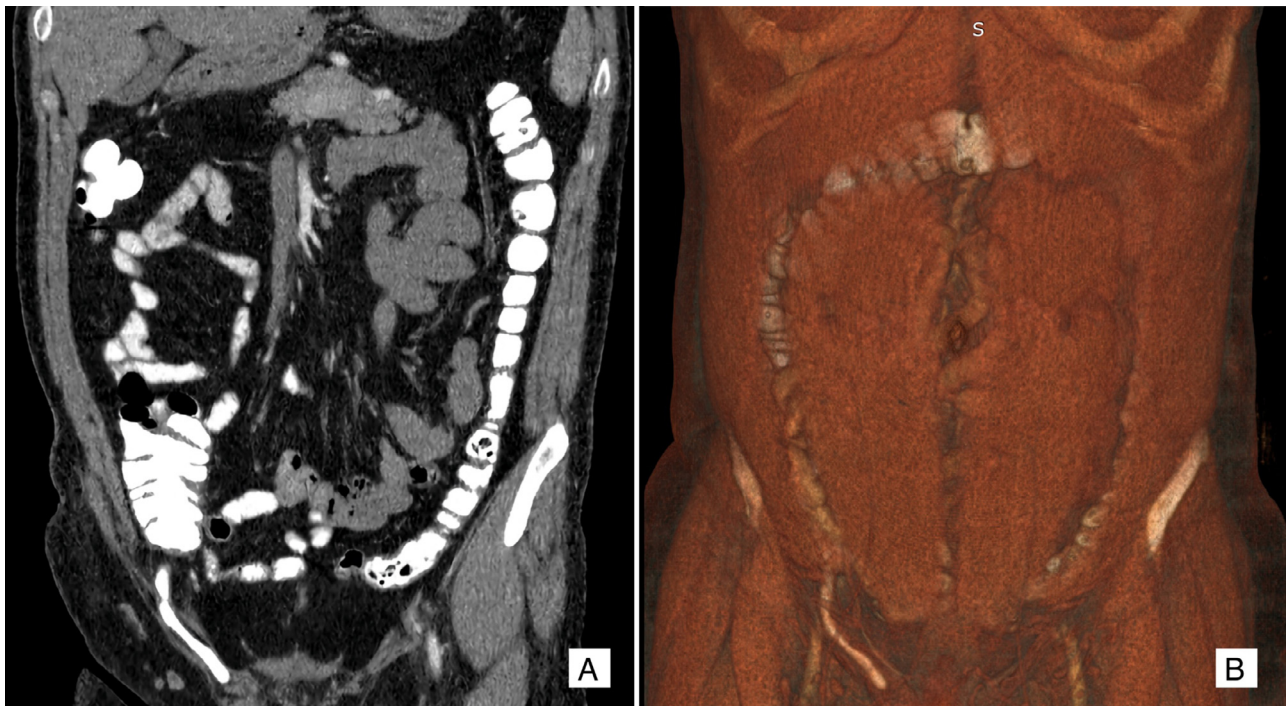

Fig. 1 - A. Coronal MPR and B. Coronal 3D shows the normal appendix within the right inguinal hernia.

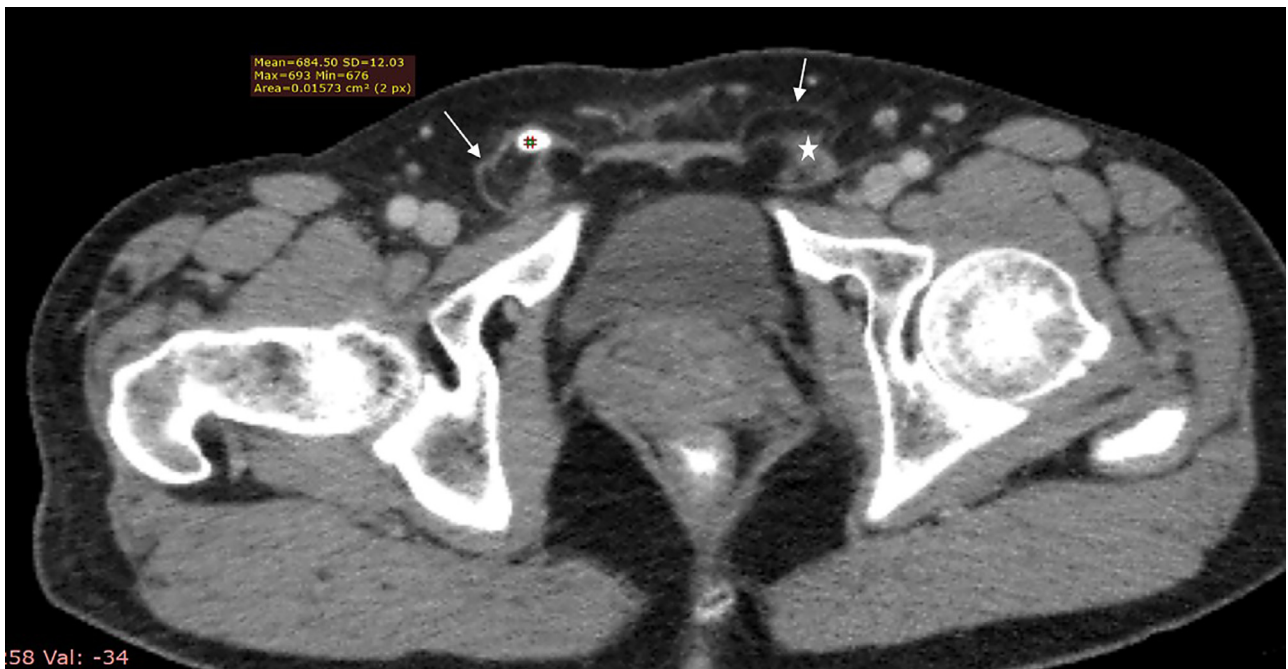

Fig. 2 - MDCT of the abdomen - MPR: At the axial plane (A) At the left side the normal spermatic cord (asterisk) is seen inside the inguinal canal (arrow). At the right side the appendix (open arrow) is seen filled with p.o. contrast agent (684,5 HU) inside the inguinal canal (arrow).

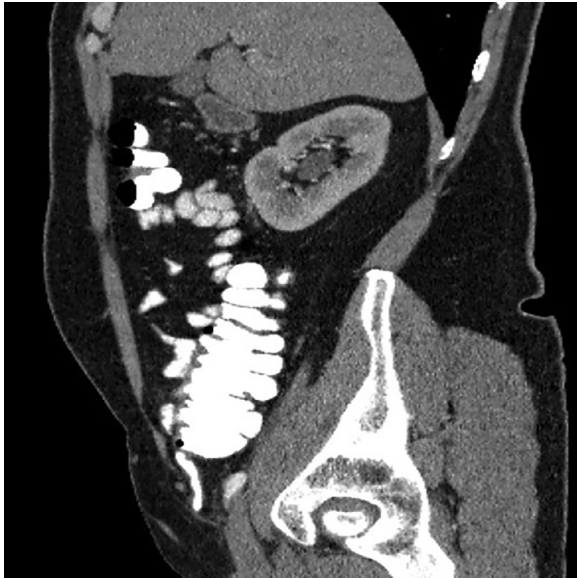


Fig. 3 – MDCT of the abdomen – MPR: At the sagittal plane (B) the appendix filled with p.o. contrast medium (open arrow) is seen inside the inguinal canal (arrow).

nia reduction or mesh repair is recommended. In younger patients, appendectomy is performed to avoid the risk of subsequent appendicitis. Type 2 is associated with acute appendicitis and limited inflammation within the hernia. Appendectomy and primary repair are usually performed, whereas mesh repair is not recommended. Acute appendicitis within the hernia or abdominal wall, and/or peritonitis are described in Type 3 Amyand's hernias, which are treated through laparotomy, appendectomy, and primary repair (mesh repair is again not recommended). Finally, Type 4 is presented with acute appendicitis within the inguinal hernia and a related or unrelated abdominal pathology. These cases are managed as Type 1-3 hernias and the second condition is investigated or treated as appropriate. The treatment and surgical approach depend on the patient's age, life expectancy and risk of developing acute appendicitis. Therefore, the treatment of Amyand's hernia depends on the state of the appendix, the Losanoff classification and the age of the patient.

The widespread use of CT and ultrasound increase the possibility of an accurate diagnosis. Ultrasound is mainly used in the pediatric population. Although sometimes it may fail to identify the appendix inside the inguinal hernia, can depict a blind-ending appendix inside the hernia sac on the hands of an experienced radiologist. Depending on whether or not inflammation is present, appendix wall thickening or stranding of the surrounding fat tissue may appear [3]. Applying modern techniques of the ultrasound such as transvaginal pelvic sonography (in women), color and pulsed Doppler and 3D sonography, the ultrasound could be a valuable diagnostic tool [16].

Unlike ultrasound, CT scan of the abdomen is more sensitive and specific as it allows direct visualization of the appendix inside the inguinal canal. However, since CT is not routinely performed as a first step evaluation tool of an inguinal hernia, diagnosis of Amyand's hernia is usually made

Table 2 – Constantine classification of Amyand's hernia.

Type 1	appendix is normal
Type 2	enlarged and thickened appendix with inflammation of the surrounding fat
Type 3	excessive inflammatory changes are present, which could obscure the appendix
Type 4	related to other intra-abdominal findings

incidentally during abdominal CT scan that is performed for another purpose. CT has been frequently used in diagnosing Amyand's hernia in many cases showing a blind-ending tubular appendix arising from the caecum to enter the inguinal canal [17]. Coronal and sagittal reformats are particularly useful in the diagnosis and administration of contrast material is critical.

According to the Losanoff and Basson classification, Constantine et al [2] illustrated 4 subtypes of Amyand's hernia by abdominal CT [Table 2]. In Type 1, the appendix appears normal, and diagnosis can be overlooked. An enlarged and thickened appendix with inflammation of the surrounding fat is found in Type 2, where the diagnosis of an Amyand's hernia is obvious. In Type 3, diagnosis is difficult as excessive inflammatory changes are present, which could obscure the appendix and may extend intra-abdominal. Finally, Type 4 is related to other intra-abdominal findings. CT scan is especially useful in the diagnosis of Type 3 and 4. In our case, the Amyand's hernia was classified as Type 1 and no surgical procedure was performed as there were no signs of appendix inflammation.

Conclusions

Amyand's hernia is a rare condition that can be life-threatening if remains undiagnosed. Therefore, a high index of suspicion is needed and the use of specific diagnostic protocols must be applied. CT scan of the abdomen with contrast material must be the gold standard diagnostic approach, leading to a prompt and accurate diagnosis and decreasing the risks of a misdiagnosis. The 3-dimensional depiction of the position and condition of the appendix can help the surgeon to classify the hernia, differentiate any other abdominal pathology and decide the best treatment outcome for the patient.

Authors contribution

G. F.: manuscript writing; V. A.: data collection; E. A.: project development; K.G.M.: manuscript writing; SE Z.: manuscript editing; I.V. F.: manuscript editing.

REFERENCES

- [1] Amyand C. Of an inguinal rupture, with a pin in the appendix coeci, incrusted with stone; and some observations on wounds in the guts. *Philos Transact Royal Soc Lond* 1736;39(436–444):329–42.

- [2] Constantine S. Computed tomography appearances of Amyand hernia. *J Comput Assist Tomogr* 2009;33:359–62. doi:10.1097/RCT.0b013-3181837fd9.
- [3] Sharma H, Gupta A, Shekhawat NS, et al. Amyand's hernia: a report of 18 consecutive patients over a 15-year period. *Hernia* 2007;11(1):31–5. doi:10.1007/s10029-006-0153-8.
- [4] Michalinos A, Moris D, Vernadakis S. Amyand's hernia: a review. *Am. J. Surg.* 2014;207(6):989–95. doi:10.1016/j.amjsurg.2013.07.043.
- [5] Akaishi R, Nishimura R, Naoshima K, et al. Amyand's hernia complicated with appendix perforation treated by two-stage surgery consisting of laparoscopic appendectomy followed by elective inguinal hernioplasty: a case report. *Int J Surg Case Rep* 2018;47:11–13. doi:10.1016/j.ijscr.2018.04.019.
- [6] Mullinax JE, Allins A, Avital I. Laparoscopic appendectomy for Amyand's hernia: a modern approach to a historic diagnosis. *J. Gastrointest. Surg.* 2011;15(3):533–5. doi:10.1007/s11605-010-1386-5.
- [7] Guler I, Alkan E, Nayman A, et al. Amyand's Hernia: Ultrasonography Findings. *J Emerg Med* 2016;50:15–17. doi:10.1016/j.jemermed.2015.07.042.
- [8] Resorlu M, Aylanç N, Karatag O, et al. Amyand's hernia detected incidentally in two patients. *BMJ Case Rep* 2017;bcr2017221837. doi:10.1136/bcr-2017-221837.
- [9] Losanoff JE, Basson MD. Amyand hernia: what lies beneath - a proposed classification scheme to determine management. *Am Surg* 2007;73(1):1288 PMID:18186392 .
- [10] Singal R, Mittal A, Gupta A, et al. An incarcerated appendix: report of three cases and a review of the literature. *Hernia* 2012;16(1):91–7. doi:10.1007/s10029-010-0715-7.
- [11] Johari HG, Paydar S, Davani SZ, et al. Left-sided Amyand hernia. *Ann Saudi Med* 2009;29:321–2. doi:10.4103/0256-4947.55305.
- [12] Ranganathan G, Kouchupapy R, Dias S. An approach to the management of Amyand's hernia and presentation of an interesting case report. *Hernia* 2011;15(1):79–82. doi:10.1007/s10029-009-0609-8.
- [13] Bhide SS. Amyand's hernia. *Indian J Pediatr* 2009;76(8):854–5. doi:10.1007/s12098-009-0173-3.
- [14] Ivanschuk G, Cesmebasi A, Sorenson EP, et al. Amyand's hernia: a review. *Med Sci Monit.* 2014;28:140–6. doi:10.12659/MSM.889873.
- [15] Apostolidis S, Papadopoulos V, Michalopoulos A, et al. Amyands hernia: a case report and review of literature. *The Internet Journal of Surgery* 2005;6:1 article.
- [16] Chanana C, Gupta N, Bansal I, et al. Different Sonographic Faces of Ectopic Pregnancy. *J Clin Imaging Sci.* 2017;20(7):6. doi:10.4103/jcis.
- [17] Luchs JS, Halpern D, Katz DS. Amyand's hernia: prospective CT diagnosis. *J Comput Assist Tomogr.* 2000;24:884–6. doi:10.1097/00004728-200011000-00011.