

## Single Case

---

# Laparoscopic Surgery for Intestinal Obstruction Caused by an Internal Paracecal Hernia

Tran Que Son<sup>a, b</sup> Tran Hieu Hoc<sup>a</sup> Tran Thanh Tung<sup>b</sup> Vu Duc Long<sup>b</sup>  
Nguyen Tien Dat<sup>b</sup> Ngo Quang Dinh<sup>c</sup> Tran Thu Huong<sup>d</sup>

<sup>a</sup>Department of Surgery, Hanoi Medical University, Hanoi, Vietnam; <sup>b</sup>Centre of Emergency Medicine (A9), Bachmai Hospital, Hanoi, Vietnam; <sup>c</sup>Radiology Center – Bach Mai Hospital, Hanoi, Vietnam; <sup>d</sup>Department of Pharmacy, Bachmai Hospital, Hanoi, Vietnam

## Keywords

Internal hernia · Laparoscopic surgery · Paracecal hernia · Abdominal pain · Bowel obstruction

## Abstract

Paracecal hernia is rarely associated with ischemia and has seldom been reported in the few published studies in the review literature. We present a case of incarcerated paracecal hernia with intestinal obstruction that was effectively treated with laparoscopic intervention. A 64-year-old woman who had not previously undergone any intestinal surgery arrived complaining of abdominal pain and vomiting at our hospital. Abdominal computed tomography suggested intestinal obstruction. A laparoscopic emergency procedure demonstrated an incarcerated small bowel loop in the paracecal region. The confined small bowel was removed from the paracecal area. On the fourth postoperative day, the patient was discharged. This case is unusual because the patient presented with small bowel strangulation, leading to intestinal obstruction. Laparoscopic surgery is beneficial for diagnosing internal hernias and curing small-bowel obstructions caused by paracecal hernias.

© 2022 The Author(s).  
Published by S. Karger AG, Basel

## Introduction

Internal hernia is a rare cause of intestinal obstruction, accounting for just 0.5–5.8% of all cases [1]. Internal hernias can be congenital or acquired and are categorized into six types: paraduodenal, foramen of Winslow, paracecal, intersigmoid, transmesenteric or transmesocolic, and retroanastomotic. Internal hernias have nonspecific symptoms, which may delay the diagnosis. Internal hernias may be asymptomatic or manifest with abdominal pain, vomiting, and recurrent intestinal obstruction [1, 2]. The duration of the hernia, its reducibility, and the existence of imprisonment and strangulation all contribute to symptom severity. As the pain in paracecal hernias typically begins in the right lower quadrant, it is frequently misdiagnosed as appendicitis [1].

When the mortality rate exceeds 50%, untreated intestinal obstruction may lead to strangulation [2–4]. Paracecal hernia is a rare cause of small-bowel obstruction, accounting for 0.1–6.6% of all internal hernias [2, 3, 5].

Abdominal computed tomography (CT) is critical for diagnosing and managing patients with intestinal obstruction. Practically, patients should be continuously evaluated to ensure that the treatment provided is appropriate, thereby lowering the risk of intestinal necrosis. To our knowledge, less than 30 laparoscopically managed cases have been reported in the literature [6].

Here, we report a clinical case with intestinal obstruction caused by a small-bowel hernia; paracecal hernia was successfully treated with laparoscopic surgery. We conducted a study of the literature to determine the clinical characteristics and treatment options. This case described in this case report may be helpful to clinicians in terms of surgical indications and treatment options based on the clinical features and anatomical defects.

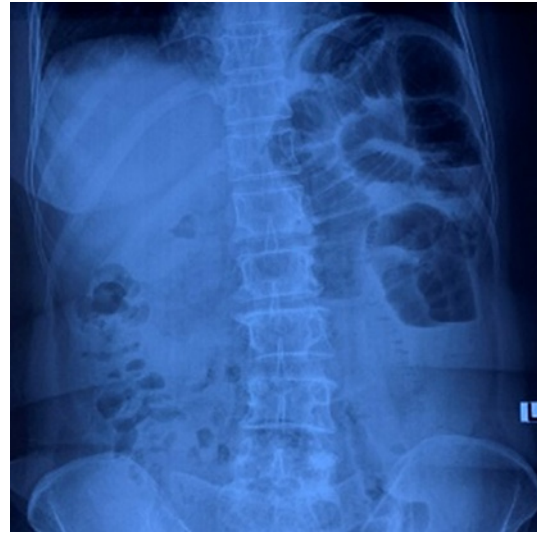
## Case Report

In May 2021, a 64-year-old female patient with a history of mastectomy and eight cycles of postresection radiation therapy received 4 years ago presented with severe abdominal discomfort, periumbilical area tenderness, vomiting, and 2-day bowel obstruction due to mechanical intestinal obstruction. She was afebrile (temperature 36.8°C), had a respiratory rate of 21 breaths per minute, and was hemodynamically stable (heart rate 85 beats/min, blood pressure 130/80 mm Hg). Physical examination revealed that the abdominal wall was unresponsive. The patient's pulse, blood pressure, abdominal pain, and blood count, baseline coagulation, and blood chemistry were assessed. A nasogastric tube was inserted.

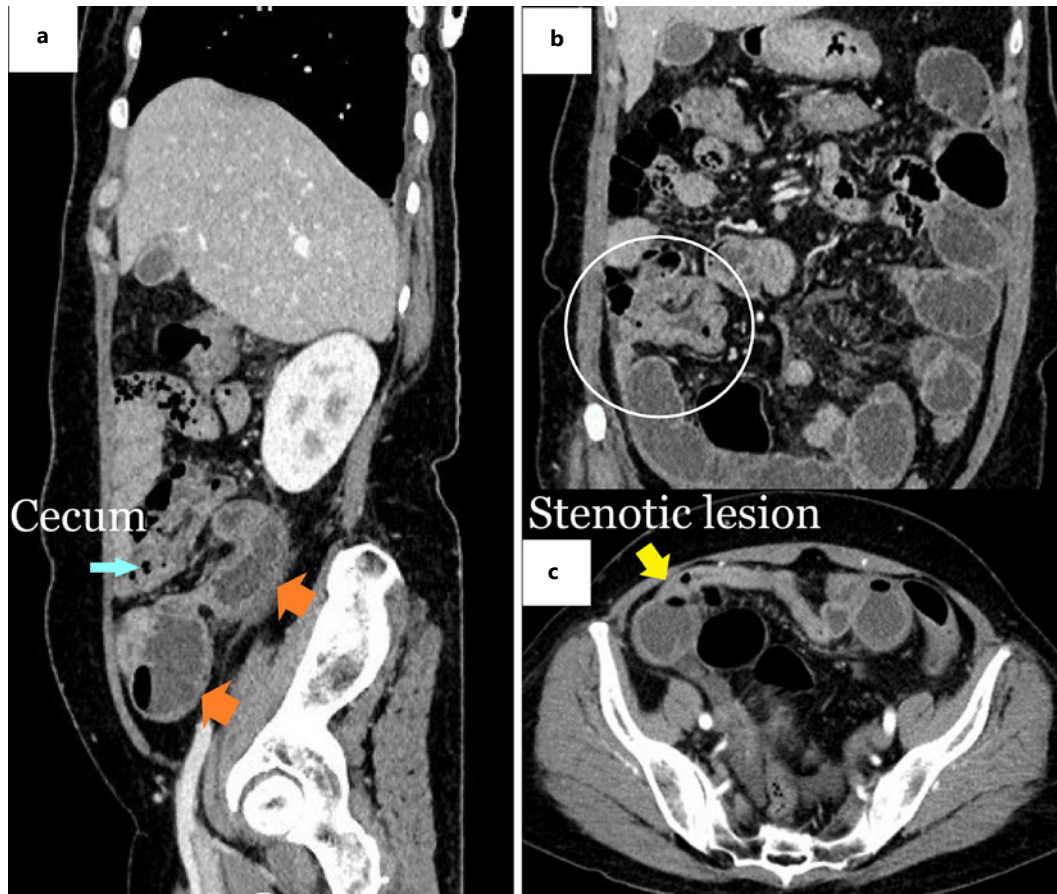
Laboratory workup showed the following: white blood cell count,  $9.9 \times 10^9/L$ ; hemoglobin, 17 g/dL; platelet count,  $360 \times 10^9/L$ ; serum albumin, 31 g/L; carbohydrate antigen 19-9, 18 U/mL; and carcinoembryonic antigen, 2.8 g/L. The patient's electrocardiogram showed normal sinus rhythm. Chest and abdomen radiography revealed typical small-bowel obstruction features, including dilated bowel loops with multiple air-fluid levels and 30–40 mm diameter. No air was present under the diaphragm (Fig. 1).

The patient was admitted for further workup. The transitional zone was located at a cluster of inflammatory distal ileal loops near the cecum and ileocecal valve. The diameter of the small bowel loop was 37 mm, and the thickness of the intestinal wall was 5 mm (Fig. 2). Neighboring small loculated collections were also present, although there was no free air. CT of the abdomen and axial and coronal images indicated small intestinal obstruction.

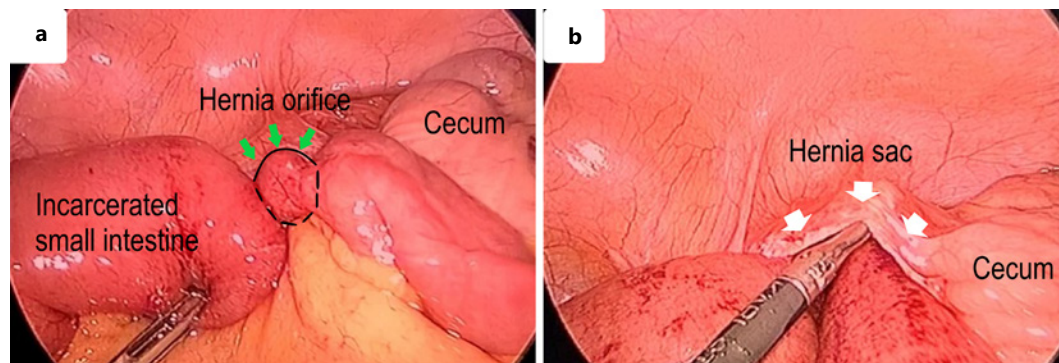
Subsequently, the patient was examined laparoscopically as an emergency case. Three trocars were placed on the abdominal wall. One 10 mm-trocar was positioned around the umbilical region, another 10 mm-trocar at the left iliac region, and a 5-mm trocar in the hypogastric area.



**Fig. 1.** A routine abdominal X-ray reveals intestinal gas in the patient's left upper abdomen.



**Fig. 2.** Abdominal enhanced computed tomography (CT) scan on admission. **a** An enhanced CT scan shows signs of intestinal obstruction at a paracecal location, along with proximal small bowel dilatation (orange arrow). **b** Location of small-bowel obstruction close to the cecum (white circle). **c** Axial CT scan of the small intestine reveals a stenotic lesion in the right paracolic gutter.



**Fig. 3.** A paracecal hernia causing intestinal obstruction was discovered during laparoscopic surgery. **a** The small bowel was distended, a hernial sac containing the small bowel was observed going through the inferior bowel ileocecal recess, and the hernia was enlarged (**b**).

The abdominal cavity was inflated with CO<sub>2</sub> at a pressure of 12 mm Hg. Intraoperatively, we found approximately 300 mL of exudate in the abdomen, mainly concentrated in the right iliac fossa and the Douglas pouch. The small bowel was distended, with a hernial sac containing a small bowel that passed through the inferior ileocecal recess (Fig. 3). The distal bowel was collapsed, and the appendix inflamed. The small intestines inside the hernial sac were released, and the hernial sac was opened, presenting a healthy, viable bowel. Moreover, the hernia sac incision was widened to prevent hernia recurrence. Finally, the color and peristalsis of the imprisoned loop returned to normal. Ultimately, intestinal resection was unnecessary (Fig. 3).

Furthermore, we prescribed antibiotics (basultam, 2 g × 2 vials daily, Medochemie Ltd., Factory C, Republic of Cyprus, and metronidazole, 500 mg × 2 vials daily, Fresenius Kabi Bidipharm, Vietnam). After 3 days, the patient was discharged. On surgical day 4, the patient was discharged without incident. Six months after the surgery, the patient gained 3 kg without gastrointestinal difficulties.

## Discussion

Since the 1950s, paracecal hernia has been reported in the literature. It is a relatively uncommon internal hernia, resulting in small-bowel obstruction. Thus, early detection to avoid complications is paramount. Paracecal hernia accounts for only 0.1–6.6% of all internal hernia [1, 3]. Available reports suggest that they account for approximately 0.5% of all intestinal obstructions [3, 7, 8].

Preoperative diagnosis of pericecal hernias is challenging because of their rare appearance and nonspecific clinical symptoms. Small-bowel herniation is the most common type of intestinal herniation and is associated with a high rate of mechanical obstruction and rapid progression to strangulation. CT is a critical tool for evaluating intestinal obstruction and acute abdominal illnesses. It has become the imaging technique for patients with a suspected internal hernia [5, 9, 10]. Simple radiography and barium-enhanced investigations may reveal symptoms of bowel obstruction or indirect evidence of an internal hernia. However, CT is superior and highly accurate for the diagnosis of internal hernias. In contrast, visceral internal herniation is frequently identified only after laparotomy [4, 11]. Our patient was diagnosed with intestinal obstruction before surgery. This patient has not displayed any symptoms of necrotizing intestinal obstruction, such as a slow pulse, absence of fever, mild tenderness,



**Table 1.** Literature review of pericecal hernia cases from 1986 to 2021

No	Author	Year	Age	Sex	History of abdominal surgery	Classification of pericecal hernia	Method	Resection of bowel
1	Rivkind et al. [15]	1986	25	Male	NA	Paracecal	Laparotomy	–
2	Patterson and Klassen [16]	2000	59	Male	None	Paracecal	Laparotomy	–
3	Lu et al. [17]	2002	69	Male	None	NA	Laparotomy	–
4	Omori et al. [14]	2003	90	Female	None	Retrocecal	Laparoscopy	–
5	Osadchy et al. [18]	2005	76	Male	None	Retrocecal	Laparotomy	–
6	Fu et al. [19]	2006	34	Male	None	Ileocecal	Laparotomy	–
7	Hirokawa et al. [20]	2007	74	Male	Appendectomy	Retrocecal	Laparoscopy	–
8	Kabashima et al. [8]	2010	43	Female	NA	Retrocecal	Mini-Laparoscopy	–
9	Shibuya et al. [21]	2010	63	Male	NA	Retrocecal	Laparotomy	–
10	Choh et al. [5]	2010	65	Female	None	NA	Laparotomy	+
11	Jang et al. [22]	2011	84	Female	None	Retrocecal	Laparotomy	–
12	Nishi et al. [23]	2011	70	Female	None	NA	Laparotomy	–
13	Kleyman et al. [24]	2013	34	Male	None	NA	Laparotomy	–
14	Kumar et al. [25]	2015	88	Female	None	Ileocecal	Laparotomy	+
15	Sasaki et al. [26]	2016	65	Male	None	Retrocecal	Laparoscopy	–
16	Ogami et al. [13]	2016	92	Male	Cholecystectomy	Retrocecal	Laparoscopy	–
17	Ito et al. [9]	2017	83	Male	None	Retrocecal	Laparotomy	–
18	Inukai et al. [3]	2017	54	Male	None	Pericecal hernia	Laparoscopy assisted	+
19	Plua-Muniz et al. [11]	2019	84	Female	None	Pericecal hernia	Laparoscopy	–
20	Our patient	2021	64	Female	None	Pericecal hernia	Laparoscopy	–

NA, not available.

peritonitis, or white blood cell count elevation. However, we could not preoperatively diagnose paracecal hernia due to the lack of hernia characteristics on CT.

In recent years, laparoscopic surgery has been increasingly popular for treating small intestinal obstructions. Chest and abdomen radiography revealed typical features of small-bowel obstruction [12]. Laparoscopic surgery is highly diagnostic and less intrusive than open surgery. To date, seven cases of pericecal hernia treated with laparoscopy have been reported [1, 2, 8, 11, 13, 14]. To our knowledge, laparoscopic management is suitable for both diagnosis and therapy and is preferred because of a shorter recovery period. Even in patients requiring bowel resection, minimally invasive laparoscopic treatment may be possible for this condition. Laparoscopic surgery is the preferred treatment approach and the best choice when uncertain diagnosis. On the other hand, open surgery should be performed without delay if the patient shows signs of shock. When intestinal ischemia is detected, the initial approach is to reduce strangling. Opening or closing the hernia orifice is required to prevent a recurrence, although whether the orifice should be left open or completed is debatable [6, 11]. Tayaran et al. [10] closed the peritoneal defect using a continuous 3/0 polydioxanone suture. We chose to widen the opening pouch because it is technically more straightforward.

Recent systematic evaluations comparing laparotomy versus laparoscopy for short-bowel obstruction found that laparoscopy was associated with lower morbidity, more temporary hospital stay, and faster recovery of bowel function. The studies concluded that laparoscopy is a feasible alternative to laparotomy for acute short-bowel obstruction performed by experienced surgeons [13].

We discovered only 19 publications detailing of internal hernia in the English language in a PubMed search of the literature published from 1986 to 2021 (Table 1). Our investigation revealed that the average patient age was 62 years, ranging from 25 to 92 years. There were no discernible disparities between men and women in terms of the incidence rates. According to the analysis, 2 patients had undergone abdominal surgery. Only 3 patients required intestinal resection because of intestinal ischemia. Congestive causes most commonly cause Pericecal hernia. Additionally, it is probable that pericecal hernias are acquired due to fragility associated with aging, increased pressure in the internal abdomen, retroperitoneal adhesions, and other undiscovered reasons [3].

In our patient, laparoscopic surgery was successfully performed. However, this study had some limitations. The specifics relating to paracecal hernias are not available. This is understandable, given the rarity of the condition and the primary symptoms of mechanical intestinal obstruction. Follow-up is critical to determine how well laparoscopic surgery works and if widening hernia openings reduce the risk of recurrence and intestinal adhesions, which can occur after surgery.

## Conclusion

Early laparoscopic surgery enhanced diagnostic and therapeutic outcomes in our situation. As a result, we recommend early laparoscopy for patients with small intestinal obstruction and no history of abdominal surgery.

## Acknowledgments

Many thanks to the Editage for editing the draft of this manuscript.

## Statement of Ethics

This study protocol was reviewed by the Bach Mai Hospital of Medicine Institutional Review Board, and the study was granted an exemption from requiring ethics approval. Written informed consent was obtained from the participant for the publication of the details of this medical case and any accompanying images.

## Conflict of Interest Statement

The authors declare that there is no conflict of Interest.

## Funding Sources

There are no funding sources to report.

## Author Contributions

Tran Que Son, Tran Thanh Tung, Tran Hieu Hoc, and Tran Thu Huong were involved in treating the patient, drafting the manuscript, and final editing the manuscript. Vu Duc Long, Nguyen Tien Dat, and Ngo Quang Dinh participated in critically revising the manuscript. All the authors declare that they contributed to this article and have read and approved the final version of the manuscript.

## Data Availability Statement

All data generated or analyzed during this report are included in this article. Further inquiries can be directed to the corresponding author.

## References

- 1 Al-Ardah M, Sisodia H, Rottenburg H, Clarke M. Laparoscopic management of strangulated paracecal hernia causing small bowel obstruction. Case report and review of the literature. *J Surg Case Rep*. 2021 Sep;2021(9):rjab353.
- 2 Alghamdi F, Alharbi A, Alshamrani A, Alomani S. Paracecal hernia with intestinal obstruction managed with laparoscopic surgery: a case report. *Int J Surg Case Rep*. 2020 Sep;77:329–32.
- 3 Inukai K, Tsuji E, Uehara S. Paracecal hernia with intestinal ischemia treated with laparoscopic-assisted surgery. *Int J Surg Case Rep*. 2018 Feb;44:20–3.
- 4 Menezes R, Kamble R, Joshi A, Chaudhari K. Closed loop small bowel obstruction due to paracecal internal herniation: a lesson in rarity. *BMJ Case Rep*. 2018 Dec;11(1):e227461.
- 5 Choh NA, Rasheed M, Jehangir M. The computed tomography diagnosis of paracecal hernia. *Hernia*. 2010 Oct;14(5):527–9.
- 6 Yokota T, Otani K, Yoshida J, Mochidome N, Miyatake E, Nakahara C, et al. Paracecal hernia due to membranous adhesion of the omentum to the right paracolic gutter. *Surg Case Rep*. 2019 Nov;5(1):183.
- 7 Chia DKA, Tay KV, Kow A, So J, Shabbir A, Kim G. Paracecal hernia: uncommon but important cause of small bowel obstruction successfully managed with laparoscopic surgery. *ANZ J Surg*. 2019 Jun;89(6):769–70.
- 8 Kabashima A, Ueda N, Yonemura Y, Mashino K, Fujii K, Ikeda T, et al. Laparoscopic surgery for the diagnosis and treatment of a paracecal hernia repair: report of a case. *Surg Today*. 2010 Apr;40(4):373–5.
- 9 Ito S, Takeda R, Kokubo R, Sakai Y, Matsuzawa H, Sugimoto K, et al. Retrocecal hernia preoperatively diagnosed by computed tomography: a case report. *Int J Surg Case Rep*. 2017 Jul;37:186–8.
- 10 Tayaran A, Abdulrasool H, Bui HT. Paracecal hernia: a case report on the evolving role of laparoscopy. *Int J Surg Case Rep*. 2017 Feb;32:29–31.
- 11 Plua-Muniz K, Sanchez-Gonzalez J, Bailon-Cuadrado M, Pacheco-Sanchez D. Small bowel obstruction caused by pericecal hernia resolved with a laparoscopic approach. *Ann R Coll Surg Engl*. 2020 Sep;102(7):e155–7.
- 12 O'Connor DB, Winter DC. The role of laparoscopy in the management of acute small-bowel obstruction: a review of over 2,000 cases. *Surg Endosc*. 2012 Jan;26(1):12–7.
- 13 Ogami T, Honjo H, Kusanagi H. Pericecal hernia manifesting as a small bowel obstruction successfully treated with laparoscopic surgery. *J Surg Case Rep*. 2016 Mar;2016(3):rjw020.
- 14 Omori H, Asahi H, Inoue Y, Irinoda T, Saito K. Laparoscopic paracecal hernia repair. *J Laparoendosc Adv Surg Tech A*. 2003 Feb;13(1):55–7.
- 15 Rivkind AI, Shiloni E, Muggia-Sullam M, Weiss Y, Lax E, Freund HR. Paracecal hernia: a cause of intestinal obstruction. *Dis Colon Rectum*. 1986 Nov;29(11):752–4.
- 16 Patterson R, Klassen G. Small bowel obstruction from internal hernia as a complication of colonoscopy. *Can J Gastroenterol*. 2000 Dec;14(11):959–60.
- 17 Lu HC, Wang J, Tsang YM, Tseng HS, Li YW. Pericecal hernia: a report of two cases and survey of the literature. *Clin Radiol*. 2002 Sep;57(9):855–8.
- 18 Osadchy A, Keidar A, Zissin R. Small bowel obstruction due to a paracecal hernia: computerized tomography diagnosis. *Emerg Radiol*. 2005 Jun;11(4):239–41.
- 19 Fu CY, Chang WC, Lu HE, Su CJ, Tan KH. Pericecal hernia of the inferior ileocecal recess: CT findings. *Abdom Imaging*. 2007 Jan–Feb;32(1):81–3.
- 20 Hirokawa T, Hayakawa T, Tanaka M, Okada Y, Sawai H, Takeyama H, et al. Laparoscopic surgery for diagnosis and treatment of bowel obstruction: case report of paracecal hernia. *Med Sci Monit*. 2007 Jul;13(7):CS79–82.
- 21 Shibuya H, Ishihara S, Akahane T, Shimada R, Horiuchi A, Aoyagi Y, et al. A case of paracecal hernia. *Int Surg*. 2010 Jul–Sep;95(3):277–80.

- 22 Jang EJ, Cho SH, Kim DD. A case of small bowel obstruction due to a paracecal hernia. [J Korean Soc Coloproctol](#). 2011 Feb;27(1):41–3.
- 23 Nishi T, Tanaka Y, Kure T. A case of pericecal hernia with a hernial orifice located on the lateral side of the cecum. [Tokai J Exp Clin Med](#). 2011 Sep 20;36(3):71–4.
- 24 Kleyman S, Ashraf S, Daniel S, Ananthan D, Sanni A, Khan F. Pericecal hernia: a rare form of internal hernias. [J Surg Case Rep](#). 2013 Feb 1;2013(2):rjs021.
- 25 Kumar S, Dikshit P, Bhaduri S, Sattavan S. Gangrenous appendicitis: a rare presentation of pericecal hernia; case report and review of the literature. [Bull Emerg Trauma](#). 2015 Oct;3(4):144–7.
- 26 Sasaki K, Kawasaki H, Abe H, Nagai H, Yoshimi F. Retrocecal hernia successfully treated with laparoscopic surgery: a case report and literature review of 15 cases in Japan. [Int J Surg Case Rep](#). 2016 Nov;18:45–7.