

Arthroscopic Anterior Elbow Capsular Release Initiated Using Metal Trocar



Michael C. Maxted, M.D., Adam C. Field, B.S., and Larry D. Field, M.D.

Abstract: Elbow stiffness occurs as a consequence of multifactorial etiologies and can be broadly classified into either extra-articular or intra-articular contracture. Although nonoperative treatment regimens may prove successful, recalcitrant cases may require operative management. Both open and arthroscopic procedures to address these contractures have been described. Open techniques have historically been the mainstay of surgical management prior to the advent and advancement of arthroscopy. Although often successful, open elbow contracture release introduces added iatrogenic insult to the soft tissue envelope and has the potential to compromise the intraoperatively obtained gains in motion. Arthroscopic contracture release, although not without its own inherent risks, has been shown to be an effective intervention for the release of elbow capsular contractures. Arthroscopic release of the elbow capsule can be challenging, however, because of its thickness and proximity to vital neurovascular structures. The authors describe an adjunctive technique for effectively and efficiently releasing the anterior and posterior capsule under arthroscopic visualization using a 4.5-mm large metal trocar.

The evaluation of a patient with elbow stiffness should include a detailed history and thorough physical examination with careful attention paid to ascertaining the etiology of an individual patient's contracture. A combination of intra-articular and extra-articular derangements can contribute to motion loss and consequent dysfunction.¹ Particular attention should be paid to the duration of a patient's signs and symptoms, and the history should include detailed inquiry regarding prior nonoperative treatments or surgeries. Documentation of incisions and recognition of prior procedures, such as ulnar nerve transposition, is critical to avoid potentially devastating neurovascular complications.²⁻⁵

Morrey et al.⁶ described the functional range of motion of the elbow as 30° of extension to 130° of flexion with 50° of pronation and supination, respectively. Operative management is generally considered in such patients who have failed nonoperative treatment, although fewer degrees of motion loss is not necessarily a surgical contraindication, depending on other symptoms and functional requirements or when quality of life is significantly affected.

Safe arthroscopy of the elbow joint requires knowledge of neurovascular anatomy and familiarity with arthroscopic portal placement. Numerous authors have published descriptions of classic as well as modified portals in elbow arthroscopy.⁷ Anatomic studies detailing the proximity of neurovascular structures to arthroscopic portals define the relationships between these portal site locations and the adjacent structures.⁸ Although a surgeon may be familiar with arthroscopic techniques designed to release elbow contracture, the abnormal capsular anatomy encountered at the time of surgical intervention may prove to be a challenging technical hurdle. Release of this often very thickened and contracted anterior and posterior capsule in such individuals is often difficult with standard mechanical up-biters, scissors, or arthroscopic shaver blades. In addition, because of the proximity of the major nerves and arteries that cross the elbow joint, a safe and simple alternative technique that can efficiently and effectively release the entire anterior and posterior capsule would be desirable. The authors describe a technique to

From the Mississippi Sports Medicine and Orthopaedic Center, Jackson, Mississippi, U.S.A.

The authors report the following potential conflicts of interest or sources of funding: L.D.F. receives institutional grants, travel support, and board membership fees from the Arthroscopy Association of North America; consultation fees from Smith & Nephew; and research and educational support from Arthrex, Mitek, and Smith & Nephew. Full ICMJE author disclosure forms are available for this article online, as [supplementary material](#).

Received February 22, 2018; accepted June 19, 2018.

Address correspondence to Larry D. Field, M.D., Mississippi Sports Medicine and Orthopaedic Center, 1325 East Fortification Street, Jackson, MS 39202, U.S.A. E-mail: lfield@msmoc.com

© 2018 by the Arthroscopy Association of North America. Published by Elsevier. This is an open access article under the CC BY-NC-ND license (<http://creativecommons.org/licenses/by-nc-nd/4.0/>).

2212-6287/18252

<https://doi.org/10.1016/j.eats.2018.06.008>

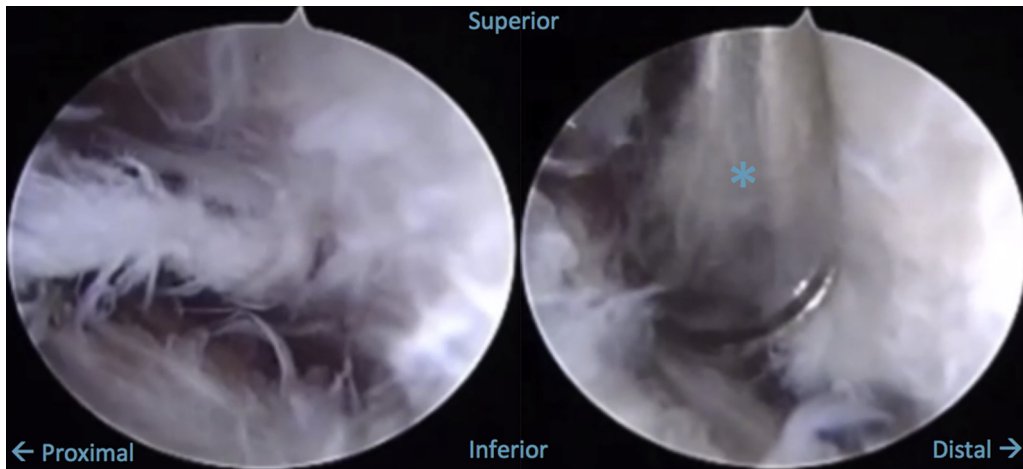


Fig 1. With the patient positioned prone, the camera has been inserted into a proximal anterolateral viewing portal of a left elbow. The anterior humeral surface is superior, and the brachialis and neurovascular structures are inferior. The joint is to the right in the image. The left image shows poor visualization and difficulty with identifying any landmarks. This represents the challenge in visualization that occurs with arthroscopic management of the stiff elbow. Adhesions and capsular thickening appear as frayed, white tissue. The right image shows the insertion of a large metal trocar and cannula (*) from a standard medial portal, under direct visualization. To successfully introduce the trocar, the surgeon uses tactile feedback and inserts it just off the bony surface of the anterior humerus. The blunt nature of the trocar ensures that no vital structures are damaged.

release the anterior and posterior elbow capsule from its humeral attachment under direct arthroscopic visualization, without the need for sharp, cutting instruments or arthroscopic shaver blades, that has proved reliable and effective for the authors.

Surgical Technique

In the following, we present a step-by-step outline of the procedure in its entirety; please refer to [Video 1](#) for a complete narration and visualization.

Positioning and Initial Considerations

The patient is positioned in the prone or lateral decubitus position with all bony prominences well padded. Sterile or nonsterile tourniquet should be applied according to surgeon preference. After exsanguination, the elbow is insufflated with 20 to 30 mL of normal saline, injected into the posterior olecranon fossa. Dense capsular adhesions may prevent insufflation. The direct lateral or so-called soft spot portal can also be used for insufflation. The surgeon must know if the ulnar nerve is in its native location or if a transposition has been performed. In cases when a transposition has been performed, we recommend open identification of the nerve before any attempt at medial portal placement.

Establishment of Portals

The arthroscope is inserted into the anterior compartment through either a proximal anterolateral or proximal anteromedial portal, depending on surgeon preference. In cases of elbow contracture, the intra-articular and capsular anatomy is often distorted, making identification of common landmarks more

difficult ([Fig 1](#)). Establishment of a working portal should occur under direct arthroscopic visualization. An 18-gauge spinal needle is used for localization prior to

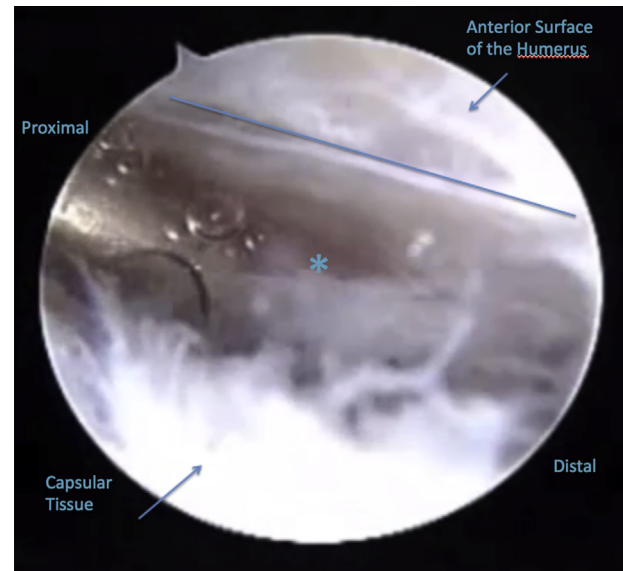


Fig 2. A trocar has been inserted into a left elbow from a medial working portal (*). This must be kept under direct visualization at all times from the anterolateral viewing portal. The surgeon moves his hand toward the joint (distally), thus directing the tip of the metal trocar (*) proximal and away from the joint, along the anterior humeral surface. This creates a plane between the humerus and a leading edge of capsular tissue for initiation of debridement. If the trocar was positioned in the correct plane, this sweeping motion safely releases the adhesions from the anterior humeral surface. A space for the shaver has now been created. Again, adhesions and capsular thickening appear as frayed, white tissue.

cannula insertion. A knife is used to create an incision only through the epidermis but no deeper.

Metal Trocar Technique: Anterior Release

A 4.5-mm large metal trocar (Dyonics; Smith & Nephew, London, United Kingdom) and cannula is then used to mechanically detach and sweep capsular tissue away from its anterior humeral insertion site (Figs 2 and 3). The surgeon uses tactile feedback to remain in direct contact with the anterior humeral cortical surface (Fig 2). This distal to proximal sweeping motion separates the proximal capsule from the humerus that results in the creation of a leading capsular edge that can then be safely and efficiently resected using a shaving device or mechanical up-biter (Fig 4). The brachialis muscle is a reliably identifiable structure that serves as an important landmark. Visualization of the brachialis muscle fibers confirms complete release of the anterior capsule and also serves as a valuable soft tissue “buffer” between the arthroscopic instruments and the vital neurovascular structures (Fig 5). Associated metal cannulas allow the surgeon to efficiently switch the metal trocar and arthroscope between these 2 anterior compartment portals. This portal switch allows the surgeon to identify any remaining intact anterior capsule that was not previously visible that can then be detached using the same metal trocar under direct arthroscopic visualization as

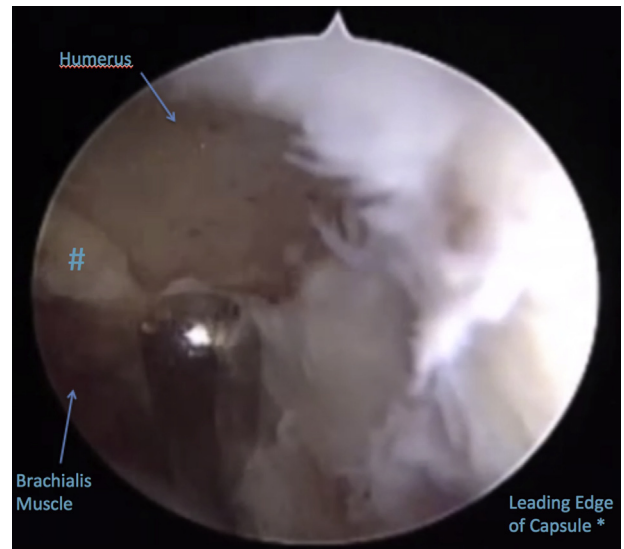


Fig 4. Viewing from the anterolateral portal of a left elbow in the prone position, a sucker-shaver device (*) is inserted from the medial working portal into the space created by the metal trocar. It is carefully positioned near the leading edge of capsule to initiate medial capsulectomy. The joint surface is distal (to the right) in the image. It is only partially visible because of robust capsular tissue and adhesions. The leading edge of tissue is easily and safely debrided with gentle suction and an oscillating setting on the shaver. The shaver proceeds away from the joint and along the plane created.

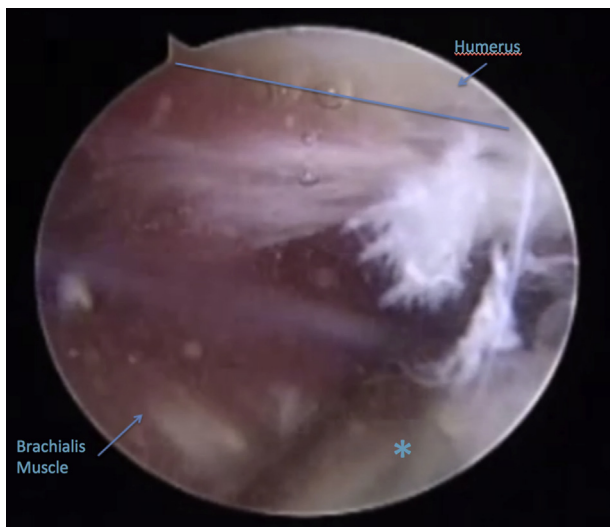


Fig 3. Viewing from the anterolateral portal in a left elbow in the prone position, the surgeon lifts his hand superiorly (away from the floor). This leverages the trocar against the adhesions and capsular tissue, further mobilizing it away from the anterior humeral surface. This maneuver expands the space between the anterior humeral surface and previously adherent fibrotic tissue. The brachialis is now partially visible, providing a landmark for safe debridement. The neurovascular structures lie anterior to the level of the brachialis, and debridement should not proceed farther anterior once the muscle is visualized.

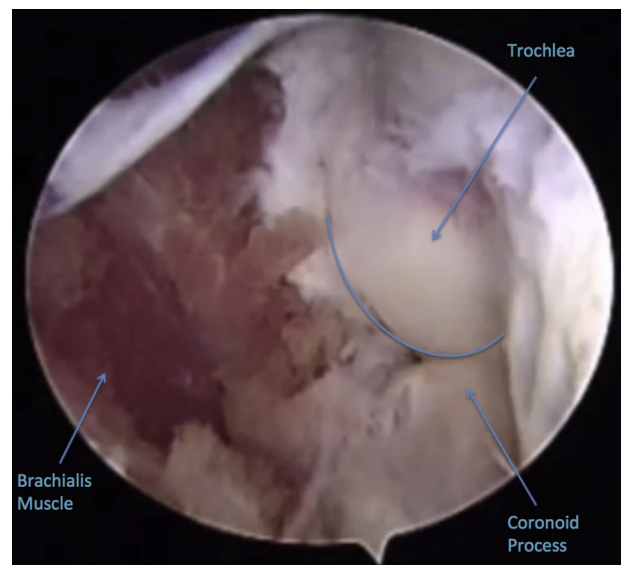


Fig 5. This view is from the anterolateral portal of a left elbow with the patient in prone position. Medial capsulectomy has been completed with the sucker-shaver device, and the bony landmarks of the elbow joint (trochlea and coronoid process) are readily visualized. Adhesions have been cleared, and the brachialis muscle is visible inferiorly in the image. Increased joint distension allows other interventions to be performed (microfracture, removal of loose bodies, etc.).

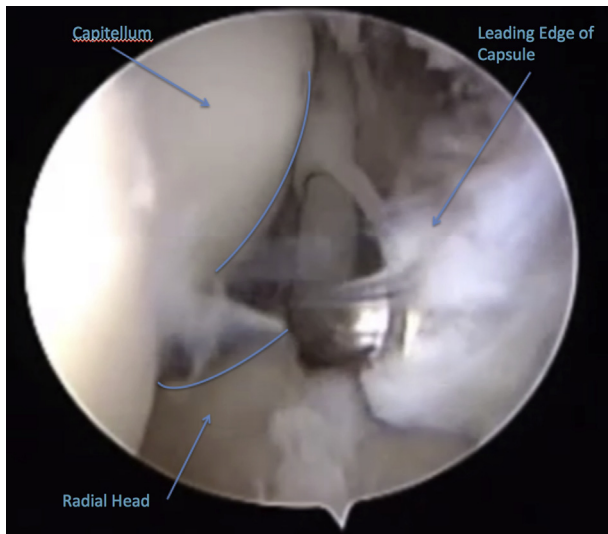


Fig 6. Although not shown in this image, the surgeon may insert a switching stick into the anteromedial portal and remove the camera attachment from the elbow. Before removing the arthroscopic bridge, an additional switching stick is inserted into the anterolateral portal. This allows quick and safe transition of the bridge and camera to an anteromedial viewing portal. Again, this is a left elbow. Note that the joint surface is now to the left of the image and the proximal humerus is to the right of the image. This allows visualization of the lateral structures, including adhesions and the leading edge of released capsule. The sucker shaver has been inserted into the anterolateral portal. Debridement of radiocapitellar joint adhesions can now be performed in a distal to proximal fashion.

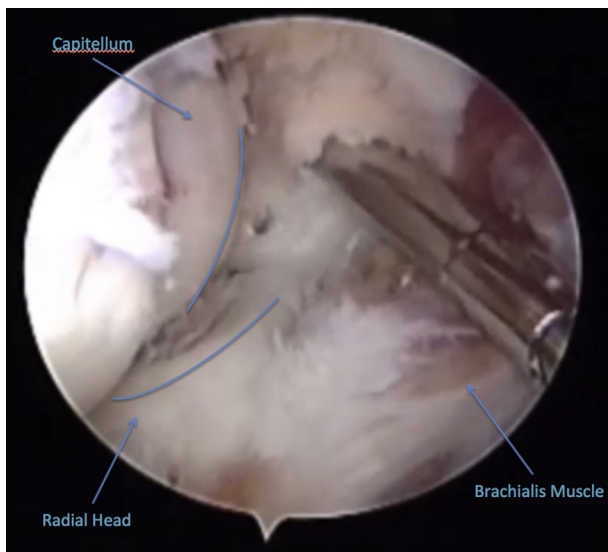


Fig 7. Viewing from the anteromedial portal in a left elbow, the anterolateral capsule has been debrided, yielding good visualization of the anatomic features of the radiocapitellar joint (left of the image). The brachialis is visible in the inferiormost portion of the image. The elbow may now be ranged to assess for improved motion (not pictured). Additional distention or “working room” in the joint has been accomplished.

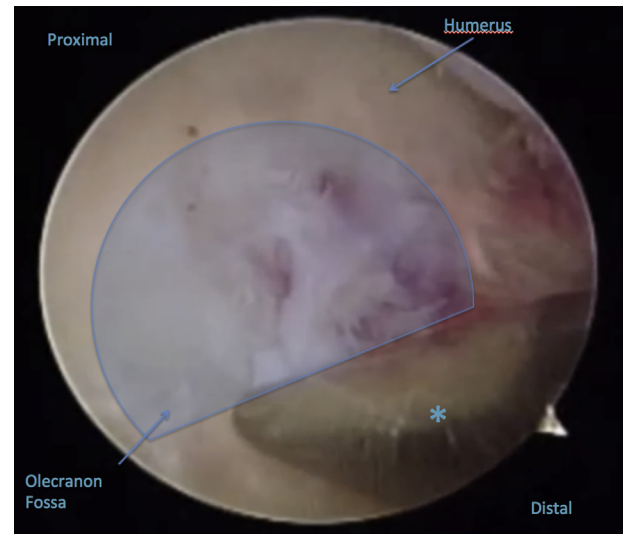


Fig 8. The surgeon may now establish posterior joint access. This is shown in a left elbow with the patient positioned prone. The camera has been inserted into the posterolateral viewing portal. Under direct visualization, the tip of the metal cannula and trocar (*) is inserted safely into the olecranon fossa from a posterior central portal. The proximal humerus is now superior in the image. Medial and lateral sides of the elbow are indicated in the image. Direct visualization of the trocar tip ensures that neurovascular structures, especially the ulnar nerve, are not inadvertently injured.

well (Fig 6). Once released, the capsule can be excised as necessary (Fig 7).

Metal Trocar Technique: Posterior Release

Posterior capsular release using the metal trocar is conducted in a very similar manner. Posterior central and posterolateral viewing portals are created. The same metal trocar is inserted into the olecranon fossa via a posterior central portal (Fig 8). Under arthroscopic visualization from the posterolateral portal, the trocar is advanced along the posterior humeral cortex until the proximal insertion of the posterior capsule is identified. The posterior capsule is then detached from its bony insertion site on the posterior humeral surface (Fig 9). This detached posterior capsule can then be excised using the arthroscopic shaver or mechanical up-biters. Similar to the brachialis muscle fibers seen anteriorly, the triceps muscle fibers serve as an important landmark posteriorly to identify the margins of the posterior capsule. These triceps muscle fibers also aid in serving as a protective layer that helps protect adjacent structures while the posterior capsule is resected (Fig 10).

Optional Additional Procedures

Once the anterior and posterior capsular releases and excisions are completed, significantly more working room is available that allows for improved visualization and instrument maneuverability. This increased intra-articular space can also aid in improving access to

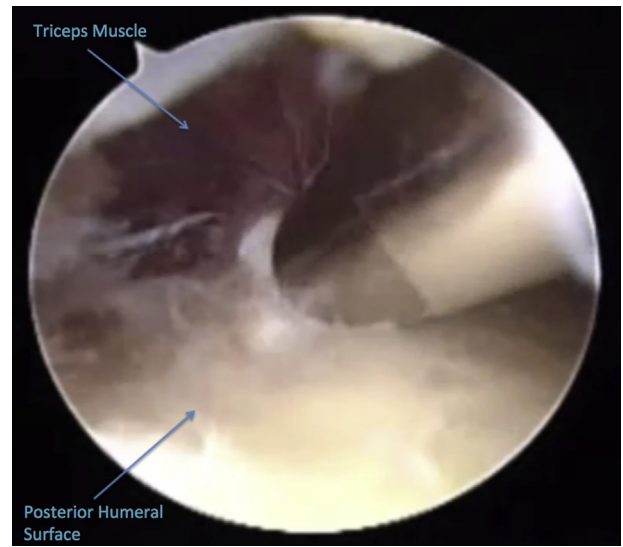
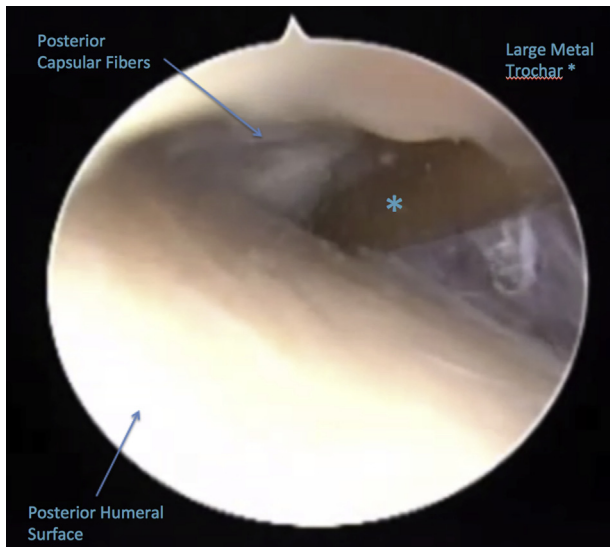


Fig 9. With this patient in the prone position, posterior access to the left elbow has been gained. Looking proximally and superiorly from the posterolateral viewing portal along the posterior humeral shaft, the metal trochar (*) is gently advanced along the posterior humeral surface. This is performed by pushing the surgeon’s hand proximally along the bony surface of the humerus in combination with gently lifting the metal trochar away from the humeral surface (dropping the hand toward the floor). Posterior capsular fibers and adhesions are visible superior to the metal trochar. The posterior humeral surface is inferior in the image. A leading edge of tissue and along with a safe space has been created for the shaver to begin debridement of adhesions.

Fig 10. In a left elbow, with the patient in the prone position, a sucker shaver has been inserted into the posterior joint space through a posterior central portal. A safe plane between the posterior humeral surface and dense adhesions was created previously using the large metal trochar. Careful debridement of the dense capsular adhesions may safely proceed. Debridement is typically sufficient once the triceps musculature is identified. On completion of posterior capsulectomy, elbow range of motion may again be assessed and other interventions performed as needed.

other areas of the elbow joint and facilitate loose body removal, osteophyte excision, posteromedial gutter release, and posterolateral gutter releases.

Discussion

Safe and efficient arthroscopic capsular release of a contracted elbow is challenging. This metal trochar technique allows for a reproducible and effective alternative to sharp mechanical or arthroscopic shaver blade release of the anterior and posterior capsule from their respective humeral attachment sites. Because of the blunt nature of the trochar and cannula, risk of iatrogenic injury to neurovascular structures can be

minimized. Occasionally, as a result of extreme thickening of the capsule or as a result of intrinsic changes to the elbow joint (i.e., gross bony deformity following distal humerus fracture malunion), this technique may not facilitate capsular detachment without undue force required. Failure to recognize this may lead to incomplete or ineffective capsular release. In such instances, a standard mechanical up-biter or arthroscopic shaver can be used to initiate the release. Once initiated with these up-biter devices, the capsular release can then usually be completed using the same metal trochar technique. If the surgeon remains dissatisfied with the arthroscopic release, limited or standard open techniques can still be employed.

For the trochar capsular release method described, [Table 1](#) lists additional technique insights observed, and

Table 1. Pearls and Pitfalls

Pearls	Pitfalls
When sweeping tissue away with the trochar, keep in direct contact with bone.	Failing to maintain the trochar on bone can lead to creating an unwanted plane within muscle. This increases the risk of neurovascular injury.
Use a cannula and trochar together. It allows for efficient switching of instruments and minimizes passage into and out of the elbow soft tissues.	When used in isolation, the metal trochar must be withdrawn, a cannula placed, and reinserted into the joint. Efficiency is decreased.
Once the trochar is beneath the scar tissue or adhesions, simply levering of the surgeon’s hand creates separation of the tissue from the underlying bone.	Because the instrument is blunt, extremely fibrotic tissue may be difficult to mobilize.

Table 2. Advantages and Disadvantages

Advantages	Disadvantages
The blunt trocar minimizes iatrogenic risk of injury to neurovascular structures in the ankylosed elbow.	Technically challenging for novice elbow arthroscopists.
If ineffective, the surgeon may use more aggressive instrumentation.	Limited ability to perform corrective osteotomy or major hardware removal (if desired/indicated).
When efficiently performed, operating room time is decreased.	Arthroscopic equipment and setup is required.

Table 2 summarizes the general advantages and disadvantages of this technique.

References

1. Keener JD, Galatz LM. Arthroscopic management of the stiff elbow. *J Am Acad Orthop Surg* 2011;19:265-274.
2. Jones GS, Savoie RH. Arthroscopic capsular release of flexion contractures (arthrofibrosis) of the elbow. *Arthroscopy* 1993;9:277-283.
3. Tucker SA, Savoie FH III, O'Brien MJ. Arthroscopic management of the post-traumatic stiff elbow. *J Shoulder Elbow Surg* 2011;20:S83-S89.
4. Kelly EW, Morrey BF, O'Driscoll SW. Complications of elbow arthroscopy. *J Bone Joint Surg Am* 2001;83:25-34.
5. Park SE, Bachman DR, O'Driscoll SW. The safety of using proximal anteromedial portals in elbow arthroscopy with prior ulnar nerve transposition. *Arthroscopy* 2016;32:1003-1009.
6. Morrey BF, Askew LJ, Chao EY. A biomechanical study of normal functional elbow motion. *J Bone Joint Surg Am* 1981;63:872-877.
7. Thon S, Gold P, Rush L, O'Brien MJ, Savoie FH III. Modified anterolateral portals in elbow arthroscopy: A cadaveric study on safety. *Arthroscopy* 2017;33:1981-1985.
8. Field LD, Altchek DW, Warren RF, O'Brien SJ, Skyhar MJ, Wickiewicz TL. Arthroscopic anatomy of the lateral elbow: A comparison of three portals. *Arthroscopy* 1994;10:602-607.