

Inflammation and Infection

## Discovery of Renal Tuberculosis in a Partial Nephrectomy Specimen Done for Renal Tumor



Ahmed Saadi\*, Haroun Ayed, Abderrazak Bouzouita, Walid Kerkeni, Mohamed Cherif, Riadh M. Ben Slama, Amine Derouiche, Mohamed Chebil

*Urology Department, Charles Nicolle University Hospital, Boulevard 9 avril 1938, Tunis 1006, Tunisia*

### ARTICLE INFO

#### Article history:

Received 13 January 2015

Received in revised form

17 January 2015

Accepted 26 January 2015

Available online 4 March 2015

#### Keywords:

Kidney

Cancer

Tuberculosis

Partial nephrectomy

### ABSTRACT

The association of renal cancer and renal tuberculosis is uncommon. While the incidental discovery of renal cell carcinoma in a tuberculous kidney is a classical finding, the discovery of tuberculous lesions after nephrectomy for cancer is exceptional. We report the case of a female patient aged 60 who had a partial nephrectomy for a 5 cm exophytic kidney tumor. Pathological examination concluded that renal clear cell carcinoma associated with follicular caseo tuberculosis.

© 2015 The Authors. Published by Elsevier Inc. This is an open access article under the CC BY-NC-ND license (<http://creativecommons.org/licenses/by-nc-nd/4.0/>).

### Introduction

The association of renal cancer and renal tuberculosis is uncommon.<sup>1,2</sup> While the incidental discovery of renal cell carcinoma in a tuberculous kidney is a classical finding, the discovery of tuberculous lesions after nephrectomy for cancer is exceptional.<sup>1,2</sup> We describe a case in which histological examination revealed associated tuberculosis.

### Case presentation

A female patient aged 60, without urological or medical history, in which we discover by chance on an ultrasound a 5 cm exophytic kidney tumor.

In CT, the lesion was isodense and enhanced after injection of contrast material (Figs. 1 and 2); there was no abnormality in the rest of the parenchyma or the urinary tract.

We performed a partial nephrectomy by lumbotomy. Macroscopically, the lesion was a polychrome appearance with hemorrhagic and pseudocystic rearrangements. The postoperative course was uneventful.

The final histological examination confirmed the diagnosis of suspected cancer by imaging. This was a conventional cell adenocarcinoma Führman grade 2. The tumor was reworked by many tuberculoid granulomas caseo-follicular (Fig. 3). The exeresis limits were away from the cancerous growth and contained some epithelioid granulomas and giant cell. Perirenal fat was removed free of histological abnormality.

The search for tubercle bacilli performed on urine and sputum after surgery was negative. A chest radiograph showed no signs of tuberculosis.

In principle, a quadruple antituberculosis therapy was introduced for 2 months and relayed by a combination therapy for 4 months.

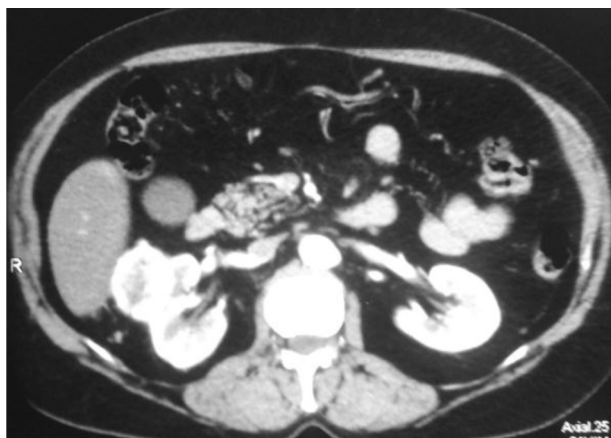A CT was performed 6 months after surgery and was without abnormalities

### Discussion

Since the late 1980s, the incidence of tuberculosis increased in the US and Europe West while the disease was virtually eradicated by the BCG vaccine. Three main factors explain this increase: immunosuppression related to the AIDS virus, the flow of immigrants living in community, and the emergence of bacterial strains resistant to usual treatments.<sup>3</sup>

\* Corresponding author. Tel.: +216 98513698.

E-mail address: [dr.saadi.ahmed@gmail.com](mailto:dr.saadi.ahmed@gmail.com) (A. Saadi).



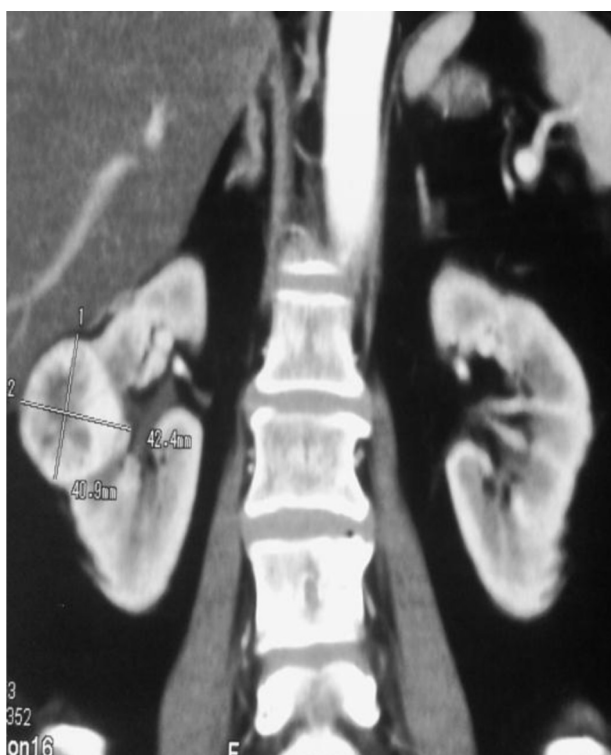**Figure 1.** Cross section of a CT showing an anterior tumor and exophytic.

Renal localization of tuberculosis is the result of hematogenous spread of mycobacteria from a pulmonary focus and occurs in 8 to 10% of cases of primary infection tuberculous.<sup>4</sup>

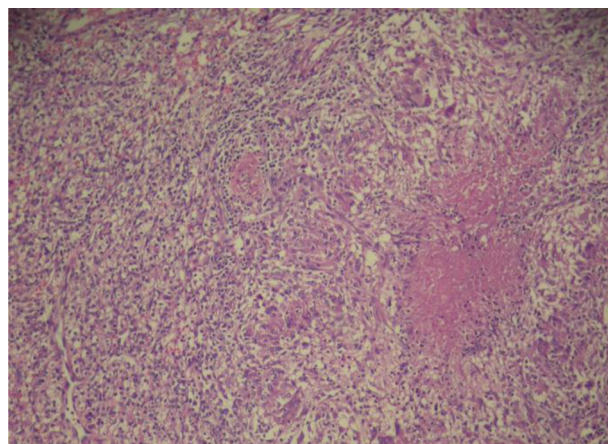
The causative agent is usually *Mycobacterium tuberculosis*. The other type of mycobacteria *Mycobacterium bovis* or *Mycobacterium africanum* are exceptionally involved.<sup>2</sup>

Less than 50 cases of tuberculous kidney cancers have been reported in the first half of the 20th century.<sup>5</sup> Despite the recent resurgence of tuberculosis, very few cases have been described in the past 20 years.<sup>1,2</sup>

The originality of our observation is based on the double chance discovery of a tumor of the kidney and renal tuberculosis. While the chance discovery, ultrasound or tomodensitométrique, kidney tumor is frequent (more than 50% of kidney cancer diagnoses),<sup>6</sup> the chance discovery of renal tuberculosis is exceptional. In most



**Figure 2.** Coronal CT showing a mid-renal tumor location and proximity to the urinary tract



**Figure 3.** Final Histological examination showed adenocarcinoma clear cell grade 2 Fährman, combined with follicles tuberculoid and caseous necrosis.

reported cases, tuberculosis was known to be the cause of kidney destruction.<sup>1</sup> The histological examination of the removed kidney highlighted the presence of an unsuspected cancer.<sup>1</sup>

In our case, it is histologically a renal tumor that introduced tuberculous lesions in a patient with no known history of mycobacterial infection. To our knowledge, only few cases of accidental discovery of isolated renal tuberculosis have been reported in the literature.<sup>1,2</sup>

In the literature, the conventional cell adenocarcinoma is the most histological form found.<sup>1,2</sup> The combination of tuberculous lesions to other tumor histological types such as transitional cell carcinoma has rarely been described.<sup>7,8</sup>

Except in cases where the kidney is no longer functional, the treatment must be adapted to the characteristics of the cancer. In case of small polar tumor, a partial nephrectomy preceded or followed by antituberculosis treatment is possible.<sup>1,2</sup>

## Conclusion

The association of renal tuberculosis and cancer is rare. The originality of this observation is based on the discovery mode of renal tuberculosis on a piece of partial nephrectomy done for kidney tumor. Imaging allows the diagnosis of renal mass, and it is the pathological examination confirms the cell granuloma giant association with caseous necrosis and malignant cells.

## Conflict of interest

The authors declare that they have no conflicts of interest related to this article.

## References

1. Peyromaure M, Sèbe P, Darwiche F, et al. Tuberculose rénale et adénocarcinome du rein: une association trompeuse. *Prog Urol.* 2002;12:89–91.
2. Hommadi A, Ghoundale O, Drissi SM. Association d'une tuberculose et d'un cancer du rein. *J Maroc Urol.* 2009;13:27–29.
3. Miller WT. Tuberculosis in the 1990's. *Radiol Clin North Am.* 1994;32:649–661.
4. Gow JG. Genitourinary tuberculosis. In: Walsh PC, Retik AB, Stamey TA, Vaughan Jr ED, eds. *Campbell's Urology.* 7ème édition. Philadelphia: Saunders WB. Co; 1998:807–836. chapitre 24.
5. Neibling HA, Walters W. Adenocarcinoma and tuberculosis of the same kidney: review of the literature and report of seven cases. *J Urol.* 1948;59:1022–1026.
6. Pantuck A, Zisman A, Rauch MK, Beldegrun A. Incidental renal tumors. *Urology.* 2000;56:190–196.
7. Sarf I, Dahami Z, Dakir M, et al. Un nouveau cas de tuberculose rénale à forme pseudotumorale. *Ann Urol.* 2001;35:34–36.
8. Conde Redondo C, Estebanez Zarranz J, Rodriguez Toves A, et al. Tuberculosis and renal cancer. *Actas Urol Esp.* 1999;23:617–620.