

Modified Boyd's Dual Onlay Bone Graft Technique for 15 Years Old Neglected Nonunion Fracture both Bone Forearm with Severe Angular Deformity: Case Report

Dhurvas Ramlal Ramprasath¹, Vasudevan Thirunarayanan¹, Duraisamy Ezhilmaran¹

What to Learn from this Article?

Methods of treating neglected atrophic nonunions with various bone graft techniques, especially modified Boyd's dual onlay bone grafting.

Abstract

Introduction: Neglected case of nonunion of fracture both bones forearm with deformity is very difficult to manage. Treatment options are minimal. Identifying such a case in literature is also very rare. One such rare case is discussed here.

Case Report: Here, we present a case of a 65-year-old male patient, who was operated 15 years back for fracture both bones forearm, with 3.5 mm dynamic compression plate. Fracture went into nonunion and plate was broken. The patient presented to us 15 years later in August 2013 with nonunion, broken, and loosened implants and varus deformity of 90°. Implants were removed, sequential correction of deformity was done, using external fixators. After deformity correction was achieved, nonunion was managed by modified Boyd's dual onlay bone graft technique.

Conclusion: Modified Boyd's dual onlay bone graft technique is an effective method in achieving union and restoration of functions, even in patients with resistant nonunion.

Keywords: Boyd, deformity, dual onlay, forearm, nonunion.

Introduction

Malunion and nonunion, once frequent, are now uncommon, and hence the short- and long-term impairment and disability are limited [1]. Most forearm nonunions are atrophic and may have associated bony defects, infection, deformity, and osteoporosis. Forearm nonunions are only rarely encountered with very few reports in literature [2, 3, 4, 5, 6, 7]. These are seen especially after treatment of neglected cases, or cases with history of smoking, alcoholism, or other comorbidities [2, 7].

We are presenting an interesting case of neglected nonunion of fracture both bones forearm in an elderly patient, with deformity and osteoporosis, treated with modified Boyd's dual onlay bone graft technique.

Case Report

A 65-year-old male patient came to our department in August 2013, with varus deformity at the level of middle third and the distal third junction of left forearm. Detailed history revealed that he sustained fracture both bones

Access this article online

Website:
www.jocr.co.in

DOI:
2250-0685.562

Author's Photo Gallery



Dr. Dhurvas Ramlal Ramprasath



Dr. Vasudevan Thirunarayanan



Dr. Duraisamy Ezhilmaran

¹Department of Orthopaedic Surgery, Government Royapettah Hospital, Chennai, Tamil Nadu, India.

Address of Correspondence

Dr. Dhurvas Ramlal Ramprasath,
12/23, Murugappa Street, Purasawalkam, Chennai - 600 007, Tamil Nadu, India.
E-mail: dhurvasramprasath@gmail.com

forearm due to road traffic accident 15 years back, for which he was treated with open reduction and plate osteosynthesis. 6 months after the surgery, the patient fell accidentally and gradually developed deformity of the left forearm, for which the patient did not approach hospital for treatment.

Our examination (Fig. 1) revealed varus deformity of 90° in the middle third and distal third junction of left forearm, shortening of about 10 cm of left forearm, healed surgical scars over radius and ulna. Furthermore, the patient had inability to move wrist and finger joints, probably due to muscle laxity. No neurovascular deficit was encountered. There was 30° fixed flexion deformity at elbow joint with further range of flexion of 80°. Radiological examination (Fig. 2) revealed nonunion of fractured both bones forearm with broken dynamic compression plate (DCP) at radius and loosened DCP at ulna, with one screw in the subcutaneous plane. The bones were found to be osteoporotic. Our aim was to correct the deformity, achieve union at the fracture site, restore optimal function of the wrist, hand, and elbow. Our treatment strategy was planned to perform the staged procedure.

Stage 1

Implants were removed, except a screw, which was adherent to the adjacent vascular tissue. Pennig external fixator was applied on radius (Fig. 3), and universal mini external fixator was applied on ulna in another surgery. The deformity was corrected by gradually stretching (1 mm/day) the contracted soft tissue over a period of 6 weeks (Fig. 4). The neurovascular monitoring done clinically. Then, the external fixator was removed, once full correction was achieved. A long arm slab was applied in fully corrected position for 3 weeks.

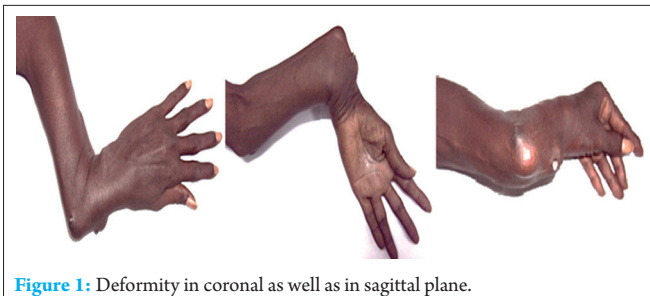


Figure 1: Deformity in coronal as well as in sagittal plane.

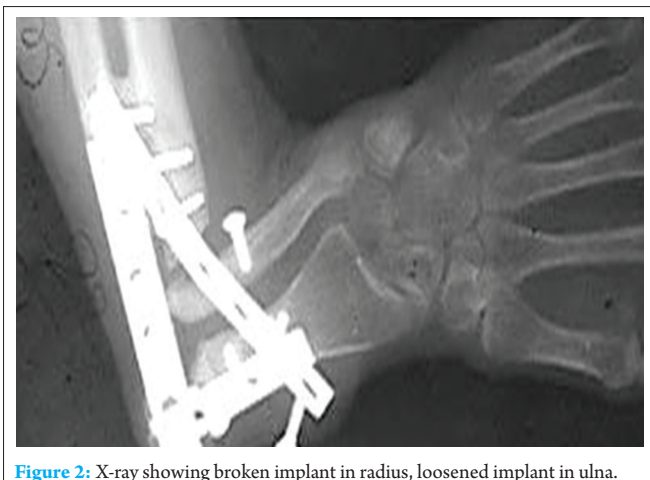

Figure 2: X-ray showing broken implant in radius, loosened implant in ulna.

Stage 2

Once the soft tissue healed and infection was ruled out, definitive fixation was done for nonunion radius (nonunion in ulna was left undisturbed, since simultaneous fixation of ulna in a scarified tissue would lead to increase in compartment pressure and difficulty in skin closure) using dual onlay fibular cortical strut grafting (procedure is explained below) with cancellous bone grafting. The fracture ends were freshened until fresh bleeding was seen from the bone ends, and medullary canal was opened with 2.5 mm drill bit before fixation was done. A gap of 2.5 cm was present. The fibular graft was harvested from left leg (direct lateral approach, middle third) leaving 6 cms of lower end of fibula for ankle stability. Cancellous bone was harvested from the left iliac crest.

The fibular graft was predrilled (with 2.5 mm drill bit), tapped and then split longitudinally into two halves using saw. The two halves of the graft were placed over the radius spanning the fracture; drilling was done through the previously drilled holes in the near onlay graft and then into host radius, and then into the opposite onlay graft (Fig. 5). The onlay graft was secured to host radius with 3.5 mm cortical screws, so as to obtain 4 cortical purchases (with each screw). The cancellous graft was placed

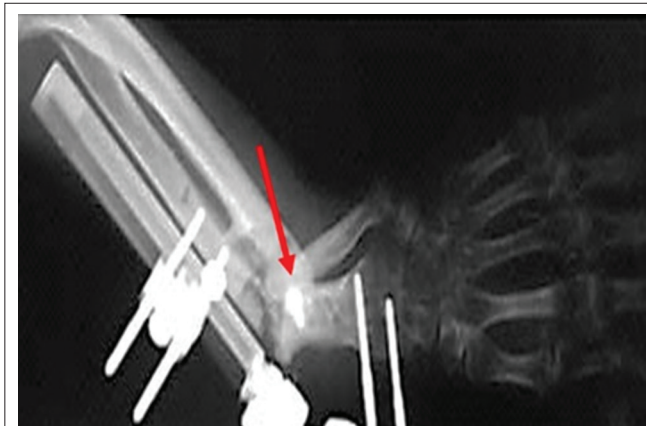

Figure 3: X-ray showing Pennig external fixator in radius (screw is adjacent to vascular tissue, hence could not be removed).

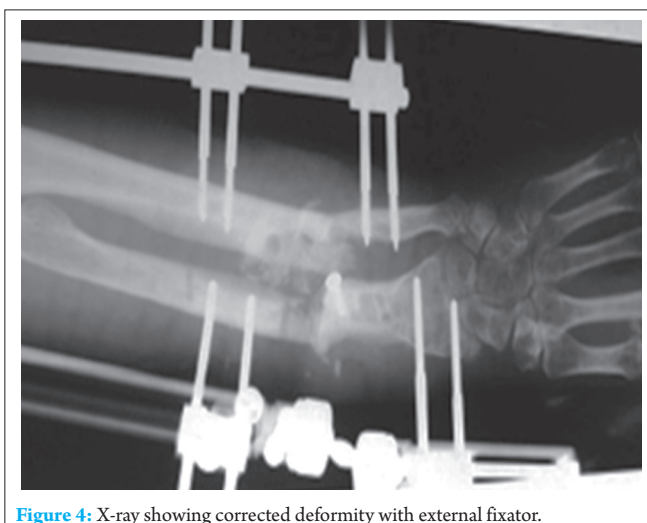

Figure 4: X-ray showing corrected deformity with external fixator.

into the trough lying between fracture ends and between the two onlay grafts. Nonunion in the ulna was left undisturbed (Fig. 6).

Follow-up

The patient was immobilized in long arm cast, in mid prone position, for 6 weeks. Immediate post-operative X-ray (Fig. 6) shows good deformity correction with graft and implants *in situ*. After 6 weeks of surgery, the patient underwent protected physiotherapy (with a splint) in the form of active and assisted mobilization of the elbow, wrist, and finger joint. The patient refused another surgery on ulna (because the patient was functionally satisfied and deformity was corrected fully). 1-year follow-up (Fig. 7) shows union at the graft site.

Results

At the end of 2 years, X-ray (Fig. 8) and cross-section image in computed tomography scan (Fig. 9) confirmed solid union between the fractured ends and also between the onlay grafts and host radius. The functions of elbow improved with range of motion of 0-140°, the function of wrist improved with the range of motion of 30° palmar flexion to 30° dorsiflexion. The functions of hand (pincer, hook, and grasp) were restored (Fig. 10). There was residual shortening of 4 cm of forearm (when compared to opposite side). There was no instability at the wrist.

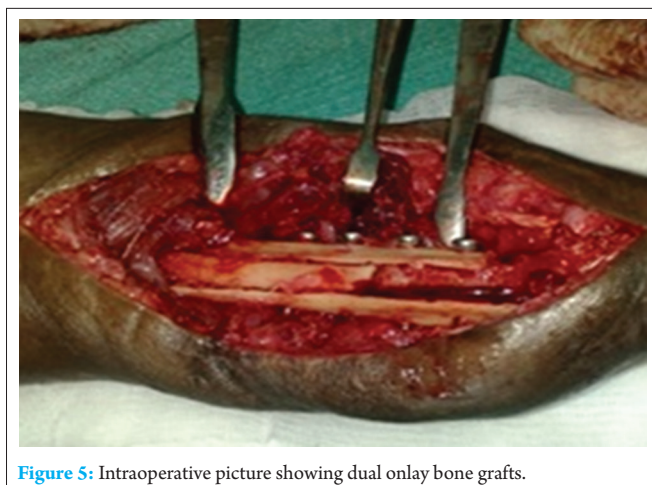

Figure 5: Intraoperative picture showing dual onlay bone grafts.

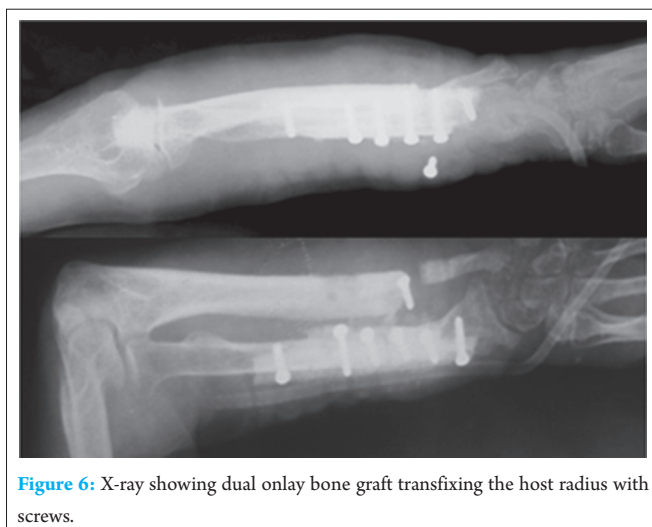


Figure 6: X-ray showing dual onlay bone graft transfixing the host radius with screws.

Discussion

Various treatment modalities devised in treating forearm bone loss include using allograft, Nicoll's cancellous insert graft [4, 6], single onlay graft [8], dual onlay graft [9, 10], Gill's massive sliding graft [10], free nonvascularized fibular graft [11], free vascularized fibular graft [2, 11], and bone transport [2]. The ideal properties of any bone graft should fulfill the following demands-osteoconduction, osteoinduction, and osteogenesis [10, 12].

Parihar and Ahuja [2], in his patient with infected gap nonunion of fracture forearm, has utilized double barrel vascular fibular graft and locking compression plate to achieve union. Dr. Campbell first reported his method of treating nonunion with single onlay graft in 1924 [8, 9]. The advantage of free vascularized fibular graft is that it can be transferred in various configurations and compositions (e.g., double barrel, multiple closing wedge osteotomized graft, and longitudinally osteotomized open book onlay graft) [11]. Nonvascularized fibular graft has been used by some authors with almost equal success rate when compared to vascularized fibular graft [13]. Of all methods of internal fixation, autogenous cortical graft is best tolerated and assists in stimulating union [14]. Even though vascularized fibular graft is superior

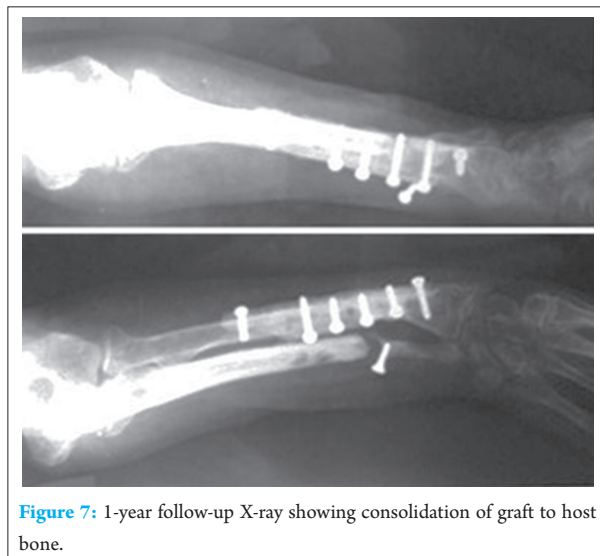


Figure 7: 1-year follow-up X-ray showing consolidation of graft to host bone.

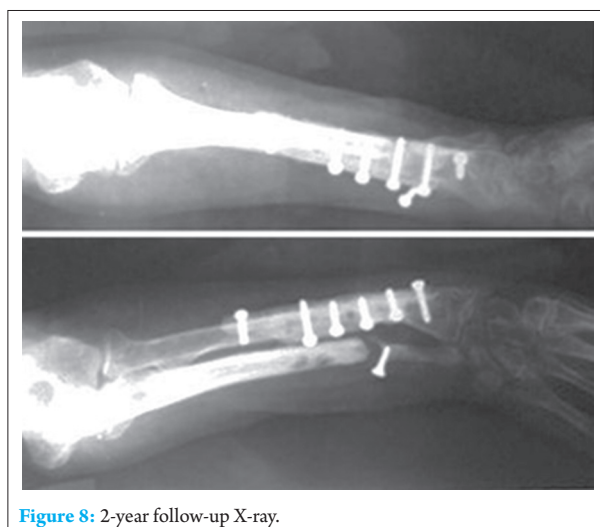


Figure 8: 2-year follow-up X-ray.

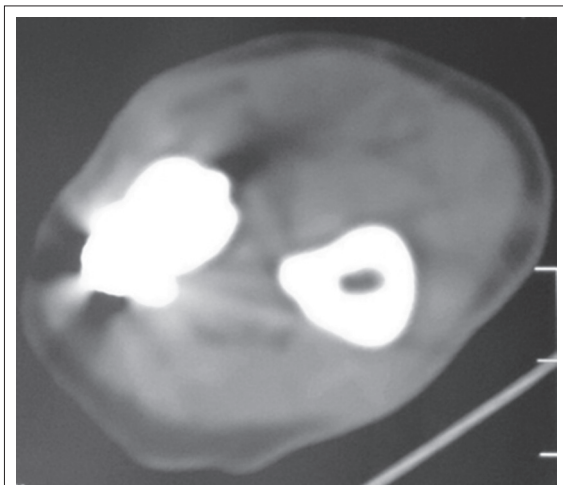


Figure 9: 2-year follow-up axial image of computed tomography scan showing solid union in radius.

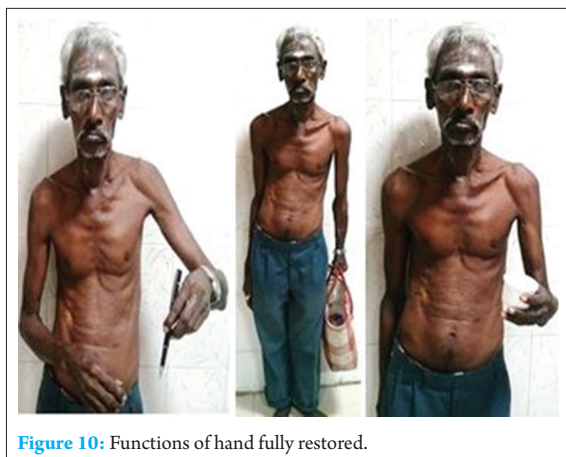

Figure 10: Functions of hand fully restored.

to nonvascularized fibular graft, harvesting and anastomosing such a graft is technically demanding.

References

1. Venkateswarlu BS, Kumar CJ. Infected gap non union of radius treated with modified Nicoll's technique - A case report. *J Clin Diagn Res* 2015;9(2):RD01-RD02.
2. Parihar M, Ahuja D. Infected nonunion of radius and ulna - Strategy of approach. *J Orthop Case Rep* 2012;2(4):26-31.
3. Hurst LC, Mirza MA, Spellman W. Vascularized fibular graft for infected loss of the ulna: Case report. *J Hand Surg Am* 1982;7(5):498-501.
4. Meals RA. The use of a flexor carpi ulnaris muscle flap in the treatment of an infected nonunion of the proximal ulna. A case report. *Clin Orthop Relat Res* 1989;240:168-172.
5. Malki A, Wong-Chung J, Hariharan V. Centralization of ulna for infected nonunion of radius with extensive bone loss. A modified Hey-Groves procedure. *Injury* 2000;31(5):345-349.
6. Dell PC, Sheppard JE. Vascularized bone grafts in the treatment of infected forearm nonunions. *J Hand Surg Am* 1984;9(5):653-658.
7. Prasarn ML, Ouellette EA, Miller DR. Infected nonunions of diaphyseal fractures of the forearm. *Arch Orthop Trauma Surg* 2010;130(7):867-873.
8. Boyd HB. The treatment of difficult and unusual non-unions. *J Bone Joint Surg Am* 1943;25(3):535-552.
9. Blumenfeld I. Pseudarthrosis of the long bones. *J Bone Joint Surg Am* 1947;29(1):97-106.
10. Canale ST, Beaty JH. *Campbell Operative Orthopaedics*, 12th ed. Philadelphia, PA: Elsevier; 2013. p. 15, 1128, 2985.
11. Malizos KN, Zalavras CG, Soucacos PN, Beris AE, Urbaniak JR. Free vascularized fibular grafts for reconstruction of skeletal defects. *J Am Acad Orthop Surg* 2004;12(5):360-369.

In 1941, Boyd devised an operation for congenital pseudarthrosis of tibia using dual cortical onlay graft fixed with screws [10]. Following are some of the advantages of Boyd's technique [8, 10].

1. Mechanical fixation by dual onlay graft is better than fixation by a single onlay graft
2. The grafts form a trough into which cancellous bone may be packed
3. During healing, the dual graft in contrast to single onlay graft prevents hemi-hourglass contracture
4. The diameter of the grafted bone is increased
5. Where one of the fragments is short, the dual graft can be made to act as a forceps, to hold the fragments
6. The cancellous bone provides quick osteoinduction, osteoconduction, and osteogenesis. Cortical bone provides stability as well as osteoconduction.

Boyd (1904-1981) has used anteromedial surface of tibia as the donor site for his dual onlay grafting and harvested cancellous graft from the undersurface of the tibial graft. However, we have used autogenous fibula, split longitudinally into two fragments for dual onlay grafting, and cancellous graft from the iliac crest.

Conclusion

Although several options are available regarding grafting, the technique which best suits the fracture pattern has to be instituted. Atrophic nonunions, especially those in juxta-articular region, associated with osteoporosis, are particularly suitable candidates for Boyd's dual onlay bone grafting since it fulfills the criteria of osteoconduction (stability), osteoinduction, and osteogenesis.

Clinical Message

The bone grafting options should be individualized for each case. Boyd's dual onlay bone graft technique has the advantage of providing stability, particularly in osteoporotic bones (apart from its osteoconductive, osteoinductive, and osteogenic properties). Addition of cancellous graft in the trough fulfills the above demands.

12. Parikh SN. Bone graft substitutes in modern orthopedics. *Orthopedics* 2002;25(11):1301-1309.
13. El-Sayed M, El-Hadidi M, El-Adl W. Free non-vascularised fibular graft for treatment of post-traumatic bone defects. *Acta Orthop Belg* 2007;73(1):70-76.
14. Boyd HB, Lipinski SW, Wiley JH. Observations on non-union of the shafts of the long bones with a statistical analysis of 842 patients. *Bone Joint Surg Am* 1961;43(2):159-168.

Conflict of Interest: Nil
Source of Support: None

How to Cite this Article

Ramprasath DR, Thirunarayanan V, Ezhilmaran D. Modified Boyd's Dual Onlay Bone Graft Technique for 15 Years Old Neglected Nonunion Fracture both Bone Forearm with Severe Angular Deformity: Case Report. *Journal of Orthopaedic Case Reports* 2016 Sep-Oct;6(4): 39-43.