



## Case Report

## Postoperative management of spontaneous pneumothorax in arthroscopic shoulder superior capsular reconstruction: A case report and review of literature

Yang-Jing Lin, Guang-Xing Chen, Ying Zhang\*

Center for Joint Surgery, Southwest Hospital, Army Medical University, Chongqing, 400038, China

## ARTICLE INFO

## Article history:

Received 28 September 2021

Received in revised form

14 February 2022

Accepted 3 March 2022

Available online 30 March 2022

## Keywords:

Spontaneous pneumothorax

Superior capsular reconstruction

Shoulder arthroscopy

Rotator cuff tear

## ABSTRACT

Arthroscopic superior capsular reconstruction is an innovative technique for the irreparable rotator cuff tears, but spontaneous pneumothorax after surgery is very rare. The present case was a 66-year-old female with irreparable rotator cuff tears of the right shoulder, treated with the arthroscopic shoulder superior capsular reconstruction. The general anesthesia and operation went smoothly, but the patient experienced stuffiness in the chest and shortness of breath after recovery from anesthesia. Thoracic CT scans showed spontaneous pneumothorax in the right side, which was successfully treated by the conservative treatments (oxygen therapy) according to multidisciplinary team. Prompt and accurate early-stage diagnosis is necessary in controlling postoperative complications and standardized treatment is the key to relieve the suffering. Spontaneous pneumothorax after arthroscopic shoulder surgery has been rarely reported in previous literatures.

© 2022 Chinese Medical Association. Production and hosting by Elsevier B.V. This is an open access article under the CC BY-NC-ND license (<http://creativecommons.org/licenses/by-nc-nd/4.0/>).

## Introduction

For irreparable rotator cuff tear, arthroscopic shoulder superior capsular reconstruction (SCR) is an advanced choice for functional reconstruction and pain relief of the shoulder joint.<sup>1</sup> Meanwhile, SCR is also one of the most complicated operations in shoulder surgery, which takes a long operation time. The complications of arthroscopic shoulder joint surgery include neuromuscular damage, infection, thromboembolic disease, fluid extravasation, etc., and the incidence is approximately 5.8%–9.5%.<sup>2</sup> However, pneumothorax has been rarely reported in patients who received shoulder arthroscopy.<sup>3,4</sup> In arthroscopic SCR cases, the complications are mostly infection, hemarthrosis, fixation failure, etc., and because of the low possibility of complications, spontaneous pneumothorax is easy to be ignored. How to make an early and accurate diagnosis is essential to relieve the patient's suffering.

We described a case with spontaneous pneumothorax after arthroscopic shoulder SCR. It indicated that spontaneous pneumothorax needs to be paid full attention to as a complication after SCR.

## Case report

A 66-year-old female was diagnosed as irreparable rotator cuff tear. She had no history of smoking, drinking or other conditions. The patient's preoperative chest X-ray showed negative findings (Fig. 1). She was then treated by SCR under arthroscope. Two anchors (Smith and Nephew, 4.5 mm) were inserted to the great tubercle of the proximal humerus, and another two anchors were inserted to the superior glenoid. Endotracheal tube was performed and no brachial plexus block was administered. The operation was performed under general anesthesia. The process of anesthesia and operation were uneventful.

Four arthroscopic portals were used, including the anterior portal, the posterior portal, the Neviaser portal and the lateral portal. Blood pressure, heart rhythm and pulse oxygen saturation were stable at 3 h after surgery. The patient suffered from chest tightness and shortness of breath after anesthesia. Arterial oxygen saturation fluctuated between 92% – 94% with nasal oxygen, and the flow rate of oxygen was 5 L/min. Physical examination showed no rhonchus and moist rales, while right lung breath sounds were weak. Subcutaneous emphysema and crepitant rales under the skin were checked around the right side of neck and chest wall. Thoracic CT scans were conducted. Thoracic CT scans revealed pneumothorax (lung compression ratio, 10%–20%), pneumomediastinum and subcutaneous emphysema (Fig. 2A and B). According to the opinion of the respiratory department, conservative treatment

\* Corresponding author.

E-mail address: [33415832@qq.com](mailto:33415832@qq.com) (Y. Zhang).

Peer review under responsibility of Daping Hospital and the Research Institute of Surgery of the Third Military Medical University.

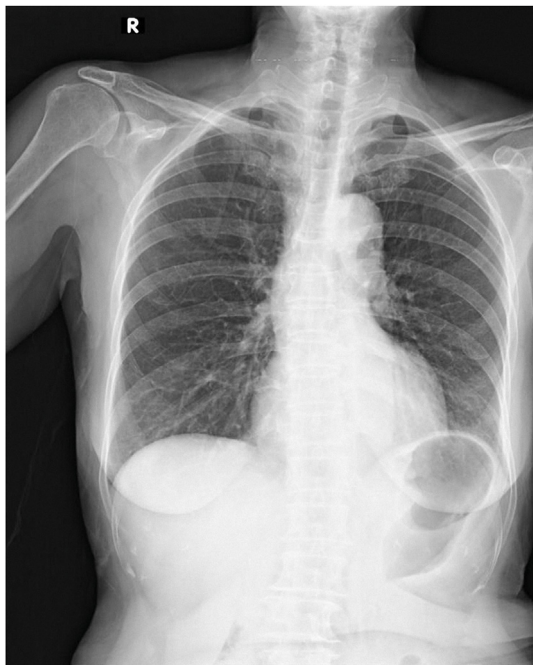

Fig. 1. Preoperative chest X-ray did not show any abnormal finding.

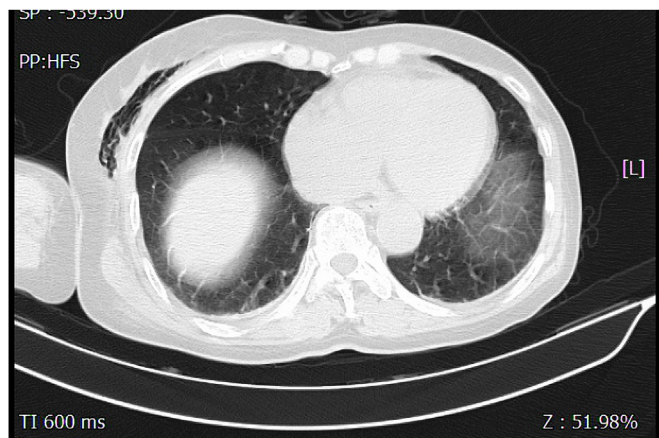


Fig. 3. After 2 days, CT reexamination showed that pneumothorax and subcutaneous emphysema were almost vanished.

including oxygen therapy (via a facemask 5 L/min) and lying in bed were performed. After 2 days, CT re-examination showed that pneumothorax, pneumomediastinum and subcutaneous emphysema almost vanished (Fig. 3). Two days later, the patient was discharged from the hospital without chest stiffness, shortness of breath or any other discomfort.

**Discussion**

Nowadays, arthroscopic shoulder surgery has become a major minimally invasive technique for rotator cuff tears patients. It is widely accepted as an efficient therapy for joint functional reconstruction around the world. Various complications after arthroscopic shoulder surgery have been reported, such as infection, bleeding, postoperative pain, joint stiffness, rotator cuff retear, deep venous thrombosis, and so on,<sup>5,6</sup> but spontaneous pneumothorax after surgery has been rarely reported.

Bamps et al.<sup>2</sup> reported a 42-year-old male patient who developed an ipsilateral pneumothorax after shoulder arthroscopy.

Cassone et al.<sup>7</sup> presented a case of a 60-year-old female with right-sided facial swelling suffered from shortness of breath 3 h after a shoulder arthroscopy and a right-sided pneumothorax. Shariyate et al.<sup>8</sup> reported a 61-year-old female with massive emphysema, who developed pneumothorax following an arthroscopic rotator cuff repair. These three cases had much in common, including no history of pulmonary diseases and smoking, and performance of general anesthesia without regional nerve block.

In this case, no brachial plexus block was administered. The shoulder is close to the thorax which increases the risk of injuring thoracic cavity when performing complex operations, such as electric drill operating near the scapular glenoid and brachial plexus block. Long-time operation might lead to spontaneous pneumothorax after arthroscopic shoulder reconstruction. However, there were no reports in the literature supporting this assumption. In this case, by reviewing the surveillance video, it showed that there was no mistake in the electric drill during the operation, which indicated that there was no association between SCR and spontaneous pneumothorax.

According to previous studies, risk factors for patients with pneumothorax included history of smoking, physical activity, chronic obstructive pulmonary disease (COPD), asthma and air pressure changes.<sup>9–11</sup> Sometimes it was hard to identify the precise causes of pneumothorax. Pressure assisted ventilation, brachial plexus block, intubation and surgery may be related to spontaneous pneumothorax in arthroscopic shoulder surgery.<sup>12</sup> In this case, the patient had no history of smoking, COPD or asthma. We had

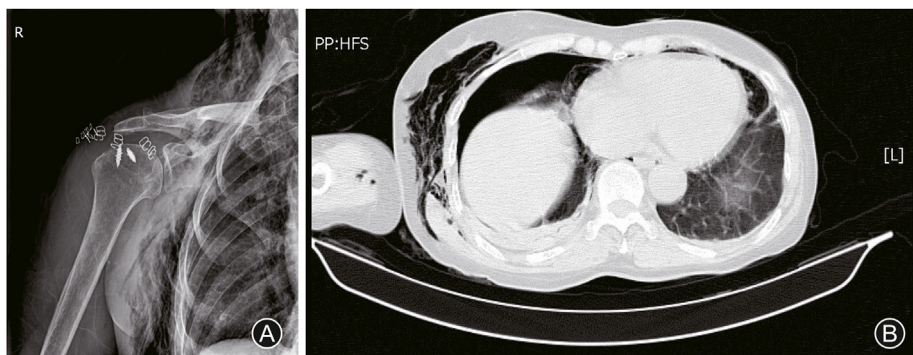


Fig. 2. A 66-year-old female suffered from irreparable massive rotator cuff tear and underwent shoulder superior capsular reconstruction in the arthroscopic. (A) Subcutaneous emphysema after the arthroscopic shoulder superior capsular reconstruction surgery; (B) Slight pneumothorax and subcutaneous emphysema were observed through thoracic CT scans.

checked records and found no anesthesia complications or pulmonary decompensation. The video of surgical procedures was checked, and no intraoperative complication was found. For each patient, a careful medical history including history of smoking, pulmonary disease such as asthma, COPD and emphysema should be recorded. And preoperative chest X-ray should also be obtained to help identify pulmonary diseases.

Prompt and accurate early-stage diagnosis of spontaneous pneumothorax is required. In this case, it was mostly based on the physical examination. Subcutaneous emphysema and crepitant rales under the skin were rapidly checked at the right side of neck and chest wall. By palpating the skin of neck and chest wall, crepitant rales might suggest pneumothorax, pneumomediastinum or subcutaneous emphysema. Subsequently, relevant auxiliary inspection should be carried out for timely diagnosis and treatment. Oxygen therapy is one of the effective non-surgical treatments for spontaneous pneumothorax. Small pneumothoraces (lung compress <20%) can be absorbed and dissipated for itself by oxygen therapy in accordance with the American College of Chest Physicians guidelines.<sup>13</sup> The review of literature illustrated that the resolution rate of pneumothorax was 1.25% per day without oxygen therapy.<sup>14</sup> Park et al.<sup>15</sup> reported that the resolution rate was (4.27% ± 1.97%) per day under oxygen therapy (via a nasal cannula at 2–4 L/min). In our case, the patient suffered from small pneumothoraces and was treated with oxygen therapy (5 mL/min). The treatment was successful, but for the patient suffering from massive emphysema and pneumothorax, a chest tube and oxygen therapy was required. The therapy strategy of pneumothorax needs to be flexibly changed according to the actual conditions.

In this study, spontaneous pneumothorax as a complication after arthroscopic shoulder SCR required high attention. Prompt and accurate diagnosis for spontaneous pneumothorax after surgery is important. Basic physical examinations can help identify the complication immediately, and conservative treatment is effective.

#### Funding

Nil.

#### Ethical statement

The patient's consent has been obtained.

#### Declaration of competing interest

The authors have no personal, financial or institutional interest in any of the drugs, materials, or devices described in this article.

#### Acknowledgments

Authors thank Xin Chen for proofreading services.

#### Author contributions

Yang-Jing Lin made investigation and data collection, wrote the original draft. Guang-Xing Chen provided resources and supervision. Ying Zhang performed the surgery and edited the text.

#### References

- Jordan RW, Sharma N, Daggett M, et al. The role of Superior Capsule Reconstruction in the irreparable rotator cuff tear - a systematic review. *Orthop Traumatol Surg Res.* 2019;105:1535–1542. <https://doi.org/10.1016/j.otsr.2019.07.022>.
- Bamps S, Renson D, Nijs S, et al. Pneumothorax after shoulder arthroscopy: a rare but life-threatening complication. *J Orthop Case Rep.* 2016;6:3–5. <https://doi.org/10.13107/jocr.2250-0685.542>.
- Oldman M, Peng Pi P. Pneumothorax after shoulder arthroscopy: don't blame it on regional anesthesia. *Reg Anesth Pain Med.* 2004;29:382–383. <https://doi.org/10.1016/j.rapm.2004.04.002>.
- Weber SC, Abrams JS, Nottage WM. Complications associated with arthroscopic shoulder surgery. *Arthroscopy.* 2002;18:88–95. <https://doi.org/10.1053/jars.2002.31801>.
- Öner K, Okutan AE, Ayas MS, et al. Predicting postoperative pain with neutrophil/lymphocyte ratio after arthroscopic rotator cuff repair. *Asia Pac J Sports Med Arthrosc Rehabil Technol.* 2020;20:24–27. <https://doi.org/10.1016/j.asmart.2020.03.001>.
- Chen JW, Zheng XF, Zheng BY, et al. Research progress on complications of arthroscopic rotator cuff repair. *Chin Orthop J Clin Basic Res.* 2019;11:52–58. <https://doi.org/10.3969/j.issn.1674-666X.2019.01.009>.
- Cassone MA, Kish KL, Nester JR, et al. Case report and literature review: post-arthroscopy pneumothorax with anterior decompression. *Clin Pract Cases Emerg Med.* 2020;4:580–583. <https://doi.org/10.5811/cpcem.2020.8.48618>.
- Shariyate MJ, Kachooei AR, Ebrahimzadeh MH. Massive emphysema and pneumothorax following shoulder arthroscopy under general anaesthesia: a case report. *Arch Bone Jt Surg.* 2017;5:459–463.
- Bense L, Eklund G, Wiman LG. Smoking and the increased risk of contracting spontaneous pneumothorax. *Chest.* 1987;92:1009–1012. <https://doi.org/10.1378/chest.92.6.1009>.
- John C, Steven K. Spontaneous pneumothorax. *Educ Teach Emerg Med.* 2017;2:22–24. <https://doi.org/10.5070/M524036782>.
- Alifano M, Forti Parri SN, Bonfanti B, et al. Atmospheric pressure influences the risk of pneumothorax: beware of the storm. *Chest.* 2007;131:1877–1882. <https://doi.org/10.1378/chest.06-2206>.
- Leander-Olsson O, Borglund-Hemph A, Jakobsson JG. Pneumothorax following shoulder arthroscopy under combined regional and general anaesthesia-A case report. *Int J Surg Case Rep.* 2016;24:73–76. <https://doi.org/10.1016/j.ijscr.2016.05.012>.
- Baumann MH, Strange C, Heffner JE, et al. Management of spontaneous pneumothorax: an American College of chest Physicians delphi consensus statement. *Chest.* 2001;119:590–602. <https://doi.org/10.1378/chest.119.2.590>.
- Kircher LT, Swartzel RL. Spontaneous pneumothorax and its treatment. *J Am Med Assoc.* 1954;155:24–29. <https://doi.org/10.1001/jama.1954.03690190030009>.
- Park CB, Moon MH, Jeon HW, et al. Does oxygen therapy increase the resolution rate of primary spontaneous pneumothorax? *J Thorac Dis.* 2017;9:5239–5243. <https://doi.org/10.21037/jtd.2017.10.149>.