



The Brazilian Journal of INFECTIOUS DISEASES


www.elsevier.com/locate/bjid



Clinical image

“Penumbra sign” of Brodie’s abscess



William F. Wright 

Johns Hopkins University School of Medicine, Department of Medicine, Division of Infectious Diseases, Baltimore, MD, USA

ARTICLE INFO

Article history:

Received 22 December 2019

Accepted 26 March 2020

Available online 25 April 2020

A 31-year-old female presented to the emergency department with a 2-year history of worsening right knee pain. She had no history of trauma, tuberculosis infection or known exposure. The physical examination revealed tenderness and swelling of the proximal right tibia without joint effusion. Laboratory studies revealed a white-cell count of 8900/mm³ (reference range, 3900–9500), a hemoglobin level of 13.5 g/dL (reference range, 12.8–16.6), a platelet count of 261,000/mm³ (reference range, 140,000–366,000), a creatinine level of 0.63 mg/dL (reference range, 0.7–1.3 mg/dL), erythrocyte sedimentation rate of 52 mm/h (reference range, 0–20 mm/h), and C-reactive protein of 1.0 mg/dL (reference range, <1.0 mg/dL). Magnetic resonance imaging (MRI) of the right tibia with the use of gadolinium enhancement revealed a rim of tissue lining an abscess cavity in the proximal metaphysis with minor signal hyperintensity relative to the main abscess contents on T1-weighted imaging

(the “penumbra sign”; panel A). A post contrast fat saturation image demonstrates enhancement of the granulation tissue (panel B). This radiographic sign is considered a characteristic MRI feature of subacute osteomyelitis but can be seen in tuberculosis osteitis, osteoid osteoma, chondrosarcoma, eosinophilic granuloma as well as in benign cystic neoplasm and intraosseous ganglion.¹ McGuinness et al. reported that the penumbra sign has a high specificity of 96% but low sensitivity of 27% for musculoskeletal infections and is helpful in differentiating neoplasm from infection.¹ The proximal tibia is the most frequent site of involvement and *Staphylococcus aureus* is the most commonly identified pathogen.² Cultures from the tibial abscess grew methicillin-sensitive *Staphylococcus aureus*; a mycobacterial culture was negative. A drain was placed, and the patient was treated with cefazolin two grams every eight hours for six weeks. The patient’s pain resolved, and she

E-mail address: wwrigh19@jhmi.edu

<https://doi.org/10.1016/j.bjid.2020.03.003>

1413-8670/© 2020 Sociedade Brasileira de Infectologia. Published by Elsevier España, S.L.U. This is an open access article under the CC BY-NC-ND license (<http://creativecommons.org/licenses/by-nc-nd/4.0/>).

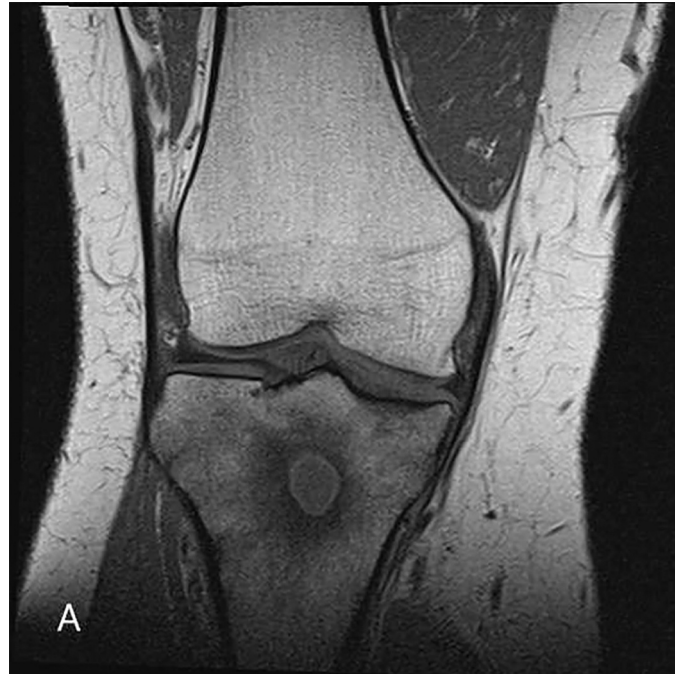

Fig. 1A – T1 coronal MR image shows a Brodie's abscess with the characteristic “penumbra sign” (thin mildly hyperintense rim of granulation tissue surrounding a low intensity fluid filled abscess cavity).

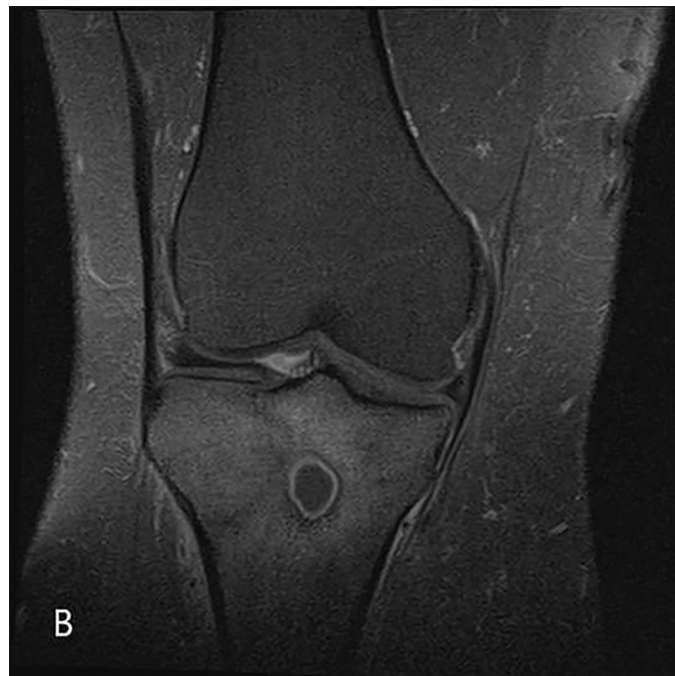

Fig. 1B – T1 post contrast fat saturation image shows enhancement of the granulation tissue.

was discharged on the fifth postoperative day. At follow-up 2 months after surgery, she remained free of symptoms (Fig. 1).

Funding

This research did not receive any specific grant from funding agencies in the public, commercial, or not-for-profit sectors.

REFERENCES

1. McGuinness B, Wilson N, Doyle AJ. The “penumbra sign” on T1-weighted MRI for differentiating musculoskeletal infection from tumour. *Skelet Radiol.* 2007;36:417–21.
2. van der Naald N, Smeeing DPJ, Houwert RM, Hietbrink F, Govaert GAM, van der Velde D. Brodie's abscess: a systematic review of reported cases. *J Bone Jt Infect.* 2019;4:33–9.