

Study on the association between TGF- β 1 and liver fibrosis in patients with hepatic cystic echinococcosis

FENGMING TIAN^{1*}, YUMEI LIU^{1*}, JIAN GAO², NING YANG¹, XIAOQIAN SHANG¹,
JIE LV¹, DERONG BA¹, XUAN ZHOU¹, CHUNTAO ZHANG² and XIUMIN MA^{1,2}

¹State Key Laboratory of Pathogenesis, Prevention and Treatment of High Incidence Diseases in Central Asia, Clinical Medical Research Institute of First Affiliated Hospital of Xinjiang Medical University;

²College of Basic Medicine of Xinjiang Medical University, Urumqi, Xinjiang 830011, P.R. China

Received June 29, 2019; Accepted November 27, 2019

DOI: 10.3892/etm.2019.8355

Abstract. The present study aimed to determine the role of the cytokine transforming growth factor- β 1 (TGF- β 1) in liver fibrosis among patients with hepatic cystic echinococcosis (hepatic CE). Hepatic tissue specimens and serum samples from 30 patients with hepatic CE were collected and TGF- β 1 levels were compared between the two groups. The degree of liver fibrosis was assessed by Masson staining. The expression levels of cytokine TGF- β 1 in liver tissue and serum were detected by immunohistochemistry and ELISA, respectively. Masson staining of liver lesion tissue in patients with hepatic CE indicated different degrees of fibrosis in the liver and the World Health Organization classification was positively correlated with the severity of liver fibrosis ($P < 0.05$). In addition, the expression of cytokine TGF- β 1 was higher in liver lesion tissue specimens compared with that in the adjacent control samples ($P < 0.05$). At the same time, cytokine TGF- β 1 in serum specimens of patients was higher than that in the healthy control group ($P < 0.05$). In conclusion, the expression of TGF- β 1 is upregulated in patients with hepatic CE, which was closely associated to liver fibrosis.

Introduction

Cystic echinococcosis (CE) is a zoonotic parasitic disease with worldwide prevalence, which is caused by infection with *Echinococcus granulosus* (Eg) (1). For example,

infection is more common in countries and regions with animal husbandry (1,2). Xinjiang Uygur Autonomous Region of China is one of the areas with the highest prevalence of CE. According to a survey, the Eg infection rate is 3.1-31.5% and the prevalence rate of CE disease is 0.5-5.0% (1). In ~65% of affected individuals, the disease has no specific clinical signs and is not distinguishable from any other diseases with similar signs. Clinical symptoms depend on the organs involved (e.g. lung, liver, brain and bone), the number, size and location of cysts, the invasion of cysts into adjacent organs and the induction of immunological reactions, including asthma and anaphylaxis (3).

Liver fibrosis is a pathological process in chronic Eg infection. Infection of Eg stimulates and activates hepatic stellate cells, resulting in secretion of a large number of collagen fibers and thereby causing excessive deposition of extracellular matrix (ECM). This process is regulated by a variety of cytokines (4-6). Studies have indicated that the cytokine transforming growth factor- β 1 (TGF- β 1) has a crucial role in wound healing and fibrosis of tissues and organs (7-12). It is also an important factor mediating cellular processes, including cell growth, differentiation, apoptosis and cellular homeostasis (13). It has been indicated that TGF- β 1 cytokines are involved in chronic Eg infection (14,15). At the same time, TGF- β 1 is an important cytokine in the development and progression of liver fibrosis. Overexpression of TGF- β 1 in the liver may lead to severe liver fibrosis. However, how TGF- β 1 influences liver fibrosis in hepatic CE remains a topic requiring further investigation. In the present study, the expression of TGF- β 1 in liver tissues and serum of patients with hepatic CE was detected to investigate the association between TGF- β 1 and hepatic fibrosis and its significance in early diagnosis.

Materials and methods

Case source and grouping. A total of 30 patients with hepatic CE admitted to the First Affiliated Hospital of Xinjiang Medical University (Urumqi, China) between July 1, 2013 and June 1, 2017 were enrolled in the present study. The age of the patients ranged from 9 to 74 years (median age, 28 years) and the male-to-female ratio was 12/18. Paired liver lesion tissue and normal tissue were obtained from each patient.

Correspondence to: Dr Xiumin Ma, State Key Laboratory of Pathogenesis, Prevention and Treatment of High Incidence Diseases in Central Asia, Clinical Medical Research Institute of First Affiliated Hospital of Xinjiang Medical University, 137 South Liyushan Road, Urumqi, Xinjiang 830011, P.R. China
E-mail: maxiumin1210@sohu.com

*Contributed equally

Key words: cystic echinococcosis, cytokine, transforming growth factor- β 1, liver, fibrosis

Healthy control subjects (matched with the hepatic CE patients according to age and sex) visited the First Affiliated Hospital of Xinjiang Medical University (Urumqi, China) for medical examination. Name, age, sex and hospitalization date were checked to confirm that there were no duplicate cases.

Inclusion criteria. The diagnosis of patients with hepatic CE (patients confirmed by B-mode ultrasonography first, underwent liver cystic hydatidosis partial hepatectomy and their biopsy specimen could be collected) was in accordance with the classification diagnostic criteria formulated by the World Health Organization (WHO) echinococcosis unofficial working group (16); the classification was intended to follow the natural history of CE and started with undifferentiated simple cysts, as presumably, hydatid cysts evolve from these structures. This was confirmed by intra-operative and post-operative pathological diagnosis (16). The patients were grouped based on their WHO classification as follows: CL, as group 1-Active group: Cysts developing and are usually fertile (contained numerous viable protoscoleces); Type CE₁-CE₃, as group 2-Transition group: Cysts starting to degenerate, but usually still contain viable protoscoleces; Type CE₄-CE₅, as group 3-Inactive group: Degenerated or partially or totally calcified cysts-unlikely to be fertile. The 30 hepatic CE patients were classified into stages of CL (0 cases), CE₁ (13 cases), CE₂ (11 cases), CE_{3a/b} (0 cases), CE₄ (5 cases) and CE₅ (1 case). All study subjects had provided written informed consent and the study protocols were approved by the ethics committee of the First Affiliated Hospital of Xinjiang Medical University (Urumqi, China; approval nos. ZACUS-201304255002 and 20160218-14) and received informed consent from all subjects. For the minors (<18 years of age) that participated in the study, written informed consent was provided by their parents/legal guardians.

Exclusion criteria. The following exclusion criteria were applied: i) Acute and chronic viral infections and autoimmune diseases; ii) rheumatic diseases and malignant tumors; iii) conditions including severe respiratory infections, hepatobiliary infections, sepsis and hyperpyrexia that are not directly associated with echinococcosis infection; iv) long-term use of inflammatory inhibitors, including steroids, non-steroidal anti-inflammatory drugs and opioids.

Blood samples. From each of the 30 patients with hepatic CE and the healthy individuals, 3 ml venous blood was collected. Peripheral blood was centrifuged at 1,008 x g for 10 min at 20°C; one aliquot of the serum was used for liver function tests, including total protein, albumin, alanine aminotransferase and aspartate aminotransferase levels, while the other part was stored in a refrigerator at -20°C for ELISA.

Hepatic tissue specimens. A total of 30 patients with hepatic CE were enrolled in the present study. Each patient underwent biopsy of normal hepatic tissue (the normal hepatic tissue 2 cm away from the lesion) used as the control group and hepatic tissue adjacent to the lesion, which was not directly part of the lesion, as the case group (within 2 cm of the lesion) (17). The obtained specimens were kept in 10% formaldehyde and then embedded in paraffin for preparation of 3- μ m slices, which

were reserved for H&E staining, Masson's trichrome staining and immunohistochemistry.

Histopathological analysis. H&E staining and Masson staining (Masson Trichrome Staining kit; Maixin Biotechnologies, Inc.) of hepatic tissue: All specimens were kept in 10% formaldehyde, embedded in paraffin and then serially sectioned at a thickness 3 μ m. After H&E staining and Masson staining, pathological changes in hepatic tissue were observed under a microscope (BX43; Olympus Corp.), including the presence or absence of liver fibrosis and if present, the degree of liver fibrosis was assessed (18).

Immunohistochemistry. Paraffin sections were subjected to gradient dehydration. Diaminobenzidine color development was performed according to the instructions of the two-step immunohistochemistry kit (OriGene Technologies, Inc.). Rabbit anti-human TGF- β 1 antibody was from Santa Cruz Biotechnologies, Inc.). Images of 5 fields of view were randomly captured under a high-power microscope (BX43; Olympus Corp.) and the area occupied by positive and negative staining was quantified using Ipp6.0 software (Intel). The percentage of positive area and standard deviation were calculated.

ELISA. For detection of TGF- β 1 in the serum, an ELISA kit (Bender Med System) was used in accordance with the manufacturer's protocol.

Statistical analysis. All experimental data were statistically analyzed using SPSS software version 17.0 (SPSS, Inc.). Quantitative data are expressed as the mean \pm standard deviation. The Student's test was used for comparison between the data of two groups. Spearman's correlation coefficient was determined to assess the correlation between WHO classification and severity of liver fibrosis. Ipp6.0 software (Intel) was used for quantitative analysis of morphological results. P<0.05 was considered to indicate a statistically significant difference.

Results

General information. The cohort comprised 30 patients with hepatic CE. The age ranged from 9 to 74 years. In accordance with the classification diagnostic criteria (16) and their clinicopathological features, 30 hepatic CE patients were classified into stages of CL (0 cases), CE₁ (13 cases), CE₂ (11 cases), CE_{3a/b} (0 cases), CE₄ (5 cases) and CE₅ (1 case). The mean diameter of lesions was 7.78 \pm 4.43 cm and the median diameter of lesions was 7.35 cm.

Laboratory examination. The 30 patients with hepatic CE were diagnosed with echinococcosis by imaging, surgery and pathology. Prior to the operation, B-mode ultrasonography is the major examination method for hepatic CE, which may determine the classification of echinococcosis, as well as the location, number, size and structure of hepatic CE lesions, and provide a reference for pre-operative diagnosis, selection of surgical sites and observation of treatment effects (19). On B-mode ultrasonography, different degrees of liver fibrosis were detected. Furthermore, liver function test and assessment of total protein, albumin, alanine aminotransferase

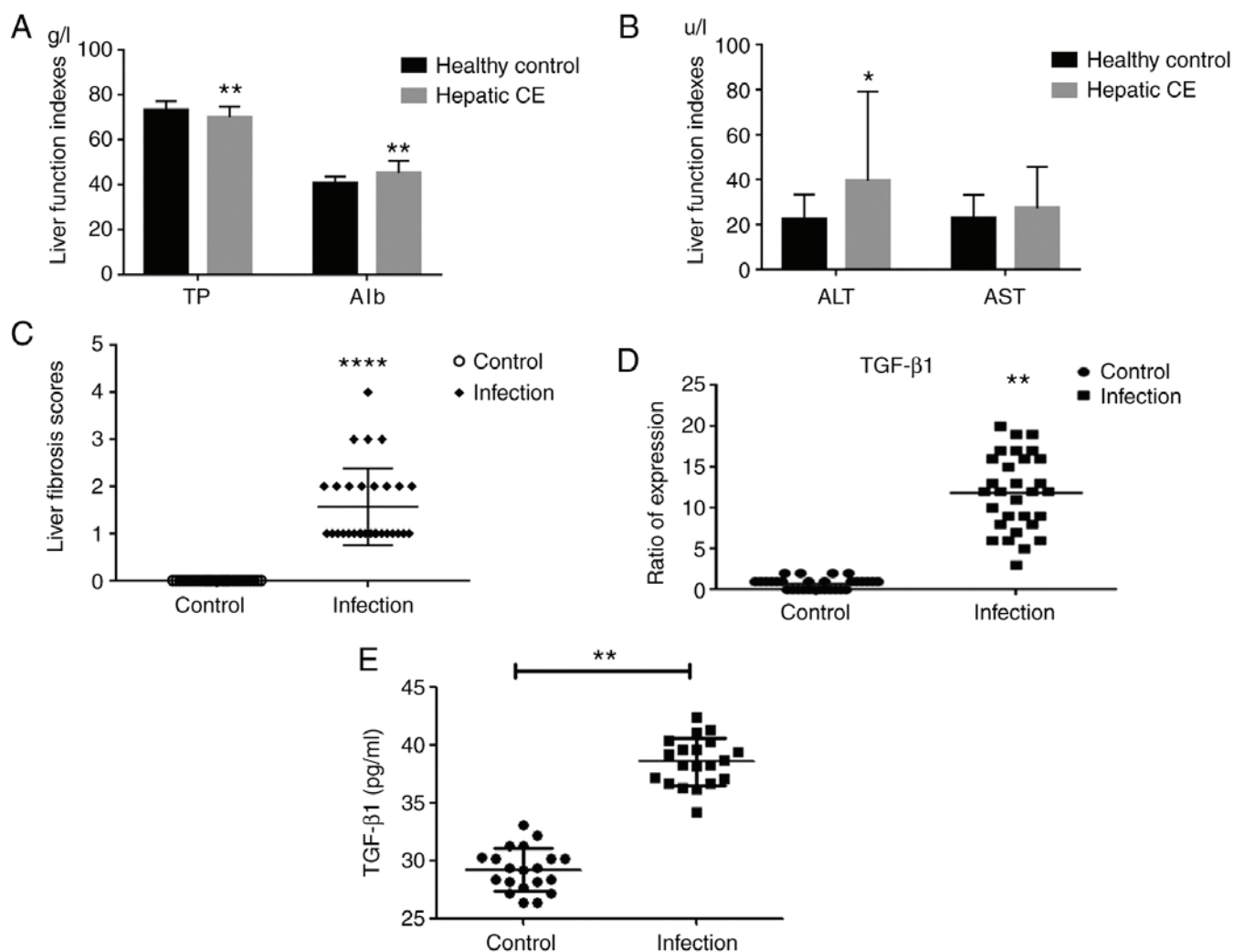


Figure 1. (A and B) Comparison of liver function indicators between hepatic CE and healthy control group. (C) Cases of liver fibrosis scores in Masson staining. (D) The variation diagram of TGF-β1 expression in the hepatocytes. (E) The serum concentration of cytokine TGF-β1 (pg/ml). *P<0.05, **P<0.01, ****P<0.0001 vs. control. TGF, transforming growth factor; CE, cystic echinococcosis; ALT, alanine aminotransferase; AST, aspartate aminotransferase; TP, total protein; Alb, albumin.

and aspartate aminotransferase levels were performed for these 30 patients. The results were significantly different in comparison with those of the healthy control group. It was clearly indicated that liver function damage was present in patients with hepatic CE (Fig. 1A and B).

Pathology of liver tissue. Microscopic observation of H&E-stained tissue indicated that the boundary of hepatocytes in normal hepatic tissue was clear and the structure of hepatic lobules was intact. Edema appeared in the hepatic cells adjacent to the lesion in patients with hepatic CE. The structure of certain hepatic lobules was destroyed, collagen fiber deposition was observed and necrotic hepatic cells were present (Fig. 2A and B).

On Masson staining, the hepatic tissue of patients with hepatic CE exhibited different degrees of hepatic steatosis and spot-like necrosis of certain liver cells was observed. Fibrous tissue hyperplasia and its extension into the lobular area were observed in the portal area. Furthermore, fibrous tissue was distributed in the portal area. In certain patients with hepatic hydatid cyst, Masson staining resulted in blue staining in the

hepatic portal area and the outer area of the hydatid cyst. In the control group, only a small amount of blue staining was observed around the elastic fibers in the blood vessel wall, whereas no obvious fibrous tissue was observed in other regions of hepatic tissue (Fig. 2C and D). At the same time, the liver fibrosis score was obtained from hepatic lesion tissue of each patient with hepatic CE (Fig. 1C). The correlation between WHO classification and severity of liver fibrosis was analyzed, revealing that the WHO classification was positively correlated with the severity of liver fibrosis ($R=0.399$, $P<0.05$; Table I).

Expression of cytokine TGF-β1 in liver tissue of patients with hepatic CE. Cytokine TGF-β1 was not substantially expressed in normal hepatic tissues. The expression of TGF-β1 in the hepatic lesion tissue of patients with hepatic CE was mainly located in the cytoplasm of hepatocytes (Figs. 1D, 2E and F). The relative levels of TGF-β1 in hepatic lesion tissue were 11.87 ± 4.64 and 0.73 ± 0.69 in the control group ($P<0.01$).

Changes in serum TGF-β1 levels in patients with hepatic CE. In order to determine the cytokine TGF-β1 expression

Table I. Correlation analysis between WHO classification and severity of liver fibrosis.

WHO classification	Cases	Sex		Liver fibrosis scores in patients with hepatic CE				
		Male	Female	0	1	2	3	4
CL	0	0	0	0	0	0	0	0
CE ₁	13	7	6	0	10	3	0	0
CE ₂	11	6	5	0	6	4	1	0
CE _{3a/b}	0	0	0	0	0	0	0	0
CE ₄	4	4	0	0	1	0	2	1
CE ₅	2	1	1	0	1	1	0	0

Among the 30 patients with hepatic CE, the age ranged from 9 to 74 years (mean age, 31.1 ± 16.4 years; median age, 28 years). The Spearman correlation coefficient was determined to assess the correlation between WHO classification and severity of liver fibrosis ($R=0.399$, $P<0.05$). WHO, World Health Organization; CL, cystic lesions; CE, cystic echinococcosis.

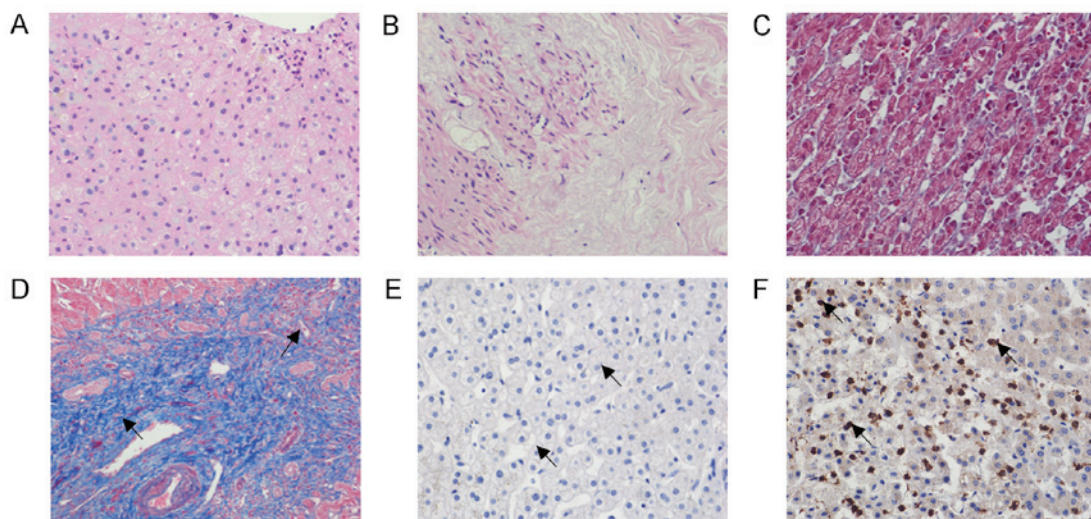


Figure 2. (A) H&E staining of hepatic normal tissue in patients with hepatic CE. The boundary of hepatocytes in normal hepatic tissue was clear and the structure of hepatic lobules was intact. (B) H&E staining of hepatic lesion tissue in patients with hepatic CE. Edema appeared in the hepatic cells adjacent to the lesion in patients with hepatic CE. The structure of certain hepatic lobules was destroyed, collagen fiber deposition was observed and necrotic hepatic cells were present. (C) Masson staining of hepatic normal tissue in patients with hepatic CE. Only a small amount of blue staining was observed around the elastic fibers in the blood vessel wall, whereas no obvious fibrous tissue was observed in other regions of hepatic tissue. (D) Masson staining of hepatic lesion tissue in patients with hepatic CE. Arrows indicate the collagen fiber deposition. Fibrous tissue hyperplasia and its extension into the lobular area were observed in the portal area. Furthermore, fibrous tissue was distributed in the portal area. (E) Immunohistochemistry indicating TGF- β 1-negative cells in hepatic normal tissue of patients with hepatic CE. Arrows indicate that TGF- β 1-positive cells were not abundant in normal hepatic tissues. (F) Immunohistochemistry indicating TGF- β 1-positive cells in hepatic lesion tissue of patients with hepatic CE. Arrows indicate positive staining mainly located in the cytoplasm of hepatocytes. Magnification, x200. CE, cystic echinococcosis; TGF, transforming growth factor.

in peripheral blood of patients with hepatic CE, the serum levels of TGF- β 1 in each group were determined by ELISA. It was indicated that the expression of TGF- β 1 in serum was significantly increased in the group of patients with hepatic CE in comparison with that in the healthy control group (Fig. 1E).

Discussion

On the basis of extensive necrosis of hepatocytes, liver fibrosis produces diffuse hyperplasia of liver fibrous tissue. Upon further progression, cirrhosis may occur and subsequently, regenerated nodules and pseudolobules are formed, resulting in a normal structural and vascular anatomy of the liver. Hepatic CE refers to a cystic change caused by the invasion of the parasite *Eg* into

the liver. Hepatic fibrosis occurs when the worm body causes damage to the liver through direct erosion, toxic damage and mechanical pressure. Hepatic fibrosis affects the function of the liver. Further progression may cause cirrhosis and even hepatic failure. Early hepatic fibrosis is reversible, whereas cirrhosis is basically irreversible. Therefore, prevention and treatment of early hepatic fibrosis are of particular importance. TGF- β 1 is a multifunctional cytokine involved in various biological processes, including tumors, inflammatory cell differentiation and tissue repair (20,21) High expression of TGF- β 1 was reported in lymphocytes surrounding hepatic lesions and high expression of inflammatory cytokine TGF- β 1 was observed around hepatic lesions of patients with alveolar echinococcosis (AE) and in a mouse *Em* infection model (22,23). AE is a severe chronic

helminthic disease caused by the intra-hepatic tumor-like growth of the metacystode of *Echinococcus multilocularis*. Gottstein *et al* (23) pointed out that cytokine TGF- β 1 is involved in the parasite-host interaction in AE. AE and CE are two types of echinococcosis, i.e., echinococcosis caused by inoculation of the eggs of *Echinococcus multilocularis* or Eg, respectively. The above studies have elucidated the immune effect of cytokine TGF- β 1 in AE, and the present study aimed to elucidate whether cytokine TGF- β 1 has a similar role in CE. Of note, liver fibrosis is part of the two pathologies; therefore, liver fibrosis in hepatic AE is the next research goal of our group. In the present study, cytokine TGF- β 1 levels were markedly increased in diseased tissues and organs, particularly in areas of fibrosis. Exogenous TGF- β 1 may cause fibrosis of tissues and organs and excessive deposition of ECM of cells if used in experimental animals and the treatment of experimental anti-TGF- β 1 may inhibit the formation of fibrosis. In a previous study by our group, the degree of fibrosis in the livers of mice infected with Eg gradually increased with the prolongation of parasite infection; in line with this, the TGF- β 1 levels in the mice were gradually increased and were positively correlated with the degree of liver fibrosis (25). This may indicate that the cytokine TGF- β 1 is the core substance regulating the development of liver fibrosis (26). Therefore, understanding the dynamic changes and effects of the most important cytokine, TGF- β 1, in the development of liver fibrosis diseases is of great significance for the interpretation of the mechanism and treatment of hepatic fibrosis.

The clinical data of the present cohort indicated that patients with hepatic CE may have different degrees of liver fibrosis; however, the degree of fibrosis is not significant, which may be associated with the current development of imaging diagnosis (27). An association with infection is frequently present at the early stage, at the beginning of the disease caused by infection by the parasite (28). In the present study, patients with hepatic CE exhibited no ethnic differences and the disease was frequently accompanied by hepatic damage. In addition, hepatic tissue specimens from patients with hepatic CE were observed to include vesicle tissue. On H&E staining, pathological features including inflammatory cell infiltration, steatosis and necrosis were observed in the hepatic tissue, while Masson staining indicated different degrees of fibrosis in the hepatic tissue. It was suggested that hepatic CE causes pathological damage to the liver, as well as different degrees of hepatic fibrosis. In the present study, the WHO classification was positively correlated with the severity of liver fibrosis. It is possible that cytokine TGF- β 1 activates hepatic stellate cells when the parasite infects the liver of the patient, which promotes hepatic fibrosis and is accompanied by infiltration of inflammatory neutrophils and fibroblasts. A future study by our group will investigate whether hepatic stellate cell activation is associated with the cytokine TGF- β 1. With the growth of the hydatid sac, severe inflammatory reaction leads to the formation of a fibrous layer around the hydatid cyst to separate it from the host tissue, effectively avoiding the host's immune response, which is conducive to the growth and erosion of the parasite. In the present study, immunohistochemistry and serum ELISA were used to detect the expression of cytokine TGF- β 1 in patients with hepatic CE, indicating that cytokine TGF- β 1 has an important role in liver fibrosis in hepatic CE. Determination of serum cytokine TGF- β 1 levels may contribute to the

diagnosis of liver fibrosis, particularly in early liver fibrosis, suggesting that anti-TGF- β 1 treatment may help to treat Eg infection. For analysis of serum levels, the healthy control group of the present study was matched with the case group in terms of age and sex. Liver lesion tissue and normal tissue were paired from the same patient. There was no influence of age or sex on the data analysis. It is also required to evaluate liver fibrosis in hepatic CE based on protein expression levels and serological levels, such as liver fibrosis activation indicators including α -smooth muscle actin, collagen I and III. In addition, in future studies, the sample size requires to be expanded. It is crucial to identify novel methods to improve the treatment of echinococcosis in order to enhance the quality of life and survival rates of patients with hepatic CE.

Acknowledgements

Not applicable.

Funding

This work was supported by the National Natural Science Foundation (grant nos. 81760372 and 81260253) and the State Key Laboratory of Pathogenesis, Prevention and Treatment of High-Incidence Diseases in Central Asia (grant no. SKL-HIDCA-2018-27).

Availability of data and materials

The datasets used and/or analyzed during the current study are available from the corresponding author on reasonable request.

Authors' contributions

XM, JG and FT made substantial contributions to conception and design. YL, XS were responsible for designing the clinical and experimental studies, drafting the manuscript, and revising it critically for important intellectual content. NY, DB and JL made substantial contributions to collection of samples and patients' general information. XZ and CZ made substantial contributions to analysis and interpretation of data. All authors read and approved the final manuscript.

Ethics approval and consent to participate

The study protocols were approved by the ethics committee of the First Affiliated Hospital of Xinjiang Medical University (Urumqi, China; approval nos. ZACUS-201304255002 and 20160218-14) and received informed consent from all subjects. For the minors (<18 years of age) that participated in the study, written informed consent was provided by their parents/legal guardians.

Patient consent for publication

Not applicable.

Competing interests

The authors declare that they have no competing interests.

References

1. Zhang W, Zhang Z, Wu W, Shi B, Li J, Zhou X, Wen H and McManus D: Epidemiology and control of echinococcosis in central Asia, with particular reference to the People's Republic of China. *Acta Trop* 141: 235-243, 2015.
2. Rossi P, Tamarozzi F, Galati F, Pozio E, Akhan O, Cretu CM, Vutova K, Siles-Lucas M, brunetti E and Casuli A; HERACLES extended network: The first meeting of the European register of cystic echinococcosis (ERCE). *Parasit Vectors* 9: 243, 2016.
3. Devi AM, Venumadhav T, Sukanya B, Manmada TR, Gopal P and Rammurti S: Role of imaging in diagnosis, predicting biological activity and in treatment plan of hydatid disease. *Open J Intern Med* 8: 177-195, 2018.
4. Ramachandran P and Iredale JP: Liver fibrosis: A bidirectional model of fibrogenesis and resolution. *QJM* 105: 813-817, 2012.
5. Lee UE and Friedman SL: Mechanisms of hepatic fibrogenesis. *Best Pract Res Clin Gastroenterol* 25: 195-206, 2011.
6. Kong X, Horiguchi N, Mori M and Gao B: Cytokines and STATs in liver fibrosis. *Front Physiol* 3: 69, 2012.
7. Friedman SL: Evolving challenges in hepatic fibrosis. *Nat Rev Gastroenterol Hepatol* 7: 425-436, 2010.
8. Gorelik L and Flavell RA: Transforming growth factor-beta in T-cell biology. *Nat Rev Immunol* 2: 46-53, 2002.
9. Perumal N, Perumal M, Halagowder D and Sivasithamparan N: Morin attenuates diethylnitrosamine-induced rat liver fibrosis and hepatic stellate cell activation by co-ordinated regulation of Hippo/Yap and TGF- β 1/Smad signaling. *Biochimie* 140: 10-19, 2017.
10. Kocabayoglu P and Friedman SL: Cellular basis of hepatic fibrosis and its role in inflammation and cancer. *Front Biosci (Schol Ed)* 5: 217-230, 2013.
11. Tsolaki E, Athanasiou E, Gounari E, Zogas N, Siotou E, Yiangou M, Anagnostopoulos A and Yannaki E: Hematopoietic stem cells and liver regeneration: Differentially acting hematopoietic stem cell mobilization agents reverse induced chronic liver injury. *Blood Cells Mol Dis* 53: 124-132, 2014.
12. Hu X, Rui W, Wu C, He S, Jiang J, Zhang X and Yang Y: Compound astragalus and salvia multiorrhiza extracts suppress hepatocarcinogenesis by modulating transforming growth factor- β /Smad signaling. *J Gastroenterol Hepatol* 29: 1284-1291, 2014.
13. Verrecchia F and Mauviel A: Transforming growth factor-beta signaling through the Smad pathway: Role in extracellular matrix gene expression and regulation. *J Invest Dermatol* 118: 211-215, 2002.
14. Pang N, Zhang F, Ma X, Zhu Y, Zhao H, Xin Y, Wang S, Chen Z, Wen H and Ding J: TGF- β /Smad signaling pathway regulates Th17/Treg balance during *Echinococcus multilocularis* infection. *Int Immunopharmacol* 20: 248-257, 2014.
15. Ma X, Wang L, Zhao H, Pang N, Zhang F, Jiang T, Liu X, Mamuti W, Wen H and Ding J: Th17 cells are associated with the Th1/Th2-cell balance during *Echinococcus multilocularis* infection. *Mol Med Rep* 10: 236-240, 2014.
16. WHO Informal Working Group: International classification of ultrasound images in cystic echinococcosis for application in clinical and field epidemiological settings. *Acta Trop* 85: 253-261, 2003.
17. Zhang C, Wang L, Ali T, Li L, Bi X, Wang J, Lü G, Shao Y, Vuitton DA, Wen H and Lin R: Hydatid cyst fluid promotes peri-cystic fibrosis in cystic echinococcosis by suppressing miR-19 expression. *Parasit Vectors* 9: 278, 2016.
18. Zhang CY, Yuan WG, He P, Lei JH and Wang CX: Liver fibrosis and hepatic stellate cells: Etiology, pathological hallmarks and therapeutic targets. *World J Gastroenterol* 22: 10512-10522, 2016.
19. Ali M, Zhang T and Jing H: The clinical value and significance of B type ultrasound in liver cystic echinococcosis. *Prog Mod Biomed* 13: 5483-5485, 2013.
20. Dong C: TH17 cells in development: An updated view of their molecular identity and genetic programming. *Nat Rev Immunol* 8: 337-348, 2008.
21. Martin-Martin N, Slattery C, McMorrow T and Ryan MP: TGF- β 1 mediates sirolimus and cyclosporine A-induced alteration of barrier function in renal epithelial cells via a noncanonical ERK1/2 signaling pathway. *Am J Physiol Renal Physiol* 301: F1281-F1292, 2011.
22. Zhang S, Hùe S, Sène D, Penfornis A, Bresson-Hadni S, Kantelip B, Caillat-Zucman S and Vuitton DA: Expression of major histocompatibility complex class I chain-related molecule A, NKG2D, and transforming growth factor-beta in the liver of humans with alveolar echinococcosis: New actors in the tolerance to parasites? *J Infect Dis* 197: 1341-1349, 2008.
23. Gottstein B and Hemphill A: *Echinococcus multilocularis*: The parasite-host interplay. *Exp Parasitol* 119: 447-452, 2008.
24. Wang J, Zhang C, Wei X, Blagosklonov O, Lv G, Lu X, Mantion G, Vuitton DA, Wen H and Lin R: TGF- β and TGF- β /Smad signaling in the interactions between *Echinococcus multilocularis* and its hosts. *PLoS One* 8: e55379, 2013.
25. Liu Y, Abudounnasier G, Zhang T, Liu X, Wang Q, Yan Y, Ding J, Wen H, Yimiti D and Ma X: Increased expression of TGF- β 1 in correlation with liver fibrosis during *Echinococcus granulosus* infection in mice. *Korean J Parasitol* 54: 519-525, 2016.
26. Liu X, Hu H and Yin J: Therapeutic strategies against TGF-beta signaling pathway in hepatic fibrosis. *Liver Int* 26: 8-22, 2006.
27. Petitclerc L, Sebastiani G, Gilbert G, Cloutier G and Tang A: Liver fibrosis: Review of current imaging and MRI quantification techniques. *J Magn Reson Imaging* 45: 1276-1295, 2017.
28. Cruz A, Cooper P, Figueiredo C, Alcantara-Neves N, Rodrigues L and Barreto M: Global issues in allergy and immunology: Parasitic infections and allergy. *J Allergy Clin Immunol* 140: 1217-1228, 2017.



This work is licensed under a Creative Commons Attribution-NonCommercial-NoDerivatives 4.0 International (CC BY-NC-ND 4.0) License.