

## Case Report

# Diffuse Ectopic Deciduosis Imitating Peritoneal Carcinomatosis with Acute Abdomen Presentation: A Case Report and Literature Review

Pavel Sorokin <sup>1</sup>, Andrei Nikiforchin <sup>2</sup>, Aleksandr Panin,<sup>3</sup> Aleksandr Zhukov,<sup>4</sup>  
Vadim Gushchin <sup>2</sup>, and Mark Kurtser <sup>5</sup>

<sup>1</sup>Department of Surgical Oncology, Lapino Clinical Hospital, 111 1st Uspenskoe Shosse, Lapino, Moscow Region, 143081, Russia

<sup>2</sup>Department of Surgical Oncology, The Institute for Cancer Care, Mercy Medical Center, 227 Saint Paul Place, Weinberg Building, 4th Floor, Baltimore, Maryland, USA 21202

<sup>3</sup>Department of General Surgery, Lapino Clinical Hospital, 111 1st Uspenskoe Shosse, Lapino, Moscow Region, 143081, Russia

<sup>4</sup>Department of Pathology, Lapino Clinical Hospital, 111 1st Uspenskoe Shosse, Lapino, Moscow Region, 143081, Russia

<sup>5</sup>Department of Obstetrics and Gynecology, Lapino Clinical Hospital, 111 1st Uspenskoe Shosse, Lapino, Moscow Region, 143081, Russia

Correspondence should be addressed to Vadim Gushchin; [vgushchin@mdmercy.com](mailto:vgushchin@mdmercy.com)

Received 31 August 2020; Accepted 18 September 2020; Published 26 September 2020

Academic Editor: Mehmet Armagan Osmanagaoglu

Copyright © 2020 Pavel Sorokin et al. This is an open access article distributed under the Creative Commons Attribution License, which permits unrestricted use, distribution, and reproduction in any medium, provided the original work is properly cited.

During pregnancy, decidual tissue can occur beyond the endometrium, predominantly on the surface of the uterus, fallopian tubes, and ovaries. This condition, called ectopic deciduosis, generally is not accompanied by any symptoms and complications, does not require treatment, and resolves completely soon after labor. However, rarely it can present with acute abdomen syndrome or imitate peritoneal malignancy and, thus, cause diagnostic difficulties and unnecessary interventions. Here, we report a challenging case of a pregnant woman admitted with acute peritonitis caused by ectopic deciduosis that mimicked peritoneal carcinomatosis. This uncommon manifestation of deciduosis hindered correct diagnosis and led to excessive surgery. While the management of the patient presented is regrettable, the case highlights the natural history of deciduosis, and therefore, important lessons could be learned from it.

## 1. Introduction

Ectopic deciduosis refers to an abnormal occurrence of decidual tissue (decidua) outside the uterus [1, 2]. While its pathogenesis is not fully elucidated, it is thought to originate from subserous stromal cells as a result of progesterone stimulation [1–3]. The ectopic decidua appears on the surface of the female reproductive organs and peritoneum; however, on rare occasions, it can be found in the lymph nodes, lungs, kidneys, and skin [4–8].

Deciduosis is a benign condition that typically does not cause any symptoms and resolves spontaneously 4–6 weeks after labor [9, 10]. However, the ectopic decidua involving the appendiceal wall often leads to appendicitis and presents with signs of acute abdomen [11–13]. Diffuse omental and

peritoneal involvement is another confusing manifestation that may mimic peritoneal carcinomatosis and mislead physicians [3, 10, 14]. A combination of both urgent surgical and oncology-like presentations of ectopic deciduosis may be even more diagnostically challenging making physicians prone to hasty clinical decisions. We report a rare case of a pregnant woman with this uncommon and complex manifestation of diffuse ectopic deciduosis that led to excessive surgery and undesirable outcome.

## 2. Case Presentation

A 36-year-old Caucasian woman (gravida 2, para 1) presented to the emergency room at 32-week gestation with acute lower abdominal pain, mild fever, and nausea. Before

this admission, her pregnancy was uneventful and carefully screened. The patient had a history of myopia and laparoscopic removal of endometrioid ovarian cysts 3 years before. She never smoked and denied any cancer history. At presentation, she had a temperature of 37.8°C (100.1°F), her pulse rate was 105/min, and her blood pressure was 104/66 mmHg. Her respiratory rate was 21/min, and her oxygen saturation was 96% on room air. Physical examination revealed a 32-week gravid uterus and guarding with rebound tenderness in the right lower quadrant (RLQ) of the abdomen; bowel sounds were decreased. Laboratory tests showed a leukocyte count of 17,000/mm<sup>3</sup> with 80% neutrophils. The levels of C-reactive protein (CRP) and interleukin 6 (IL-6) were elevated to 47 mg/L and 113 pg/mL, respectively. The performed abdominal and pelvic ultrasound (US) did not reveal an enlarged appendix or adnexa but showed slightly dilated bowel loops and a moderate amount of fluid in the RLQ and rectouterine pouch. The fetal heart rate was 160 beats/min. Due to suspected acute appendicitis, the patient underwent surgery.

The performed diagnostic laparoscopy revealed numerous 3-5 mm yellow peritoneal nodules on the small bowel and cecum serosa (Figure 1(a)). Similar lesions covered the surface of the uterus, enlarged ovaries and fallopian tubes, and partially the peritoneum of the abdominal wall and pelvis (Figure 1(b)). The subdiaphragmatic peritoneum, as well as the liver capsule, gallbladder, stomach, spleen, and appendix, was spared. Macroscopically, the lesions resembled peritoneal carcinomatosis, and the peritoneal cancer index (PCI) was 21 [15]. Purulent-appearing fluid was seen in the RLQ and pelvis and between inflamed and dilated bowel loops (Figure 1(a)). Peritoneal nodule biopsy was performed; however, the frozen sections were inconclusive, suggesting a neoplasm composed of spindle cells with unknown malignant potential. During the revision, the patient blood pressure decreased to 88/57 mmHg and she was started on fluid resuscitation with intravenous boluses. The patient was discussed intraoperatively with the obstetrician and surgical oncologist. Considering the severity of the patient condition (peritonitis, hypotension), the absence of a visible source of peritonitis (intact appendix, uninflamed adnexa), and the lack of sufficient visibility due to the gravid uterus, we decided to proceed with laparotomy and cesarean section. This decision was dictated by the risk of compromising the fetus and the necessity of a thorough revision of the abdomen to identify the origins of peritonitis and revealed lesions. After cesarean delivery, no gastrointestinal or pelvic source of peritonitis was found; therefore, the necrosis of peritoneal lesions was concluded to be its cause. Interpreting the peritoneal nodules as carcinomatosis and considering ovarian, tubal, and peritoneal cancer its most common origin in women, we performed bilateral salpingoophorectomy with omental and multiple peritoneal biopsies for further histopathology confirmation.

The postoperative evaluation of suppurative fluid did not show bacterial growth. The final pathology of sampled tissues did not reveal any signs of malignancy and reported mesothelial fields of spindle and oval cells, forming bundles and swirls suspicious of decidual transformation (Figures 2(a) and 2(b)). The immunohistochemical (IHC) assay demon-

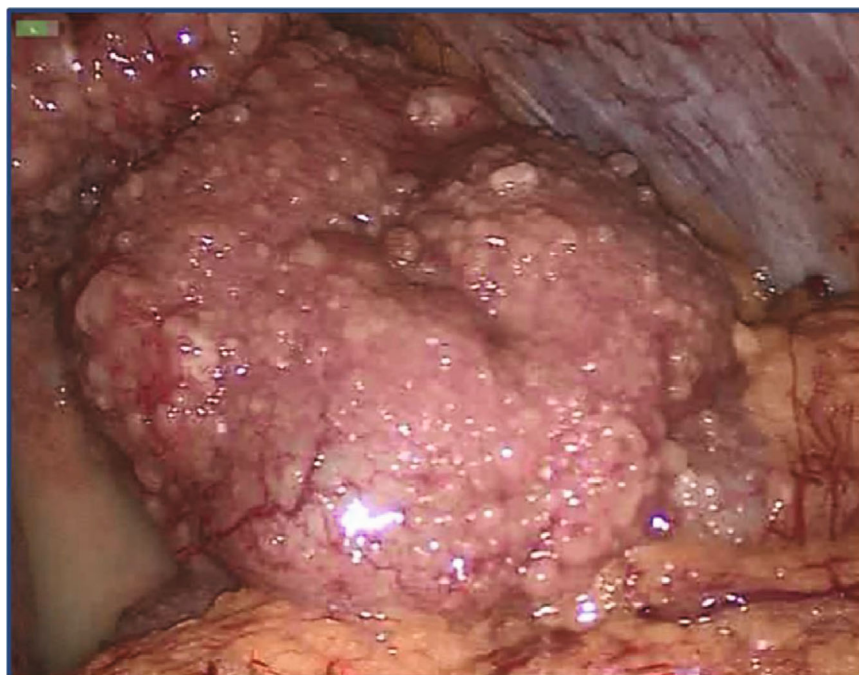
strated coexpression of progesterone (PR) and estrogen receptors (ER) (Figures 3(a) and 3(b)), vimentin, desmin, and the cluster of differentiation 10 (CD10) (Figures 4(a)–4(c)), but there was no staining for calretinin, cytokeratin 5, smooth muscle actin (SMA), c-kit (CD117), human melanoma black 45 (HMB-45), and S-100 protein, which is consistent with decidual criteria.

The patient recovered uneventfully and was discharged on the 6<sup>th</sup> postoperative day. After delivery, the 2100 g (4 lb 10 oz) male newborn was transferred to the neonatal intensive care unit and discharged one week after. The patient underwent a control diagnostic laparoscopy six weeks after surgery that showed the complete regression of peritoneal nodules (Figures 5(a) and 5(b)). Given the premature surgical menopause, the patient was offered hormone therapy with estrogen which she refused. At six months of follow-up, the patient and her child do not have any symptoms or concerns.

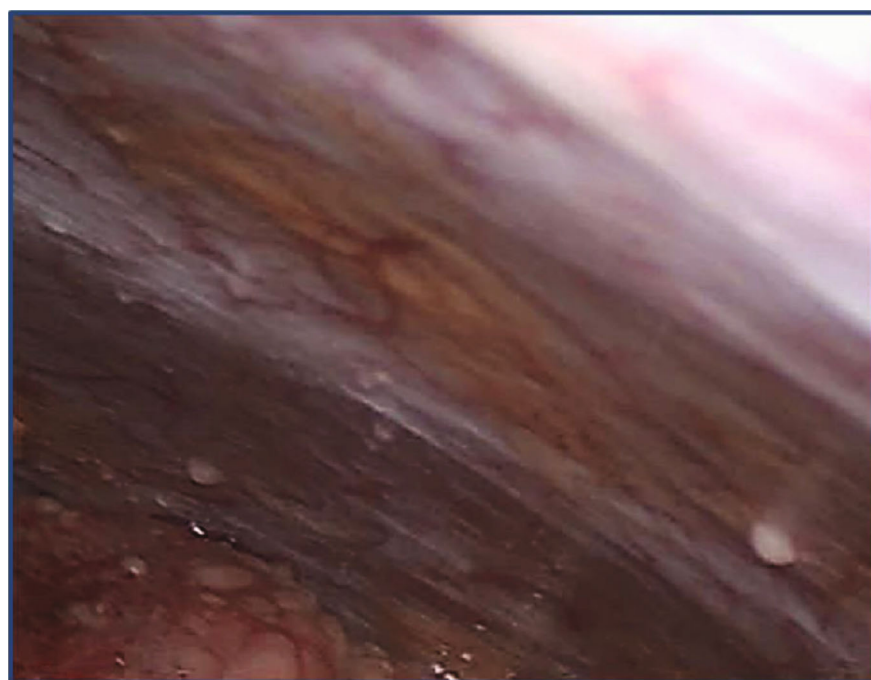
### 3. Discussion

This case demonstrates management challenges that physicians may face due to an uncommon presentation of ectopic decidual. As a rule, this obstetric condition does not cause any symptoms or laboratory abnormalities and resolves spontaneously 4-6 weeks after delivery [1, 9, 14]. However, if the appendix wall undergoes a decidual transformation, it can lead to appendicitis with typical clinical and laboratory characteristics [11–13]. Also, there are a number of reports describing other urgent manifestations caused by diffuse ectopic decidual including intraperitoneal hemorrhage, tuboovarian abscess, bowel obstruction, and dystocia [11, 16–20]. In our case, the symptoms and physical examination indicated acute abdomen syndrome, and elevated inflammatory markers (neutrophilic leukocytosis, CRP, and IL-6) corroborated the clinical impression. When presented as acute abdomen syndrome, ectopic decidual requires further thorough investigation to rule out other common causes of this surgical emergency [21].

Imaging can significantly contribute to the differential diagnosis of acute lower abdominal pain during pregnancy and identify its causes, more common than ectopic decidual. The abdominal and pelvic US should be an initial test since it is noninvasive, not associated with ionizing radiation exposure, and informative in acute appendicitis or gynecological emergencies [22, 23]. Magnetic resonance imaging (MRI) is also preferable as it avoids ionizing radiation and not inferior to computed tomography in the evaluation of acute nontraumatic abdominal pain during pregnancy [21, 24]. Unfortunately, ectopic decidual itself is usually unseen on imaging due to the insufficient size of nodules and indifferent tissue density. In the present case, ultrasonography did not reveal an enlarged appendix or adnexa but it visualized a moderate amount of fluid in the RLQ and rectouterine pouch. Based on physical examination and laboratory test results, we suspected acute appendicitis, the most common surgical emergency in pregnancy [25]. A diagnostic laparoscopy was chosen as the next minimally invasive and safe



(a)



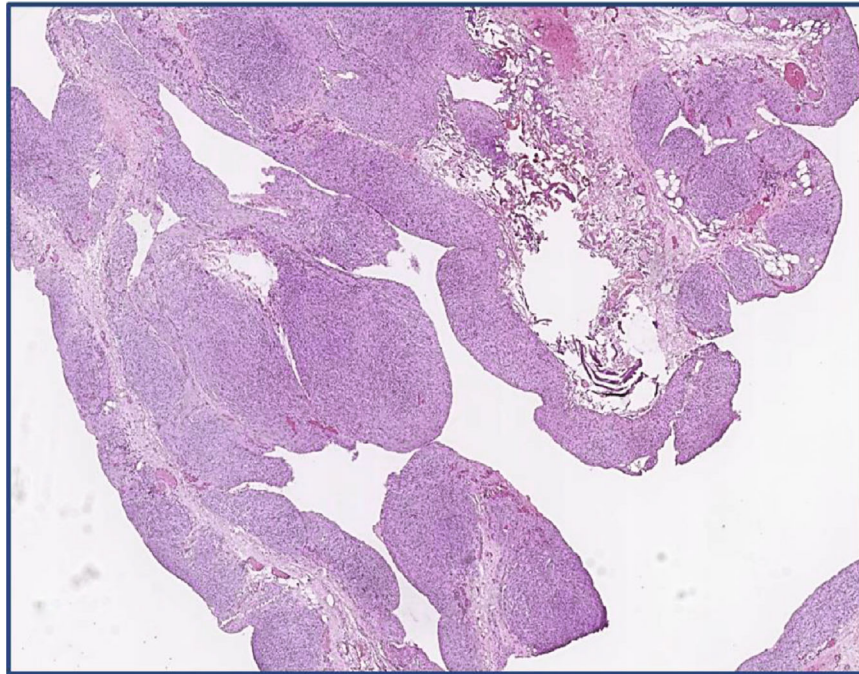
(b)

FIGURE 1: (a) A diagnostic laparoscopy demonstrates numerous ectopic decidual nodules covering the small bowel and imitating peritoneal carcinomatosis. There is a moderate amount of purulent-appearing fluid in the pelvis. (b) A diagnostic laparoscopy shows 3-5 mm nodules of ectopic deciduosis on the abdomen wall peritoneum.

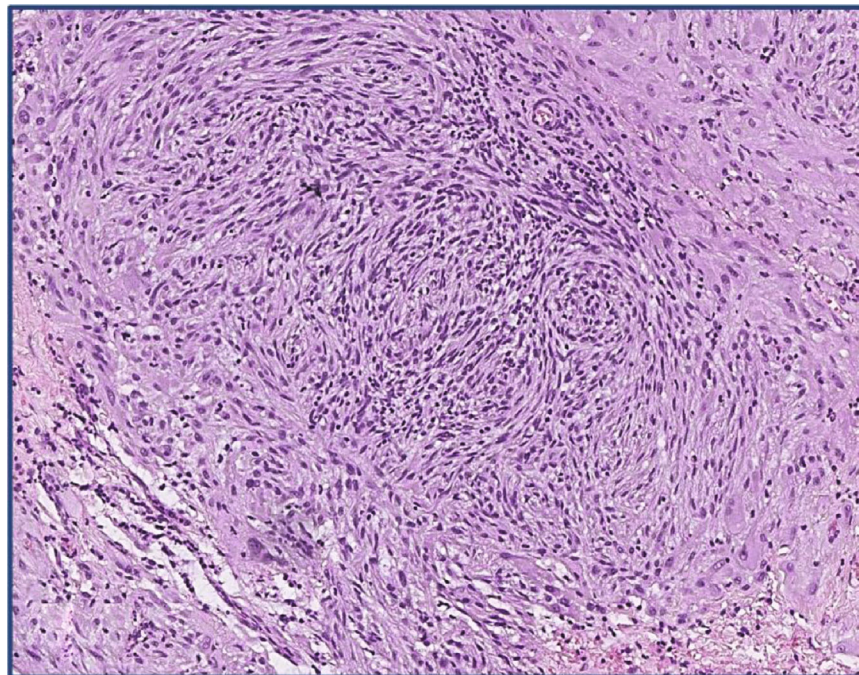
management step allowing both abdominal revision and curative surgery [21, 26].

The macroscopic appearance of the ectopic decidua is insidious as it lacks specific features and can be easily mistaken for a tumor. In general, it presents as small yellow to tan elastic, sometimes focally hemorrhagic, nodules or plaques localized on the surface of the uterus, fallopian tubes,

ovaries, and pelvic peritoneum without any exudate [1, 2, 4, 9]. Diffuse involvement of the peritoneum and abdominal organs is rare and thus can be especially challenging for diagnosis because it imitates peritoneal carcinomatosis [3, 9, 10, 14]. In the present case, the laparoscopy suggested peritonitis along with numerous small yellow nodules covering the uterus, fallopian tubes, enlarged ovaries, peritoneum, loops



(a)

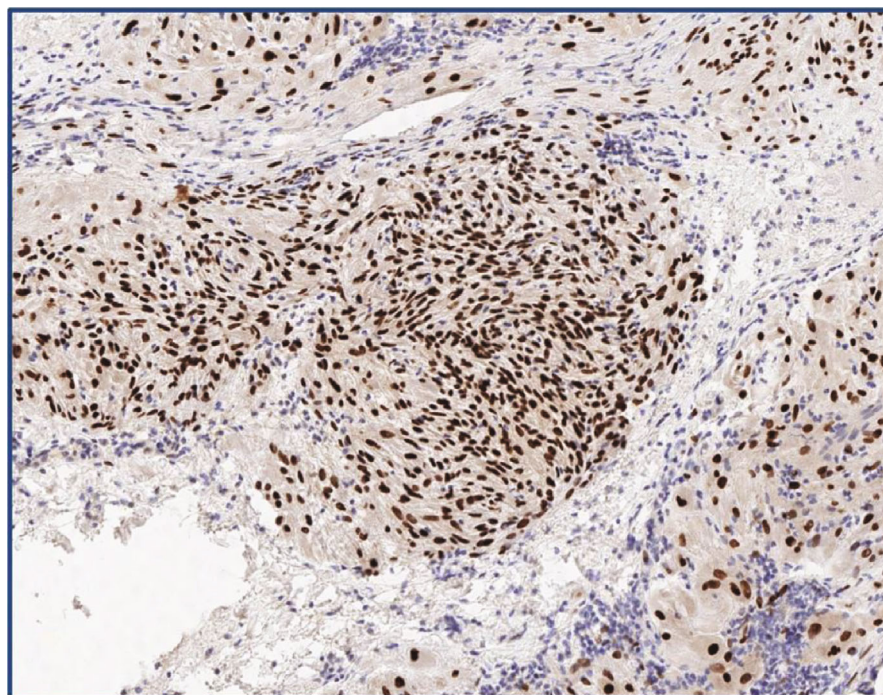


(b)

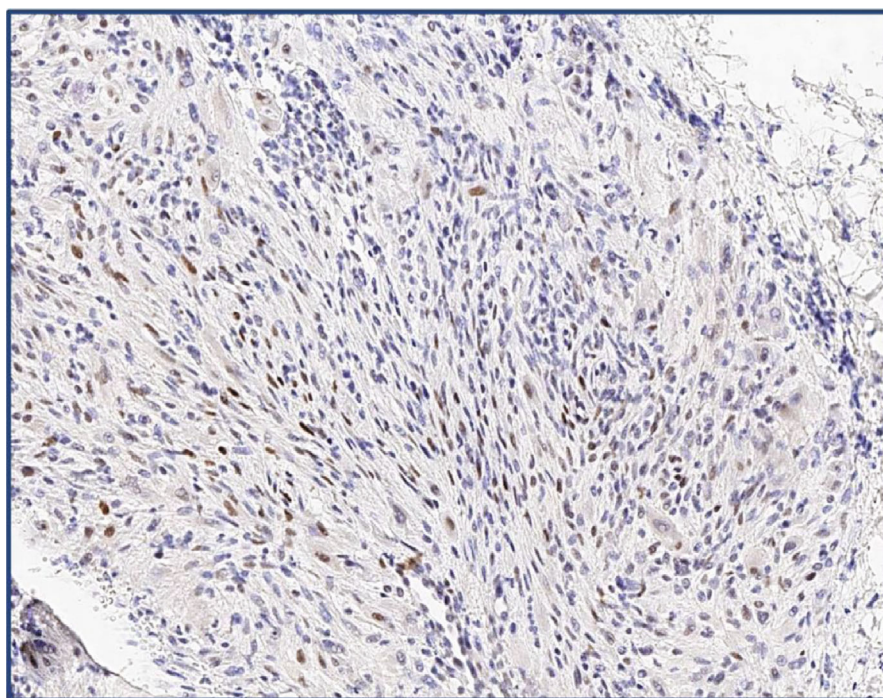
FIGURE 2: (a) Microscopic examination of the peritoneum sample shows several foci of atypical tissue growth (H&E, magnification  $\times 50$ ). (b) Microscopic examination of the peritoneal lesion demonstrates nodes and fields of large spindle and oval cells with uniform nuclei and a moderately developed cytoplasm, forming bundles and swirls (H&E, magnification  $\times 400$ ). H&E: hematoxylin and eosin.

of the small bowel, and cecum (Figures 1(a) and 1(b)). The severity of the patient condition (peritonitis, hypotension) required rapid decision-making, and right after intraoperative discussion with the obstetrician, cesarean section was performed to reduce the fetal risks. However, after delivery, no distinct source of peritonitis was identified, and the frozen section of the lesions suggested a spindle cell neoplasm with

unknown malignant potential. The surgical oncologist interpreted the intraoperative findings as carcinomatosis from the ovarian primary tumor with decay that led to peritonitis (the postoperative assessment of suppurative fluid did not show bacterial growth). Although the incidence of ovarian, tubal, and peritoneal cancer during pregnancy is low, it remains the most common origin of peritoneal carcinomatosis in



(a)



(b)

FIGURE 3: (a) The diffuse nuclear PR expression in decidualy transformed cells (magnification  $\times 400$ ). (b) The mild nuclear ER expression in decidualy transformed cells (magnification  $\times 400$ ). PR: progesterone receptors; ER: estrogen receptors.

women, and since the appendix, stomach, colon, liver, and gallbladder were intact, all specialists agreed on this diagnosis [27, 28]. An extensive spread of lesions was interpreted as an advanced stage of the disease with PCI 21. The striking macroscopic resemblance of deciduous with peritoneal carcinomatosis contributed to major departure from common

sense and unnecessary further surgery. Analyzing the case retrospectively, the initial intervention should have been limited to appropriate drainage and peritoneal and omental biopsies which are sufficient for establishing a diagnosis when ovarian cancer is suspected [29]. Thus, in pregnant women with peritoneal lesions, ectopic deciduous should

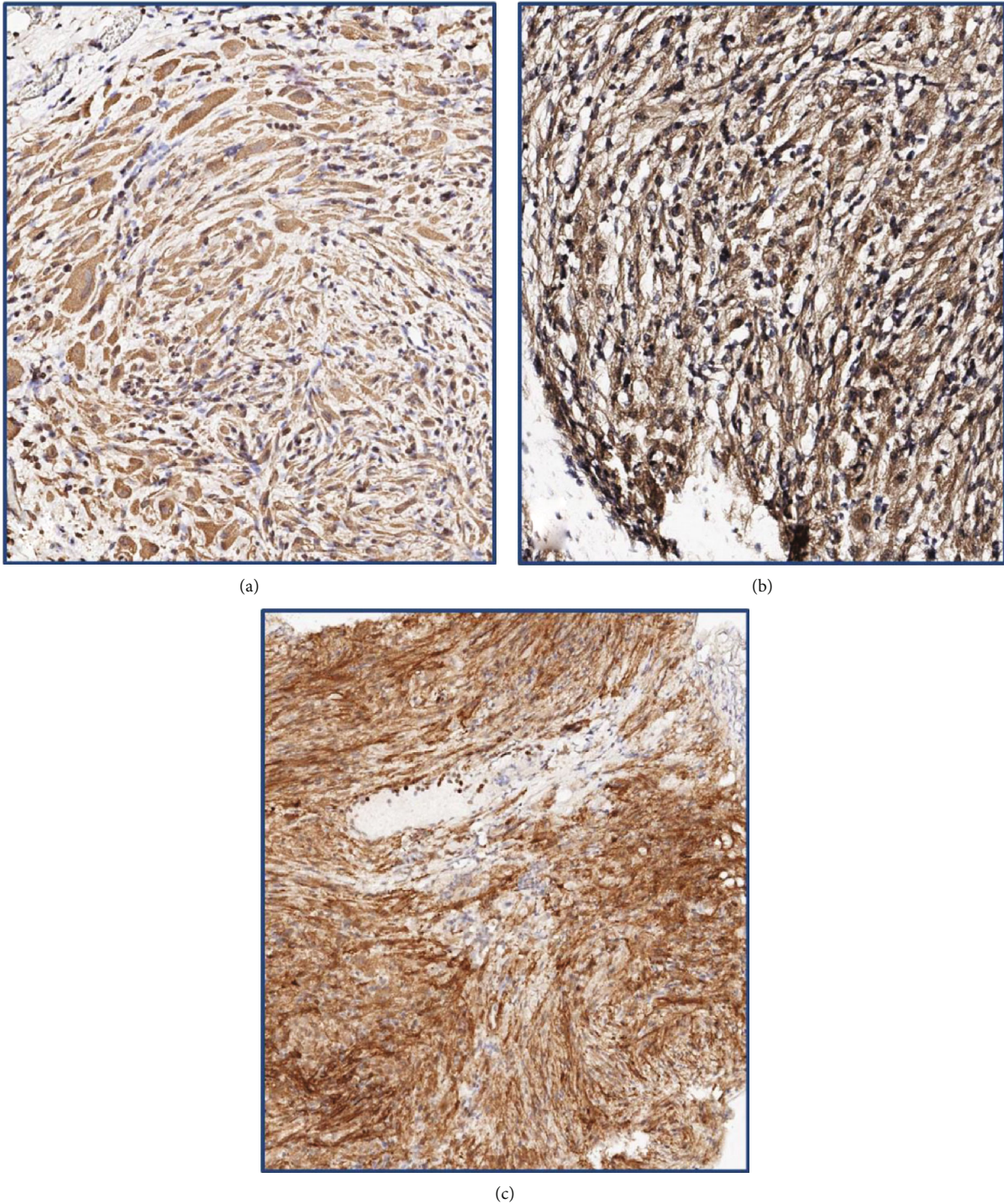
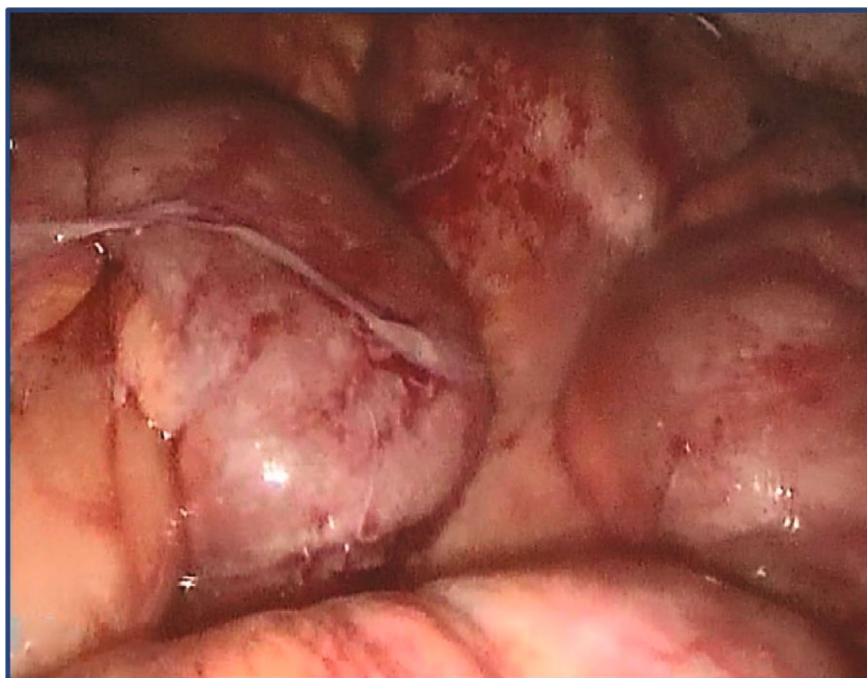

FIGURE 4: (a) The intensive diffuse cytoplasmic expression of vimentin in decidualy transformed cells (magnification  $\times 400$ ). (b) The diffuse cytoplasmic desmin expression in decidualy transformed cells (magnification  $\times 400$ ). (c) The intensive membrane and cytoplasm expression of CD10 in decidualy transformed cells (magnification  $\times 400$ ). CD10: cluster of differentiation 10.

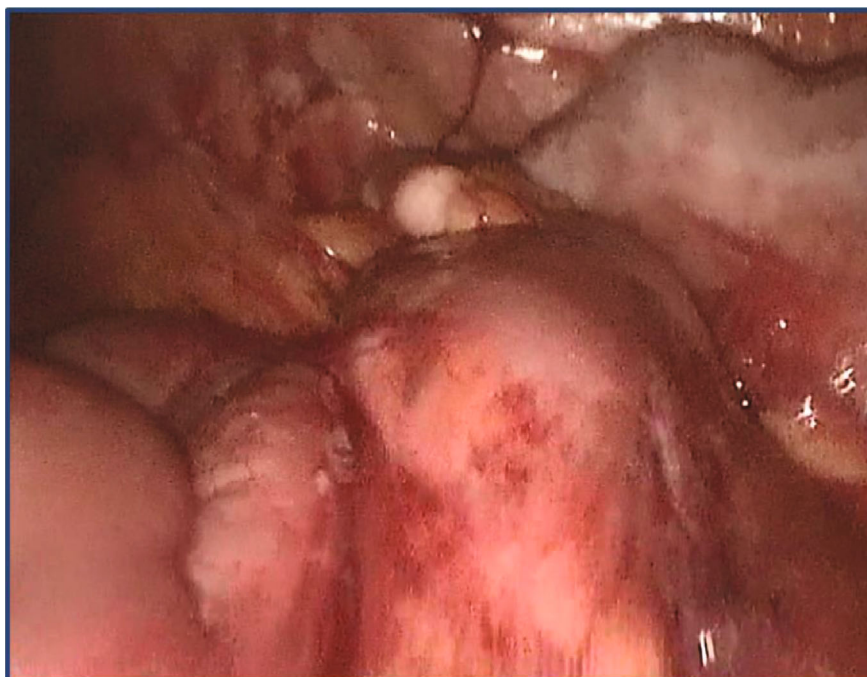
be always taken into account since its gross anatomy can be mistaken for carcinomatosis and no intraoperative decisions should be made based on sole macroscopic appearance.

Generally, ectopic decidualosis is a self-limited condition that resolves completely in the early postpartum period and on its own not requiring any treatment [9]. However, surgical intervention may be needed in case of acute appendicitis or a

tuboovarian abscess caused by the decidual transformation of corresponding tissues [11, 12]. Other rare complications including intraperitoneal hemorrhage and bowel obstruction may also require surgery when they do not respond to conservative measures [16, 18, 19]. Pregnancy management is another important component of care of these patients, and the obstetrician should be involved even though the vast



(a)



(b)

FIGURE 5: (a) A control diagnostic laparoscopy 6 weeks after cesarean delivery shows a full regression of ectopic deciduosis that covered small bowel loops. (b) A control diagnostic laparoscopy 6 weeks after cesarean delivery shows an entire regression of ectopic deciduosis that used to cover the terminal ileum and cecum completely.

majority of cases will end with at-term delivery [9, 10]. In the case of such a challenging manifestation of ectopic deciduosis such as peritonitis and peritoneal lesions, we also recommend a surgical oncologist consultation for comprehensive differential diagnosis and deliberate decision-making. Importantly, regardless of clinical presentation, if the surgery

is performed, it should always include sufficient biopsy of the decidua for further histopathology evaluation.

A thorough pathological assessment of surgical specimens, which is the key in making a diagnosis of ectopic deciduosis, requires time and resources and cannot be performed intraoperatively with frozen sections. In general,

microscopic evaluation of the decidua shows large cells with spindle, oval, or polygonal shape that form bundles or clusters in the submesothelial layer [1, 2, 10]. Decidual tissue is benign so it typically does not demonstrate increased mitotic activity, nuclear pleomorphism, necrosis, and vascular invasion [1, 2]. A broad IHC assay should be also performed to distinguish the ectopic decidua from some neoplasms that have similar macro- and microscopic appearance [2]. The expression of PR, ER, vimentin, desmin, and CD-10 showed to be specific for decidual tissue, while calretinin and cytokeratin 5/6 positivity supports decidual malignant mesothelioma [2, 9, 14]. To rule out metastatic melanoma, IHC should demonstrate negativity for HMB-45 and S-100 protein stains, while the negativity for c-kit (CD117) excludes gastrointestinal stromal tumors [2, 14]. In the reported case, the final pathology revealed the fields of spindle and oval cells forming bundles and swirls (Figures 2(a) and 2(b)) that along with an expression of PR, ER (Figures 3(a) and 3(b)), vimentin, desmin, and CD10 (Figures 4(a)–4(c)) confirmed ectopic decidual tissue. Sufficient biopsy and meticulous pathology evaluation with the IHC analysis are crucial for accurate diagnosis of ectopic decidual tissue.

#### 4. Conclusion

The presented case demonstrates diagnostic challenges caused by an uncommon manifestation of ectopic decidual tissue that led to excessive surgery. This benign obstetric condition should be always kept in mind for differential diagnosis when the peritoneal spread of tumor-like lesions is found during pregnancy and the early postpartum period, and sufficient but not excessive biopsy of suspicious nodules is required for an accurate diagnosis. We believe that our clinical experience and its analysis will aid physicians in the appropriate management and reduce the risk of undesirable outcomes.

#### Data Availability

The data used to support the findings of this study is restricted by the Ethical Committee of Lapino Clinical Hospital in order to protect patient privacy. Data is available upon request from the corresponding author for researchers who meet the criteria for access to confidential data.

#### Consent

The signed informed consent was obtained from the patient before conducting the study.

#### Conflicts of Interest

The authors declare that they have no conflict of interest regarding this publication.

#### Authors' Contributions

Pavel Sorokin developed the study conception and design, collected and interpreted the data, performed the literature review, and drafted the manuscript. Andrei Nikiforichin contributed to the literature review, manuscript drafting, and its

critical revision for content and English stylistics and grammar. Aleksandr Panin contributed to the data acquisition and revision of the manuscript. Aleksandr Zhukov revised the pathology slides and contributed to the data acquisition and revision of the manuscript. Vadim Gushchin contributed to the revision of the manuscript for content and English grammar. Mark Kurtser contributed to the revision of the manuscript. All authors contributed to the review and amendments of the manuscript for important intellectual content and approved the final version for submission.

#### References

- [1] P. Zaytsev and J. B. Taxy, "Pregnancy-associated ectopic decidua," *The American Journal of Surgical Pathology*, vol. 11, no. 7, pp. 526–530, 1987.
- [2] F. Bolat, T. Canpolat, and E. Tarim, "Pregnancy-related peritoneal ectopic decidua (deciduosis): morphological and clinical evaluation," *Turkish Journal of Pathology*, vol. 28, no. 1, pp. 56–60, 2012.
- [3] A. Kondi-Pafiti, D. Grapsa, K. Kontogianni-Katsarou, K. Papadias, and E. Kairi-Vassilatou, "Ectopic decidua mimicking metastatic lesions—report of three cases and review of the literature," *European Journal of Gynaecological Oncology*, vol. 26, no. 4, pp. 459–461, 2005.
- [4] G. A. Markou, I. Goubin-Versini, O. M. Carbanaru, C. Karatzios, J. M. Muray, and M. Fysekidis, "Macroscopic decidual tissue in pregnancy is finally a common entity," *European Journal of Obstetrics & Gynecology and Reproductive Biology*, vol. 197, pp. 54–58, 2016.
- [5] R. A. Burnett and D. Millan, "Decidual change in pelvic lymph nodes: a source of possible diagnostic error," *Histopathology*, vol. 10, no. 10, pp. 1089–1092, 1986.
- [6] D. B. Flieder, C. A. Moran, W. D. Travis, M. N. Koss, and E. J. Mark, "Pleuro-pulmonary endometriosis and pulmonary ectopic decidual tissue: a clinicopathologic and immunohistochemical study of 10 cases with emphasis on diagnostic pitfalls," *Human Pathology*, vol. 29, no. 12, pp. 1495–1503, 1998.
- [7] K. P. Fair, J. W. Patterson, R. J. Murphy, and R. J. Rudd, "Cutaneous decidual tissue," *Journal of the American Academy of Dermatology*, vol. 43, no. 1, pp. 102–107, 2000.
- [8] H. F. Bettinger, "Ectopic decidua in the renal pelvis," *The Journal of Pathology and Bacteriology*, vol. 59, no. 4, pp. 686–687, 1947.
- [9] A. Büttner, R. Bässler, and C. Theele, "Pregnancy-associated ectopic decidua (deciduosis) of the greater omentum," *Pathology, Research and Practice*, vol. 189, no. 3, pp. 352–359, 1993.
- [10] D. B. Cruz, T. Dhameer, V. W. da Rocha, and R. F. Dupont, "Diffuse peritoneal decidual tissue mimicking metastatic lesions," *Case Reports*, vol. 2014, 2014.
- [11] E. Dogan, E. Okyay, B. Saatli, S. Olgan, S. Sarioglu, and M. Koyuncuoglu, "Tuba ovarian abscesses formation from decidualized ovarian endometrioma after appendiceal endometriosis presenting as acute appendicitis in pregnancy," *Iranian Journal of Reproductive Medicine*, vol. 10, no. 3, pp. 275–278, 2012.
- [12] A. Balta, M. Lubgane, I. Orube et al., "Deciduosis of the appendix manifesting as acute abdomen in pregnancy," *Acta Chirurgica Latviensis*, vol. 14, no. 1, pp. 43–45, 2014.
- [13] M. Löfwander, G. Haugen, C. Hammarström, O. Røkke, and Ø. Mathisen, "A pregnant woman with abdominal pain and fever," *Tidsskrift for den Norske lægeforening*, vol. 127, no. 19, pp. 2528–2529, 2007.



- [14] L. J. Adhikari and R. Shen, "Florid diffuse peritoneal deciduosis mimicking carcinomatosis in a primigravida patient: a case report and review of the literature," *International Journal of Clinical and Experimental Pathology*, vol. 6, no. 11, pp. 2615–2619, 2013.
- [15] P. Jacquet, A. D. Stephens, A. M. Averbach et al., "Analysis of morbidity and mortality in 60 patients with peritoneal carcinomatosis treated by cytoreductive surgery and heated intraoperative intraperitoneal chemotherapy," *Cancer*, vol. 77, no. 12, pp. 2622–2629, 1996.
- [16] S. M. O'Leary, "Ectopic decidualization causing massive postpartum intraperitoneal hemorrhage," *Obstetrics & Gynecology*, vol. 108, Supplement, pp. 776–779, 2006.
- [17] L. C. H. Tang, M. Y. W. Cheung, and H. K. Ma, "Intraperitoneal bleeding from ectopic decidua following hormonal contraception. Case report," *BJOG: An International Journal of Obstetrics and Gynaecology*, vol. 92, no. 1, pp. 102–103, 1985.
- [18] H. Heidegger, A. Hümpfner, R. Hugo, and W. Schulz, "Peritoneale Deziduose: Ursache für einen mechanischen ileus in der Schwangerschaft," *Geburtshilfe und Frauenheilkunde*, vol. 51, no. 04, pp. 307–309, 1991.
- [19] M. A. Richter, A. Choudhry, J. J. Barton, and R. E. Merrick, "Bleeding ectopic decidua as a cause of intraabdominal hemorrhage. A case report," *The Journal of Reproductive Medicine*, vol. 28, no. 6, pp. 430–432, 1983.
- [20] A. Malpica, M. T. Deavers, and I. Shahab, "Gross deciduosis peritonei obstructing labor: a case report and review of the literature," *International Journal of Gynecological Pathology*, vol. 21, no. 3, pp. 273–275, 2002.
- [21] S. K. Zachariah, M. Fenn, K. Jacob, S. A. Arthungal, and S. A. Zachariah, "Management of acute abdomen in pregnancy: current perspectives," *International Journal of Women's Health*, vol. 11, pp. 119–134, 2019.
- [22] M. P. Smith, D. S. Katz, T. Lalani et al., "ACR Appropriateness Criteria® right lower quadrant pain—suspected appendicitis," *Ultrasound Quarterly*, vol. 31, no. 2, pp. 85–91, 2015.
- [23] R. Williams and J. Shaw, "Ultrasound scanning in the diagnosis of acute appendicitis in pregnancy," *Emergency Medicine Journal*, vol. 24, no. 5, pp. 359–360, 2007.
- [24] K. T. Baron, E. K. Arleo, C. Robinson, and P. C. Sanelli, "Comparing the diagnostic performance of MRI versus CT in the evaluation of acute nontraumatic abdominal pain during pregnancy," *Emergency Radiology*, vol. 19, no. 6, pp. 519–525, 2012.
- [25] I. L. Tamir, F. S. Bongard, and S. R. Klein, "Acute appendicitis in the pregnant patient," *American Journal of Surgery*, vol. 160, no. 6, pp. 571–576, 1990.
- [26] T. C. Cox, C. R. Huntington, L. J. Blair et al., "Laparoscopic appendectomy and cholecystectomy versus open: a study in 1999 pregnant patients," *Surgical Endoscopy*, vol. 30, no. 2, pp. 593–602, 2016.
- [27] J. Palmer, M. Vatish, and J. Tidy, "Epithelial ovarian cancer in pregnancy: a review of the literature," *BJOG: An International Journal of Obstetrics and Gynaecology*, vol. 116, no. 4, pp. 480–491, 2009.
- [28] L. A. Torre, B. Trabert, C. E. DeSantis et al., "Ovarian cancer statistics, 2018," *CA: A Cancer Journal for Clinicians*, vol. 68, no. 4, pp. 284–296, 2018.
- [29] H. Marret, C. Lhommé, F. Lecuru et al., "Guidelines for the management of ovarian cancer during pregnancy," *European Journal of Obstetrics, Gynecology, and Reproductive Biology*, vol. 149, no. 1, pp. 18–21, 2010.