

Research article

**THE EXPRESSION OF INDUCIBLE NITRIC OXIDE SYNTHASE
 (iNOS) IN THE TESTIS AND EPIDIDYMIS OF RATS WITH
 A DIHYDROTESTOSTERONE (DHT) DEFICIENCY**

AGNIESZKA KOLASA^{1*}, MARIOLA MARCHLEWICZ¹, RAFAŁ
 KURZAWA², WOJCIECH GŁĄBOWSKI¹, GRZEGORZ TRYBEK¹,
 LIDIA WENDA-RÓŻEWICKA¹ and BARBARA WISZNIEWSKA^{1*}

¹Department of Histology and Embryology, ²Department of Reproductive
 Medicine and Gynecology, Pomeranian Medical University, Powstanców Wlkp. 72,
 70-111 Szczecin, Poland

Abstract: In our previous studies, we showed that a finasteride-induced DHT deficiency may cause changes in the morphology of the seminiferous epithelium without any morphological alteration of the epididymis. In this study, we demonstrated the constitutive immunoexpression of inducible nitric oxide synthase (iNOS) in the testis and epididymis of Wistar rats treated with finasteride for 28 days (the duration of two cycles of the seminiferous epithelium) and 56 days (the duration of one spermatogenesis). We noted that a 56-day finasteride treatment mainly caused a decrease in the level of circulating DHT, as well as a statistically insignificant decrease in the level of T. The hormone deficiency also led to a change in the iNOS immunoexpression in the testis and epididymis of the finasteride-treated rats. *In vitro*, DHT did not modify NO production by the epithelial cells of the caput epididymis even when stimulated with LPS and IFN γ , but it did give rise to an increase in NO

* Authors for correspondence. Tel./fax: + 48 91 466 1677, e-mails: ak1712@sci.pam.szczecin.pl, barbwisz@sci.pam.szczecin.pl

Abbreviations used: 5 α -red – 5 α -reductase; 5 α -red1 – 5 α -reductase type 1; 5 α -red2 – 5 α -reductase type 2; AR – androgen receptor; DHT – dihydrotestosterone; E₂ – estradiol; ELFA – enzyme linked fluorescent assay; ER α – estrogen receptor α ; ER β – estrogen receptor β ; IFN γ – interferon gamma; LC – Leydig cell; LPS – lipopolysaccharide; NO – nitric oxide; NO²⁻ – nitrite; NOS – nitric oxide synthase; eNOS – endothelial nitric oxide synthase; iNOS – inducible nitric oxide synthase; nNOS – neuronal nitric oxide synthase; PS – pachytene spermatocyte; preLS – preleptotene spermatocyte; RIA – radioimmunoassay; RT-PCR – reverse transcriptase-polymerase chain reaction; SC – Sertoli cell; SD – spermatid; SG – spermatogonium; T – testosterone

production by the epithelial cells of the cauda epididymis without the stimulation. DHT did not have a statistically significant influence on estradiol production by cultured, LPS- and IFN γ -stimulated epithelial cells from the caput and cauda epididymis. In conclusion, our data clearly indicates that a finasteride-induced DHT deficiency intensifies the constitutive expression of iNOS in most rat testicular and epididymal cells, so it can be expected that the expression of inducible nitric oxide synthase (iNOS) could be regulated by DHT. On the other hand, the profile of the circulating DHT and T levels strongly suggests that the regulation of constitutive iNOS expression is complex and needs more detailed study.

Key words: iNOS immunoexpression, DHT-deficiency, Testis, Epididymis, Rat

INTRODUCTION

Nitric oxide (NO) is a short-lived free radical with a biological function. It is synthesized from L-arginine by the activation of nitric oxide synthase (NOS), which exists in three isoforms. Two of them, endothelial nitric oxide synthase (eNOS, NOS I) and neuronal nitric oxide synthase (nNOS, NOS III), are constitutive calcium-dependent enzymes. The third isoform, inducible nitric oxide synthase (iNOS, NOS II), is Ca²⁺ independent [1, 2].

Both nNOS and eNOS are normally expressed in many types of cells, but were first discovered in the neuronal and vascular endothelial cells. The expression of inducible NOS has been described from a variety of cell types, including macrophages, hepatocytes, smooth muscle cells, keratinocytes, pancreatic islet β -cells and mesangial cells [3, 4]. Unlike the constitutive forms of NOS (eNOS, nNOS), inducible nitric oxide synthase (iNOS) produces a large amount (nanomolar quantities) of NO over a prolonged period of time (from hours to several days) after its activation by cytokines or bacterial endotoxins (lipopolysaccharide; LPS) [5].

NOS protein and the enzyme's activity have been detected in both the human and rat male reproductive systems, including in the testis and epididymis [6, 7]. When stimulated, iNOS is expressed in rat Sertoli cells [8], Leydig cells [9] and macrophages of the interstitial compartment of the testis [10]. The NO produced by iNOS is regarded as an autocrine/paracrine messenger in local testicular steroidogenesis in normal rats. Using RT-PCR and immunohistochemistry, we detected for the first time the mRNA and protein for iNOS in cultured rat epididymal epithelial cells stimulated with LPS and IFN γ [11]. Upon stimulation, the epididymal epithelial cells released NO into the medium [11, 12]. However, cells that had been freshly isolated from the epididymis of control rats also contained an iNOS transcript, suggesting that the enzyme is constitutively expressed [11]. Moreover, non-stimulated cells in culture also released NO into the medium [12]. Our findings have been confirmed by other authors. The constitutive expression of iNOS was also observed in normal

tissues of the male reproductive system. Recent findings indicate that iNOS is constitutively expressed in somatic and normal testicular spermatogenic cells in rats [13], horses [14], pigs [15] and monkeys [16]. iNOS expression was also observed by Ha *et al.* [14] in horses and by Sun *et al.* [16] in the *macaca fascicularis* epididymis. However, the regulation of the constitutive expression of iNOS is not fully understood.

The organs of the male reproductive system are mainly T- and DHT-dependent. DHT is formed in the androgen target tissue via an irreversible reduction of testosterone catalyzed by 5 α -reductase (5 α -red). The enzyme exists in two isoforms, 5 α -reductase type 1 (5 α -red1) and 5 α -reductase type 2 (5 α -red2), which are encoded by different genes [17, 18]. Northern blot analysis of the 5 α -reductase expression in rats suggested that the immature testes had a higher level of 5 α -red1 than those of the adult, and that 5 α -red2 expression was detectable at any age [19]. Viger and Robaire [19] concluded that 5 α -red1 is the major isoenzyme expressed in the testis at all stages, albeit in a different manner. Other studies have strongly suggested that 5 α -red2 is the major isoenzyme present in the testicular [20] and epididymal tissues [21, 22].

Finasteride, which mainly inhibits 5 α -red2, is used to inhibit 5 α -reductase activity in both basic and clinical studies [23-26]. In our earlier studies in which rats were treated with finasteride for the duration of two cycles of the seminiferous epithelium (28 days) and the total duration of spermatogenesis (56 days), we finally found that a 56-day DHT deficiency causes changes in the morphology of the testes [27]. The aim of this study was to explain the influence of a DHT deficiency on the inducible NOS expression in the rat testes and epididymis.

MATERIAL AND METHODS

The study was performed on 3-month old sexually mature male Wistar rats. The rats were maintained under standard conditions of lighting (12L:12D) and nutrition. The study was approved by the local Ethics and Animal Research Committee. The animals were randomly divided into a control group of 10 animals, and two experimental groups of finasteride-treated rats, with 5 animals in each group. Finasteride (Proscar[®], MSD Sweden) was administered *per os* at 5 mg/kg b.w./day to each animal in one experimental group for 28 days (the duration of two cycles of the seminiferous epithelium), and to each animal in the other experimental group for 56 days (the total duration of spermatogenesis). Half the rats of the control group and all those from the experimental groups were anesthetized with 90 mg/kg b.w. thiopental (Biochemie, GmbH, Austria). Blood was obtained via cardiac puncture for the estimation of the hormone concentration. The testes and caput and cauda epididymides were fixed in Bouin's fluid, and embedded in paraffin for the immunohistochemical analysis. The epididymides from the other five rats of the control group were reserved for the isolation of epididymal epithelial cells.

Isolation of epididymal cells and cell culture

The procedure of epididymal epithelial cell isolation and culture was described previously [28]. The procedure yielded small segments of the epididymal duct without its outer sheath of connective tissue, smooth muscle cells and spermatozoa. The isolated epididymal epithelial cells were transferred to Dulbecco's modified Eagle's medium without phenol red (Gibco, USA), supplemented with inactivated 3% fetal calf serum (Gibco, USA), antibiotics (penicillin, streptavidine, Sigma), 1 nM testosterone (T; Sigma) or 5 α -dihydrotestosterone (DHT; Sigma), and placed into 24-well cell culture dishes (Corning, USA). The cells were incubated at 34°C, in 5% CO₂ for 72 h until they formed a monolayer. The medium was changed and the cells were cultured with or without 10 μ g/ml lipopolisaccharide (LPS; Sigma) and 500 U/ml rat recombinant interferon- γ (IFN- γ ; Sigma), and with or without 300 mM N-methyl-L-arginine (L-NMA; Sigma). After 48 h of culture, the media were collected and centrifuged, and the supernatants were used to measure the concentrations of estradiol (E₂) and nitrite (NO²⁻).

Determination of the nitrite concentration

An indirect spectrophotometric method for nitric oxide determination was used. The Ding method [29] was applied to detect NO²⁻ accumulation in the culture media. The absorbance was measured at 540 nm. The reaction was linear in the range of 0.5-100 μ M, with a detection limit at 0.5 μ M.

Hormone analysis

The levels of testosterone (T) and dihydrotestosterone (DHT) were estimated in the sera of the control and finasteride-treated rats. The concentration of T was measured using the immunofluorescence method (ELFA – enzyme linked fluorescent assay; with a range of test sensitivity from 0.069 to 52.0 ng/ml and a measuring accuracy of \pm 0.1 ng/ml); and the DHT level via radioimmunoassay (DHT-RIA, BioSource Europe S.A., Nivelles, Belgium), at the minimum detectable concentration \pm 20 pg/ml. The estradiol concentrations in the culture media were measured using the enzyme linked fluorescent assay VIDAS Estradiol II (E2II; BioMerieux, France), the sensitivity of which is in the range from 5 to 4300 pg/ml.

Inducible NOS immunohistochemistry

Paraffin-embedded sections (5 μ m) of the rat testes and epididymides were immunostained to visualize the inducible nitric oxide synthase (iNOS). The immunohistochemistry (IHC) was performed using a specific primary antibody: rabbit polyclonal anti-mouse inducible nitric oxide synthase (diluted 1:400; from SEROTEK Ltd, Kidlington, Oxford, UK; NOS-II; iNOS, AHP303, mouse macrophage NOS C-terminal peptide (1131-1144) + additional N-terminal Cys conjugated to KLM; recognizes iNOS, and does not cross react with eNOS or nNOS; species cross-reactivity: human & rat). The deparaffinized sections were

microwave irradiated in citrate buffer (pH 6.0) for heat-induced epitope retrieval. After slow cooling to room temperature, the slides were washed in PBS twice for 5 min and then incubated for 60 min with primary anti-iNOS antibody. Next, the sections were stained with an avidin-biotin-peroxidase system with diaminobenzidine as the chromogen (EnVision⁺System-HRP (DAB); Code K4010 DakoCytomation, Glostrup, Denmark) as per the manufacturer's staining protocol. The sections were washed in distilled H₂O and counterstained with hematoxylin. As a negative control, the specimens were processed in the absence of the primary antibody. Positive staining was defined microscopically by visual identification of brown pigmentation.

Statistical analysis

The data is expressed as the number of tests (n), the median (M), the arithmetic mean (X), the standard deviation (SD) and the upper/lower quartile (Q₁-Q₃). The differences between the groups were tested using the non-parametric Mann-Whitney U-test (for data close to the normal range) or Student's t-test. Probability values < 0.05 were considered to be statistically significant. Statistical comparisons were performed with the Statistica 5.0 Program PL for Windows (StatSoft, Poland).

RESULTS

DHT and T levels in the sera of the control and finasteride-treated rats

Treating the rats with finasteride significantly decreased the level of circulating DHT relative to the level for the control group of animals (Tab. 1). The level of circulating T was also lower in the finasteride-treated rats relative to the control group, but the reduction was statistically insignificant (Tab. 1).

Tab. 1. The level of DHT and T in the blood serum of the control rats and the rats that underwent finasteride treatment for 56 days.

		Control (C)	Finasteride-treated (Fin56)
Dihydrotestosterone (DHT) (pg/ml) (n = 9)	M	606.63	515.12
	Q ₁ -Q ₃	599.25-612.57	504.15-570.94
	X ± SD	607.27 ± 9.85	528.34 ± 37.01
			vs C***
Testosterone (T) (ng/ml) (n = 5)	M	1.15	0.95
	Q ₁ -Q ₃	0.82-1.27	0.65-1.26
	X ± SD	1.07 ± 0.21	0.92 ± 0.66

M – median, Q₁-Q₃ – upper quartile and lower quartile, X ± SD – arithmetic mean ± standard deviation. Asterisks show the statistically significant differences in the Mann-Whitney U-test. ***p < 0.001.

iNOS-immunolocalization

Testis

The results of the immunoreactivity assay for iNOS in the testes are presented in Fig. 1A-I and Fig. 2. There is no immunostaining in the testis sections incubated without the primary antibody (Fig. 1A; insert), indicating the specificity of the immunohistochemical (IHC) procedure. In all of the studied groups (control, Fin28, Fin56), the iNOS-expression was detected with different intensity, in cells of both the seminiferous epithelium (Fig. 1A-I; Fig. 2) and the interstitial tissue (Fig. 1A-I). We compared stages II (Fig. 1A, B, C), VIII (Fig. 1D, E, F) and XII (Fig. 1G, H, I) of the seminiferous epithelium cycle in the control (Fig. 1A, D, G) and experimental groups of rats (Fin28 – Fig. 1B, E, H; Fin56 – Fig. 1C, F, I).

In stage II of the seminiferous epithelium cycle in the control rats (Fig. 1A), the most intensive iNOS-expression was in the cytoplasm of the Sertoli cells (SC) and the spermatids (SD) of the 16th step of spermiogenesis (Fig. 1A). In general, a weak immunodetection of iNOS was also observed in the cytoplasm surrounding the nuclei of the spermatids of the 2nd step of spermiogenesis (Fig. 1A), the pachytene spermatocytes (PS; Fig. 1A) and the spermatogonia (SG; Fig. 1A). In stage II of the seminiferous epithelium cycle of the rats treated with finasteride for 28 days (Fig. 1B), the pattern of immunorepression was the same as in the control testes, but the intensity was slightly higher, especially in the pachytene spermatocytes. In the cells of the seminiferous epithelium of the Fin56 rat testes, the level of immunostaining (Fig. 1C) was similar to that observed in the Fin28 rats.

In stage VIII of the seminiferous epithelium cycle of the control rats (Fig. 1D), the spermatids of the 8th and 19th steps of spermiogenesis were immunopositive, as were the pachytene and preleptotene spermatocytes, and the spermatogonia (Fig. 1D). In the testes of the Fin28 rats (Fig. 1E), the expression of iNOS was slightly increased, mainly in the spermatids of the 8th step of spermiogenesis (Fig. 1E). In the pachytene spermatocytes, preleptotene spermatocytes and spermatogonia (Fig. 1E), the intensity of iNOS-expression was also higher than in the control testes (Fig. 1D). Stronger immunostaining was noticed in the pachytene spermatocytes and elongated spermatids of the Fin56 rat testes (Fig. 1F).

In stage XII of the seminiferous epithelium cycle of the control rats (Fig. 1G), intensive iNOS-expression was visible mainly in the Sertoli cells and the elongated spermatids of the 12th step, and also in the spermatogonia (Fig. 1G). The Fin28 and Fin56 rat testes had stronger iNOS immunostaining mainly in the basal part of the epithelium, principally in the elongated spermatids (Fig. 1H, I). In both finasteride-treated groups, the marked product of the IHC-reaction was also observed in the spermatogonia and pachytene spermatocytes (Fig. 1H, I). Moreover, a brown pigmentation indicating the positive statement of immunoreaction was visible in sloughed immature germ cells in the lumen of the seminiferous tubules of the Fin56 rats (Fig. 1I).

Inducible NO synthase immunostaining was also seen in the interstitial tissue (Leydig cells, endothelial and smooth muscle cells of the vessels) in all three groups of rats (Fig. 1A-I). The Leydig cells displayed the highest immunostaining in the control rats (Fig. 1A), while the immunoexpression in these cells decreased in both Fin28 (Fig. 1B, E) and Fin56 rats (Fig. 1C).

In addition, in the testes of rats treated with finasteride for 56 days, seminiferous tubules with a degenerated appearance were occasionally observed (Fig. 2). In these seminiferous tubules, the multinucleated giant cells, probably derived from round spermatids, have a strong immunoreactivity for iNOS (Fig. 2).

Epididymis

In the epididymis of the control (Fig. 3A, B, C) and finasteride-treated (Fig. 3E-H) rats, the differences in the intensity of the IHC reaction product were noted in the cytoplasm. Fig. 3D shows the negative control for immunostaining.

In the caput epididymis of the control rats (Fig. 3A, B), iNOS reactivity was observed in the apical region of the cytoplasm (Fig. 3A) and stereocilia (Fig. 3B) of the principal cells and in the cytoplasm of the basal cells of the epithelium (Fig. 3A). The immunoexpression of iNOS was shown in both myoid cells of the epididymal wall and cells of the interstitial tissue (Fig. 3A). In the cauda epididymis of the control rats (Fig. 3C), weak expression of inducible NO synthase appeared in the apical part or whole cytoplasm (Fig. 3C) of some epithelial cells.

In rats treated with finasteride for 28 days (Fig. 3E, F), the positive immunoreaction was more intense than in the control group, and was noted in the cytoplasm and stereocilia of the principal cells, and in the cytoplasm of the basal (Fig. 3E, F) epithelial cells of the caput (Fig. 3E) and cauda (Fig. 3F) epididymis. iNOS immunoreaction was found in the myoid cells (Fig. 3E, F), and in vascular smooth muscle cells (Fig. 3E) and cells of the interstitial tissue (Fig. 3E, F).

In the epididymal epithelium of rats treated with finasteride for 56 days (Fig. 3G, H), iNOS expression was visible in the cytoplasm, especially in the perinuclear region of some of the principal epithelial cells in the caput (Fig. 3G) and the majority of the principal cells in the cauda epididymis (Fig. 3H). Immunoexpression of iNOS was also seen in the basal cells of the caput (Fig. 3G) and caudal (Fig. 3H) part of the epididymal duct. The cells of the interstitial tissue and the peritubular smooth muscle cells appeared less immunopositive for iNOS (Fig. 3G, H) than in the control rats and those treated for 28 days. Only one place with intense brown pigmentation was seen in the vascular smooth muscle cells (Fig. 3G). Moreover, many lymphocyte-like cells were found in the epithelium of the epididymis of rats that experienced 56 days of DHT deficiency (Fig. 3G, H). Spermatozoa within the lumen of the caudal part of the epididymal duct of the experimental groups of rats showed immunoexpression of iNOS (Fig. 3C, F, H).

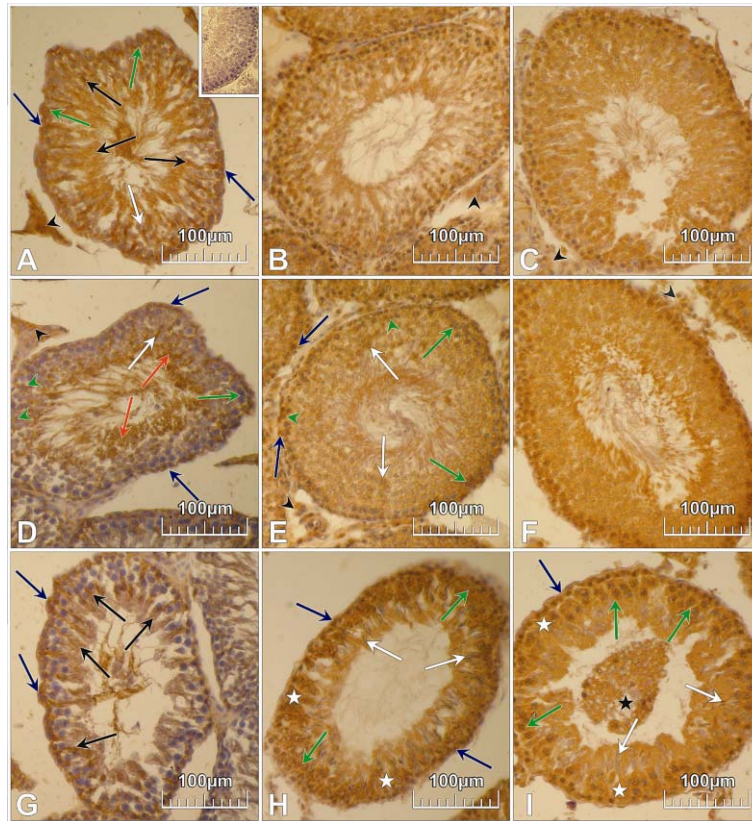


Fig. 1. The immunoexpression of iNOS in the testes of control rats (A, D, G) and rats treated with finasteride for 28 days (B, E, H) or 56 days (C, F, I), showing the seminiferous tubulules in stages II (A, B, C), VIII (D, E, F) and X (G, H, I) of the seminiferous epithelium cycle, and the interstitial tissues. The insert in A is the negative control. Legend for the arrows and asterisks: blue arrows – SG; green arrow heads – preLS; green arrows – PS; black arrows – SC and 16th step SD (A) and SC and elongated 12th step SD (G); white arrow – 2nd step SD (A), 8th step SD (D, E) and elongated SD (H, I); red arrows – 19th step SD; white asterisks – the basal part of the seminiferous epithelium (H, I); black asterisk – sloughed immature germ cells (I); black arrow heads – LC (A, B, C).

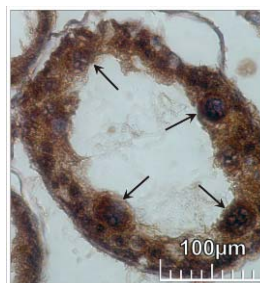


Fig. 2. The strong immunoreactivity for iNOS (arrows) in the multinucleated giant cells of a degenerating seminiferous tubule from a rat treated with finasteride for 56 days.

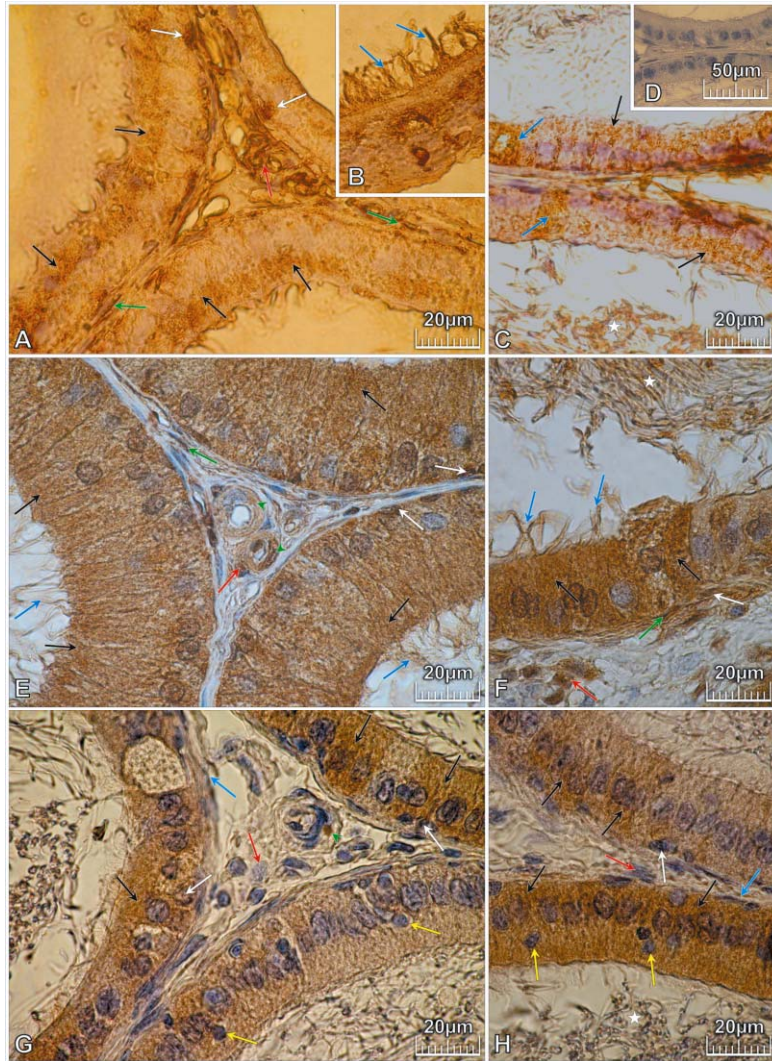


Fig. 3. The immunostaining for iNOS in the caput (A, B, D, F) and cauda (C, F, H) epididymis of control rats (A, B, C), and rats treated for 28 (E, F) or 56 days (G, H) with finasteride. Negative control for immunostaining (D). Legend for the arrows and asterisks: black arrows – principal cells; white arrows – basal cells; green arrows – myoid cells; green arrow heads – vascular smooth muscle cells; red arrows – cells of the interstitial tissue; yellow arrows – lymphocyte-like cells; blue arrows – stereocilia of the principal cells (B, E, F) or cells of the interstitial tissue and peritubular smooth muscle cells (G, H) or the whole cytoplasm of some epithelial cells (C).

Nitrite determination

The level of NO^2^- was measured in the media of the epididymal epithelial cells cultured with or without DHT, and with or without LPS and $\text{IFN-}\gamma$ stimulation. The results for the levels of nitrites released by the cells are summarized in Tab. 2.

Nitrite synthesis by the epithelial cells of the caput epididymis cultured without DHT was generally higher (with the highest concentration being 3.8 μM); however, the increase was not statistically significant. In the media of the cultured caudal epididymal epithelial cells after LPS and $\text{IFN}\gamma$ stimulation, with or without DHT, the concentration of nitrite was significantly lower compared to that in the media of the cells that had not been LPS/ $\text{IFN}\gamma$ stimulated (Tab. 2).

Tab. 2. The concentration of nitrite (μM) in the culture medium of the epididymal cells of the caput and cauda epididymis.

Caput epididymis				
n		DHT	DHT + LPS + $\text{IFN}\gamma$	LPS + $\text{IFN}\gamma$
	M	2.12	2.5	2.5
5	Q ₁ -Q ₃	1.9-2.3	2.4-2.7	1.2-3.8
	X \pm SD	2.1 \pm 0.32	2.7 \pm 0.65	2.56 \pm 1.43
Cauda epididymis				
n		DHT	DHT + LPS + $\text{IFN}\gamma$	LPS + $\text{IFN}\gamma$
	M	2.12	2.1	0.8
5	Q ₁ -Q ₃	0.9-2.6	1.9-2.25	0.5-0.9
	X \pm SD	1.88 \pm 0.83	1.95 \pm 0.57 vs LPS + $\text{IFN}\gamma$ **	0.72 \pm 0.2 vs DHT*

M – median, Q₁-Q₃ – upper quartile and lower quartile, X \pm SD – arithmetic means \pm standard deviation. Asterisks show the statistically significant differences in the Mann-Whitney U-test. **p < 0.01, *p < 0.05.

Tab. 3. The concentration of 17 β -estradiol (pg/ml) in the culture medium of epithelial cells of the caput and cauda epididymis.

Caput epididymis				
n		DHT	DHT + LPS + $\text{IFN}\gamma$	LPS + $\text{IFN}\gamma$
	M	124.5	111.7	109.2
5	Q ₁ -Q ₃	120.1-135.3	103.8-111.8	98.0-136.6
	X \pm SD	135.28 \pm 27.58	111.68 \pm 16.79	136.6 \pm 63.1
Cauda epididymis				
n		DHT	DHT + LPS + $\text{IFN}\gamma$	LPS + $\text{IFN}\gamma$
	M	92.6	82.3	66.5
5	Q ₁ -Q ₃	88.9-93.8	71.5-108.2	55.2-73.7
	X \pm SD	98.44 \pm 30.1	82.28 \pm 28.35	73.72 \pm 26.76

M – median, Q₁-Q₃ – upper quartile and lower quartile, X \pm SD – arithmetic means \pm standard deviation.

The 17 β -estradiol concentration in the culture media of the epithelial cells of the caput and cauda epididymis

The level of estradiol was measured in the media of the epididymal epithelial cells cultured with or without DHT, and with or without LPS and $\text{IFN}\gamma$.

stimulation. In the media of the epithelial cells of the caput and cauda epididymis cultured with DHT, the level of E2 was higher than in the media of the LPS- and IFN- γ -stimulated cells cultured with or without DHT. However, the differences were statistically insignificant (Tab. 3).

DISCUSSION

In recent studies, transcripts for iNOS and immunoexpression of this enzyme were observed in the testes and epididymis of rats [6, 13], horses [14], pigs [15] and monkeys [16] without earlier stimulation with cytokines or lipopolisaccharide. Our results showed the constitutive expression of iNOS in the testes and epididymis of Wistar rats. The regulation of iNOS expression in the testis and epididymis *in vivo* is still poorly understood. The testes and epididymis are androgen-dependent tissues controlled by testosterone and the most physiologically potent androgen, dihydrotestosterone. Therefore, in this study, we assessed the iNOS expression in two organs in rats with a DHT deficiency. To assess the influence of DHT on iNOS expression, we produced an animal model with a decreased level of DHT by using finasteride, one of the most effective steroid-like inhibitors of 5 α -reductase type 2 [24, 25, 26] and an isoform of the enzyme preferentially acting in male reproductive tissues [20, 21, 22]. We found that a 5 mg/kg b.w./day dose of finasteride over 56 days of treatment caused a reduction in the level of circulating DHT. The decrease in the DHT level in finasteride-treated rats was statistically significant relative to the levels for the control animals. However, other researchers showed that finasteride treatment resulted in a stronger decrease in the DHT concentration [25, 26]. The difference might have resulted from the dose of finasteride, the means of application, and the duration of the treatment. Moreover, the level of the circulating hormone can differ from that within the testis and epididymis.

In previous studies, we observed that a 28-day DHT deficiency did not affect the morphology of the seminiferous epithelium, whereas a 56-day-long DHT deficiency resulted in the sloughing of premature germinal cells into the lumen of the seminiferous tubules [27]. The results of this study indicate that 5 α -red2 inhibition by finasteride also caused changes in iNOS expression. There was an increase in the intensity of iNOS-immunoexpression in both the somatic and germ cells of the seminiferous epithelium in the two experimental groups of animals. However, the diversity of iNOS-expression depended on both the stage of the seminiferous epithelium cycle and the duration of DHT deficiency. Strong immunostaining was also observed in cells sloughed into the lumen of the seminiferous tubules and in the multinucleated giant cells in degenerating tubules after 56 days of finasteride treatment. This observation may indicate that a change in the DHT level could induce an increase in NO formation in the testes according to the stage of the seminiferous epithelium cycle and the duration of the DHT deficiency. Therefore, it could be hypothesized that the release of germ cells into the lumen of the seminiferous tubules could be

a manifestation of NO-induced apoptosis. As postulated, the generation of a huge amount of NO mediates cell death and plays a role in cell selection during spermatogenesis [15, 30]. Many reports indicate that mainly eNOS is associated with the cell death [30], but the results of our study suggest that iNOS can also be involved. Moreover, we found an increase in iNOS immun-expression in Sertoli cells. Nitric oxide is regarded as one of the regulators of spermatogenesis, as it interferes with the morphology of the tight junction between Sertoli cells [31] and germ cell apoptosis [32, 33]. Therefore, the sloughing of germ cells into the lumen of the seminiferous tubules may result from both the destruction of the tight junction of the Sertoli cells and the NO-induced apoptosis of the germ cells.

Despite the iNOS overexpression in the seminiferous epithelium of experimental rats, the Leydig cells displayed a diminished level of iNOS expression relative to the control rats. In many species [13-15], the interstitial cells of the testes, including the Leydig cells, under LPS-stimulated and non-stimulated conditions, are an important source of NO produced by iNOS [34, 35]. Much data indicates that NO may participate in Leydig cell steroidogenesis [10]. The effect of the decrease in iNOS expression observed here in experimental rats could have been caused by self-modulation of Leydig cells in term of androgen production under finasteride-induced DHT deficiency. Generally, it was shown by Welsh *et al.* [35] that the inhibition of NOS activity results in an increase in testosterone production. However, in our study, the levels of circulating testosterone after 56 days of finasteride treatment had not changed significantly, and were not elevated, as could be expected. Consequently, the role of T in the regulation of iNOS expression cannot be completely excluded. Additionally, the epididymis may be concerned as an organ where the synthesis of T and the formation of DHT and E2 take place [28, 36]. Chamness *et al.* [37] showed that castration caused an increase in NOS activity by about 88% in the caput, 73% in the corpus, and 54% in the cauda epididymis of the rat, and the enzyme activity was restored after testosterone supplementation. The findings of many other investigators showed the epididymal immunoeexpression of iNOS in the stereocilia of the principal epididymal epithelial cells and spermatozoa located within the lumen of the epididymal duct of monkeys [16], horses [14] and Sprague-Dawley rats [6]. In our experiment, iNOS expression was noted in the stereocilia and cytoplasm of the apical part of the principal cells, and in the cytoplasm of the basal cells of the caput and cauda epididymal epithelium of the control rats. The immunostaining was also observed in spermatozoa inside the lumen of the studied segments of the epididymis. We noticed that the pattern and the level of inducible nitric oxide synthase expression in the epididymis of the DHT-deficient rats had changed. In both groups of finasteride-treated rats (Fin28, Fin56), we observed an increase in the level of iNOS immunoeexpression in the epithelial cells in the studied segments of the epididymis. However, the product of immunoreaction was diffuse and occupied the whole cytoplasm of the principal cells of the epithelium in the caput epididymis, while the cytoplasm of the clear cells was

moderately stained. It was interesting that in the epithelium of the cauda epididymis, groups of epithelial cells with stronger immunoreactivity were visible. This observation could indicate that the function of the epithelial cells varies, and that when some cells are active, others are resting.

To evaluate the influence of DHT on the activity of iNOS in the epididymal epithelial cells, without potential interference from endogenous hormones as *in vivo*, we performed additional *in vitro* studies. We cultured the cells in a medium with or without DHT and with or without LPS and IFN- γ stimulation. The results confirmed that *in vitro*, DHT is involved in iNOS expression and NO formation. It is known that NO may be involved in the biosynthesis and secretion of steroid hormones in the male reproductive system [35], and that NO is able to inhibit the synthesis of testosterone by Leydig cells [9, 10]. It can be supposed that similarly to the Leydig cells, NO can modulate steroidogenesis in the epididymal epithelial cells. As documented, the epididymal epithelial cells *in vitro* synthesise and release androgens into the medium and are able to convert them into the estradiol E2 [28, 36].

Estrogens also play an important role in the functional regulation of testicular and epididymal cells. Cytochrome P450 aromatase is expressed in meiotic and post-meiotic germ cells in the gonads [38, 39] and in the epididymis of various species [36, 40, 41]. In this study, we verified the influence of NO on E2 synthesis in stimulated epididymal epithelial cells *in vitro*. The level of E2 was reduced in the medium of the cells. It is known that nitric oxide can also modulate cytochrome P450 aromatase activity by linking to the cysteine of the active centre of the enzyme [42], thus affecting the synthesis of estrogens

We obtained similar results *in vivo*, where in finasteride-treated rats, the level of circulating E2 decreased by approximately 40% (data unpublished). However, the activity of aromatase is not affected by NO only, because, as was presented by Shayu *et al.* (2006), supplementing the medium with DHT increased two-fold the mRNA P450arom level in cultured minces of rat caput and cauda epididymis [41]. However, in our preliminary unpublished experiment, in which the activity of cytochrome P450 aromatase was inhibited with letrozole in a dose of 2.5 mg/kg b.w/day for 56 days, the iNOS-immunoexpression was found to be increased in the caput and cauda epididymis (unpublished).

In conclusion, our data clearly indicates that finasteride-induced DHT deficiency intensifies the constitutive expression of iNOS in most rat testicular and epididymal cells, and therefore it can be expected that the expression of the inducible nitric oxide synthase (iNOS) could be regulated by DHT. On the other hand, the profile of circulating sex hormone levels strongly suggests that regulation of constitutive iNOS expression is complex and needs more detailed study.

REFERENCES

1. Moncada, S., Palmer, R.M. and Higgs, E.A. Nitric oxide: physiology, pathophysiology, and pharmacology. **Pharmacol. Rev.** 43 (1991) 109-134.
2. Xie, Q. and Nathan, C. The high-output nitric oxide pathway: role and regulation. **J. Leukoc. Biol.** 56 (1994) 576-582.
3. Knowles, R.G. and Moncada, S. Nitric oxide synthases in mammals. **Biochem. J.** 298 (1994) 249-258.
4. Lowenstein, C.J., Glatt, C.S., Bredt, D.S. and Snyder, S.H. Cloned and expressed macrophage nitric oxide synthase contrasts with the brain enzyme. **Proc. Natl. Acad. Sci. USA.** 89 (1992) 6711-6715.
5. Kröncke, K.D., Fehsel, K. and Kolb-Bachofen, V. Inducible nitric oxide synthase and its product nitric oxide, a small molecule with complex biological activities. **Biol. Chem. Hoppe. Seyler.** 376 (1995) 327-343.
6. Burnett, A.L., Ricker, D.D., Chamness, S.L., Maguire, M.P., Crone, J.K., Bredt, D.S., Snyder, S.H. and Chang, T.S. Localization of nitric oxide synthase in the reproductive organs of the male rat. **Biol. Reprod.** 52 (1995) 1-7.
7. Ehrén, I., Adolfsson, J. and Wiklund, N.P. Nitric oxide synthase activity in the human urogenital tract. **Urol. Res.** 22 (1994) 287-290.
8. Stéphan, J.P., Guillemois, C., Jégou, B. and Bauché, F. Nitric oxide production by Sertoli cells in response to cytokines and lipopolysaccharide. **Biochem. Biophys. Res. Commun.** 213 (1995) 218-224.
9. Tatsumi, N., Fujisawa, M., Kanazaki, M., Okuda, Y., Okada, H., Arakawa, S. and Kamidono, S. Nitric oxide production by cultured rat Leydig cells. **Endocrinology** 138 (1997) 994-998.
10. Weissman, B.A., Niu, E., Ge, R., Sottas, C.M., Holmes, M., Hutson, J.C. and Hardy, M.P. Paracrine modulation of androgen synthesis in rat leydig cells by nitric oxide. **J. Androl.** 26 (2005) 369-378.
11. Wiszniewska, B., Kurzawa, R., Ciechanowicz, A. and Machaliński, B. Inducible nitric oxide synthase in the epithelial epididymal cells of the rat. **Reprod. Fertil. Dev.** 9 (1997) 789-794.
12. Kurzawa, R., Barcew-Wiszniewska, B. and Skowron, J. Rat epididymal epithelial cells produce nitric oxide upon concomitant lipopolysaccharide and interferon-gamma stimulation. **Folia Histochem. Cytobiol.** 4 (1996) 85-86.
13. O'Bryan, M.K., Schlatt, S., Gerdprasert, O., Phillips, D.J., de Kretser, D.M. and Hedger, M.P. Inducible nitric oxide synthase in the rat testis: evidence for potential roles in both normal function and inflammation-mediated infertility. **Biol. Reprod.** 63 (2000) 1285-1293.
14. Ha, T.Y., Kim, H.S. and Shin, T. Expression of constitutive endothelial, neuronal and inducible nitric oxide synthase in the testis and epididymis of horse. **J. Vet. Med. Sci.** 66 (2004) 351-356.

15. Kim, H.C., Byun, J.S., Lee, T.K., Jeong, C.W., Ahn, M. and Shin, T. Expression of nitric oxide synthase isoform in the testes of pigs. **Anat. Histol. Embryol.** 36 (2007) 135-138.
16. Sun, L., Ren, Y.P., Jiang, W., Zhang, M.Y. and Hou, Q.Y. Expression and role of nitric oxide synthase in the testis and epididymis of *Macaca fascicularis*. **Zhonghua Nan Ke Xu** 12 (2006) 876-878.
17. Jin, Y. and Penning, T.M. Steroid 5 α -reductases and 3 α -hydroxysteroid dehydrogenases: key enzymes in androgen metabolism. **Best Pract. Res. Clin. Endocrinol. Metab.** 15 (2001) 79-94.
18. Russell, D.W. and Wilson, J.D. Steroid 5 α -reductase: two genes/two enzymes. **Annu. Rev. Biochem.** 63 (1994) 25-61.
19. Viger, R.S. and Robaire, B. Steady state steroid 5 α -reductase messenger ribonucleic acid levels and immunocytochemical localization of the type 1 protein in the rat testis during postnatal development. **Endocrinology** 136 (1995) 5409-5415.
20. Pratis, K., O'Donnell, L., Ooi, G.T., McLachlan, R.I. and Robertson, D.M. Enzyme assay for 5 α -reductase type 2 activity in the presence of 5 α -reductase type 1 activity in rat testis. **J. Steroid. Biochem. Mol. Biol.** 75 (2000) 75-82.
21. Viger, R.S. and Robaire, B. The mRNAs for the steroid 5 α -reductase isoenzymes, types 1 and 2, are differentially regulated in the rat epididymis. **J. Androl.** 17 (1996) 27-34.
22. Mahony, M.C., Swanlund, D.J., Billeter, M., Roberts, K.P. and Pryor, J.L. Regional distribution of 5 α -reductase type 1 and type 2 mRNA along the human epididymis. **Fertil. Steril.** 69 (1998) 1116-1121.
23. Robaire, B. and Henderson, N.A. Actions of 5 α -reductase inhibitors on the epididymis. **Mol. Cell. Endocrinol.** 250 (2006) 190-195.
24. Metcalf, B.W., Levy, M.A. and Holt, D.A. Inhibitors of steroid 5 α -reductase in benign prostatic hyperplasia, male pattern baldness and acne. **Trends Pharmacol. Sci.** 10 (1989) 491-495.
25. George, F.W. Androgen metabolism in the prostate of the finasteride-treated, adult rat: a possible explanation for the differential action of testosterone and 5 α -dihydrotestosterone during development of male urogenital tract. **Endocrinology** 138 (1997) 871-877.
26. Vaughan, E.D. Long-term experience with 5 α -reductase inhibitors. **Rev. Urol.** 5 (2003) S22-S27.
27. Kolasa, A., Marchlewicz, M., Wenda-Rózewicka, L. and Wiszniewska, B. Morphology of the testis and the epididymis in rats with dihydrotestosterone (DHT) deficiency. **Rocz. Akad. Med. Białymst.** 49 (2004) 117-119.
28. Wiszniewska, B. Steroidogenic characteristics of in vitro cultured epididymal epithelial cells of the rat. **Reprod. Biol.** 1 (2001) 60-66.

29. Ding, A.H., Nathan, C.F. and Stuehr, D.J. Release of reactive nitrogen intermediates and reactive oxygen intermediates from mouse peritoneal macrophages. Comparison of activating cytokines and evidence for independent production. **J. Immunol.** 141 (1988) 2407-2412.
30. Zini, A., Abitbol, J., Girardi, S.K., Schulsinger, D., Goldstein, M. and Schlegel, P.N. Germ cell apoptosis and endothelial nitric oxide synthase (eNOS) expression following ischemia-reperfusion injury to testis. **Arch. Androl.** 41 (1998) 57-65.
31. Lee, N.P. and Cheng, C.Y. Regulation of Sertoli cell tight junction dynamics in the rat testis via the nitric oxide synthase/soluble guanylate cyclase/3',5'-cyclic guanosine monophosphate/protein kinase G signaling pathway: an in vitro study. **Endocrinology** 144 (2003) 3114-3129.
32. Lue, Y., Sinha-Hikim, A.P., Wang, C., Leung, A. and Swerdloff, R.S. Functional role of inducible nitric oxide synthase in the induction of male germ cell apoptosis, regulation of sperm number and determination of testis size: evidence from null mutant mice. **Endocrinology** 144 (2003) 3092-3100.
33. Zini, A., O'Bryan, M.K., Magid, M.S. and Schlegel, P.N. Immunohistochemical localization of endothelial nitric oxide synthase in human testis, epididymis, and vas deferens suggests a possible role for nitric oxide in spermatogenesis, germ maturation, and programmed cell death. **Biol. Reprod.** 55 (1996) 935-941.
34. Gerdprasert, O., O'Bryan, M.K., Muir, J.A., Caldwell, A.M., Schlatt, S., de Krester, D.M. and Hedger, M.P. The response of testicular leucocytes to lipopolysaccharide-induced inflammation: further evidence heterogeneity of the testicular macrophage population. **Cell. Tissue Res.** 308 (2002) 277-285.
35. Welsh, C., Watson, M.E., Poth, M., Hong, T. and Francis, G.L. Evidence to suggest nitric oxide is an interstitial regulator of Leydig Cell steroidogenesis. **Metabolism** 44 (1995) 234-238.
36. Wiszniewska, B. Primary culture of the rat epididymal epithelial cells as a source of oestrogen. **Andrologia** 34 (2002) 180-187.
37. Chamness, S.L., Ricker, D.D., Crone, J.K., Dembeck, C.L., Maguire, M.P., Burnett, A.L. and Chang, T.S. The effect of androgen on nitric oxide synthase in the male reproductive tract of the rat. **Fertil. Steril.** 63 (1995) 1101-1107.
38. Carreau S. The testicular aromatase: from gene to physiological role. **Reprod. Biol.** 2 (2002) 5-12.
39. Lambard, S., Galeraud-Denis, I., Saunders, P.T. and Carreau, S. Human immature germ cells and ejaculated spermatozoa contain aromatase and oestrogen receptors. **J. Mol. Endocrinol.** 32 (2004) 279-289.
40. Carpino, A., Romeo, F. and Rago, V. Aromatase immunolocalization in human ductuli efferentes and proximal ductus epididymis. **J. Anat.** 204 (2004) 217-220.

41. Shayu, D. and Rao, A.J. Expression of functional aromatase in the epididymis: role of androgens and LH in modulation of expression and activity. **Mol. Cell. Endocrinol.** 249 (2006) 40-50.
42. Snyder, G.D., Holmes, R.W., Bates, J.N. and Van Voorhis, B.J. Nitric oxide inhibits aromatase activity: mechanism of action. **J. Steroid. Biochem. Mol. Biol.** 58 (1996) 63-69.