

Traumatic Chance Fracture of Cervical Spine: A Rare Fracture Type and Surgical Management

Abstract

Cervical spine chance fracture (flexion-distraction) is a rare type of fracture, and the surgical management remains a dilemma to the neurosurgeons as there is a paucity of evidence accordingly. We herein report a traumatic chance fracture of C7 fractures and its surgical management. A 33-year-old male was transferred to our center after being hit as pedestrian and was diagnosed to have a chance fracture of C7 and bilateral C7 root injury. He underwent open reduction of the deformity by posterior-only fixation of C5 and C6 with a lateral mass screw and T1 and T2 with pedicular screws. The neurological examination improved postoperatively, and the patients were neurologically intact after 6 months of treatment. Traumatic cervical spine chance fracture is extremely rare and can be managed surgically through posterior fixation and open reduction of the deformity. The best choice of treatment is limited by the paucity of the evidence and should be individualized.

Keywords: Cervical spine, chance fracture, fixation, surgical management

Introduction

Cervical spine fractures following trauma are among the most common traumatic injuries which are associated with significant morbidity especially when accompanied by the cervical spinal cord injury.^[1,2] The epidemiologic studies have demonstrated that the cervical spine fractures account for 17%–26% of all spinal fractures following trauma and 8.5%–11% of all spinal cord injuries.^[1-4] The most frequent fracture types were closed at C2 (32.0%) and C7 (20.9%).^[2] The most of the patients present with the fractures types of axial loading and the flexion-distraction (FD) types are extremely rare in the cervical spine.^[5]

The chance fracture was first described by G. Q. Chance, a British radiologist, in 1948.^[6] The pattern of this fracture is a pure bony injury extending horizontally through the spinous process, pedicles, and vertebral body, respectively.^[6] Mechanism of this fracture is FD forces that seen in a car accident when the passenger is restrained with a seat belt.^[7] The most common location of this fracture is thoracolumbar area (T10-L2), and the

This is an open access journal, and articles are distributed under the terms of the Creative Commons Attribution-NonCommercial-ShareAlike 4.0 License, which allows others to remix, tweak, and build upon the work non-commercially, as long as appropriate credit is given and the new creations are licensed under the identical terms.

For reprints contact: reprints@medknow.com

management is considered surgical fixation and open reduction of the deformity using the pedicular screws.^[8] However, the chance fracture of the cervical spine is extremely rare as the cervical spine does not have an anterior support except for the anterior longitudinal ligament (ALL), and its flexibility does not allow the posterior components to be ruptured.^[9] Currently, only a few cases of cervical spine chance fractures have been reported in the literature especially in patients with ankylosing spondylitis (AS).^[10-14] The surgical management of patients with cervical spine chance fracture remains a dilemma to the neurosurgeons as there is a paucity of evidence accordingly. In the current study, we report a traumatic chance fracture of C7 fractures and its surgical management.

Case Report

A 33-year-old male was transferred to our center (Shahid Rajaei hospital, a Level I trauma center affiliated with Shiraz University of Medical Sciences in Southern Iran) by the emergency service. He was struck as a pedestrian by a car in a rural road. On admission, he had a Glasgow Coma Scale of 15, bilateral reactive pupils, and stable vital sign. He complained of severe neck pain. In physical examination,

How to cite this article: Eghbal K, Abdollahpour HR, Ghaffarpasand F. Traumatic chance fracture of cervical spine: A rare fracture type and surgical management. Asian J Neurosurg 2018;13:906-9.

**Keyvan Eghbal,
Hamid Reza
Abdollahpour¹,
Fariborz
Ghaffarpasand²**

Departments of Neurosurgery and ¹Orthopedics, Shiraz University of Medical Sciences, ²Student Research Committee, Shiraz University of Medical Sciences, Shiraz, Iran

Address for correspondence:
Dr. Fariborz Ghaffarpasand,
Shiraz University of Medical
Sciences, Neurosurgery Office,
Namazi Hospital, Namazi
Square, PO Box 71973-11351,
Shiraz, Iran.
E-mail: fariborz.
ghaffarpasand@gmail.com,
ghafarf@sums.ac.ir

Access this article online

Website: www.asianjns.org

DOI: 10.4103/ajns.AJNS_80_18

Quick Response Code:



he had midline cervical tenderness in the lower cervical region with the bilateral symmetrical weakness of the distal part of the upper extremities (muscle powers: 4/5). There was no proximal weakness of upper extremities, and the lower extremities were intact. The anal and urinary sphincters were normal, the deep tendon reflexes were normal, the Hoffman's reflex was negative, and the plantar reflexes were downward (there was no sign of myelopathy). The patient suffered from paresthesia in the 4th and 5th fingers of both upper extremities. Cervical computed tomography (CT) scan revealed a C7 fracture with compression of the vertebral body and distraction of the middle and posterior column through the body elements. There was no lockage of the facets [Figure 1]. Magnetic resonance imaging of the cervical spine revealed FD of the C7 vertebral along with rupture of the ligamentum flavum and interspinous and supraspinous ligaments also. There was no signal change in the cervical spinal cord [Figure 2]. He was diagnosed with a chance fracture of the C7 along with bilateral C7 root injuries. We underwent emergency surgery through a posterior approach. Cervicothoracic spine fixation with lateral mass screws of C5 and C6 and pedicular screws of T1 and T2 utilizing a rod was performed. Open reduction of the deformity was conducted [Figure 3]. Postoperatively, the patients improved his muscle powers of the distal part of the upper extremities and the paresthesia resolved. He had an uneventful hospital course and was discharged on the 4th postoperative day with a cervical Philadelphia collar. On 6-month follow-up, he had an intact neurological examination and no cervical pain and radiculopathy. He had developed cervicothoracic fusion and back on his daily activity and work.

Discussion

The FD fractures of the cervical spine are extremely rare, and the reported cases in the literature confine to patients with (AS).^[10,12,14] However, only one case of traumatic chance fracture of the cervical spine has been reported in the old literature.^[13] In the current study, we have described the chance fracture of C7 in patients with severe trauma which was successfully managed by posterior cervical instrumentation. The management of these injuries is controversial mainly because of the rarity of the subject and lack of appropriate evidence.

Patients with AS develop posterior and anterior fusion of the vertebrae secondary to inflammation and spondylitis. This results in the formation of “Bamboo spine” which makes it susceptible to fractures extending to the posterior elements. However, the chance fracture in these patients is extremely rare. Meena and Dhandapani^[10] reported a chance fracture of the C5, C6 vertebrae resulting in quadriplegia following a car collision. The patient was placed over cervical traction to reduce the fracture and undergo 360° fusion surgery. However, the patient

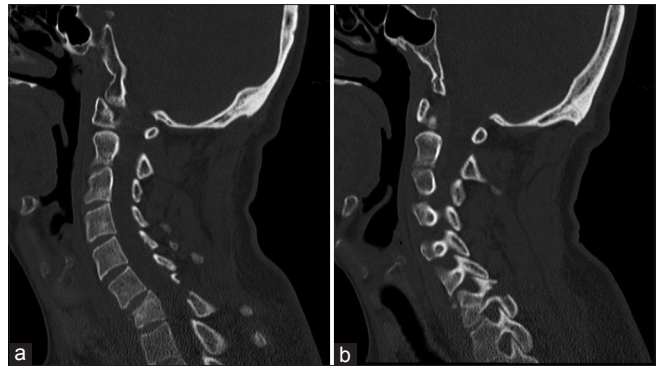


Figure 1: Sagittal cervical computed tomography-scan of the patient demonstrating flexion-distraction fracture of the C7 vertebrae. As demonstrated there is a compression fracture of the C7 vertebral body (a), and the fracture line has expanded through the posterior bony elements (b) resulting in fracture distraction injury

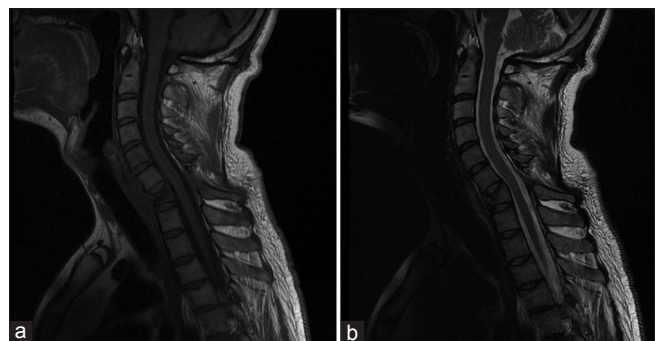

Figure 2: The T1-weighted (a) and T2-weighted (b) sagittal Magnetic resonance imaging of the cervical spine of the patient demonstrating the flexion-distraction injury of the C7 vertebra with rupture of the ligamentum flavum and interspinous and supraspinous ligaments. There is no sign of cervical spinal cord signal change

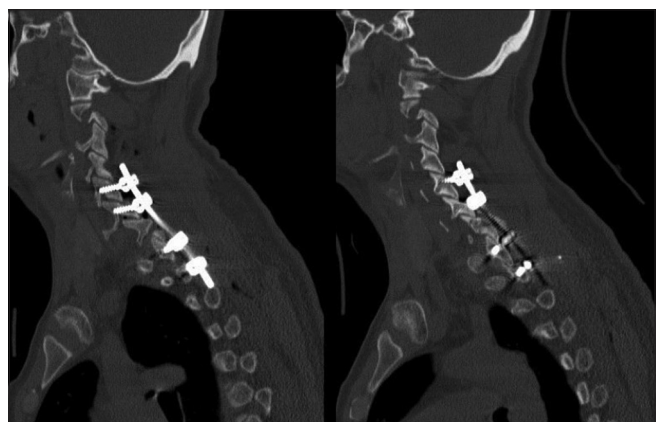

Figure 3: Postoperative sagittal computed tomography scan of the cervical spine demonstrating complete reduction of the deformity (C7 flexion-distraction injury) by posterior spinal fixation with C5 and C6 lateral mass screws and T1 and T2 pedicular screws insertion. The reduction of the deformity has resulted in normal cervical spine alignment and intact canal

developed hypotension and died and could not be operated.^[10] Wong and Yu^[12] also reported a chance fracture of C4 and quadriplegia in a patient with AS following fall from height. He was managed surgically by a 360° fusion

and regained his muscle powers and returned to normal daily activity and employment.^[12] In another study, Gilard *et al.*^[11] reported a series of seven patients with AS who presented with cervical spine fractures following trauma. Among this series, there were two patients with cervical spine chance fractures. Both of the patients presented with spinal cord injury and quadriplegia and were managed surgically by 360° fusion.^[11] Although there are several cases of cervical spine chance fracture in patients with AS; however, there is only one case of traumatic chance fracture of cervical spine reported in the literature.^[13] Our reported case is among the few cases of cervical spine chance fracture in the literature.

The mechanism responsible for this fracture pattern is FD forced around a fulcrum.^[6,9] If the fulcrum is in the anterior side of ALL, all three column of spine will fail in tension, such as seat belt injury, and if the fulcrum is on or posterior to ALL, the anterior column will fail in compression and posterior and middle column will fail in tension forces.^[6] FD forced produce three type fracture pattern: (1) complete ligamentous fracture; (2) pure osseous FD fracture; and (3) combined bony and ligamentous fracture of spine.^[8,9] Although all three types are now commonly identified under the name of chance fracture, but in fact, a true chance fracture is pure bony lesion.^[6,9] Less than 10% of all thoracolumbar fractures are FD type, and true chance fracture is a subtype of that.^[9] The most common location of true chance fractures is thoracolumbar junction from T10 to L2, and a few cases are reported in the upper thoracic region.^[15]

Treatment of chance fracture depends on the presence of neurological deficit or mechanical instability of spinal column.^[8] Pure bony chance fractures of thoracolumbar area without neurological problem are generally managed with close reduction and hyperextension brace but is this treatment recommended in the cervical area too? Due to the rarity of this fracture in the cervical area, there was no evidence for therapeutic approach. Recently, Jack *et al.*^[5] reviewed the incidence of and examined risk factors for clinical and radiographic failure in patients with one segment cervical distraction injuries having undergone anterior surgical fixation. They have demonstrated that anterior-only approaches are associated with acceptable outcome in patients with single level distraction injuries.^[5] Accordingly, the management of cervical spine chance fractures remains controversial as there is a paucity of the evidence. In the current case, we choose a posterior-only approach as there was no anterior cord compression and the cervical spine canal had a normal diameter. Currently, the choice of surgical fixation is mostly based on the expert's opinion.

Conclusion

Traumatic cervical spine chance fracture is extremely rare and can be managed surgically through posterior fixation

and open reduction of the deformity. The best choice of treatment is limited by the paucity of the evidence and should be individualized.

Declaration of patient consent

The authors certify that they have obtained all appropriate patient consent forms. In the form the patient(s) has/have given his/her/their consent for his/her/their images and other clinical information to be reported in the journal. The patients understand that their names and initials will not be published and due efforts will be made to conceal their identity, but anonymity cannot be guaranteed

Acknowledgment

The authors would like to acknowledge the participation of the patient and his family for providing the permission of publishing his case. We also would like to acknowledge the editorial assistance of Diba Nigar Research Institute for improving the English and style of the manuscript.

Financial support and sponsorship

Nil.

Conflicts of interest

There are no conflicts of interest.

References

1. Kamravan HR, Haghnegahdar A, Paydar S, Khalife M, Sedighi M, Ghaffaripasand F, *et al.* Epidemiological and clinical features of cervical column and cord injuries; A 2-year experience from a large trauma center in Southern Iran. *Bull Emerg Trauma* 2014;2:32-7.
2. Passias PG, Poorman GW, Segreto FA, Jalai CM, Horn SR, Bortz CA, *et al.* Traumatic fractures of the cervical spine: Analysis of changes in incidence, cause, concurrent injuries, and complications among 488,262 patients from 2005 to 2013. *World Neurosurg* 2018;110:e427-37.
3. Liu P, Yao Y, Liu MY, Fan WL, Chao R, Wang ZG, *et al.* Spinal trauma in Mainland China from 2001 to 2007: An epidemiological study based on a nationwide database. *Spine (Phila Pa 1976)* 2012;37:1310-5.
4. Wang H, Ou L, Zhou Y, Li C, Liu J, Chen Y, *et al.* Traumatic upper cervical spinal fractures in teaching hospitals of China over 13 years: A retrospective observational study. *Medicine (Baltimore)* 2016;95:e5205.
5. Jack A, Hardy-St-Pierre G, Wilson M, Choy G, Fox R, Nataraj A, *et al.* Anterior surgical fixation for cervical spine flexion-distraction injuries. *World Neurosurg* 2017;101:365-71.
6. Chance GQ. Note on a type of flexion fracture of the spine. *Br J Radiol* 1948;21:452.
7. Gordon ZL, Gillespie RJ, Ponsky TA, Barksdale EM Jr., Thompson GH. Three siblings with chance fractures: The importance of 3-point restraints. *J Pediatr Orthop* 2009;29:856-9.
8. Vaccaro AR, Schroeder GD, Kepler CK, Cumhur Oner F, Vialle LR, Kandziora F, *et al.* The surgical algorithm for the AOSpine thoracolumbar spine injury classification system. *Eur Spine J* 2016;25:1087-94.
9. Vaccaro AR, Koerner JD, Radcliff KE, Oner FC,

- Reinhold M, Schnake KJ, *et al.* AOSpine subaxial cervical spine injury classification system. *Eur Spine J* 2016;25:2173-84.
10. Meena RK, Dhandapani S. Chance fracture in ankylosing spondylitis – Not merely by chance! Danger of injudicious use of skull traction. *Spine J* 2015;15:e47-8.
 11. Gilard V, Curey S, Derrey S, Perez A, Proust F. Cervical spine fractures in patients with ankylosing spondylitis: Importance of early management. *Neurochirurgie* 2014;60:239-43.
 12. Wong AS, Yu DH. Cervical spine fracture in a patient with ankylosing spondylitis causing a C2-T9 spinal epidural hematoma- treatment resulted in a rapid and complete recovery from tetraplegia: Case report and literature review. *Asian J Neurosurg* 2015;10:53.
 13. Budorick TE, Anderson PA, Rivara FP, Cohen W. Flexion-distraction fracture of the cervical spine. A case report. *J Bone Joint Surg Am* 1991;73:1097-100.
 14. Xiang LB, Yu HL, Liu J, Chen Y, Yang HF. One-stage surgery by a combined anterior-posterior approach to treat ankylosing spondylitis complicated by a multiple-level cervical vertebral chance fracture. *Mod Rheumatol* 2015;25:282-5.
 15. Daffner RH. Chance fracture of the upper thoracic spine. *AJR Am J Roentgenol* 2005;185:555.