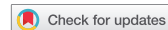
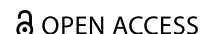


SHORT COMMUNICATION



## Structural signature of trauma: white matter volume in right inferior frontal gyrus is positively associated with use of expressive suppression in recently traumatized individuals

Katharina Wermuth<sup>a,b</sup>, Dominik Ülsmann<sup>c</sup>, Janine Borngräber<sup>b</sup>, Jürgen Gallinat<sup>b,d</sup>, Olaf Schulte-Herbrüggen<sup>b,c</sup> and Simone Kühn<sup>id a,d</sup>

<sup>a</sup>Max Planck Institute for Human Development, Center for Lifespan Psychology, Berlin, Germany; <sup>b</sup>St. Hedwig-Krankenhaus, Clinic for Psychiatry and Psychotherapy, Charité University Medicine, Berlin, Germany; <sup>c</sup>Friedrich Von Bodelschwingh-Klinik Clinic for Psychiatry, Psychotherapy and Psychosomatic Medicine, Berlin, Germany; <sup>d</sup>University Clinic Hamburg-Eppendorf, Clinic and Polyclinic for Psychiatry and Psychotherapy, Hamburg, Germany

### ABSTRACT

**Background:** Differences in grey and white matter structure have been found between trauma-exposed individuals with and without PTSD. Yet, it remains unclear which functional processes are underlying these volumetric changes. Avoidance- and suppression-based emotion regulation strategies are candidates of interest since they play an important role in the development and maintenance of PTSD.

**Method:** We used voxel-based morphometry to examine differences in brain structure in 20 recently trauma-exposed individuals and 20 healthy controls in respect of their relation to emotion regulation.

**Results:** We found a significantly larger white matter volume close to the right inferior frontal gyrus (rIFG) in patients compared to healthy controls. White matter volume close to the rIFG was positively correlated with expressive suppression.

**Conclusion:** The region of volumetric white matter difference in our study overlaps with brain regions previously associated with executive functioning and inhibitory control, functions that are known to be impaired in PTSD. Our findings support the idea that impaired executive functions in PTSD might be compensated by suppression-based emotion regulation strategies.

### La firma estructural del trauma: el volumen de materia blanca en la circunvolución frontal inferior derecha se asocia positivamente con el uso de la supresión expresiva en individuos recientemente traumatizados

**Antecedentes:** Se han encontrado diferencias en estructuras de la sustancia gris y blanca entre individuos expuestos a trauma con y sin TEPT. Sin embargo, no está claro qué procesos funcionales subyacen a estos cambios volumétricos. Las estrategias de regulación emocional basadas en la supresión y evitación son candidatas de interés ya que desempeñan un rol importante en el desarrollo y mantención del TEPT.

**Método:** Usamos morfometría basada en voxel para examinar las diferencias en la estructura cerebral en 20 individuos recientemente expuestos a trauma y 20 controles sanos, con respecto a su relación con la regulación emocional.

**Resultados:** Encontramos un volumen de sustancia blanca significativamente mayor cerca de la circunvolución frontal inferior derecha (rIFG por sus 35 siglas en inglés) en pacientes comparados con los controles sanos. El volumen de sustancia blanca cerca del rIFG se correlacionó positivamente con la supresión expresiva.

**Conclusiones:** La región de diferencia de volumen de materia blanca en nuestro estudio se superpone con las regiones del cerebro previamente asociadas con el funcionamiento ejecutivo y el control inhibitorio, las que se conocen que están alteradas en el TEPT. Nuestros hallazgos apoyan la idea que las alteraciones de las funciones ejecutivas en el TEPT podrían compensarse con estrategias de regulación emocional basadas en la supresión.

### 创伤的结构特征:右下额回中的白质体积与最近遭受创伤个体的表达抑制作用呈正相关

**创伤的结构特征:** 右下额回中的白质体积与最近遭受创伤个体的表达抑制作用呈正相关  
**背景:** 已经在遭受创伤后有和无创伤后应激障碍的人之间,发现灰质和白质的结构差异。然而,尚不清楚这些体积变化背后的功能过程。基于回避和抑制的情绪调节策略是所关注的候选因素,因为它们它们在PTSD的发展和保持中起着重要作用。

### ARTICLE HISTORY

Received 15 April 2020  
Revised 23 September 2020  
Accepted 3 October 2020

### KEYWORDS

Trauma; voxel-based morphometry; emotion regulation; expressive suppression; right inferior frontal gyrus; white matter

### PALABRAS CLAVE

Trauma; morfometría basada en voxel; regulación emocional; supresión expresiva; circunvolución frontal inferior derecha; sustancia blanca

### 关键词

创伤; 基于体素的形态测量学; 情绪调节; 表达抑制; 右下额回; 白质

### HIGHLIGHTS

- Differences in brain structure found in recently traumatized individuals compared to healthy controls.
- Increased white matter volume close to the right inferior frontal gyrus of recently traumatized individuals correlates positively with expressive suppression.

**方法：**我们使用基于体素的形态测量学方法考查了20名最近遭受创伤的个体和20名健康对照者之间在情绪调节方面大脑的结构差异。

**结果：**我们发现，与健康对照组相比，患者右下额回 (rIFG) 附近的白质体积明显更大。rIFG 附近的白质体积与表达抑制呈正相关。

**结论：**在我们的研究中，白质体积差异区域与前人发现执行功能和抑制控制这些已知PTSD受损功能的相关脑区有所重叠。我们的发现支持PTSD执行功能损伤也许可以被基于抑制的情绪调节策略所补偿。

**关键词：**创伤；基于体素的形态测量学；情绪调节；表达抑制；右下额回；白质

## 1. Introduction

Exposure to potentially traumatic events (such as sexual or physical assault) can lead to a range of psychological symptoms occurring immediately after the traumatic event. These symptoms are summarized as acute stress disorder (ASD) in the fifth edition of the *Diagnostic and Statistical Manual of Mental Disorders (DSM-5)*, American Psychological Association, 2013) and include re-experiencing the event (e.g. in intrusive memories, flashbacks or nightmares), low mood, difficulties in experiencing positive emotions such as happiness, dissociative symptoms, avoidance of external reminders, memories or feelings associated with the event and arousal symptoms such as hypervigilance, irritable behaviour and sleep disturbances. The majority of people recover from a traumatic event over time. However, some people do not, resulting in the development of a posttraumatic stress disorder (PTSD).

Traumatic experiences and their consequences as ‘an extremely aversive form of learning’ might result in changes in brain structure (Siehl, King, Burgess, Flor, & Nees, 2018). Volumetric differences in brain structures underlying memory and emotion regulation functions have been observed between individuals with and without PTSD in several neuroimaging studies, affecting areas such as the hippocampus, anterior cingulate cortex (ACC), amygdala, insula and medial prefrontal cortex (mPFC) (Karl et al., 2006; Woon, Sood, & Hedges, 2010). Changes in grey matter (Li et al., 2014; Zhang et al., 2011) and white matter integrity have been found in PTSD patients (Fani et al., 2012; Li et al., 2016), predominantly in cingulum and frontal regions as well as frontal gyrus (Siehl et al., 2018). Grey matter reductions (Sui et al., 2010; Zhang et al., 2011) but also an increase in grey matter in some regions (e.g. in the left precentral cortex, inferior parietal lobule and right post-central cortex) have been found in trauma-exposed individuals with PTSD in contrast to trauma-exposed individuals without PTSD (Sui et al., 2010). As a possible explanation for structural changes in PTSD patients, Li et al. (2016) suggest that a heightened demand for emotion regulation might lead to increased myelination in brain regions related to emotion regulation.

Pre-trauma difficulties in emotion regulation, as well as difficulties regulating negative emotions in the aftermath of a traumatic event, are positively associated with posttraumatic stress symptoms (Badour & Feldner, 2013;

Bardeen, Kumpula, & Orcutt, 2013; Ehring & Quack, 2010), suggesting that ineffective emotion regulation strategies play a crucial role in the development and maintenance of PTSD. Two specific emotion regulation strategies – *cognitive reappraisal* and *expressive suppression* – have been well investigated in this context. Cognitive reappraisal and expressive suppression have been introduced by Gross (1998a, 1998b) in his process model of emotion. Cognitive reappraisal includes the modification of one’s cognitions concerning the situation and therefore altering its meaning. Expressive suppression modulates the response tendencies of an emotion already generated, inhibiting its related facial expression and emotional expressive behaviour. Inter-individual differences in emotion regulation are thought to be quite stable over time and constitute a trait. Habitual use of both strategies is assessed by the Emotion Regulation Questionnaire (ERQ; Gross & John, 2003). In accordance with Gross and Levenson (1993), we refer to suppression of emotional expressions (expressive suppression) as a characteristic of emotion suppression in this article. So far, PTSD has been associated with a greater use of expressive suppression and an underutilization of cognitive change strategies (e.g. reappraisal) to decrease negative emotion experience (Ehring & Quack, 2010; Shepherd & Wild, 2014).

Cognitive and behavioural processes of emotion regulation (e.g. control and inhibition of emotion response tendencies as well as cognitive change strategies) require active preparatory and inhibitory processes (Gross & Levenson, 1993). Looking at functional brain activity related to suppression and reappraisal, a study of Vanderhasselt, Kühn, and De Raedt (2013) found neural activity in the right frontal cortex, right inferior parietal lobe, lower precuneus and left dorsolateral prefrontal cortex to be associated with suppression of emotions in an experimental paradigm. Frequent use of emotion regulation strategies might as well lead to structural changes in the brain. Habitual use of expressive suppression was positively correlated with grey matter volume in the dorsomedial prefrontal cortex (dmPFC) in a study with healthy participants (Kühn, Gallinat, & Brass, 2011). Other studies report a positive association between expressive suppression and grey matter volume in the dorsal anterior/paracingulate cortex and medial prefrontal cortex (vmPFC) (Hermann, Bieber, Keck, Vaitl, & Stark, 2014) as well as anterior insula volume (Giuliani,

Drabant, & Gross, 2011b). Studies investigating brain structure in recently traumatized individuals and patients with recent-onset PTSD have mostly recruited survivors of fire accidents (Li et al., 2006), accidents (Wignall et al., 2004) and coalmine-flood disaster (Chen et al., 2012; Liu, Li, Luo, Lu, & Yin, 2012; Qi et al., 2013; Zhang et al., 2011). Few studies have investigated brain structure in victims of interpersonal violence in an early state after trauma exposure such as Fani et al. (2019). As to our knowledge, the association between expressive suppression as well as cognitive reappraisal and brain structure has not been investigated in recently trauma-exposed individuals so far.

In the current study, we aimed to assess differences in brain regions related to emotion regulation, in particular those that are related to unfavourable emotion regulation strategies such as emotion suppression. We used voxel-based morphometry (VBM) with an exploratory whole-brain approach to examine structural differences in trauma-exposed individuals in an early state after the traumatic event compared to healthy-matched controls.

## 2. Material and methods

### 2.1. Participants

In total 40 participants were recruited. Twenty of those were recently exposed to a traumatic event (mean age = 43.36 years (SD = 10.10), 13 females, 7 males, BDI = 21.25 (SD = 13.19), PDS Sum = 28.84 (SD = 10.77)) and recruited via the outpatient clinic at the St. Hedwig Hospital Charité University Clinic Berlin (Table 1). The mean number of days between the happening of the individuals' traumatic event and our testing session was 77.3 days (SD 50.8). Inclusion criteria for the patient group were an experience of severe interpersonal violence (e.g. sexual assault/rape, physical assault, intimate partner violence/domestic violence) within the last 4 months. All patients were diagnosed with post-traumatic stress disorder, adjustment disorder or acute stress reaction by trauma therapists according to the criteria of the International statistical classification of diseases and related health problems (ICD-10; World Health Organization, 2004) in relation to this event.

Diagnoses were taken from the medical record. Exclusion criteria for patients were substance abuse, acute suicidal tendencies and some comorbidities such as psychotic episodes and severe depressivity. The control group consisted of twenty healthy volunteers (mean age = 43.39 years (SD = 10.13), 13 females, years of education = 17.3 (SD = 3.28), BDI = 3.84 (SD = 3.18)) who were recruited by means of advertisements and the internet. Healthy participants were screened using the Mini-International Neuropsychiatric Interview (Sheehan et al., 1998). No healthy control subject had an axis-I psychiatric disorder according to the interview. Other medical and neurological disorders were excluded in a personal interview. Substance and medication use were carefully screened. Exclusion criteria for all subjects were abnormalities in the MRI or any clinically relevant abnormalities. The study was approved by the ethics committee of the German Psychological Association. After complete description of the study, subjects informed written consent was obtained from all participants.

### 2.2. Scanning procedure

Structural images were collected on a Siemens Tim Trio 3 T scanner (Erlangen, Germany) with a 12-channel head coil. Structural images were obtained using a T1-weighted magnetization prepared gradient-echo sequence (MPRAGE) based on the ADNI protocol (TR = 2500 ms; TE = 4.77 ms; TI = 1100 ms, acquisition matrix = 256 × 256 × 176; flip angle = 7°; 1×1×1mm<sup>3</sup> voxel size). Participants were asked to close their eyes and relax during data acquisition.

### 2.3. Questionnaires

We administered the Emotion Regulation Questionnaire (ERQ) designed by Gross and John (2003) comprising the two subscales expressive suppression and cognitive reappraisal. The ERQ consists of 10 items and participants give their answers on a 7-point Likert scale with the endpoints 'strongly disagree' and 'strongly agree'. The expressive suppression items clearly address the tendency of

**Table 1.** Sample characteristics (N = 40).

	Patient group (n = 20)		Control group (n = 20)		t Value	p Value
	N (%)	Mean (SD)	N (%)	Mean (SD)		
Gender						
Female	13 (65%)		13 (65%)			
Male	7 (35%)		7 (35%)			
		Mean (SD)		Mean (SD)		
Age		43.36 (10.10)		43.39 (10.13)		
PDS Sumscore		28.84 (10.77)		-		
BDI		21.25 (13.19)		3.84 (3.18)	5.73	0.00
ERQ – Expressive Suppression		15.65 (4.64)		12.85 (4.15)	2.01	0.05
ERQ – Cognitive Reappraisal		28.30 (6.34)		25.25 (5.30)	1.65	0.11

Note: all *p* values refer to two-sided tests. BDI = Beck Depression Inventory, PDS = Posttraumatic Diagnostic Scale.

participants not to show their emotions: ‘I keep my emotions to myself’, ‘When I am feeling positive emotions, I am careful not to express them’, ‘I control my emotions by not expressing them’ and ‘When I am feeling negative emotions, I make sure not to express them’. The cognitive reappraisal items address the tendency of participants to change the way they feel by altering their cognitions: ‘When I want to feel less negative emotions, I change the way I’m thinking about the situation’ and ‘When I’m faced with a stressful situation, I make myself think about it in a way that helps me stay calm’. In order to assess depressivity, we used the Beck Depression Inventory (BDI; Beck, Steer, & Brown, 1996) for all participants. Additionally, patients filled out the Posttraumatic Stress Diagnostic Scale (PDS; Ehlers, Steil, Winter, & Foa, 1996) to assess self-reported posttraumatic stress symptoms.

#### 2.4. Data analysis

Structural data were processed by means of the VBM8 toolbox (<http://dbm.neuro.uni-jena.de/vbm.html>) and SPM8 (<http://www.fil.ion.ucl.ac.uk/spm>) with default parameters. The VBM8 toolbox involves bias correction, tissue classification and affine registration. The affine registered GM and white matter (WM) segmentations were used to build a customized DARTEL (diffeomorphic anatomical registration through exponentiated lie algebra) template. Then, warped GM and WM segments were created. Modulation was applied in order to preserve the volume of a particular tissue within a voxel by multiplying voxel values in the segmented images by the Jacobian determinants derived from the spatial normalization step. In effect, the analysis of modulated data tests for regional differences in the absolute amount (volume) of GM. Images were smoothed with an FWHM (full-width at half maximum) kernel of 8 mm. Statistical analysis was carried out by means of whole brain between group t-tests on GM/WM volume maps. Age, sex and whole-brain volume were entered as covariates of no interest. The resulting maps were thresholded with  $p < 0.001$  and the statistical extent threshold was used to correct for multiple comparisons combined with a non-stationary smoothness correction based on permutation (Hayasaka, Phan, Liberzon, Worsley, & Nichols, 2004).

#### 2.5. Results

When comparing the two groups in whole-brain analyses in terms of grey matter and white matter volume, we found a significant difference in white matter volume. Acutely traumatized patients showed more white matter volume close to right inferior frontal gyrus (rIFG) cortex compared to healthy controls (Figure 1A). In line with the previous literature on

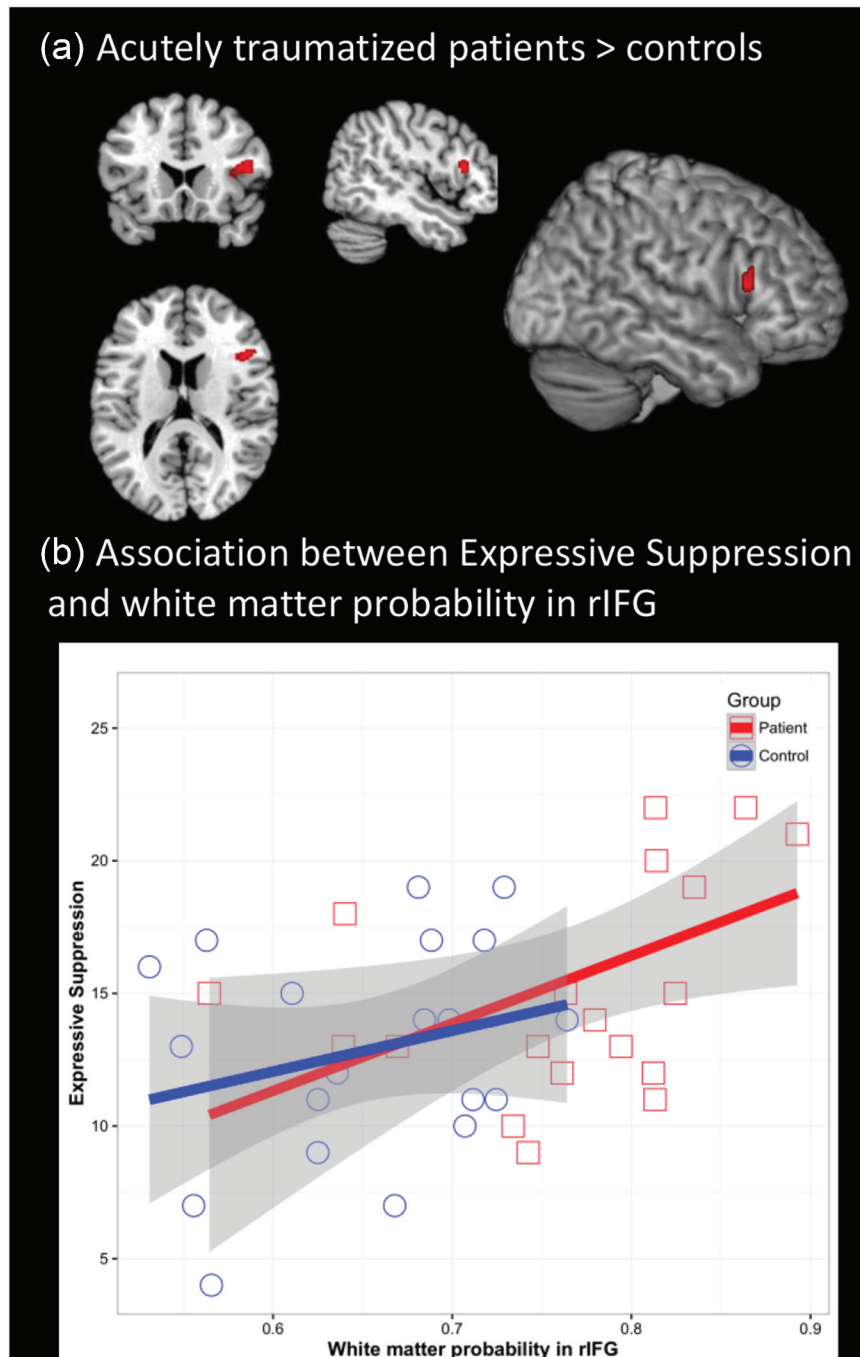
emotion regulation, the average white matter volume from that region was positively associated with expressive suppression ( $r(40) = 0.480$ ,  $p = 0.002$ , Figure 1B). The correlation remained significant when partialling out patient status ( $r(37) = 0.385$ ,  $p = 0.015$ ), as well as when partialling out patient status, age and sex ( $r(34) = 0.375$ ,  $p = 0.024$ ). We observed no significant differences in grey matter volume. We found a trend towards higher scores in recently traumatized patients (mean = 15.65 (SD = 4.64)) compared to healthy controls (mean = 12.85 (SD = 4.15)) in terms of their ERQ score in expressive suppression  $t(38) = 2.01$ ,  $p = .051$  but not in terms of their ERQ score in cognitive reappraisal  $t(38) = 1.65$ ,  $p = 0.107$ , with a mean score = 28.30 (SD = 6.34) for patients and a mean score = 25.25 (SD = 5.30) for healthy controls.

(B) Scatterplot illustrating the correlation between white matter volume and expressive suppression score from the emotion regulation questionnaire.

#### 2.6. Discussion

In a comparison of recently traumatized individuals with non-traumatized controls, we found a significant difference in white matter volume in the rIFG. Recently traumatized patients showed more white matter volume in the rIFG compared to healthy, non-traumatized controls. No significant differences for grey matter volume were found. Most interestingly, we found this white matter cluster in the ventrolateral prefrontal cortex to be positively correlated with habitual use of expressive suppression in our study, indicating that participants who are better able to hide their emotional expressions and use more frequently expressive suppression as an emotion regulation strategy show larger white matter volume in the rIFG. We found a trend towards higher scores of expressive suppression in recently traumatized patients compared to healthy controls. However, we found no significant difference between recently traumatized patients and healthy controls in terms of their ERQ score in cognitive reappraisal.

The association of increased white matter volume in the rIFG with habitual use of expressive suppression in trauma-exposed patients in our study fits well to previous research on functional activity of expressive suppression and associated structural changes in healthy individuals (Kühn et al., 2011; Vanderhasselt et al., 2013) and can be seen as supporting evidence that differences in the individuals’ use of emotion regulation strategies are relatively stable over time. Furthermore, our results suggest that using expressive suppression as an emotion regulation strategy does recruit similar brain regions as suppression of pre-potent behavioural responses and actions in response to a stimulus. The rIFG has previously been implicated in executive control, response inhibition, attentional control and suppression of emotional memories in functional paradigms (Aron, 2007; Aron,



**Figure 1.** (A) Brain region in right inferior frontal gyrus in which acutely traumatized patients show higher white matter volume than healthy controls (MNI coordinate:  $x = 47, y = 19, z = 13$ ).

Robbins, & Poldrack, 2004, 2014). Anatomically, the posterior and middle part of the IFG (pars opercularis and pars triangularis) were identified as two cortical terminations of the arcuate fasciculus (AF), a major white-matter bundle in the brain, by post-mortem fibre dissection and DTI tractography studies (Catani & Thiebaut de Schotten, 2008; Glasser & Rilling, 2008; Martino et al., 2013; Wang et al., 2015). The AF, as part of the superior longitudinal system (SLS), connects the IFG and the orbital gyri of the frontal lobe to temporal lobe cortices (Catani & Thiebaut de Schotten, 2008; Mandonnet, Sarubbo, & Petit, 2018). Long association fibres of the AF terminate in the IFG region (Catani,

Howard, Pajevic, & Jones, 2002) and contribute substantially to white matter in this region.

Our findings of increased volume in the rIFG of recently traumatized patients stand in contrast to previous findings of reduced functional activity and cortical thinning in inhibition-related regions in PTSD patients. PTSD has been commonly associated with impairments in executive functions (Olf, Polak, Witteveen, & Denys, 2014) and deficits in inhibitory control (Aupperle, Melrose, Stein, & Paulus, 2012; DeGutis et al., 2015). Reduced neural activity has been found in PTSD patients in regions associated with inhibitory control during Go/No-Go Tasks (Aupperle et al., 2012; Falconer et al.,

2008) and a reduced rIFG response has been reported in a stop-signal anticipation task (Van Rooij et al., 2014) in PTSD patients compared to controls. Furthermore, recent-onset PTSD was associated with cortical thinning in the rIFG and regional cortical thickness of rIFG was negatively associated with symptom severity in the same study (Liu et al., 2012). Yet, there is evidence that increased volume of the rIFG can be related to cognitive dysfunction in psychiatric disorders. Larger grey matter volume of the rIFG has been discussed as a biomarker of genetic risk for bipolar disorders (Drobinin et al., 2019; Hajek et al., 2013) and larger white matter volume in the vicinity of rIFG in patients with remitted geriatric depression was associated with executive function deficits in a study of Yuan et al. (2009). Interestingly, larger IFG volume was related to an increased number of early intrusive memories after experimental trauma exposure (trauma film paradigm) in healthy participants (Gvozdanoviz, Stämpfli, Seifritz, & Rasch, 2019).

Increased white matter volume close to rIFG cortex in our study may be interpreted as follows: it might reflect a compensatory response to pre-trauma inhibitory control deficits and/or pre-trauma emotion regulation difficulties that are compensated by increased recruitment of suppression-based emotion regulation strategies (Aupperle et al., 2012). Supporting evidence for pre-trauma cognitive control deficits comes from twin-studies, linking lower pre-trauma cognitive functioning to PTSD (Gilbertson et al., 2006). It might further be possible that pre-trauma emotion regulation difficulties impair the ability of trauma-exposed individuals to deal with an acute posttraumatic stress response in the aftermath of a traumatic event and lead to a reliance on avoidant coping strategies. Supporting evidence is provided by studies linking pre-trauma emotion regulation difficulties with PTSD symptoms (Badour & Feldner, 2013; Bardeen et al., 2013). Therefore, pre-trauma habitual use of expressive suppression and related structural characteristics might constitute a risk factor for the development of PTSD. Prospective studies with healthy participants showed that use of expressive suppression is associated with impaired social functioning and increased stress levels (Butler et al., 2003; Srivastava, Tamir, McGonigal, John, & Gross, 2009). Unfortunately, prospective studies relating pre-trauma use of expressive suppression and PTSD psychopathology after a potential traumatic event are lacking. Since we examined the participants in our study retrospectively, we cannot clarify whether anatomical differences in our study reflect a pre-existing condition or the result of increased emotion regulation in response to the traumatic event or both. Prospective studies examining inter-individual differences in the use of emotion regulation strategies and brain structure in relation to potentially traumatic events are needed to address this question more specifically.

As another option, it could be possible that inhibiting emotion expressive behaviour does require more recruitment of ventrolateral prefrontal regions in recently traumatized patients compared to healthy controls due to heightened levels of negative emotions in patients. Interestingly, enhanced task-related recruitment of regions associated with cognitive control and top-down attentional control has been observed in trauma-exposed individuals without PTSD relative to PTSD patients and healthy individuals (New et al., 2009), whereas PTSD patients showed deficits in recruiting the superior and inferior frontal cortex and parietal cortex (Blair et al., 2013). Blair et al. (2013) suggest that impaired ability to recruit cognitive control regions in PTSD could be driven by a stronger emotional response rather than reflecting a recruitment deficit.

The findings of this study have to be seen in light of some limitations. First, our results are based on a small sample size of 20 patients and 20 healthy controls due to the challenge of recruiting patients at an early state after trauma-exposure. With regard to small sample sizes, significant effects might represent an overestimation of the effect in the population (Button et al., 2013). Replication of the current findings is therefore critical, ideally with a larger sample size to increase statistical power. Second, patients were included by diagnoses that were taken from the medical record. Although diagnoses were made by trained trauma therapists according to the criteria of the International statistical classification of diseases and related health problems (ICD-10; World Health Organization, 2004), verification of diagnoses by standardized tools based on DSM-criteria (Clinician-Administered PTSD Scale (CAPS), Cwik and Woud (2015); Structured Clinical Interview for DSM-5 (SCID-5), First, Williams, Karg, & Spitzer, 2015) would significantly improve the quality of the study. Third, a trauma-exposed control group is lacking in our design. Future studies should include trauma-exposed controls and control for PTSD symptom severity.

In conclusion, our study indicates that habitual use of expressive suppression is associated with larger white matter volume close to right IFG cortex of recently traumatized patients compared to non-traumatized controls. Practical implications of our results might be specifically targeting and reducing the use of expressive suppression during PTSD treatment. Promising results have been observed in a study of Boden et al. (2013), where change in expressive suppression during treatment was predictive of PTSD symptom severity at treatment discharge in a sample of military veterans. However, further research is needed to better understand how white matter abnormalities may be associated with inhibitory control processes and maladaptive emotion regulation in the development and maintenance of PTSD.

## Disclosure statement

No potential conflict of interest was reported by the authors.

## Funding

This research did not receive any specific grant from funding agencies in the public, commercial, or not-for-profit sectors. The data that support the findings of this study are available on request from the corresponding author. The data are not publicly available due to privacy or ethical restrictions.

## ORCID

Simone Kühn  <http://orcid.org/0000-0001-6823-7969>

## References

- American Psychiatric Association. (2013). *Diagnostic and statistical manual of mental disorders*. (5<sup>th</sup> ed). Arlington, VA: American Psychiatric Association. doi: [10.1176/appi.books.9780890425596](https://doi.org/10.1176/appi.books.9780890425596)
- Aron, A. R. (2007). The neural basis of inhibition in cognitive control. *The Neuroscientist*, *13*(3), 214–228.
- Aron, A. R., Robbins, T. W., & Poldrack, R. A. (2004). Inhibition and the right inferior frontal cortex. *Trends in Cognitive Sciences*, *8*(4), 170–177.
- Aron, A. R., Robbins, T. W., & Poldrack, R. A. (2014). Inhibition and the right inferior frontal gyrus: One decade on. *Trends Cognitive Sciences* *8*(4), 177–185.
- Aupperle, R. L., Melrose, A. J., Stein, M. B., & Paulus, M. P. (2012). Executive function and PTSD: Disengaging from trauma. *Neuropharmacology*, *62*(2), 686–694.
- Badour, C. L., & Feldner, M. T. (2013). Trauma-related reactivity and regulation of emotion: Associations with posttraumatic stress symptoms. *Journal of Behavior Therapy and Experimental Psychiatry*, *44*(1), 69–76.
- Bardeen, J. R., Kumpula, M. J., & Orcutt, H. K. (2013). Emotion regulation difficulties as a prospective predictor of posttraumatic stress symptoms following a mass shooting. *Journal of Anxiety Disorders*, *27*(2), 188–196.
- Beck, A. T., Steer, R. A., & Brown, G. K. (1996). *Manual for the Beck depression inventory-II*. San Antonio, TX: Psychological Corporation.
- Blair, K. S., Vythilingam, M., Crowe, S. L., McCaffrey, D. E., Ng, P., Wu, C. C., & Blair, R. J. (2013). Cognitive control of attention is differentially affected in trauma-exposed individuals with and without post-traumatic stress disorder. *Psychological Medicine*, *43*(1), 85–95.
- Boden, M., Westermann, S., Mcrae, K., Kuo, J., Alvarez, J., Kulkarni, M. R., ... Bonn-Miller, M. O. (2013). Emotion regulation and posttraumatic stress disorder: A prospective investigation. *Journal of Social and Clinical Psychology*, *32*(3), 296–314.
- Butler, E. A., Egloff, B., Wilhelm, F. H., Smith, N. C., Erickson, E. A., & Gross, J. J. (2003). The social consequences of expressive suppression. *Emotion*, *3*(1), 48–67.
- Button, K. S., Ionnadis, J., Mokrysz, C., Nosek, B. A., Flint, J., Robinson, E., & Munafò, M. (2013). Power failure: Why small sample size undermines the reliability of neuroscience. *Nature Reviews Neuroscience*, *14*, 365–376.
- Catani, M., Howard, R. J., Pajevic, S., & Jones, D. K. (2002). Virtual in vivo interactive dissection of white matter fasciculi in the human brain. *Neuroimage*, *17*(1), 77–94.
- Catani, M., & Thiebaut de Schotten, M. (2008). A diffusion tensor imaging tractography atlas for virtual in vivo dissections. *Cortex*, *44*(8), 1105–1132.
- Chen, Y., Fu, K., Feng, C., Tang, L., Zhang, J., Huan, Y., ... Yin, H. (2012). Different regional grey matter loss in recent-onset PTSD and non PTSD after a single prolonged trauma exposure. *PLoS ONE*, *7*(11), e48298.
- Cwik, J. C., & Woud, M. L. (2015). German version of the clinician-administered PTSD scale for DSM-5 (CAPS-5). *Mental Health Research and Treatment Center Bochum*.
- DeGutis, J., Esterman, M., McCulloch, B., Rosenblatt, A., Milberg, W., & McGlinchey, R. (2015). Posttraumatic psychological symptoms are associated with reduced inhibitory control, not general executive dysfunction. *Journal of the International Neuropsychological Society*, *21*(5), 342–352.
- Drobinin, V., Slaney, C., Garnham, J., Propper, L., Uher, R., Alda, M., & Hajek, T. (2019). Larger right inferior frontal gyrus volume and surface area in participants at genetic risk for bipolar disorders. *Psychological Medicine*, *49*(8), 1308–1315.
- Ehlers, A., Steil, R., Winter, H., & Foa, E. B. (1996). *Deutsche Übersetzung der Posttraumatic Diagnostic Scale (PDS)*. Oxford: University, Warneford Hospital.
- Ehring, T., & Quack, D. (2010). Emotion regulation difficulties in trauma survivors: The role of trauma type and PTSD symptom severity. *Behavior Therapy*, *41*(4), 587–598.
- Falconer, E., Bryant, R., Felmingham, K. L., Kemp, A. H., Gordon, E., Peduto, A., ... Williams, L. M. (2008). The neural networks of inhibitory control in posttraumatic stress disorder. *Journal of Psychiatry & Neuroscience : JPN*, *33*(5), 413–422.
- Fani, N., King, T. Z., Jovanovic, T., Glover, E. M., Bradley, B., Choi, K., ... Ressler, K. J. (2012). White matter integrity in highly traumatized adults with and without Post-traumatic stress disorder. *Neuropharmacology*, *37*(12), 2740–2746.
- Fani, N., Michopoulos, V., vanRooij, S., Clendinen, C., Hardy, R. A., Jovanovic, T., ... Stevens, J. S. (2019). Structural connectivity and risk for anhedonia after trauma: A prospective study and replication. *Journal of Psychiatric Research*, *116*, 34–41.
- First, M. B., Williams, J. B. W., Karg, R. S., & Spitzer, R. L. (2015). *Structured clinical interview for DSM-5-research version (SCID-5 for DSM-5, research version; SCID-5-RV)*. Arlington, VA: American Psychiatric Association.
- Gilbertson, M. W., Paulus, L. A., Williston, S. K., Gurvits, T. V., Lasko, N. B., Pitman, R. K., & Orr, S. P. (2006). Neurocognitive function in monozygotic twins discordant for combat exposure: Relationship to post-traumatic stress disorder. *Journal of Abnormal Psychology*, *115*(3), 484–495.
- Giuliani, N. R., Drabant, E. M., & Gross, J. J. (2011b). Anterior cingulate cortex volume and emotion regulation: Is bigger better? *Biological Psychology*, *86*(3), 379–382.
- Glasser, M. F., & Rilling, J. K. (2008). DTI tractography of the human brain's language pathways. *Cerebral Cortex*, *18*(11), 2471–2482.
- Gross, J. J. (1998a). The emerging field of emotion regulation: An integrative review. *Review of General Psychology*, *2*(3), 271–299.
- Gross, J. J. (1998b). Antecedent- and response-focused emotion regulation: Divergent consequences for experience, expression and physiology. *Journal of Personality and Social Psychology*, *74*(1), 224–237.
- Gross, J. J., & John, O. P. (2003). Individual differences in two emotion regulation processes: Implications for

- affect, relationships and well-being. *Journal of Personality and Social Psychology*, 85(2), 348–362.
- Gross, J. J., & Levenson, R. W. (1993). Emotional suppression: Physiology, self-report, and expressive behaviour. *Journal of Personality and Social Psychology*, 115(3), 970–986.
- Gvozdanoviz, G., Stämpfli, P., Seifritz, E., & Rasch, B. (2019, March 2). Structural brain differences predict early traumatic memory processing. *Psychophysiology*, e13354. doi:10.1111/psyp
- Hajek, T., Cullis, J., Novak, T., Kopecek, M., Blagdon, R., Propper, L., & Stopkova, P. (2013). Brain structural signature of familial predisposition for bipolar disorder: Replicable evidence for involvement of the right inferior frontal gyrus. *Biological Psychiatry*, 73(2), 144–152.
- Hayasaka, S., Phan, K. L., Liberzon, I., Worsley, K. J., & Nichols, T. E. (2004). Nonstationary cluster-size inference with random field and permutation methods. *Neuroimage*, 22(2), 676–687.
- Hermann, A., Bieber, A., Keck, T., Vaitl, D., & Stark, R. (2014). Brain structural basis of cognitive reappraisal and expressive suppression. *Social Cognitive and Affective Neuroscience*, 9(9), 1435–1442.
- Karl, A., Schaefer, M., Loretta, S. M., Dörfel, D., Rohleder, N., & Werner, A. (2006). A meta-analysis of structural brain abnormalities in PTSD. *Neuroscience & Biobehavioral Reviews*, 30(7), 1004–1031.
- Kühn, S., Gallinat, J., & Brass, M. (2011). Keep calm and carry on: Structural correlates of expressive suppression of emotions. *PloS One*, 6(1), e16569.
- Li, L., Chen, S., Liu, J., Zhang, J., He, Z., & Lin, X. (2006). Magnetic resonance imaging and magnetic resonance spectroscopy study of deficits in hippocampal structure in fire victims with recent-onset posttraumatic stress disorder. *The Canadian Journal of Psychiatry*, 51(7), 431–437.
- Li, L., Lei, D., Li, L., Huang, X., Suo, X., Xiao, F., ... Gong, Q. (2016). White-matter abnormalities in post-traumatic stress disorder following a specific traumatic event. *EBioMedicine*, 4, 176–183.
- Li, L., Wu, M., Liao, Y., Ouyang, L., Du, M., & Lei, D. (2014). Grey matter reduction associated with posttraumatic stress disorder and traumatic stress. *Neuroscience & Biobehavioral Reviews*, 43, 163–172.
- Liu, Y., Li, Y.-J., Luo, E.-P., Lu, H.-B., & Yin, H. (2012). Cortical thinning in patients with recent onset post-traumatic stress disorder after a single prolonged trauma exposure. *PLoS One*, 7(6), e39025.
- Mandonnet, E., Sarubbo, S., & Petit, L. (2018). The nomenclature of human white matter association pathways: Proposal for a systematic taxonomic anatomical classification. *Frontiers in Neuroanatomy*, 12, 94.
- Martino, J., De Witt Hamer, P. C., Berger, M. S., Lawton, M. T., Arnold, C. M., Marco de Lucas, E., & Duffau, H. (2013). Analysis of the subcomponents and cortical terminations of the perisylvian superior longitudinal fasciculus: A fiber dissection and DTI tractography study. *Brain Structure & Function*, 218, 105–121.
- New, A. S., Fan, J., Murrrough, J. W., Liu, X., Liebmann, R. E., Guise, K. G., & Charney, D. S. (2009). A functional magnetic resonance imaging study of deliberate emotion regulation in resilience and posttraumatic stress disorder. *Biological Psychiatry*, 66(7), 656–664.
- Olf, M., Polak, A., Witteveen, A., & Denys, D. (2014). Executive function in posttraumatic stress disorder (PTSD) and the influence of comorbid depression. *Neurobiology of Learning and Memory*, 112, 114–121.
- Qi, S., Mu, Y., Liu, K., Zhang, J., Huan, Y., Tan, Q., ... Yin, H. (2013). Cortical inhibition deficits in recent onset PTSD after a single prolonged trauma exposure. *NeuroImage: Clinical*, 3, 226–233.
- Sheehan, D. V., Lecrubier, Y., Sheehan, K. H., Amorim, P., Janavas, J., Weiller, E., ... Dunbar, G. C. (1998). The mini-international neuropsychiatric interview (M.I.N.I.): The development and validation of a structured diagnostic psychiatric interview for DSM-IV and ICD-10. *The Journal of Clinical Psychiatry*, 59(Suppl 20), 22–33. qui 34–57.
- Shepherd, L., & Wild, J. (2014). Emotion regulation, physical arousal and PTSD symptoms in trauma-exposed individuals. *Journal of Behavior Therapy and Experimental Psychiatry*, 45(3), 360–367.
- Siehl, S., King, J. A., Burgess, N., Flor, H., & Nees, F. (2018). Structural white matter changes in adults and children with posttraumatic stress disorder. A systematic review and meta-analysis. *Neuroimage Clinical*, 19, 581–598.
- Srivastava, S., Tamir, M., McGonigal, K. M., John, O. P., & Gross, J. J. (2009). The social costs of emotional suppression: A prospective study of the transition to college. *Journal of Personality and Social Psychology*, 96(4), 883–897.
- Sui, S. G., Wu, M. X., King, M. E., Zhang, Y., Ling, L., Xu, Y. M., ... Li, L. J. (2010). Abnormal grey matter in victims of rape with PTSD in Mainland China: A voxel-based morphometry study. *Acta neuropsychiatrica*, 22(3), 118–126.
- Van Rooij, S. J. H., Rademaker, A., Kennis, M., Vink, M., Kahn, R. S., & Geuze, E. (2014). Impaired right inferior frontal gyrus response to contextual cues in male veterans with PTSD during response inhibition. *Journal of Psychiatry & Neuroscience*, 39(5), 330–338.
- Vanderhasselt, M. A., Kühn, S., & De Raedt, R. (2013). Put on your poker face: Neural systems supporting the anticipation for expressive suppression and cognitive reappraisal. *SCAN*, 8, 903–910.
- Wang, X., Pathak, S., Stefanescu, L., Yeh, F.-C., Li, S., & Fernandez-Miranda, J. C. (2015). Subcomponents and connectivity of the superior longitudinal fasciculus in the human brain. *Brain Structure and Function*, 221(4), 2075–2092.
- Wignall, E. L., Dickson, J. M., Vaughan, P., Farrow, T., Wilkinson, I. D., Hunter, M. D., & Woodruff, P. (2004). Smaller hippocampal volume in patients with recent-onset posttraumatic stress disorder. *Biological Psychiatry*, 56(11), 832–836.
- Woon, F. L., Sood, S., & Hedges, D. W. (2010). Hippocampal volume deficits associated with exposure to psychological trauma and posttraumatic stress disorder in adults: A meta-analysis. *Progress in Neuro-Psychopharmacology and Biological Psychiatry*, 34(7), 1181–1188.
- World Health Organization. (2004). *ICD-10: International statistical classification of diseases and related health problems: Tenth revision* (2nd ed.). Geneva: World Health Organization.
- Yuan, Y., Zhang, Z., Bai, F., Yu, H., You, J., Shi, Y., ... Jiang, T. (2009). Larger regional white matter volume is associated with executive function deficit in remitted geriatric depression: An optimized voxel-based morphometry study. *Journal of Affective Disorders*, 115(1–2), 225–229.
- Zhang, J., Tan, Q., Yin, H., Zhang, X., Huan, Y., Tang, L., ... Li, L. (2011). Decreased grey matter volume in the left hippocampus and bilateral calcarine cortex in coal mine flood disaster survivors with recent onset PTSD. *Psychiatry Research: Neuroimaging*, 192(2), 84–90.