



Case Report

Brain aspergilloma in an immunocompetent individual: A case report

João Ribeiro Memória Jr¹, Erlan Pércio Lopes Rufino², Pedro Lukas do Rêgo Aquino³, Francisco Vaz Guimarães Filho², Túlio Maranhão Neto¹, Herika Karla Negri Brito de Vasconcelos¹

¹Department of Neurosurgery, Hospital da Restauração, ²Department of Neurosurgery, Real Hospital Português de Beneficência em Pernambuco,

³Department of Medicine, Faculty of Medical Science, University of Pernambuco, Recife, Brazil.

E-mail: *João Ribeiro Memória - joaomemorianc@gmail.com; Erlan Pércio Lopes Rufino - erlanplr@hotmail.com; Pedro Lukas do Rêgo Aquino - pedrolukas7477@gmail.com; Francisco Vaz Guimarães Filho - drfranciscovaz@realneuro.com; Túlio Maranhão Neto - tmaranhaoneto@gmail.com; Herika Karla Negri Brito de Vasconcelos - hnegri@gmail.com



*Corresponding author:

João Ribeiro Memória Jr,
Department of Neurosurgery,
Hospital da Restauração, Av.
Gov. Agamenon Magalhães,
s/n - Derby, Recife - PE, Recife,
Pernambuco, Brazil.

joaomemorianc@gmail.com

Received : 28 May 2020

Accepted : 03 July 2020

Published : 25 July 2020

DOI

10.25259/SNI_321_2020

Quick Response Code:



ABSTRACT

Background: Aspergillosis is caused by fungi from the *Aspergillus* species, mainly *Aspergillus fumigatus*. Patients with aspergillosis typically have an underlying immunosuppression, and it is rare within the central nervous system (CNS) in an immunocompetent host. The mortality rate is as high as 90% if untreated, and the diagnosis is usually delayed due to nonspecific clinical presentation. This study described a case of CNS aspergillosis in an immunocompetent patient, through which we sought to discuss the current knowledge regarding brain *Aspergillus* focusing in the immunocompetent host.

Case Description: A 45-year-old male presented with 2 years of low-intensity headache and history of chronic sinusitis with epistaxis in the left nostril. Fifteen days before admission, he had high-intensity headache, episodes of transient aphasia, and seizure. Imaging showed a contrast-enhancing mass within the left maxillary sinus and another lesion in the left frontal lobe. The left frontal craniotomy was conducted, and complete resection was achieved. Biopsy identified *A. fumigatus*, and antifungal therapy was initiated. After 2 weeks, a new lesion was detected in the right frontal lobe, and the patient underwent a new procedure with complete lesion resection. Follow-up at 3 weeks did not reveal any evidence of residual or recurrent disease. The patient did not develop neurological complaints and was referred for resection of the remaining lesion by an otolaryngology team.

Conclusion: Being one of the few cases reporting a successful outcome for brain aspergilloma in an immunocompetent patient after complete surgical resection and amphotericin B and itraconazole therapy, we sought to reveal novel insight into brain aspergillosis.

Keywords: Aspergillosis, Central nervous system, Fungal infection, Immunocompetent host, Surgery

INTRODUCCION

Aspergillosis is caused by ubiquitous and saprophytic fungi of the *Aspergillus* species. The most common human pathogen is *Aspergillus fumigatus*.^[3,13] *Aspergillus* spores are airborne and inhaled by the host, entering into the respiratory system. In most cases, its pathogenicity is not high, and immunocompetent host infection is rare.^[11,14] Patients with aspergillosis typically have an underlying immunosuppression factor, including human immunodeficiency virus (HIV) and prolonged hospitalization.^[3,10,13,14] Aspergillosis within the central nervous system (CNS) is very

This is an open-access article distributed under the terms of the Creative Commons Attribution-Non Commercial-Share Alike 4.0 License, which allows others to remix, tweak, and build upon the work non-commercially, as long as the author is credited and the new creations are licensed under the identical terms.

©2020 Published by Scientific Scholar on behalf of Surgical Neurology International

rare in the immunocompetent host. The fungal may then gain access to the brain by direct spread from the paranasal sinuses or hematogenic pathways.^[10,13] In general, the mortality rate is as high as 90% if untreated. In most cases, the diagnosis is significantly delayed due to the nonspecific clinical presentation.^[9,13,18]

We reported a rare case of CNS aspergillosis in an immunocompetent patient, and this article sought to reveal the current knowledge regarding brain *Aspergillus* focusing on the immunocompetent host.

CASE REPORT

A 45-year-old male presented with 2 years of low-intensity headache and history of chronic sinusitis with epistaxis in the left nostril. Fifteen days before admission, he had high-intensity headache, episodes of transient aphasia, and seizure episodes. He was alert, afebrile, and hemodynamically stable, and his neurological examination was unremarkable. His personal history includes cocaine use and smoking. He did not have diabetes mellitus, HIV infection, or any previous chemotherapy or immunomodulatory therapies. There was no history of craniofacial trauma. There were not regular medications. Routine investigations, including full blood count, serum electrolytes, and C-reactive protein, were normal. A computed tomography (CT) demonstrated a hyperdense mass in the left frontal region. Magnetic resonance imaging (MRI) revealed a contrast-enhancing mass within the left maxillary sinus measuring $51 \times 30 \times 14$ mm [Figure 1a] and other lesions in left frontal lobe measuring $50 \times 45 \times 44$ mm in diameter, iso-to-hypointense in both T1-weighted and T2-weighted sequences, and demonstrated heterogeneous enhancement postgadolinium contrast administration [Figure 1b]. The patient underwent surgery. Through a left frontal craniotomy, lesion was approached, and complete resection was achieved. The biopsy was performed subsequently. The mass was brownish red, firm structure without necrosis, pigmentation, or hemorrhage [Figure 2]. Fungal cultures of the biopsy specimens later identified the growth of *A. fumigatus*, and we initiated on 70 mg/day (1 mg/kg) amphotericin-B deoxycholate. One week after starting therapy with amphotericin B deoxycholate, the patient developed renal failure, requiring the antifungal change. Then, oral itraconazole 400 mg/day was started and was observed improvement of renal function. CT scan at the immediate postoperative showed absent frontal lobe lesion. CT scan at the end of 2 weeks after operation showed a new lesion in the right frontal lobe [Figure 3]. The patient underwent a new surgical approach, and complete lesion resection was performed. The patient showed clinical improvement and followed outpatient treatment with itraconazole. Follow-up at 3 weeks did not reveal

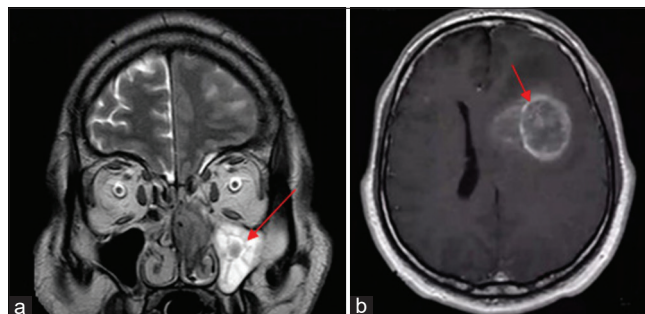


Figure 1: (a) Preoperative coronal T2-weighted magnetic resonance imaging image shows hypointense lesion in maxillary sinus measuring $51 \times 30 \times 14$ mm (red arrow). (b) Axial T1-weighted MRI image shows hypointense lesion in the left frontal lobe measuring $50 \times 45 \times 44$ mm in diameter (red arrow).

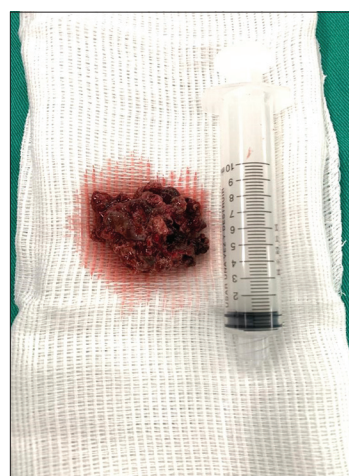


Figure 2: Surgical piece.

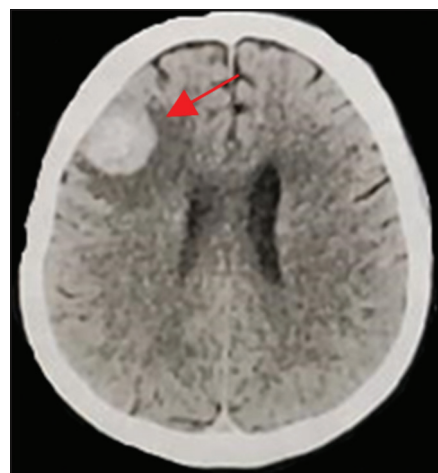


Figure 3: Computed tomography scan at the end of 2 weeks after operation showing a new lesion in the right frontal lobe (red arrow).

any evidence of residual or recurrent disease in CT scan [Figure 4], and the patient did not develop neurological

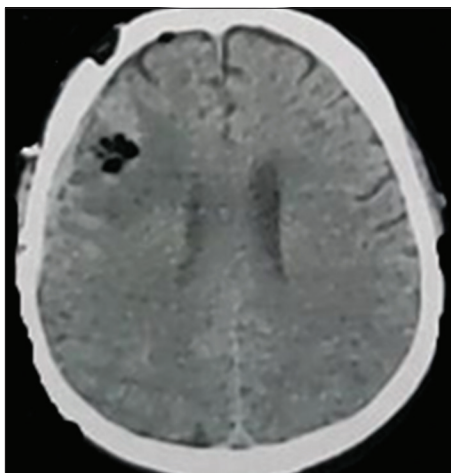


Figure 4: Three weeks after second resection did not reveal any evidence of residual or recurrent disease in computed tomography scan.

complaints. The patient was referred for surgical resection of the nasal lesion by an otolaryngology team after discharge from the neurosurgery.

DISCUSSION AND SHORT LITERATURE REVIEW

Physiopathology

CNS manifestations of intracranial aspergillosis include intracranial aneurysms, meningitis, infarction, hemorrhage, and space-occupying granulomas.^[21] The most common finding in an immunocompetent patient is a mass lesion with a thick irregular wall, which indicates a competent host defense mechanism that is attempting to encapsulate or isolate the offending organisms.^[16] Different from other cases of immunocompetent hosts presented in the literature, our patient had not diabetes mellitus, prolonged hospitalization, or malignant disease. However, in the present case, the patient had a history of cocaine use and smoking as possible predisposing factors for the development of nasal aspergillosis followed by spread to the brain.

Clinical features

The most common presentation of CNS aspergillosis includes meningitis, abscess, cerebritis, infarction, mycotic aneurysms, and granuloma.^[1] Space-occupying lesion as a clinical presentation is less common and happened in the present case.

Brain aspergillosis in immunocompetent hosts has been reported mainly from African countries.^[2,17] This prevalence in immunocompetent hosts is thought to be

related to tropical hot and undeveloped countries.^[2,16] The physiopathology causing invasiveness of aspergillosis in immunologically competent hosts remains poorly understood.^[11]

Clinical presentations are similar to those in neoplasms, making diagnosis problematic. The most common symptoms involved focal neurologic deficits, and it depends on the region affected.^[16] Convulsions, fever, hemiparesis, cranial nerve deficits, paralysis, and sensory impairment are common. Features of meningitis and subarachnoid hemorrhage resulting from mycotic aneurysms also have been reported in the literature.^[16] In our review focusing on immunocompetent host presented with space-occupying lesions, the most common symptom was headache.

Diagnosis

The clinical diagnosis is difficult to make because the presenting symptoms and signs are nonspecific. Radiologically, differential diagnosis can be made with abscess, brain tumor, tuberculosis, or hemorrhage. In our review, the most common differential diagnosis in the immunocompetent host was tuberculosis, following to brain tumor.^[6,8,13]

On CT scan, the lesion commonly appears hyperdense with calcification, and, in most of the cases, mass effect signs may be visualized.^[17]

MRI images show irregular space-occupying lesion from iso-to-hypointense. On T1 postgadolinium, there is a bright homogenous ring enhancement due to necrosis, fungal, and vascular involvement. Hypointensity on T2-weighted images is an important point in the aspergilloma diagnosis, indicating high concentrations of ferromagnetic elements, including iron, zinc, and magnesium – critical for fungal amino acid metabolism.^[3,8,17] The aspergilloma lesion appears as a small infarction and edema on diffusion-weighted imaging.^[9,14] In the present case, MRI showed iso-to-hypointense in both T1-weighted and T2-weighted sequences with heterogeneous enhancement postgadolinium contrast administration. The temporal lobe and frontal lobe are the areas most affected by aspergilloma in the brain.^[8]

The diagnosis can be confirmed only through histopathological examination or culture of biopsy the specimen.^[5] In our case, the biopsy specimen identified the growth of *A. fumigatus*.

Treatment and prognosis

Immune status is crucial to determine the clinical outcomes.^[4,12] Mortality remains high, and it ranges from 40 to 80% in immunocompetent hosts.^[19] Some authors recommend radical surgical excision followed by antifungal therapy.^[2,5,21] Voriconazole is the optimum drug to use

in aspergillosis since it has shown good penetration into the CNS in humans.^[7] Other drugs, such as itraconazole and amphotericin B, have been reported for effectiveness in intracranial aspergillosis.^[5,14,20] In our patient, surgical resection and oral itraconazole were successfully attempted. We chose amphotericin B due to the unavailability of voriconazole in our neurosurgery service. However, after the development of renal failure, amphotericin B was replaced by oral itraconazole. Patients with sinonasal disease and extradural aspergillosis showed to have a better prognosis between all patients. Some studies have shown better effectiveness when intracavitary antifungals are administered.^[5,14]

The biopsy may be performed through stereotactic or craniectomy. Stereotactic biopsy is associated with higher disease recurrence.^[22] The extension of lesion's resection is still controversial. Radical resection is related to lower mortality rates, but it is related to more complication numbers. However, no radical resection is associated with decreasing of neurological deficits, but higher mortality and recurrence of the disease rates.^[6,14] The postoperative period is extremely important to patient outcome. Postoperative complications include hydrocephalus, hyponatremia, seizures, and ischemic events.^[1,7,15]

CONCLUSION

To the best of our knowledge, this is one of the few cases reported of successful treatment of brain aspergilloma in an immunocompetent patient with amphotericin B and itraconazole after complete surgical resection. However, longer follow-up is needed. Our case illustrates the importance of radical surgical resection and antifungal therapy in the treatment of these cases. This article also sought to reveal novel insight into brain aspergillosis in immunocompetent hosts.

Declaration of patient consent

The authors certify that they have obtained all appropriate patient consent.

Financial support and sponsorship

Nil.

Conflicts of interest

There are no conflicts of interest.

REFERENCES

1. Ahmadzai H, Raley DA, Masters L, Davies M. An unusual case of a pituitary fossa aspergilloma in an immunocompetent

patient mimicking infiltrative tumour. *J Surg Case Rep* 2013;4:1-4.

2. Alahmari AF. Medical treatment of brain aspergilloma followed by MRI: A case report. *Radiol Case Rep* 2019;14:103-11.
3. Alrajhi AA, Enani M, Mahasin Z, Al-Omran K. Chronic invasive aspergillosis of the paranasal sinuses in immunocompetent hosts from Saudi Arabia. *Am J Trop Med Hyg* 2001;65:83-6.
4. Denning DW. Therapeutic outcome in invasive aspergillosis. *Clin Infect Dis* 1996;23:608-15.
5. Elgamal EA, Murshid WR. Intracavitary administration of amphotericin B in the treatment of cerebral aspergillosis in a non-immune-compromised patient: Case report and review of the literature. *Br J Neurosurg* 2000;14:137-41.
6. Ellenbogen JR, Waqar M, Cooke RP, Javadpour M. Management of granulomatous cerebral aspergillosis in immunocompetent adult patients: A review. *Br J Neurosurg* 2016;30:280-5.
7. Espinel-Ingroff A. *In vitro* fungicidal activities of voriconazole, itraconazole, and amphotericin B against opportunistic moniliaceous and dematiaceous fungi. *J Clin Microbiol* 2001;39:954-8.
8. Harris DE, Enterline DS. Neuroimaging of AIDS. I. Fungal infections of the central nervous system. *Neuroimaging Clin N Am* 1997;7:187-98.
9. Hussain S, Salahuddin N, Ahmad I, Salahuddin I, Joorna R. Rhinocerebral invasive mycosis: Occurrence in immunocompetent individuals. *Eur J Radiol* 1995;20:151-5.
10. Isselbacher KJ, Braunwald E, Wilson JD. In: Isselbacher KJ, Braunwald E, Wilson JD, editors. *Harrison's Principles of Internal Medicine*. 13th ed. New York: Mc Graw Hill; 1995. p. 855, 861-2.
11. Kim DG, Hong SC, Kim HJ, Chi JG, Han MH, Choi KS, et al. Cerebral aspergillosis in immunologically competent patients. *Surg Neurol* 1993;40:326-31.
12. Koshy R, Malhotra P. Treatment of primary aspergilloma of the central nervous system in a diabetic immunocompetent patient with surgical resection and voriconazole: A case report and review of the literature. *Turk Neurosurg* 2011;21:641-4.
13. Kumar D, Nepal P, Singh S, Ramanathan S, Khanna M, Sheoran R, et al. CNS aspergilloma mimicking tumors: Review of CNS aspergillus infection imaging characteristics in the immunocompetent population. *J Neuroradiol* 2018;45:169-76.
14. Nabika S, Kiya K, Satoh H, Mizoue T, Araki H, Oshita J. Local administration of amphotericin B against aspergilloma in the prepontine cistern-case report. *Neurol Med Chir* 2007;47:89-92.
15. Nadkarni TD, Desai KI, Muzumdar D. Ischaemic complications after surgical resection of intracranial aspergilloma. *J Clin Neurosci* 2003;10:500-2.
16. Sahip NB, Santral DB. Treatment of primary aspergilloma of the central nervous system in a diabetic immunocompetent patient with surgical resection and voriconazole: A case report and review of the literature. *Turk Neurosurg* 2011;21:641-4.
17. Scully EP, Baden LR, Katz JT. Fungal brain infections. *Curr Opin Neurol* 2008;21:347-52.
18. Segal BH. Aspergillosis. *N Engl J Med* 2009;360:1870-84.

19. Siddiqui AA, Shah AA, Bashir SH. Craniocerebral aspergillosis of sinonasal origin in immunocompetent patients: Clinical spectrum and outcome in 25 cases. *Neurosurgery* 2004;55:602-13.
20. Steinbach WJ, Stevens DA, Denning DA. Combination and sequential antifungal therapy for invasive aspergillosis: Review of published *in vitro* and *in vivo* interactions and 6281 clinical cases from 1966 to 2001. *Clin Infect Dis* 2003;37:188-224.
21. Xiao A, Jiang S, Liu Y, Deng K, You C. Invasive intracranial aspergillosis spread by the pterygopalatine fossa in an immunocompetent patient. *Braz J Infect Dis* 2012;16:192-5.
22. Yamada K, Shrier DA, Rubio A, Shan Y, Zoarski GH, Yoshiura T, *et al.* Imaging findings in intracranial aspergillosis. *Acad Radiol* 2002;9:163-71.

How to cite this article: Memória JR Jr., Rufino EP, Aquino PL, Filho FV, Neto TM, de Vasconcelos HK. Brain aspergilloma in an immunocompetent individual: A case report. *Surg Neurol Int* 2020;11:211.