



Received: 2015.10.23
Accepted: 2015.11.22
Published: 2016.06.19

Authors' Contribution:

- A** Study Design
- B** Data Collection
- C** Statistical Analysis
- D** Data Interpretation
- E** Manuscript Preparation
- F** Literature Search
- G** Funds Collection

Radiological Evaluation of Strategic Structures in Patients with Mild Cognitive Impairment and Early Alzheimer's Disease

Tomasz Nesteruk^{1,ABCDEF}, Marta Nesteruk^{2,DEF}, Maria Styczyńska^{3,8},
Maria Barcikowska-Kotowicz^{4,8}, Jerzy Walecki^{1,5,ACDF}

¹ Department of Diagnostic Radiology, Central Clinical Hospital of the Ministry of Interior in Warsaw, Warsaw, Poland

² Clinical Department of Neurology, Central Clinical Hospital of the Ministry of Interior in Warsaw, Warsaw, Poland

³ Institute of Experimental and Clinical Medicine, Polish Academy of Sciences, Warsaw, Poland

⁴ Department of Neurodegenerative Disorders, Mossakowski Medical Research Centre, Polish Academy of Sciences, Warsaw, Poland

⁵ Department of Experimental Pharmacology, Institute of Experimental and Clinical Medicine, Warsaw, Poland

Author's address: Tomasz Nesteruk, Department of Diagnostic Radiology, Central Clinical Hospital of the Ministry of Interior in Warsaw, Warsaw, Poland, e-mail: tnesteruk@vp.pl

Summary

Background:

The aim of the study was to evaluate the diagnostic value of two measurement techniques in patients with cognitive impairment – automated volumetry of the hippocampus, entorhinal cortex, parahippocampal gyrus, posterior cingulate gyrus, cortex of the temporal lobes and corpus callosum, and fractional anisotropy (FA) index measurement of the corpus callosum using diffusion tensor imaging.

Material/Methods:

A total number of 96 patients underwent magnetic resonance imaging study of the brain – 33 healthy controls (HC), 33 patients with diagnosed mild cognitive impairment (MCI) and 30 patients with Alzheimer's disease (AD) in early stage. The severity of the dementia was evaluated with neuropsychological test battery. The volumetric measurements were performed automatically using FreeSurfer imaging software. The measurements of FA index were performed manually using ROI (region of interest) tool.

Results:

The volumetric measurement of the temporal lobe cortex had the highest correct classification rate (68.7%), whereas the lowest was achieved with FA index measurement of the corpus callosum (51%).

The highest sensitivity and specificity in discriminating between the patients with MCI vs. early AD was achieved with the volumetric measurement of the corpus callosum – the values were 73% and 71%, respectively, and the correct classification rate was 72%.

The highest sensitivity and specificity in discriminating between HC and the patients with early AD was achieved with the volumetric measurement of the entorhinal cortex – the values were 94% and 100%, respectively, and the correct classification rate was 97%.

The highest sensitivity and specificity in discriminating between HC and the patients with MCI was achieved with the volumetric measurement of the temporal lobe cortex – the values were 90% and 93%, respectively, and the correct classification rate was 92%.

Conclusions:

The diagnostic value varied depending on the measurement technique. The volumetric measurement of the atrophy proved to be the best imaging biomarker, which allowed the distinction between the groups of patients. The volumetric assessment of the corpus callosum proved to be a useful tool in discriminating between the patients with MCI vs. early AD.

MeSH Keywords:

Alzheimer Disease • Magnetic Resonance Imaging • Mild Cognitive Impairment

PDF file:

<http://www.polradiol.com/abstract/index/idArt/896412>

Background

Due to a gradually extending lifespan, early diagnosing and treatment of dementia syndromes is becoming the object of increasing interest of numerous research centers and researchers all over the world. Aside from genetic testing and cerebrospinal fluid marker tests, the greatest hopes are associated with *in vivo* neuroimaging of the brain. It is a relatively fast and non-invasive technique. At present, the radiologists have at their disposal a wide range of imaging methods. These methods are not ideal, but they are still being improved and upgraded, and their accuracy is getting better each year.

Discriminating between the changes associated with physiological aging processes and those in the setting of pathological cerebral atrophy is of key importance.

Mild cognitive impairment (MCI) is a disease entity which is characterized by cognitive function decline in the degree which is inadequate for age or education, and it does not fulfill the criteria of diagnosing dementia syndrome. The greatest fear in this case is associated with the risk of conversion to Alzheimer's disease (AD). It is estimated that approximately 10–15% of the patients with MCI will progress to AD within the year [1–3]. The diagnosis of MCI using basic diagnostic imaging methods (computed tomography – CT, magnetic resonance – MR) is impossible, and their significance is usually limited to excluding other pathologies. However, along with technological progress and due to application of the new imaging and image processing methods, there are at present possibilities which (together with appropriate clinical data) allow to discriminate between the patients with MCI and with early AD, or healthy controls. These methods include i.a. amyloid imaging using PET (positron emission tomography), PET imaging with use of fluorodeoxyglucose (FDG), volumetry, diffusion weighted imaging and proton NMR spectroscopy.

Alzheimer's disease is the most common cause of dementia in people aged 65 years and over. It is estimated that even 21 million people all over the world can suffer from AD. In Poland the number is estimated to be around 500 000 [4].

Alzheimer's disease is a neurodegenerative disorder associated with accumulation of pathological proteins. This process leads to a gradual atrophy and degeneration of neurons, especially in temporal and parietal lobes, and partially in frontal lobes and posterior cingulate gyrus. Degenerative changes in AD are located mainly in the grey matter, affecting first of all the entorhinal cortex, hippocampus, amygdala, parahippocampal gyrus, and then the posterior cingulate gyrus and the cortex of the whole brain. AD is characterized by an insidious onset and patient's gradual decline of the cognitive functions, which leads to the loss of possibility of performing self-care. Thanks to new data from the metaanalyses it is known that many years pass between the beginning of the underlying pathological processes leading to Alzheimer's disease and the onset of the clinical symptoms. That is why it is of key importance to define the preclinical phase.

Since the beginning of using the brain diagnostic imaging techniques their role in diagnosing Alzheimer's disease has changed, starting from excluding other causes of cognitive impairment, such as tumors or chronic haematomas, through detecting on the basic structural images macroscopic changes in the brain distinctive for AD (such as e.g. atrophy), to a present function as a tool that would help to detect the moment of disease onset in the preclinical phase and allow to introduce an appropriate treatment in good time. Unfortunately among the wide variety of available neuroimaging methods there is no such technique that could serve all the purposes and meet all the requirements an ideal measurement technique should do, such as simultaneous macroscopic evaluation (i.e. quantitative measurement of the atrophy), microscopic assessment (i.e. assessment and quantification of the amount of pathological protein deposits within the brain), assessment of the nerve fibers, assessment of the chemical composition and functional assessment. Each of the methods has its benefits and drawbacks, which contribute to its usefulness or uselessness, depending on what the examiner wants to evaluate.

The aim of the study was the assessment of the diagnostic value of selected measurement methods used in neuroimaging of mild cognitive impairment and probable Alzheimer's disease in early stage, establishing the best imaging biomarkers and evaluation of the usefulness of the result classification methods.

Material and Methods

The study group consisted of 63 patients referred from Clinical Department of Neurology and Memory Impairment Outpatient Clinic of Central Clinical Hospital of the Ministry of Interior in Warsaw. They were divided into two groups based on the clinical diagnosis. The first group comprised 33 patients with mild cognitive impairment, and the second – 30 patients with clinical diagnosis of probable Alzheimer's disease in early stage.

In case of each patient the diagnosis was made based on the medical history, neurological examination, neuropsychological assessment, psychiatric assessment and additional tests.

The severity of the dementia was evaluated with GDS (global deterioration scale) and MMSE (mini mental state examination). The results of neuropsychological assessment were taken into account as well.

The control group consisted of 33 patients with no abnormalities detected in the brain MR study (performed due to other reasons, e.g. headaches), who achieved 28–30 score in MMSE.

The measurements were performed in strategic for Alzheimer's disease regions of the brain, using two methods.

The first method – fractional anisotropy index measurement in diffusion tensor imaging – allows to 'look into' the microstructure of the neurons, which gives hope to detect early degenerative changes distinctive for

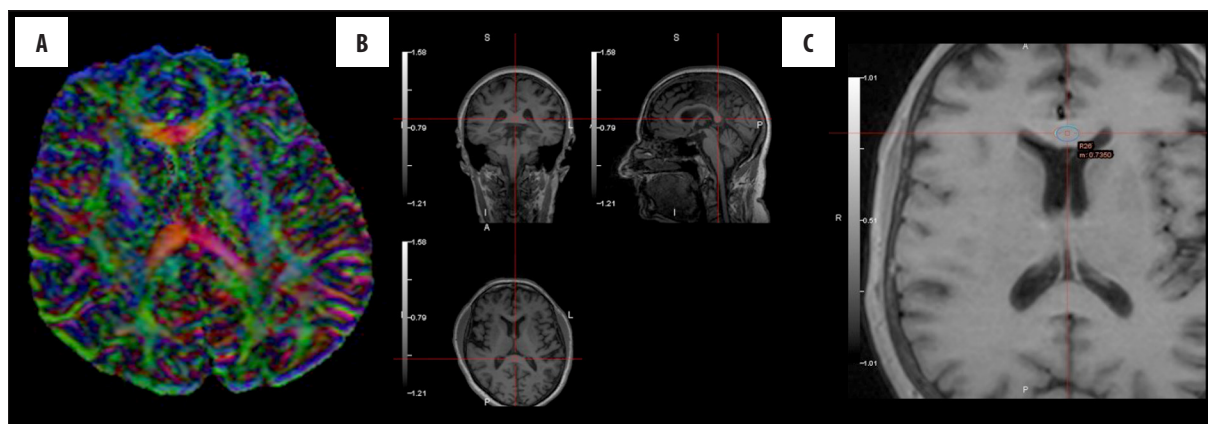

Figure 1. (A) A map of fractional anisotropy; (B, C) A way of putting ROI within the corpus callosum.

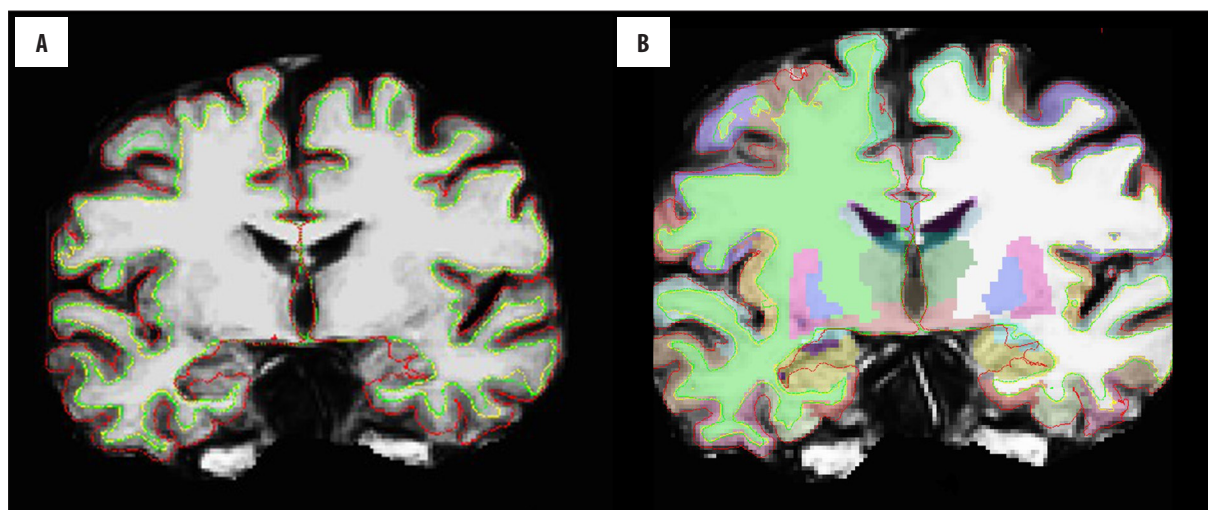


Figure 2. (A, B) Segmentation of the brain cortex and subcortical structures using FS software.

neurodegenerative process [5]. Diffusion tensor imaging is a method based on the model of the motion of water molecules, which is determined by the cell membranes, components of the cytoskeleton and myelin sheaths of the nerve axons – an anisotropic diffusion. This process can be observed more frequently in the regions with greater accumulation of axons, and because of that a quantitative and qualitative measurement of integrity of these fibers can be made [6,7].

The measurement of the fractional anisotropy index was performed at the workstation in Diagnostic Radiology Department of Central Clinical Hospital of the Ministry of Interior in Warsaw, using BrainMagix software, version 1.0-beta build 2247. BrainMagix is a neuroimaging software which can create maps of fractional anisotropy. FA measurements were performed manually (by one person) in all the patients in three parts of the corpus callosum (central parts of the genu, splenium and trunk) on axial images by marking the regions of interest (ROI) (Figure 1A–1C).

The second technique – volumetric measurement – was performed using FreeSurfer (FS) software – version 5.3 (<http://surfer.nmr.mgh.harvard.edu/>), which is widely available. It is composed of a set of automated tools (algorithms), which allow to obtain data about the brain and its

structures, including their volume. The software performs, among other things, a complete and automatic segmentation of the brain cortex and subcortical structures using so-called neuroanatomical labels assigned to each voxel in the given volume (Figure 2A, 2B).

The measured structures were: corpus callosum divided into five parts according to Hofer and Frahm scheme [8] and bilaterally the volume of the hippocampus, entorhinal cortex, parahippocampal gyrus, cortex of the temporal lobe and posterior cingulate gyrus (Figure 3A–3D). In order to eliminate the inter-subject variability in the brain size, obtained results were ‘normalized’ by dividing the measured volume by the total intracranial volume, which resulted in obtaining the absolute value.

Results

Table 1 shows the baseline characteristics of the study groups including age, sex and number of years of education.

The control group was characterized by the highest mean age, whereas the mean age of the patients in the AD group was slightly lower, and significantly lower in the MCI group. The most variable group in terms of age was the MCI group, whereas the least variable one was the control

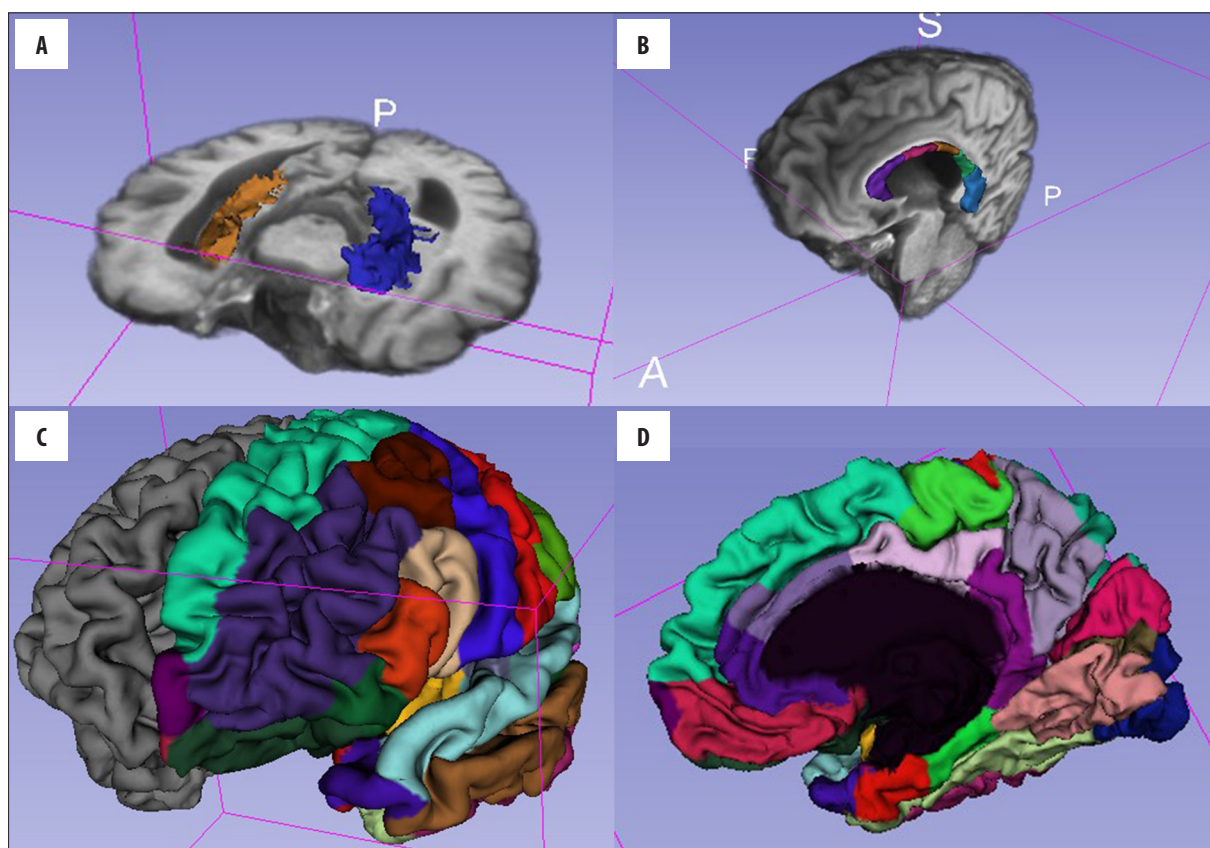


Figure 3. (A, B) Reconstruction of the hippocampi and the corpus callosum based on data obtained from FS using Slicer 3D software. (C, D) Parcellation of the brain cortex of the right hemisphere (a view from the external and internal side) based on data obtained from FS using Slicer 3D software.

Table 1. Baseline characteristics of the study groups.

	Control group	MCI	AD
Age (years)			
Mean	71.1	64.0	70.0
Standard error of the mean	0.8	1.5	1.2
Median	72.7	60.0	70.5
Range	19.1	25.0	25.0
Male percentage	48.5	39.4	43.3
Number of years of education			
Mean	16.2	14.7	14.7
Standard error of the mean	0.5	0.5	0.6
Median	16.0	14.0	14.0
Range	8.0	11.0	12.0

group. The control group was at the same time balanced in terms of sex.

The basic analysis of the results obtained from FA measurements of the genu and splenium of the corpus callosum showed decreasing mean values of the measurements along with disease progression. In case of trunk of the corpus

callosum the mean values were stable in each study group. During analysis of the volumetric measurements a decrease in the obtained values along with disease progression was observed in all the evaluated regions, except for the middle-posterior part of the corpus callosum, where the mean values were stable.

Table 2. Measurements correct classification rate.

Measurement	Correct classification rate (%)
FA of the corpus callosum	51.0
Volumetric of the corpus callosum	61.4
Volumetric of the hippocampus	54.1
Volumetric of the entorhinal cortex	63.5
Volumetric of the temporal lobe cortex	68.7
Volumetric of the parahippocampal gyri	63.5
Volumetric of the posterior cingulate gyrus	54.1

The measurements of all the measured regions of the corpus callosum using FA were considered altogether. The same procedure was performed in case of the volumetric measurement of the corpus callosum divided into five parts and the volumetric and linear measurements of bilateral brain structures.

Analysis of variance (ANOVA) showed statistical significance of the obtained results, with assumed significance level of 0.05, except for the measurement of the trunk of the corpus callosum using fractional anisotropy and the measurement of the middle-posterior part of the corpus callosum.

Moreover, an additional post-hoc least significant differences (LSD) test for ANOVA showed that the main source of differences between study groups are the differences between the control group and the patients with Alzheimer's disease. It applies to all the measurements, except for the fractional anisotropy measurement of the trunk of the corpus callosum and the volumetric measurement of the middle-posterior part of the corpus callosum, where no significant differences were observed between obtained results in the study groups. However, with assumption of the borderline significance at level 0.05, statistically significant results in discriminating between all study groups were obtained for volumetric measurements of the right hippocampus and the right entorhinal cortex.

After that, the effectiveness of the patient correct classification to respective groups was calculated, using each of the performed measurements, as shown in Table 2.

In the next stage the sensitivity and specificity of performed measurements were calculated, as well as the

Table 3. Measurement sensitivity, comparing the selected groups.

Sensitivity (%)	FA CC	Vol H	Vol ERC	Vol CC	Vol PHG	Vol PCG	Vol TTG
N vs. MCI	55	54	79	80	90	72	90
N vs. AD	75	72	94	70	80	80	88
MCI vs. AD	60	66	55	73	44	61	57

N – control group; H – hippocampus; PHG – parahippocampal gyrus; ERC – entorhinal cortex; FA – fractional anisotropy measurement; Vol – volumetric measurement; PCG – posterior cingulate gyrus; CC – corpus callosum; TTG – total volume of the cortex of the temporal lobes.

Table 4. Measurement specificity, comparing the selected groups.

Specificity (%)	FA CC	Vol H	Vol ERC	Vol CC	Vol PHG	Vol PCG	Vol TTG
N vs. MCI	82	74	91	78	90	79	93
N vs. AD	65	92	100	81	96	85	96
MCI vs. AD	71	59	51	71	64	46	64

N – control group; H – hippocampus; PHG – parahippocampal gyrus; ERC – entorhinal cortex; FA – fractional anisotropy measurement; Vol – volumetric measurement; PCG – posterior cingulate gyrus; CC – corpus callosum; TTG – total volume of the cortex of the temporal lobes.

Table 5. Measurement correct classification, comparing the selected groups.

Classification (%)	FA CC	Vol H	Vol ERC	Vol CC	Vol PHG	Vol PCG	Vol TTG
N vs. MCI	68	65	86	79	90	76	92
N vs. AD	69	82	97	76	91	82	93
MCI vs. AD	65	63	53	72	55	53	61

N – control group; H – hippocampus; PHG – parahippocampal gyrus; ERC – entorhinal cortex; FA – fractional anisotropy measurement; Vol – volumetric measurement; PCG – posterior cingulate gyrus; CC – corpus callosum; TTG – total volume of the cortex of the temporal lobes.

Table 6. Classification results comparing the selected groups.

Measurement	Correct classification rate (%)
FA of the corpus callosum	51.0
Volumetric of the temporal lobe cortex	68.7
Volumetric of the hippocampi, entorhinal cortex and corpus callosum	75.0
All volumetric	83.3
FA of the corpus callosum + all volumetric	85.4

effectiveness of the classification in discriminating between the respective groups of patients (Tables 3–5).

Due to obtaining unsatisfactory results assessing the correct classification of the patients to respective clinical subgroups based on the measurement of the given structure (range 47.9–68.7%), it was decided to use the groups of the various measurements. The results of the predictions with use of the linear discriminant analysis for the respective measurement groups showed that the most optimal group would comprise the volumetric measurements (with use of the values for all the examined structures) with effectiveness index at a level of 83.3% (Table 6).

Discussion

The aim of performing several measurements and using two different techniques was to establish optimal measurements/measurement sets, which could be used in daily medical practice in radiological diagnosis of Alzheimer's disease and preceding stages of dementia (including MCI).

The utility of the used tools varied depending on the measurement technique. The highest effectiveness of the classification was achieved in the bilateral volumetric measurements of the gyri of temporal lobe cortex (68.7%). The measurement of fractional anisotropy index in three parts of the corpus callosum – the genu, trunk and splenium – has not met the expectations, and the correct classifications rate was 51%. However, it is worth noting that the correct classification rate in discriminating between MCI and AD (it is at present the most important differentiation from the clinical point of view) was 65% and was just slightly inferior to the measurement of the corpus callosum volume, for which the effectiveness of the correct discrimination between these two diseases was 72%, with a sensitivity of 73% and a specificity of 71%. It is the first report stating that the volumetry of the corpus callosum is the most sensitive indicator discriminating between MCI and AD. In the previous studies (most often evaluating single structures or respective structures of the medial part of the temporal lobe) the most useful parameter was the entorhinal cortex [9,10] or the hippocampus [11]. In our study the measurement of the hippocampus volume had a sensitivity of 66% in discriminating between MCI vs. AD (the second most sensitive volumetric measurement after the volume of the corpus callosum).

The highest sensitivity and specificity in discriminating between the patients from the control group and the patients with Alzheimer's disease in early stage was achieved using the volumetric measurement of the entorhinal cortex, as in Jauhiainen study, whereas in Pennanen study a superior parameter in discriminating between the patients proved to be the volumetric measurement of the hippocampus. The highest sensitivity and specificity in discriminating between the patients from the control group and the patients with MCI was achieved with the volumetric measurement of the temporal lobe cortex, unlike in the studies cited above, where the measurement of the entorhinal cortex proved to be the best parameter.

The combination of the volumetric measurements increased the sensitivity of the correct classification to 83.3% (from 68.7% for the measurement of the temporal lobe volume), and adding the fractional anisotropy measurement to the set of the volumetric measurements increased the correct classification rate to 85.4%. Despite the better value which was a result of taking into consideration two measurement techniques, it seems that using the set of the volumetric measurements is optimal as with use of FS software they are performed simultaneously. This means that the time spent on performing one volumetric measurement equals the time spent on performing several measurements. In analysing the combinations of the measurements, for example the part of the volumetric measurements and FA measurements, the time and effort allocated for the evaluation of a given patient would increase significantly, which would put into question the effectiveness of performing certain analyses. It should also be emphasized that volumetric measurements are automated unlike FA measurements. Unfortunately, automated volumetric measurements are still not accurate enough, which is confirmed by the discrepancies between the results obtained by our team and the authors cited above (the measurements were performed mainly manually or in a semi-automated way). It should be noted, however, that the measurements are still being upgraded and their accuracy is higher each year, which gives hope to achieve a greater accuracy in comparison with the manual methods (which at present remain the 'golden standard', but require much time) in the nearest future.

Conclusions

The highest classification effectiveness was obtained for temporal grey mater volume on both sides. Measurement of fractional anisotropy value within the parts of the corpus callosum was not effective.

The highest sensitiveness and specificity in distinguishing between patients with MCI and patients with possible AD at an early stage was achieved with the volumetric measurement of the corpus callosum.

The combined use of volumetric measurements of the studied structures showed high effectiveness of the correct classification.

The strongest imaging biomarker used to differentiate various disease entities was assessment of the volume loss.

References:

1. Daly E, Zaitchik D, Copeland M et al: Predicting conversion to Alzheimer disease using standardized clinical information. *Arch Neurol*, 2000; 57: 675–80
2. Morris JC, Storandt M, Miller JM et al: Mild cognitive impairment represents early stage Alzheimer's disease. *Arch Neurol*, 2001; 58: 397–405
3. Petersen RC, Doody R, Kurz A et al: Current concepts in mild cognitive impairment. *Arch Neurol*, 2001; 58: 1985–92
4. Jack CR Jr, Albert MS, Knopman DS et al: Introduction to the recommendations from the National Institute on Aging-Alzheimer's Association workgroups on diagnostic guidelines for Alzheimer's disease. *Alzheimers Dement*, 2011; 7(3): 257–62
5. Walecki J, Skarżyński H, Szary C (eds.): *Obrazowanie szlaków istoty białej mózgowia: od morfologii do patologii*. 2012 [in Polish]
6. Parente DB, Gasparetto EL, da Cruz LC Jr et al: Potential role of diffusion tensor MRI in the differential diagnosis of mild cognitive impairment and Alzheimer's disease. *Am J Roentgenol*, 2008; 190(5): 1369–74
7. Walecki J, Bulski T, Sklinda K: Choroby naczyniopochodne ośrodkowego układu nerwowego. In: Walecki J (ed.), *„Postępy neuroradiologii”*; 2007; 472–512 [in Polish]
8. Hofer S, Frahm J: Topography of the human corpus callosum revisited – comprehensive fiber tractography using diffusion tensor magnetic resonance imaging. *Neuroimage*, 2006; 32(3): 989–94
9. Jauhiainen AM, Pihlajamäki M, Tervo S et al: Discriminating accuracy of medial temporal lobe volumetry and fMRI in mild cognitive impairment. *Hippocampus*, 2009; 19(2): 166–75
10. Pedro T, Weiler M, Yasuda CL et al: Volumetric brain changes in thalamus, corpus callosum and medial temporal structures: Mild Alzheimer's disease compared with amnesic mild cognitive. *Dement Geriatr Cogn Disord*, 2012; 34(3–4): 149–55
11. Pennanen, Kivipelto M, Tuomainen S et al: Hippocampus and entorhinal cortex in mild cognitive impairment and early AD. *Neurobiol Aging*, 2004; 25(3): 303–10