

# Dissecting intracranial aneurysm in pregnancy: A rare association

Manasi Mehrotra, Anant Mehrotra<sup>1</sup>, Anup Nair<sup>1</sup>, Arun Srivastava<sup>1</sup>, Rabi Narayan Sahu<sup>1</sup>, Mandakini Pradhan, Raj Kumar<sup>1</sup>

Departments of Maternal and Reproductive Health and <sup>1</sup>Neurosurgery, Sanjay Gandhi Postgraduate Institute of Medical Sciences, Raebareli Road, Lucknow, Uttar Pradesh, India

## ABSTRACT

We report a case of dissecting aneurysm of the right posterior cerebral artery presenting with sudden onset headache and altered behavior during labor. A 26-year-old P1001 with uncomplicated antenatal period, except history of headache off and on since 32 weeks of pregnancy, developed sudden onset headache and altered behavior during 3<sup>rd</sup> stage of labor. She had vaginal delivery and a live born male baby was delivered with good Apgar score. The CT was suggestive of subarachnoid hemorrhage and DSA was suggestive of dissecting aneurysm of the right P2 segment with hypoplasia of right P1 segment and A1 segment of posterior and anterior cerebral artery, respectively. The patient was managed conservatively. At 4-month follow-up, the patient was doing well. We discuss about the rare association of a dissecting aneurysm and pregnancy, especially dissection of the posterior cerebral artery.

**Key words:** Pregnancy, dissecting aneurysm, sub-arachnoid haemorrhage

## Introduction

Intracranial hemorrhage from aneurysms and arteriovenous malformations during pregnancy and puerperium have been reported and although these lesions are rare but account for a substantial number of maternal deaths. Intracranial hemorrhage (ICH) (subarachnoid and/or intraparenchymal) is a rare occurrence during pregnancy with incidence reported to be 0.01% to 0.05% of all pregnancies.<sup>[1]</sup> Despite being such a rare occurrence, it accounts for 5 to 12% of maternal deaths during pregnancy.<sup>[1]</sup> Dissecting intracranial aneurysm associated with pregnancy is extremely rare. Dissection of the posterior cerebral artery is even rarer and its association with pregnancy has been reported only in 3 more cases in English literature. In our case, the site of dissection of the posterior cerebral artery (P2) segment

and the occurrence of the dissection during labor has not been reported till date, as all the 3 cases reported were in the post-partum period.

## Case Report

We present a case of a 26-year-old P1001 who presented to our emergency ward at 12 hours post-partum with complaints of sudden-onset severe holocranial headache followed by altered behavior for one day. She had an uncomplicated antenatal period except history of headache off and on since 32 weeks of pregnancy. Throughout her pregnancy, she was normotensive and never had any seizure. She went into spontaneous labor at term. Total duration of labor was eight hours. She had vaginal delivery and a live born male baby was delivered with good Apgar score. However, immediately following delivery, during 3<sup>rd</sup> stage of labor, she developed severe headache and altered behavior for which she was referred to our center. At time of presentation, she was conscious, oriented, and had no cranial nerve or sensory or motor deficit. She was diagnosed as case of

This is an open access article distributed under the terms of the Creative Commons Attribution-NonCommercial-ShareAlike 3.0 License, which allows others to remix, tweak, and build upon the work non-commercially, as long as the author is credited and the new creations are licensed under the identical terms.

**For reprints contact:** reprints@medknow.com

Access this article online	
<b>Quick Response Code:</b> 	<b>Website:</b> <a href="http://www.asianjns.org">www.asianjns.org</a>
	<b>DOI:</b> 10.4103/1793-5482.150224

## Address for correspondence:

Dr. Mandakini Pradhan, Department of Maternal and Reproductive Health, Sanjay Gandhi Postgraduate Institute of Medical Sciences, Rae Bareli Road, Lucknow - 226 014, Uttar Pradesh, India.  
E-mail: mandakini\_pradhan@rediffmail.com

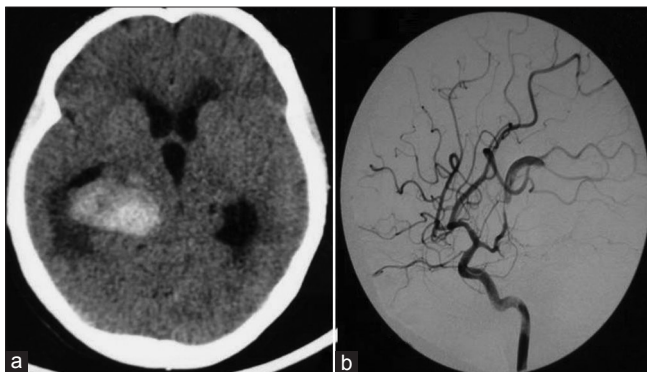
**How to cite this article:** Mehrotra M, Mehrotra A, Nair A, Srivastava A, Sahu RN, Pradhan M, *et al.* Dissecting intracranial aneurysm in pregnancy: A rare association. Asian J Neurosurg 2017;12:127-30.

subarachnoid hemorrhage (SAH) on the basis of Computerized Tomography (CT). A Digital Subtraction Angiography (DSA) was done which showed a dissecting aneurysm of posterior cerebral artery (second segment) (PCA) on the right side with hypoplasia of right P1 (first segment) of PCA and right A1 (first segment) of anterior cerebral artery (ACA) [Figure 1]. Patient and relatives were explained about the need for surgical procedure and risk of rebleed and they opted for conservative management. On last follow-up (4 months after discharge), she was doing fine.

## Discussion

Dissections in the intracranial arteries most often involve the vertebral and basilar arteries<sup>[1]</sup> with dissections in the intracranial carotid and middle cerebral artery occurring rarely. PCA dissections are extremely uncommon.<sup>[2-7]</sup>

Although intracranial hemorrhage from aneurysms and arteriovenous malformations during pregnancy and puerperium have been reported, but to the best of our knowledge, only 3 cases of dissecting intracranial aneurysm associated with pregnancy have been reported. One was



**Figure 1:** (a) CT showing intraparenchymal bleed; (b) DSA showing dissection in the right PCA

dissection of the basilar artery, another of the superior cerebellar artery, and one was of the PCA<sup>[8-10]</sup> [Table 1]. Our case is only the second case of PCA dissecting aneurysm associated with pregnancy. The case previously reported had dissection at P3/P4 segment and was in the post-partum period. In our case, the dissection was at the P2 segment and is probably the first case to be reported with dissection occurring during labor.

## Etiopathogenesis

Intracranial dissecting aneurysms have been associated with trauma, migraine, oral contraceptive use, syphilis, polyarteritis nodosa, fibro muscular dysplasia, and mucoid degeneration of the media<sup>[8]</sup>. Dissection might be initiated in the presence of internal elastic lamina defect in the wall of the artery, particularly if medical comorbidities are present<sup>[8]</sup>. P1-P2 junction lies close to the free border of the tentorium and it is the most common site of PCA dissections.<sup>[10]</sup> Dissections may occur in mild head trauma secondary to a stretch or shear injury of the vessels.

Dissecting aneurysms involving the intracranial peripheral arteries predominantly occur in younger patients, in whom no underlying abnormalities are present in most cases to explain the dissection of an artery. In our case, the cause of the PCA dissection was unclear, but probably a congenital wall defect or acquired angiopathy was present triggered by an initiating factor, such as the hemodynamic changes that occur during pregnancy and hemodynamic stress brought on by hypertension occurring during labor and delivery,<sup>[10]</sup> or other physiological changes, such as elevation of progesterone and human chorionic gonadotropin and secretion of relaxin.<sup>[11]</sup> Reports of aneurysmal SAH in pregnancy relate it to the physiological changes, such as pregnancy-induced degeneration of collagen; hyperplasia of the arterial intima; smooth muscle proliferation and alteration in the protein and acid mucopolysaccharide content of media; hemorrhage from the vasa vasorum

**Table 1: Dissecting intracranial aneurysms associated with pregnancy**

Author	Artery involved	Period of pregnancy	Presentation	Radiology	Management
Kelft EV <sup>[8]</sup>	Basilar artery	4 hours after labor (Vaginal delivery)	Brainstem ischemia	CT-Normal MRI-ischemic lesions of the right thalamus, posterior limb of internal capsule and occipital lobe DSA-a dissecting aneurysm of the basilar artery, a thrombosis of the intracranial segment of the right vertebral artery proximal to and at the origin of the right posterior inferior cerebellar artery	Conservative
Ikeda K <sup>[9]</sup>	Right SCA	Caesarian section; symptoms 1 day after delivery	1 <sup>st</sup> episode-Headache and loss of consciousness 2 <sup>nd</sup> episode-deep coma	CT-SAH, primarily in the suprasellar, prepontine, and right ambient cisterns DSA-fusiform dilatation of the right superior cerebellar artery (SCA) with distal luminal narrowing	Clipping and wrapping
Inoue T <sup>[10]</sup>	Left PCA	6 days postpartum	Sudden onset of headache, vomiting, and unconsciousness	CT-SAH DSA-fusiform dilatation of the left PCA (P3/P4 segment)	Conservative
Present case	Right PCA	During labor	Sudden onset of headache, vomiting and altered behavior	CT-Intraparenchymal bleed involving the right posterior thalamic and temporoparietal region DSA-right P2 segment Dissecting aneurysm	Conservative

into the outer third of tunica media; altered prostaglandin metabolism; and the secretion of relaxin.<sup>[12-14]</sup> All these factors can lead to changes in the vessel wall and its integrity and hence lead to dissection.

### Clinical presentation

Vertebrobasilar dissections have a male preponderance, whereas isolated PCA dissections are predominant in females, with a female-male ratio of 3.1:115. Intracranial arterial dissections typically occur in the late third to fifth decade.

SAH and posterior circulation ischemia are the two major clinical presentations. Posterior fossa mass effect is rare.<sup>[15]</sup> The most common initial symptom of vertebrobasilar dissection is headache.<sup>[16]</sup> Pain is the most constant symptom of dissection and is usually in the occipital and posterior cervical regions. PCA dissection is variably described as an unusual sensation in the head or as a pop or snap. This is usually closely followed by discomfort and aching that is localized to the occiput on the side of the dissection.<sup>[15]</sup> Rapidly evolving brain stem dysfunction is the most common clinical presentation.<sup>[17]</sup> Isolated PCA dissections more commonly present with ischemic symptoms and have a more benign clinical course and prognosis.<sup>[18]</sup>

### Radiological appearances

The string sign of occlusion, rosette, intimal flap, proximal and/or distal dilatation, double lumen, retention of contrast medium in the late venous phase, and intramural pooling of the contrast are the angiographic features suggestive of dissection. The double lumen (true lumen and subintimal false lumen) is the sole pathognomonic sign of a dissecting aneurysm.<sup>[19]</sup>

### Management

Treatment of intracranial dissections is controversial. The options include surgery, endovascular techniques, and conservative management.<sup>[20-22]</sup> Ischemia can be countered by augmenting blood volume and blood pressure, which might increase perfusion to the ischemic area through collateral vessels. However, if thrombus formation is the main underlying component, anticoagulation (heparin/warfarin) could theoretically prevent thrombus formation and embolization. The other mode of presentation is rupture causing severe parenchymatous and/or SAH. Thus, whether to initiate anticoagulation should be individualized on the basis of the clinical mode of presentation.

The indications for surgical treatment of the dissecting aneurysms remain controversial. In view of high rate of recurrent hemorrhage and the extremely poor outcome in patients with ruptured dissecting aneurysm of the posterior circulation, endovascular/surgical treatment is recommended. However, spontaneous evolution of a dissecting aneurysm of the PCA and similar results in the vertebrobasilar system

indicate the need for conservative management in the absence of neurological deterioration. However, if there is recurrent SAH or angiographic progression of the dissection, surgical intervention might be indicated. In neurologically stable patients who present with ischemia or no recurrent hemorrhage, conservative management might be a better option.<sup>[9]</sup> In our case, patient had bled and there was risk of further rebleed and as the compliance was doubtful, surgery was advised (endovascular was also advised, but she was not willing for either). At 4-month follow-up, the patient was asymptomatic for the aneurysm and was doing well. Follow-up radiology was not advised as the patient was asymptomatic.

Endovascular techniques have been reported in the literature as a treatment modality for dissecting intracranial aneurysms. The endovascular techniques include either a reconstructive technique (stenting with or without coiling) or deconstructive techniques (proximal occlusion or internal trapping of the parent artery).<sup>[23-25]</sup> However, with the endovascular techniques, recurrence of up to 13% have been reported for vertebral artery dissecting aneurysms.<sup>[23]</sup> Surgical treatment of dissecting aneurysms includes excision, trapping, proximal ligation, and reinforcement with or without intracranial extracranial bypass, but the optimal surgical procedure has not yet been established. Thus, it appears that the treatment needs to be individualized.

### Conclusion

Intracranial hemorrhage in pregnancy is rare but is associated with high rate of mortality/morbidity. ICH can be because of various causes including aneurysms. Dissecting aneurysms in association with pregnancy have been rarely reported in literature. All dissecting aneurysms in association with pregnancy have been reported in posterior circulation only. They can present with either bleed or ischemic symptoms. Treatment is controversial and includes conservative or surgical/endovascular options and needs to be individualized.

### Financial support and sponsorship

Nil.

### Conflicts of interest

There are no conflicts of interest.

### References

1. Dias MS, Sekhar LN. Intracranial hemorrhage from aneurysms and arteriovenous malformations during pregnancy and the puerperium. *Neurosurgery* 1990;27:855-66.
2. Caplan LR. *Posterior Circulation Disease: Clinical Findings, Diagnosis, and Management*. Boston, Mass: Blackwell Science; 1996.
3. Berger MS, Wilson CB. Intracranial dissecting aneurysms of the posterior circulation. *J Neurosurg* 1984;61:882-94.
4. Sasaki O, Koizumi T, Ito Y, Sorimachi T, Koike T, Tanaka R. Dissecting aneurysm of the posterior cerebral artery treated with proximal ligation. *Surg Neurol* 1992;37:394-401.
5. Pozzati E, Padovani R, Fabrizi A, Sabatini L, Gaist G. Benign arterial

- dissections of the posterior circulation. *J Neurosurg* 1991;75:69-72.
6. Pozzati E, Andreoli A, Limoni P, Casmiro M. Dissecting aneurysms of the vertebrobasilar system: Study of 16 cases. *Surg Neurol* 1994;41:119-24.
  7. Maillou A, Diaz P, Morales F. Dissecting aneurysm of the posterior cerebral artery: Spontaneous resolution. *Neurosurgery* 1991;29:291-4.
  8. Kelft EV, Kunnen J, Truyen L, Heytens L. Postpartum dissecting aneurysm of the basilar artery. *Stroke* 1992;23:114-6.
  9. Ikeda K, Shoin K, Taguchi H, Yamano J, Kawahara R. Postpartum Dissecting Aneurysm of the Superior Cerebellar Artery. *Neurol Med Chir (Tokyo)* 1999;39:852-7.
  10. Inoue T, Nishimura S, Hayashi N, Numagami Y, Takazawa H, Nishijima M. Postpartum dissecting aneurysm of the posterior cerebral artery. *J Clin Neuro* 2007;14:576-81.
  11. Robinson JL, Hall CJ, Sedzimir CB. Subarachnoid hemorrhage in pregnancy. *J Neurosurg* 1972;36:27-33.
  12. Adams HP Jr, Aschenbrener CA, Kassel NF, Ansbacheret L, Cornell SH. Intracranial hemorrhage produced by spontaneous dissecting intracranial aneurysm. *Arch Neurol* 1982;39:773-5.
  13. Barret J, Van Hooydonk JE, Boehm FH. Pregnancy-related rupture of arterial aneurysms. *Obstet Gynecol Surv* 1982;37:557-66.
  14. Hartman JD, Eftychiadis AS. Medial smooth muscle lesions and dissection of aorta and muscular arteries. *Arch Pathol Lab Invest* 1990;114:50-61.
  15. Selo-Ojemea DO, Marshmanb LA, Ikomia A, Ojutikua D, Aspoasb RA, Chawdac SJ, *et al.* Aneurysmal subarachnoid haemorrhage in pregnancy. *Eur J Obstet Gynecol Reprod Biol* 2004;116:131-43.
  16. Fullerton HJ, Johnston SC, Smith WS. Arterial dissection and stroke in children. *Neurology* 2001;57:1155-60.
  17. Caplan LR, Baquis MD, Pessin MS, D'Alton J, Adelman LS, De Witt LD, *et al.* Dissection of the intracranial vertebral artery. *Neurology* 1988;38:868-77.
  18. Bradac GB, Kaernbach A, Bolk-Weischel D. Spontaneous dissecting aneurysm of cervical cerebral arteries: Report of six cases and review of the literature. *Neuroradiology* 1981;21:149-54.
  19. Sherman P, Oka M, Aldrich E, Jordan L, Gailloud L. Isolated Posterior Cerebral Artery Dissection: Report of Three Cases. *AJNR Am J Neuroradiol* 2006;27:648-52.
  20. Su W, Gou S, Ni S, Li G, Liu Y, Zhu S, *et al.* Management of ruptured and unruptured intracranial vertebral artery dissecting aneurysms. *J Clin Neurosci* 2011;18:1639-44.
  21. Wang H, Du R, Stary J, Gkogkas C, Kim D, Day A, *et al.* Dissecting aneurysms of the posterior cerebral artery: Current endovascular/surgical evaluation and treatment strategies. *Neurosurgery* 2012;70:1581-8.
  22. Wang J, Sun Z, Bao J, Zhang B, Jiang Y, Lan W. Characteristics and endovascular treatment of aneurysms of posterior cerebral artery. *Neurol India* 2011;59:6-11.
  23. Kim BM, Shin YS, Kim SH, Suh SH, IhnYK, Kim DI, *et al.* Incidence and risk factors of recurrence after endovascular treatment of intracranial incidence and risk factors of recurrence after endovascular treatment of intracranial. *Stroke* 2011;42:2425-30.
  24. Seung WB, Kim JW, Park YS. Stent-Assisted coil trapping in a manual internal carotid artery compression test for the treatment of a fusiform dissecting aneurysm. *J Korean Neurosurg Soc* 2012;51:296-300.
  25. Kai Y, Nishi T, Watanbe M, Morioka M, Hirano T, Yano S, *et al.* Strategy for treating unruptured vertebral artery dissecting aneurysms. *Neurosurgery* 2011;69:1085-92.