

[ CASE REPORT ]

## Five Cases of IgG4-related Disease with Nasal Mucosa and Sinus Involvement

Masanobu Ueno, Kazuhisa Nakano, Ippei Miyagawa and Yoshiya Tanaka

### Abstract:

We herein report five patients with nasal mucosa and sinus involvement who were diagnosed with immunoglobulin G4-related disease (IgG4-RD). In all cases, the lacrimal, parotid, and submandibular glands were swollen; biopsies of these glands were risky, so the labium and nasal mucosa were instead targeted. All patients tested positive through these biopsies, suggesting alternative sites for confirming IgG4-RD. These five patients had first been diagnosed and unsuccessfully treated for allergic rhinitis or chronic sinusitis. After the IgG4-RD diagnosis, they were administered corticosteroid therapy, which drastically improved the nasal mucosa and sinus involvement. When refractory allergic rhinitis or sinusitis is detected, IgG4-RD should be considered.

**Key words:** IgG4-related disease, chronic sinusitis, IgG4-positive plasma cell, nasal involvement, nasal mucosa biopsy

(Intern Med 59: 1905-1911, 2020)

(DOI: 10.2169/internalmedicine.4127-19)

### Introduction

Immunoglobulin G4-related disease (IgG4-RD) is a systemic disease characterized by hyperimmunoglobulinemia G4, an infiltration of immunoglobulin (Ig) G4-positive plasma cells into tissues throughout the body, mass formation, and fibrosis. Since Hamano et al. reported autoimmune pancreatitis to be associated with an infiltration of IgG4-positive plasma cells into the pancreas in 2001 (1), the infiltration of IgG4-positive plasma cells into various organs throughout the body has been reported in cases of hypophysitis, hypertrophic pachymeningitis, Mikulicz disease, interstitial pneumonia, sclerosing cholangitis, retroperitoneal fibrosis, or inflammatory pseudotumor (2).

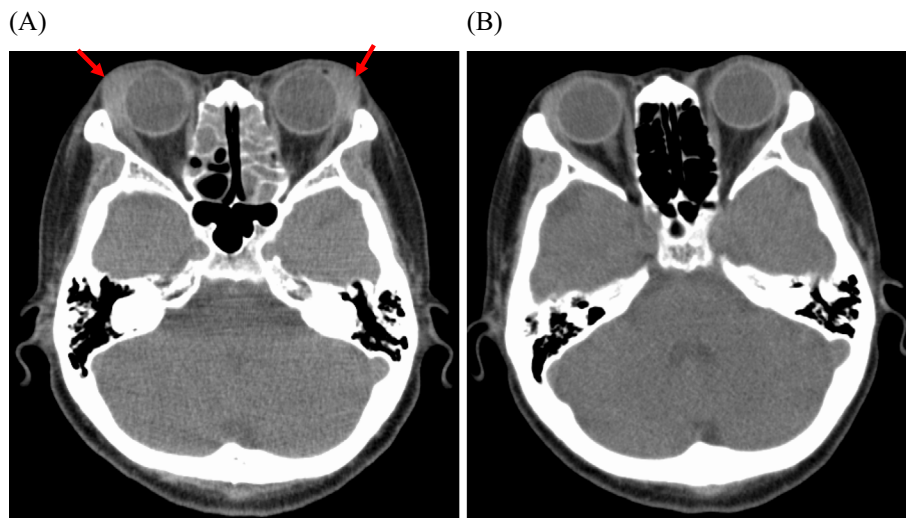
The diagnosis of IgG4-RD requires confirmation of deposition of IgG4-positive plasma cells by a tissue biopsy of the lesions. Depending on the site of the lesion, biopsies are often associated with a high risk and are difficult to perform. However, the lip and papilla of Vater are reported to be useful alternative biopsy sites to lesions (3, 4). In recent years, the nasal mucosa has been attracting attention as a biopsy site that is easy to approach with a low risk (5).

We encountered five patients with IgG4-related nasal mucosa and sinus involvement who had all been diagnosed with refractory allergic rhinitis or sinusitis. Although IgG4-RD is considered to often coexist with allergic diseases, there are patients with nasal mucosa or sinus involvement presenting with organ dysfunction caused by IgG4-RD, as in the present patients. Our cases suggested that nasal mucosa biopsies might be useful for the histological diagnosis of IgG4-RD. In addition, it seems necessary to include IgG4-RD in the differential diagnosis in patients with refractory rhinitis or sinusitis.

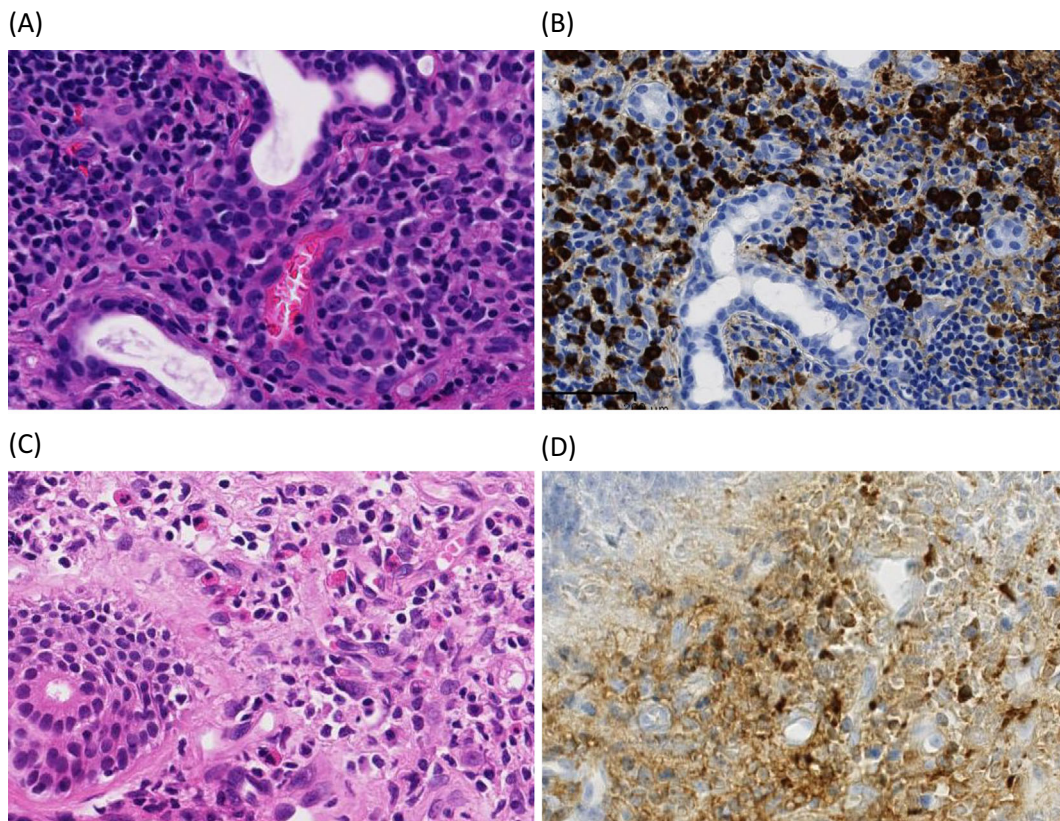
### Case Reports

#### Case 1

The patient was a 69-year-old woman. Her chief complaints were swelling of both lacrimal glands, nasal congestion, and dry mouth. In year X-2, an otolaryngologist at a nearby hospital diagnosed her with allergic rhinitis and started treatment with antihistamines. However, her symptoms were not relieved. Because swelling of the lacrimal glands and dry mouth occurred, she was referred to our de-



**Figure 1.** (A) Pre-treatment computed tomographic image of Case 1. (B) Post-treatment computed tomographic image of Case 1.



**Figure 2.** Histological findings of the labium and nasal mucosa of Case 1. (A) Pathological findings of the salivary gland [Hematoxylin and Eosin (H&E) staining; magnification,  $\times 100$ ]; (B) Pathological findings of the salivary gland stained for immunoglobulin G4-positive plasma cells (magnification,  $\times 100$ ); (C) Pathological findings of the nasal mucosa (H&E staining; magnification,  $\times 100$ ); (D) Pathological findings of the salivary gland stained for immunoglobulin G4-positive plasma cells (magnification,  $\times 100$ ).

partment in year X. The serum IgG4 level was as high as 524 mg/dL. Computed tomography (CT) revealed swelling of both lacrimal glands, the parotid gland, and the submandibular gland, as well as fluid retention in the paranasal sinus (Fig. 1A). Pathological images of the lip and nasal mu-

cosa biopsy specimens are shown in Fig. 2. An examination of the lip biopsy specimens revealed that the salivary glands were atrophic and also fibrotic (Fig. 2A). Immunostaining also revealed infiltration of many IgG4-positive plasma cells (IgG4/IgG>40%) (Fig. 2B). The nasal mucosa biopsy speci-

mens contained few eosinophils and were partially fibrotic (Fig. 2C). Immunostaining revealed infiltration of IgG4-positive plasma cells (IgG4/IgG=40%) (Fig. 2D). Based on these findings and the results of the histopathological examination of the lip and nasal mucosa biopsy specimens, the patient was diagnosed with IgG4-RD. As for treatment, the administration of prednisolone (PSL) at a dose of 0.6 mg/kg/day was started. Nasal congestion was markedly reduced after the start of treatment. CT performed two weeks after the start of treatment also showed that the swelling of both lacrimal glands, the parotid gland, and the submandibular gland had been reduced, and that the fluid retained in the paranasal sinus was decreasing (Fig. 1B).

### Case 2

The patient was a 69-year-old woman. Her chief complaints were swelling of both lacrimal glands, nasal congestion, and dry mouth. In year X-7, a physician at a nearby hospital diagnosed her with allergic rhinitis. Her symptoms had since been well controlled by anti-allergic drugs. However, in year X-1, the nasal congestion worsened, and swelling of both lacrimal glands and dry mouth also occurred. She was therefore referred to our department in year X. A detailed examination showed a high serum IgG4 level of 1,180 mg/dL, and CT revealed swelling of both lacrimal glands, the parotid gland, and the submandibular gland, as well as fluid retention in the paranasal sinus. Based on these findings and the results of the histopathological examination of the lip and nasal mucosa biopsy specimens, the patient was diagnosed with IgG4-RD. The administration of PSL at a dose of 0.6 mg/kg/day was started. The swelling of both lacrimal glands and nasal congestion were markedly reduced after the start of treatment.

### Case 3

The patient was a 64-year-old woman. Her chief complaint was nasal congestion. In year X-3, she was diagnosed with chronic sinusitis at the Department of Otolaryngology of a nearby hospital. Although treatment with antibiotics and antihistamines was started, symptom improvement was limited. In year X, a high serum IgG4 level was incidentally detected at the Department of Internal Medicine of a nearby hospital. She was therefore referred to our department. A detailed examination showed a high serum IgG4 level of 1,370 mg/dL and fluid retention in the paranasal sinus. Based on these findings and the results of the histopathological examination of nasal mucosa biopsy specimens, the patient was diagnosed with IgG4-RD. Because she concomitantly had poorly controlled type 2 diabetes mellitus but no significant organ dysfunction, treatment with corticosteroid nasal spray was started. The nasal congestion was promptly reduced.

### Case 4

The patient was a 41-year-old woman. Her chief complaints were swelling of both lacrimal glands and nasal con-

gestion. Although she had been aware of nasal congestion since year X-1, she had not visited any hospital. Because swelling of both lacrimal glands was pointed out by her family, she visited a clinic where she was referred to our department. She visited us in year X. A detailed examination showed a high serum IgG4 level of 162 mg/dL, and CT revealed swelling of both lacrimal glands, the parotid gland, and the submandibular gland, as well as fluid retention in the paranasal sinus. Based on these findings and the results of the histopathological examination of nasal mucosa biopsy specimens, the patient was diagnosed with IgG4-RD. As for treatment, the administration of PSL at a dose of 0.6 mg/kg/day was started. The swelling of both lacrimal glands and nasal congestion were markedly reduced after the start of treatment.

### Case 5

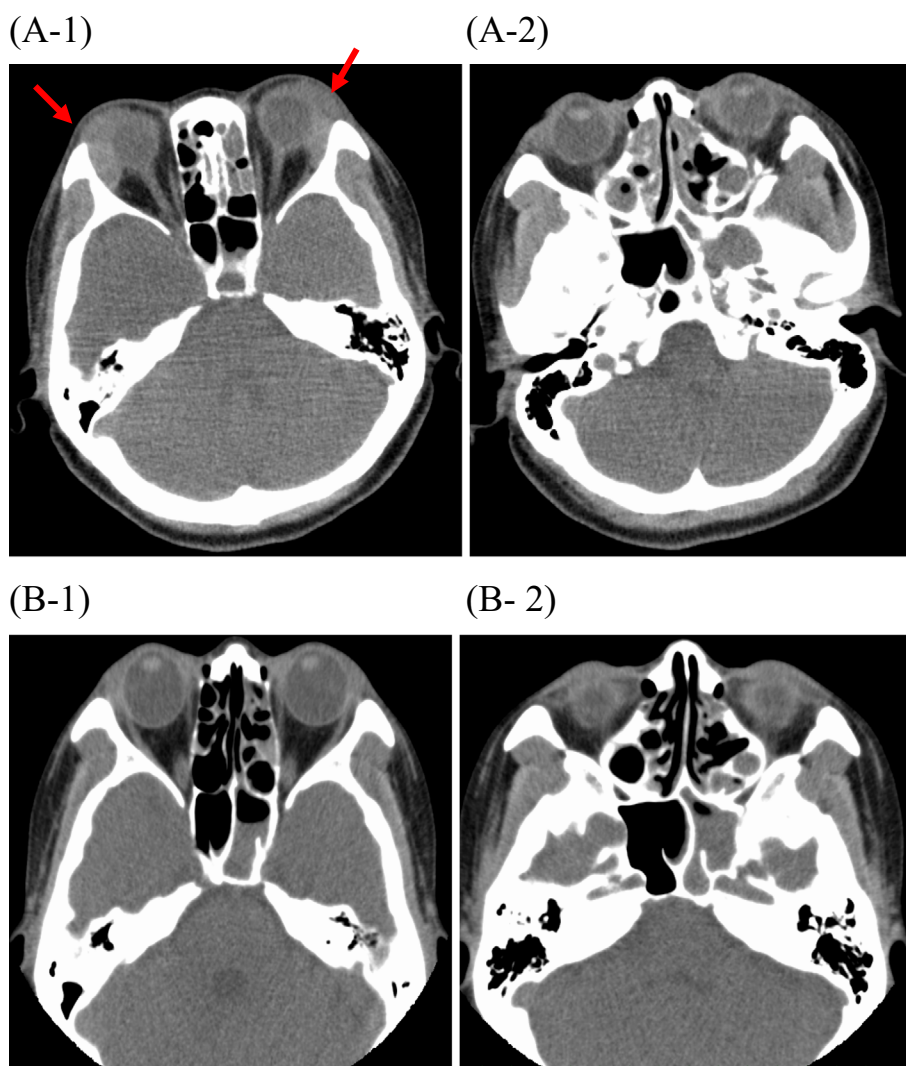
The patient was a 39-year-old woman. Her chief complaints were swelling of both lacrimal glands, nasal congestion, and dry mouth. In year X-7, she was diagnosed with chronic sinusitis at the otolaryngology department of a nearby hospital. She had since been taking corticosteroids and antihistamines as needed. At our department in year X, a detailed examination showed a high serum IgG4 of 1,180 mg/dL, and CT revealed swelling of both lacrimal glands and fluid retention in the paranasal sinus (Fig. 3A-1, 3A-2). Based on the results of the histopathological examination of lip biopsy specimens, the patient was diagnosed with IgG4-RD. The administration of PSL at a dose of 0.6 mg/kg/day was started. Nasal congestion was markedly reduced after the start of treatment. CT performed 2 weeks after the start of treatment also showed that swelling of both lacrimal glands, the parotid gland, and the submandibular gland was reduced and that the fluid retained in the paranasal sinus was decreasing (Fig. 3B-1, B-2).

The clinical and pathological findings of Cases 1 to 5 are summarized in Tables 1 and 2, respectively.

## Discussion

The five patients we encountered were initially diagnosed with allergic rhinitis or chronic sinusitis, which was treated with antihistamines and other drugs. Because their conditions had not improved, they had been assumed to have refractory allergic rhinitis or sinusitis. However, when corticosteroid therapy was started after the diagnosis of IgG4-RD, the nasal mucosa and sinus involvement was dramatically improved.

All five patients were women, and the mean age was 56.4 ±15.1 years old. The clinical symptoms noted by them were nasal congestion in all five patients, swelling of both lacrimal glands in four patients, and dry mouth in three patients. As for the organ dysfunction, all patients had concomitant sinusitis; four patients had swelling of the lacrimal and parotid glands, and one patient had cholecystitis. Allergic rhinitis and chronic sinusitis had previously been diagnosed



**Figure 3.** (A-1, A-2) Pre-treatment computed tomographic images of Case 5. (B-1, B-2) Post-treatment computed tomographic images of Case 5.

**Table 1.** Background of Five IgG4-RD Cases in Nasal Mucosa and Sinus Lesion.

Case	Age	Gender	Clinical symptom	Duration	Organ disorder	WBC( $\mu$ L) (Eosi)	IgG (mg/dL)	IgG4 (mg/dL)	IgE-RIST (IU/mL)
1	69	F	Eyelid swelling Nasal obstruction Dry mouth	17M	Lg, Pg, Gb, Ps	4,000 (200)	1,919	524	399
2	69	F	Eyelid swelling Nasal obstruction Dry mouth	93M	Lg, Pg, Ps	5,800 (754)	2,254	1,180	732
3	64	F	Nasal obstruction	38M	Lg, Ps	7,700 (1,232)	2,889	1,370	108
4	41	F	Eyelid swelling Nasal obstruction	6M	Lg, Pg, Ps	7,500 (600)	1,339	162	713
5	39	F	Eyelid swelling Nasal obstruction Dry mouth	34M	Lg, Pg, Ps	7,100 (426)	2,055	721	193

IgG4-RD: IgG4-related disease, F: Female, M: Male, RIST: radioimmunosorbent test, Lg: Lacrimal gland, Pg: Parotid gland, Gb: Gall bladder, Ps: Paranasal sinus

in two patients, both of whom responded poorly to antihistamines. The mean serum levels were  $2,091.2 \pm 561.1$  mg/dL for IgG and  $791.4 \pm 489.5$  mg/dL for IgG4. The eosinophil

count was also elevated in Cases 2-5. CT revealed fluid retention in the paranasal sinus in all patients and swelling of both eyelids in four patients. For the histologic examination,

**Table 2. Histological Findings of Lip and Nasal Mucosal Biopsy.**

Case	Biopsy site	Lip biopsy			Nasal mucosal biopsy			Eosinophilic filtration
		Lymphocytes, plasmablast infiltration	fibrosis	Ratio of IgG4/IgG plasma cells	Lymphocytes, plasmablast infiltration	fibrosis	Ratio of IgG4/IgG plasma cells	
1	Lip Nasal mucosal	○	○	>40%	○	○	>40%	<10/HPF
2	Lip Nasal mucosal	○	○	>50%	○	○	40%	<10/HPF
3	Nasal mucosal	Not done	Not done	Not done	○	○	80%	<10/HPF
4	Lip Nasal mucosal	×	×	×	○	○	>40%	<10/HPF
5	Lip Nasal mucosal	○	○	>40%	○	×	20%	<10/HPF

HPF: High Power Field

**Table 3. JESREC Score in Our Five Cases.**

Case		Total score
1	bilateral (3), CT shadow (2), eosinophils in peripheral blood (4)	9
2	bilateral (3), CT shadow (2), eosinophils in peripheral blood (10)	15
3	bilateral (3), CT shadow (2), eosinophils in peripheral blood (10)	15
4	bilateral (3), CT shadow (2), eosinophils in peripheral blood (8)	13
5	bilateral (3), CT shadow (2), eosinophils in peripheral blood (8)	13

JESREC: Japanese epidemiological survey of refractory eosinophilic chronic rhinosinusitis

a lip biopsy was performed in four patients, and a nasal mucosa biopsy was performed in five patients. The histopathological findings of both biopsies met the comprehensive diagnostic criteria for IgG4-RD in two patients. One patient showed a negative result for the lip biopsy and a positive result for the nasal mucosa biopsy, whereas another patient showed positive and negative results, respectively. In the remaining patient, no lip biopsy was performed, and the result of the nasal mucosa biopsy was positive. This means that the pathological findings of the nasal mucosa biopsy were positive in four of the five patients. All four of these patients showed infiltration of IgG4-positive plasma cells and mild fibrosis.

For treatment, moderate-dose corticosteroid therapy (PSL 0.5-0.6 mg/kg/day) was started in Cases 1, 2, 3, and 5, and nasal congestion was promptly reduced. In Cases 1 and 5, CT performed after treatment confirmed the improvement in sinusitis and swelling of both eyelids (Fig. 1, 2). In Case 4, the patient had poorly controlled type 2 diabetes mellitus, mild sinusitis, and no significant organ dysfunction. Treatment with corticosteroid nasal spray was started, and nasal congestion was reduced.

In these five patients, differentiation of eosinophilic sinusitis was necessitated by the presence of eosinophilia and findings suggestive of sinusitis. According to the JESREC scoring system reported by Tokunaga et al. (6), which comprises bilateral disease (3 points), the presence of nasal polyp (2 points), CT shadow (ethmoid sinus>maxillary sinus; 2 points), and eosinophils in peripheral blood (2%<

eosinophils≤5%, 5%<eosinophils≤10%, >10%; 4, 8, and 10 points, respectively), eosinophilic sinusitis is strongly suspected when the total score is ≥11 points. A definitive diagnosis is made when eosinophil infiltration in the tissue is 70/high-power field. Cases 2-5 met the JESREC score criteria (Table 3). However, as all four patients had a low eosinophil count in the tissue, eosinophilic sinusitis was ruled out, and the diagnosis of sinusitis associated with IgG 4-RD was made.

It was recently reported that IgG4-RD is complicated by sinusitis. Moteki et al. reported that 10 of 31 patients with IgG4-RD had concomitant sinusitis (7). In IgG4-RD, the clinical symptoms of nasal mucosa and sinus involvement vary from mild, such as nasal congestion (as seen in our 5 cases) and smell disorder, to serious, such as infiltration accompanied by surrounding bone destruction (8). There are no symptoms or findings specific to the nasal mucosa and sinus involvement caused by IgG4-RD. However, in patients who poorly respond to treatment for preexisting allergic rhinitis or sinusitis, it seems necessary to consider the possibility of nasal mucosa and sinus involvement associated with IgG4-RD and make a differential diagnosis. Although IgG4-RD is considered to often coexist with allergic diseases, our cases suggested that when patients with IgG4-RD present with nasal mucosa and sinus involvement, the fact that the involvement might be caused by organ dysfunction caused by IgG4-RD in addition to concomitant allergic diseases should be considered.

To diagnose IgG4-RD, the presence of IgG4-positive

**Table 4. Literature Review on Symptoms of Immunoglobulin G4-related Disease Complicated by Sinusitis, Other Organs Affected by Immunoglobulin G4-related Disease, Serum Immunoglobulin G4/immunoglobulin G Ratio, Treatment, Treatment Response, and Differences in Nasal Mucosal Pathology between Immunoglobulin G4-related Disease and Chronic Sinusitis.**

Reference	N	Age	Nasal symptoms	Other IgG4-related disease	Serum IgG (mg/dL)	Serum IgG4 (mg/dL)	Therapy	Effectiveness	Recurrence	Pathological difference
I <sup>10)</sup>	10	59.1 ±11.2	hyposmia 4, nasal obstruction 3, nothing 3	MD 6, AIP 5, RF 4, SC 3, LYM 2, KID 1	2,040.2 ±537.2	740.4 ±472.4	surgery 8, CS 8	10	1	ND
II <sup>6)</sup>	5	54.4 ±4.0	Postnasal drip 5, nasal obstruction 1	AIP 5, MD 5, SC 3, LUN 4	3,286.2 ±1,423.8	1,530 ±1,012.9	surgery 0, CS 5	5	0	-
III <sup>15)</sup>	12	51.8 ±9.6	nasal obstruction 5, nothing 7	MD 12, LUN 6, LYM 4, SC 1	2,668.7 ±1,382.6	490.1 ±468.6	surgery 0, CS 12	12	0	+

MD: Mikulicz disease, AIP: autoimmune pancreatitis, RF: retroperitoneal fibrosis, SC: sclerosing cholangitis, LYM: lymphadenopathy, KID: kidney disease, LUN: lung disease, CS: corticosteroid, ND: not detected

plasma cells infiltrating tissues is essential, in addition to the presence of one or more swollen organs and elevated serum IgG4 levels ( $\geq 135$  mg/dL). Furthermore, it is necessary to exclude other diseases, such as malignant lymphoma, solid cancer, sarcoidosis, and infections; a biopsy is therefore important. However, because a highly invasive surgical procedure is sometimes required, depending on the lesion site, no biopsy can be performed in some cases. In such cases, a biopsy should be performed at non-lesion sites, from which biopsy specimens can be obtained in a relatively less-invasive manner.

The lip and papilla Vater are reported to be useful biopsy sites (3, 4). There are some reports that the sensitivity of a lip biopsy is 55.6-83.3% (9-11). Regarding nasal mucosa biopsies, several studies have been reported. One study found that IgG4-positive plasma cells infiltrated into the nasal mucosa in 56.5% of patients with IgG4-RD (5). Another case report showed that, despite the lack of imaging findings suggestive of symptoms of rhinitis or sinusitis, a nasal mucosa biopsy yielded pathological findings meeting the diagnostic criteria for IgG4-RD (12). There is also another report that regardless of the severity of sinonasal manifestations on CT scans, pathological images showed no difference in infiltration of IgG4-positive cells (13). The nasal mucosa is expected to be another useful and easily accessible biopsy site. Piao et al. reported that the degree of infiltration of IgG4-positive plasma cells into the nasal mucosa differed between patients with IgG4-RD complicated by sinusitis and those with chronic sinusitis (14). However, Moteki et al. reported no significant difference between patients with IgG4-RD complicated by sinusitis and those with chronic sinusitis (7), and no consensus has been obtained concerning the differences in histological features of a nasal mucosal biopsy between IgG4-RD sinusitis and chronic/allergic sinusitis. No published report has compared the usefulness of lip and nasal mucosal biopsies. Our study was also conducted in a small number of cases, making it impossible to examine which biopsy approach was superior for the diagnosis. Therefore, the further accumulation of cases is needed.

In our five cases, the lacrimal, parotid, and submandibular glands were swollen. Because biopsies of these swollen or-

gans were associated with a high risk, biopsies were performed on the labium and nasal mucosa. All patients had positive findings on either a lip or nasal mucosa biopsy. Like the lip biopsy, the nasal mucosa biopsy is minimally invasive and easy to perform even at an outpatient clinic. Although the further accumulation of cases is necessary for clarification, it was suggested that the nasal mucosa might be a useful biopsy site for the diagnosis of IgG4-RD. In addition, nasal symptoms were promptly relieved after the start of treatment, and CT revealed a decrease in the fluid retained in the paranasal sinus. Furthermore, a previous report also indicated that patients with sinusitis, which is an organ dysfunction caused by IgG4-RD, respond well to corticosteroid therapy (Table 4) (6, 10, 15). These findings strongly suggested that sinus involvement was an organ dysfunction caused by IgG4-RD in all five patients.

The present patients we encountered had been treated with antihistamines for refractory allergic rhinitis or sinusitis for a long period of time, but no improvement had been observed. When refractory allergic rhinitis or sinusitis is detected, it seems necessary to include IgG4-RD in the differential diagnosis.

**The authors state that they have no Conflict of Interest (COI).**

## References

- Hamano H, Kawa S, Horiuchi A, et al. High serum IgG4 concentrations in patients with sclerosing pancreatitis. *N Engl J Med* **344**: 732-738, 2001.
- Uchida K, Satoi S, Miyoshi H, et al. Inflammatory pseudotumors of the pancreas and liver with infiltration of IgG4-positive plasma cells. *Intern Med* **46**: 1409-1412, 2007.
- Kamisawa T, Tu Y, Nakajima H, Egawa N, Tsuruta K, Okamoto A. Usefulness of biopsying the major duodenal papilla to diagnose autoimmune pancreatitis: a prospective study using IgG4-immunostaining. *World J Gastroenterol* **12**: 2031-2033, 2006.
- Yamamoto M, Ohara M, Suzuki C, et al. Elevated IgG4 concentrations in serum of patients with Mikulicz's disease. *Scand J Rheumatol* **33**: 432-433, 2004.
- Suzuki M, Nakamura Y, Akazawa S, et al. Nasal manifestations of immunoglobulin G4-Related Disease. *Laryngoscope* **123**: 829-834, 2013.

6. Tokunaga T, Sakashita M, Haruna T, et al. Novel scoring system and algorithm for classifying chronic rhinosinusitis: the JESREC Study. *Allergy* **70**: 995-1003, 2015.
7. Moteki H, Yasuo M, Hamano H, Uehara T, Usami S. IgG4-related chronic rhinosinusitis: a new clinical entity of nasal disease. *Acta Otolaryngol* **131**: 518-526, 2011.
8. Pace C, Ward S. A rare case of IgG4-related sclerosing disease of the maxillary sinus associated with bone destruction. *J Oral Maxillofac Surg* **68**: 2591-2593, 2010.
9. Akiyama M, Kaneko Y, Yamaoka K, et al. Subclinical labial salivary gland involvement in IgG4-related disease affected with vital organs. *Clin Exp Rheumatol* **33**: 949-950, 2015.
10. Abe A, Takano K, Seki N, et al. The clinical characteristics of patients with IgG4-related disease with infiltration of the labial salivary gland by IgG4-positive cells. *Mod Rheumatol* **24**: 949-952, 2014.
11. Moriyama M, Ohta M, Furukawa S, et al. The diagnostic utility of labial salivary gland biopsy in IgG4-related disease. *Mod Rheumatol* **26**: 725-729, 2016.
12. Nakata R, Yoshimura S, Motomura M, Tsujino A, Hayashi T, Hara M. IgG4-related disease with cavernous sinus and intra-orbital lesions diagnosed by nasal mucosa biopsy. *Rinsho Shinkeigaku (Clin Neurol)* **56**: 637-640, 2016 (in Japanese, Abstract in English).
13. Takano K, Abe A, Yajima R, et al. Clinical evaluation of sinonasal lesions in patients with immunoglobulin G4-related disease. *Ann Otol Rhinol Laryngol* **124**: 965-971, 2015.
14. Piao Y, Wang C, Yu W, et al. Concomitant occurrence of Mikulicz's disease and immunoglobulin G4-related chronic rhinosinusitis: a clinicopathological study of 12 cases. *Histopathology* **68**: 502-512, 2016.
15. Hanaoka M, Kammasawa T, Koizumi S, et al. Clinical features of IgG4-related rhinosinusitis. *Adv Med Sci* **62**: 393-397, 2017.

The Internal Medicine is an Open Access journal distributed under the Creative Commons Attribution-NonCommercial-NoDerivatives 4.0 International License. To view the details of this license, please visit (<https://creativecommons.org/licenses/by-nc-nd/4.0/>).