

Treatment Strategy Based on Plaque Vulnerability and the Treatment Risk Evaluation for Internal Carotid Artery Stenosis

Yoshiro ITO,¹ Wataro TSURUTA,¹ Yasunobu NAKAI,² Tomoji TAKIGAWA,¹
Aiki MARUSHIMA,¹ Tomohiko MASUMOTO,³ Yuji MATSUMARU,⁴
Eiichi ISHIKAWA,¹ and Akira MATSUMURA¹

¹Department of Neurosurgery, Faculty of Medicine, University of Tsukuba,
Tsukuba, Ibaraki, Japan;

²Department of Neurosurgery, Tsukuba Medical Center Hospital, Tsukuba, Ibaraki, Japan;

³Department of Radiology, Faculty of Medicine, University of Tsukuba,
Tsukuba, Ibaraki, Japan;

⁴Division for Stroke, Department of Neurosurgery, Faculty of Medicine,
University of Tsukuba, Tsukuba, Ibaraki, Japan

Abstract

Carotid endarterectomy (CEA) and carotid artery stenting (CAS) are not appropriate treatment procedure for internal carotid artery stenosis (ICAS) in some patients. The importance of plaque vulnerability and the treatment risk evaluation has been reported. We analyzed whether treatment selection contributes to the outcome. We retrospectively examined 121 patients who underwent CEA or CAS. Treatment was selected based on plaque vulnerability and the treatment risk evaluation. We selected CAS for patients with stable plaques and CEA for patients with unstable plaques, and considered the other treatment for high-risk patients. The patients were classified as the stable plaque (Stable: $n = 42$), the unstable plaque and CEA low risk (Unstable/Low: $n = 30$), and the CEA high-risk (Unstable/High: $n = 49$). Frequency of perioperative stroke, myocardial infarction, death, and systemic complications was examined. CEA and CAS were performed in 35 and 86 patients, respectively. One patient (2.9%) had a stroke in CEA and five patients (5.8%) in CAS ($P = 0.50$). Systemic complications were observed in two patients (5.7%) in CEA and six (7.1%) in CAS ($P = 0.80$). There were no differences in stroke (Stable; 2.4%, Unstable/Low; 3.2%, and Unstable/High; 8.2%) and systemic complications (Stable; 9.5%, Unstable/Low; 3.3%, and Unstable/High; 6.1%) among three groups ($P = 0.44$ and $P = 0.59$, respectively). The treatment selection based on plaque vulnerability and the treatment risk evaluation could provide good treatment outcome for high-risk patients. It is ideal to select an appropriate treatment for ICAS by one neurovascular team.

Key words: internal carotid artery stenosis, carotid endarterectomy, carotid artery stenting, plaque vulnerability, treatment risk evaluations

Introduction

Previous large studies have reported whether carotid endarterectomy (CEA) or carotid artery stenting (CAS) produce better outcomes for the internal carotid artery stenosis (ICAS).^{1–4} Advances in various devices have improved the treatment outcome of CAS.^{5–7} Recently published randomized studies revealed no statistically significant difference in long-term

outcome and rates of disabling stroke between CEA and CAS.⁸ It is essential to prevent the perioperative complications, specifically ischemic stroke and systemic complications.

The current literature describes CEA and CAS not to be appropriate for all patients with ICAS.^{2,9,10} A plaque image of ICAS is one of most attractive diagnostic methods.¹¹ Development of MRI enabled noninvasive assessment of plaque imaging.¹² Vulnerability of carotid artery plaque has been associated with not only plaque rupture that causes artery-to-artery embolism, but also an increased number of embolism after CEA or CAS.^{13,14} That means it is important to understand plaque vulnerability and

Received November 23, 2017; Accepted February 7, 2018

Copyright© 2018 by The Japan Neurosurgical Society This work is licensed under a Creative Commons Attribution-NonCommercial-NoDerivatives International License.

select an appropriate treatment to be able to avoid the neurological perioperative complications and improve outcome. Moreover, it is necessary to evaluate the treatment risks, such as systemic comorbidity and vessel architecture, because patients with ICAS often have atherosclerotic lesion and cardio-pulmonary disease.^{6,15} It is thought that preoperative evaluation of plaque vulnerability and the comorbidity in patients with ICAS can affect the perioperative outcome for CEA and CAS.

In our institute, CEA and CAS have been performed by one neurovascular team, and the treatment for each patient has been selected based on plaque vulnerability and the treatment risk evaluation. Recent reports recommend treatment strategy based on the plaque imaging and the treatment risk evaluation for ICAS.^{7,16} However, the reports regarding the treatment selection based on the patient's risk factors were limited.^{14,17,18} The purpose of this study was to determine whether treatment selection based on plaque vulnerability and the treatment risk evaluation can contribute to the treatment outcome for ICAS.

Materials and Methods

Patient population

We retrospectively searched a maintained database from the University of Tsukuba Hospital. Between April 2008 and October 2015, 121 consecutive patients underwent CEA or CAS for ICAS in our institute. Information regarding the following factors was collected for each patient by reviewing their medical records: age, sex, systemic comorbidity, symptomatic stenosis, radiological imaging, and clinical outcome. Intervention for ICAS was indicated based on the presence of angiographic documentation of ICAS of >50% in symptomatic patients and >80% in asymptomatic patients, according to the North American Symptomatic Carotid Endarterectomy Trial criteria.¹⁹ This study was approved by the Institutional Review Committee at our institution and all subjects gave informed consent.

MRI parameter

Carotid plaque images were obtained using a 1.5-T system (Achieva, Philips Healthcare, Best, the Netherlands). We used a volume isotropic turbo spin echo acquisition (VISTA) sequence. MRI parameters were as follows: T1-weighted VISTA (TR/TE = 400/16 ms, refocusing angle = 60°, thickness = 1 mm, field of view (FOV) = 18 cm, Matrix = 384 × 384, SENSE factor = 2, number of signal averaging = 2), T2-weighted VISTA (TR/TE = 3500/119 ms, refocusing angle = 60°, thickness = 1 mm, FOV = 18 cm, Matrix = 384 × 384, SENSE factor = 2, number

of signal averaging = 2), and time of flight (TOF) MRA (TR/TE = 16/6.9 ms, flip angle = 18°, thickness = 1.5 mm, FOV = 22 cm, matrix = 512 × 512, SENSE factor = 1.8, number of signal averaging = 2).

Treatment selection

The treatment method CEA or CAS was selected based on plaque vulnerability and the treatment risk evaluation for each subject. Lipid-rich and necrotic core plaque was diagnosed as unstable plaque based on the previous reports (signal intensity ratio ≥ 1.25 using T1-weighted VISTA).^{12,13,20} The treatment risks were compiled from previous reports.^{2,9,10,21,22} Risk factors of CEA were listed high position (>C2), post-radiation therapy, restenosis, and general anesthesia high risk (cardio-pulmonary disease, dual antiplatelet therapy, contralateral occlusion, and post-Swan–Ganz catheter insertion). Risk factors of CAS were listed tortuous or elongated vessel, thoracic aortic aneurysm, abdominal aortic aneurysm, severe calcification, and severe aortic valve stenosis. We assumed CAS for the stable plaques and CEA for the unstable plaques. Cross-overs of strategy are accepted due to risks of each treatment such as general conditions or vessel anatomy. All patients were investigated and all treatments were performed by one neurovascular team. The procedure of treatment selection is portrayed in Fig. 1A.

Perioperative management of CEA and CAS

All CEA and CAS were performed by an experienced neurovascular team including board-certified operators from the Japan Neurosurgical Society and the Japanese Society for Neuroendovascular Therapy. CEA was performed under general anesthesia while continuing single antiplatelet therapy. A bolus of heparin was given prior to the internal carotid artery clamping. An intraluminal shunt was used in these procedures and the dilation of the carotid artery was assessed by performing intraoperative angiography. A patch graft was not used.

Five to seven days before CAS, all patients received dual antiplatelet therapy. CAS was performed under local anesthesia using double balloon protection in the patients with ischemic tolerance, and using filter protection in the patients without ischemic tolerance and contralateral occlusion. Heparin was given with an activated clotting time of 250–300 s. Proximal balloon protection using Optimo (Tokai Medical Products, Aichi, Japan) was performed. Distal embolic protection devices like the Percusurge Guardwire (Medtronic AVE, Santa Rosa, CA, USA) and the Filterwire EZ (Boston Scientific, Natick, MA, USA) were used. All patients were treated

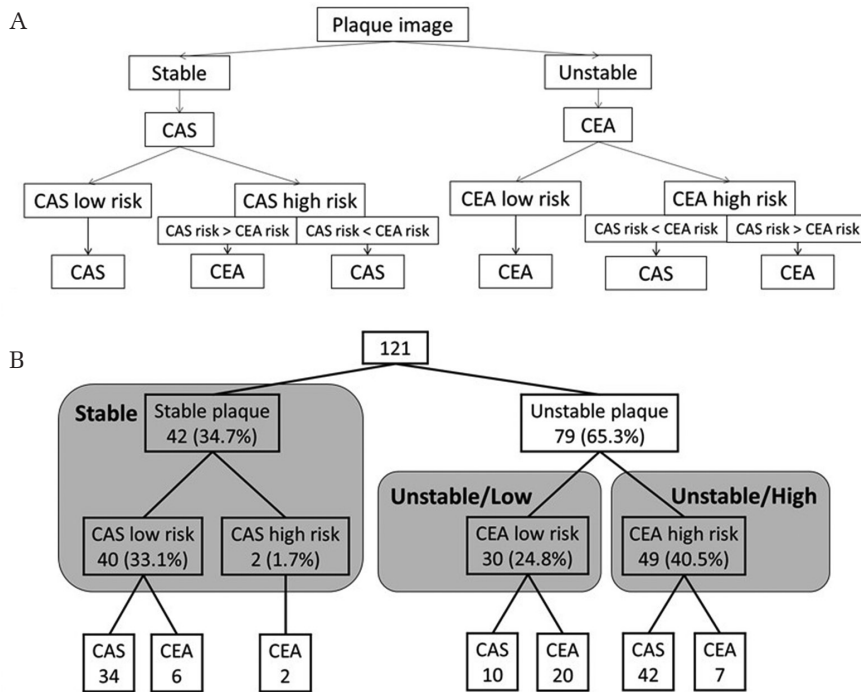


Fig. 1 (A) Treatment strategy based on plaque image and treatment risk evaluations for carotid artery stenosis. (B) The number of patients according to the classification.

using the self-expandable stents, Carotid Wallstent (Stryker). After the procedure, heparin treatment was not reversed.

In each treatment, ischemic and hemorrhagic complications were evaluated using MRI or CT within 72 h after the procedure.

Evaluation

The patients were classified as stable plaque (Stable) group or unstable plaque group based on plaque vulnerability. Furthermore, unstable plaque group was subdivided CEA low-risk (Unstable/Low) group and CEA high-risk (Unstable/High) group based on the treatment risk evaluation (Fig. 1B). The occurrence of a stroke, myocardial infarction (MI), death, and systematic complications within 30 days after the procedure were examined among the three groups (Stable, Unstable/Low, and Unstable/High) and between the treatment methods (CEA and CAS). Stroke was defined as any new neurological deficit that did not resolve completely within 24 h. MI was defined as the development of new electrocardiogram findings consistent with infarction or a creatine kinase level at least twice the upper limit of normal. Systemic complication was defined as any disease, except for stroke and MI, which caused an extended hospital stay.

Statistical analysis

Continuous data are expressed as mean \pm standard deviation, and discrete data are presented as counts and percentages. Differences between groups were

assessed using the Pearson's chi-square and Fisher exact tests for discrete data, and the Mann-Whitney U test for continuous data. SPSS statistics software version 21.0 (IBM, Armonk, New York, USA) was used for all analyses. A *P*-value less than 0.05 was considered significant.

Results

There were 121 patients with a mean age of 72.4 ± 6.6 years. There were 106 male patients (87.6%). About 52 patients (43.0%) had symptomatic lesions. Mean degree of stenosis was $78.8 \pm 11.3\%$. CEA and CAS were performed in 35 (28.9%) and 86 patients (71.1%), respectively. Mean age was significantly greater in CAS than CEA (73.3 ± 6.3 and 70.3 ± 6.9 , $P = 0.03$). There were no significant differences in sex, symptomatic stenosis, and degree of stenosis between CEA and CAS. Unstable plaque in CEA (77.1%) was greater than CAS (60.5%), but not significantly. Stroke within 30 days after the procedure was observed in six patients (5.0%); cerebral ischemic event ($n = 4$; 3.3%) and intracranial hemorrhage ($n = 2$; 1.7%). Permanent morbidity was observed in four patients (3.3%). Systemic complications were observed in eight patients (6.7%); acute heart failure ($n = 3$), acute coronary syndrome ($n = 1$), pulmonary disease ($n = 1$), and gastrointestinal disease ($n = 3$). There were no cases of MI and death. One patient (2.9%) had a stroke in CEA and five patients (5.8%) in CAS ($P = 0.50$). Systemic complications were observed

Table 1 Characteristics of patients treated with carotid endarterectomy or carotid artery stenting

	Total	CEA	CAS	P-value
Patients	121	35 (28.9%)	86 (71.1%)	
Age (years old)	72.4 ± 6.6	70.3 ± 6.9	73.3 ± 6.3	0.03
Men	106 (87.6%)	32 (91.4%)	74 (86.0%)	0.41
Symptomatic stenosis	52 (43.0%)	16 (45.7%)	36 (41.9%)	0.70
Degree of stenosis (%)	78.8 ± 11.3	76.7 ± 11.5	79.7 ± 11.2	0.19
Unstable plaque	79 (65.3%)	27 (77.1%)	52 (60.5%)	0.08
Death	0	0	0	
Stroke	6 (5.0%)	1 (2.9%)	5 (5.8%)	0.50
Cerebral ischemic event	4 (3.3%)	1 (2.9%)	3 (3.5%)	
Intracranial hemorrhage	2 (1.7%)	0	2 (2.3%)	
Myocardial infarction	0	0	0	
Systematic complication	8 (6.7%)	2 (5.7%)	6 (7.1%)	0.80

CEA: carotid endarterectomy, CAS: carotid artery stenting.

Table 2 Characteristics and clinical results among three groups

	Stable	Unstable/Low	Unstable/High	P-value
Patients	42 (34.7%)	30 (24.8%)	49 (40.5%)	
Age (years old)	73.0 ± 8.0	72.0 ± 5.8	72.2 ± 5.9	0.79
Men	36 (85.7%)	28 (93.3%)	42 (85.7%)	0.55
Symptomatic stenosis	19 (45.2%)	13 (43.3%)	20 (40.8%)	0.91
Degree of stenosis (%)	81.4 ± 9.5	76.7 ± 11.4	77.9 ± 12.4	0.17
CEA	8 (19.1%)	20 (66.7%)	7 (14.2%)	
Death	0	0	0	
Stroke	1 (2.4%)	1 (3.2%)	4 (8.2%)	0.44
Cerebral ischemic event	1 (2.4%)	1 (3.2%)	2 (4.1%)	
Intracranial hemorrhage	0	0	2 (4.1%)	
Myocardial infarction	0	0	0	
Systemic complication	4 (9.5%)	1 (3.3%)	3 (6.1%)	0.59

CEA: carotid endarterectomy.

in two patients (5.7%) in CEA and six (7.1%) in CAS ($P = 0.80$) (Table 1).

Preoperative plaque vulnerability demonstrated stable plaque in 42 patients (34.7%) and unstable plaque in 79 patients (65.3%). A total of 40 patients out of the 42 patients with stable plaques were assessed CAS low-risk, and 34 of 40 patients (85.0%) underwent CAS. Two of the 42 patients with stable plaques, who were assessed as CAS high-risk because of severe calcification, underwent CEA. In contrast, 30 of 79 patients with unstable plaques were assessed CEA low-risk, and 20 of 30 patients (66.7%) underwent CEA. Forty-nine patients were assessed CEA high-risk, and 42 of 49 patients (85.7%) underwent CAS (Fig. 1B). Main risk factors

of CEA in patients with unstable plaques were the presence of high position ($n = 25$; 51.0%) and post-radiation therapy ($n = 13$; 26.5%).

In the classification based on plaque vulnerability and the treatment risk evaluation, Stable, Unstable/Low, and Unstable/High was 42 (34.7%), 30 (24.8%), and 49 (40.5%), respectively (Table 2). There were no significant differences in age, sex, symptomatic stenosis, and degree of stenosis among three groups. Stroke did not have the difference among three groups (Stable; 2.4%, Unstable/Low; 3.2% and Unstable/High; 8.2%) ($P = 0.44$). Systemic complications did not have the difference among three groups (Stable; 9.5%, Unstable/Low; 3.3%, and Unstable/High; 6.1%) ($P = 0.59$) (Table 2). Seven

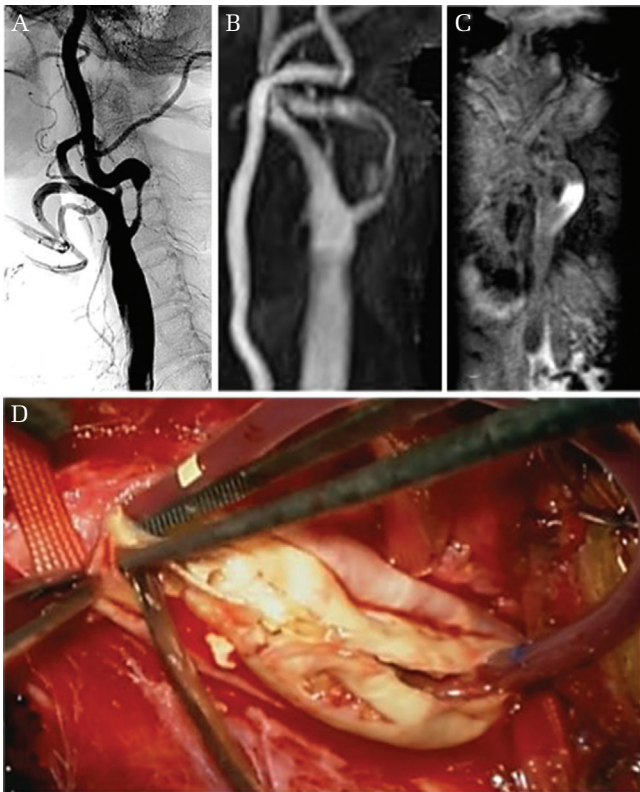


Fig. 2 Case 1: (A) Preoperative angiography reveals severe stenosis in the right internal carotid artery, which is tortuous. Preoperative magnetic resonance angiography (B) and carotid plaque imaging (C) shows unstable plaque. (D) Carotid endarterectomy was performed uneventfully.

patients in Unstable/High had CAS high-risk, and they underwent CEA. They did not have any stroke and systemic complications.

Representative cases

Case 1: The patient was a 69-year-old man with asymptomatic right ICAS. Preoperative radiological imaging revealed ICAS with unstable plaque; the distal portion was C2 body level and very tortuous (Figs. 2A–2C). He was assessed as CEA high-risk because of the high position of the plaque; and CAS high-risk because of the presence of a severe tortuous vessel and unstable plaque. We discussed that tortuous vessels and unstable plaques in CAS posed higher treatment risk than the high position of the plaque in CEA. CEA was performed uneventfully, and adequate vasodilatation was obtained (Fig. 2D). There were no perioperative complications.

Case 2: The patient was a 73-year-old man with asymptomatic left ICAS. Three months ago, he underwent percutaneous coronary intervention for coronary artery

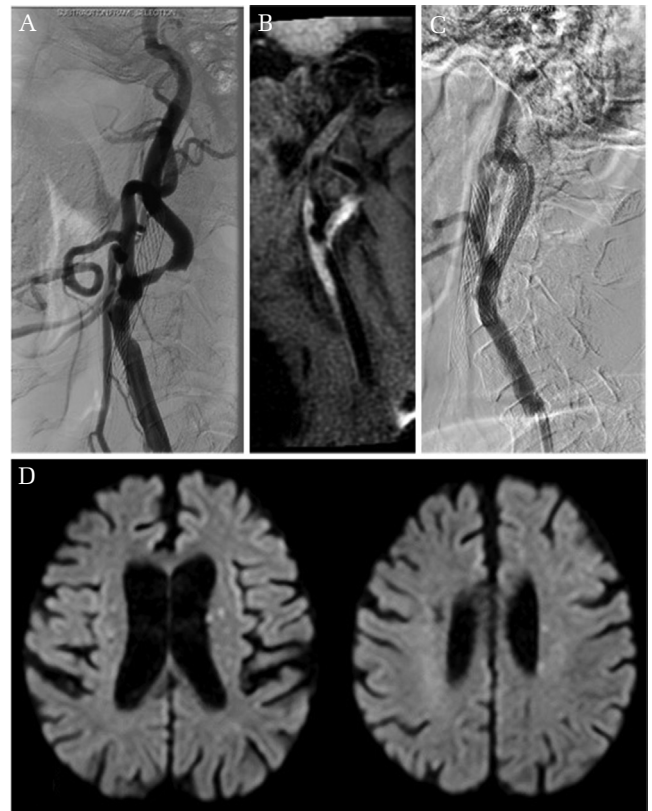


Fig. 3 Case 2: (A) Preoperative angiography reveals severe stenosis in the left internal carotid artery. (B) Preoperative carotid plaque imaging by MRI shows unstable plaque. (C) Carotid artery stenting was performed using filter protection under local anesthesia. During the procedure, disturbance of consciousness and conjugate deviation of the eyes to the left were observed. (D) Postoperative MRI reveals multiple cerebral infarctions.

disease. Preoperative radiological imaging revealed ICAS with unstable plaque, with the distal portion at the C2 body level (Figs. 3A and 3B) and stenosis of the petrous portion of the contralateral internal carotid artery. He was assessed as both a CEA high-risk patient because of the high position of the plaque and comorbidity and a CAS high-risk patient because of the unstable plaque. The high position of the plaque and comorbidity in CEA posed a higher treatment risk than the unstable plaque in CAS. CAS was performed using filter protection under local anesthesia (Fig. 3C). During the procedure, disturbance of consciousness and conjugate deviation of the eyes to the left were observed, and post-operative MRI revealed multiple cerebral infarctions (Fig. 3D).

Discussion

The findings in this study demonstrated that the treatment selection based on plaque vulnerability

and the treatment risk evaluation could improve the treatment outcome, not only the perioperative stroke but also the systemic complications.

The Stenting and Angioplasty with Protection in Patients at High Risk for Endarterectomy trial revealed that CAS for patients at high risk for CEA was not inferior to CEA.²⁾ CAS had been performed for the patients with CEA high-risk, which were cardiopulmonary diseases, contralateral internal carotid artery occlusion, post-radiation therapy, high position and the insertion of Swan-Ganz catheter.^{2,18,21)} Because therapeutic devices and techniques of CAS have advanced, the Carotid Revascularization Endarterectomy vs. Stenting Trial indicated that CAS for patients at low risk for CEA could achieve the same results as CEA.⁵⁾ Therefore, CAS has been more frequently performed. In contrast, vulnerable plaque was reported as high risk of CAS.^{12,13)} Technological progressions allow a visualization of plaque vulnerability, which reveals that unstable plaques and plaque volumes were strongly associated with the cerebral embolic complications, and plaque vulnerability was regarded as more important than stenosis rate.^{11–13)} Moreover, the treatment selection based on plaque vulnerability decreased the perioperative cerebral ischemic complications, and it was recommended that the patients with unstable plaques are candidates for CEA.¹⁴⁾ In addition, some reports mentioned that plaque volumes, severe aortic valve stenosis, approach route, intraoperative hemodynamic instability, were associated with the treatment outcomes of CAS.^{9,22–24)} For these findings, it is reasonable to evaluate treatment risks and select the treatment.^{7,16)} Recently, CEA and CAS appear to be complementary treatments for ICAS with various risk factors.

We classified three groups, Stable, Unstable + CEA low-risk (Unstable/Low), and Unstable + CEA high-risk (Unstable/High), based on plaque vulnerability and the treatment risk evaluation, and compared the treatment outcome. This classification is thought to be ideal, although the treatment risk evaluation varies according to the experience and skills of the operators.¹⁷⁾ Moreover, the subjectivity of the operators is removed in this classification. The clinical problem is the treatment selection for the patients with unstable plaques and CEA high-risk.^{7,16)} About 42 of 49 patients (85.8%) in Unstable/High underwent CAS because there were few risks of CAS except the unstable plaque in comparison with a treatment risk of CEA. Seven patients underwent CEA, because CAS was higher risk than CEA. There were no statistically significant differences among three groups in this study. However, stroke in Unstable/High (8.2%) was slightly higher compared with previous reports

(2.8–9.8%).^{2,5)} Two of four strokes occurred in the Unstable/High group had intracranial hemorrhage due to the hyperperfusion syndrome. An impaired cerebrovascular reactivity is considered the main mechanism in hyperperfusion syndrome;²⁵⁾ therefore, intracranial hemorrhage does not seem to be associated with plaque vulnerability and the treatment risk evaluation. Those outcomes suggested that the treatment selection based on plaque vulnerability and the treatment risk evaluation could improve the treatment outcome, not only the perioperative stroke but also the systemic complications. These outcomes may have been observed because the double balloon may act as a protective factor for patients receiving CAS with unstable plaques. The double balloon protection was reported to be a method that reduces the risk of ischemic stroke after the procedure.²⁶⁾ A recent study reported the efficacy of a hybrid operation for the patients with CEA high-risk and CAS high-risk;²⁷⁾ therefore, a hybrid operation is thought to be a considerable treatment for those patients.

In this study, perioperative major adverse events were 5.0% (2.9% in CEA and 5.8% in CAS). This outcome is not inferior in comparison with the previous studies.^{1–5,8,28)} In our institute, the treatments for ICAS are selected by one neurovascular team, and operators performed both CEA and CAS. We understand the characteristics of each treatment well, so the treatment selection is thought to be less arbitrary. It is thought that the selection of the appropriate treatment led to the positive outcomes, even though the sample size is small compared with the reports from Europe and US.^{1–5,8)}

Patients with ICAS are older individuals and often have some past illnesses, so we sometimes experience the systemic complications, except for the cerebrovascular and cardiovascular disease after the operation. In this study, there were no significant differences among the groups. There is no report about the systemic complications after CEA or CAS. However, the treatment selection based on the treatment risk evaluations may have a good influence for the systemic complications.

The presence of unstable plaque and low risk for CEA was an indication for CEA in our strategy, but the proportion of patients who underwent CAS was approximately one-third. Several factors may have contributed to why our strategy did not agree with the actual treatment selection. First, we classified plaques as either unstable or stable, and did not consider plaque volume. The patients with a small amount of unstable plaque may have undergone CAS. Second, some patients were introduced from other hospitals for their preference for CAS.

There are some limitations in this study. There was a small sample size and this study was performed retrospectively. A prospective and large-scale study is necessary because the treatment of ICAS is changing into the era of combination with CEA and CAS. We did not objectively evaluate plaque properties or treatment risk. The range of treatment risks and treatment risk contents are variables for operators and institutes to consider. Moreover, we did not evaluate the plaque volume, although some studies reported that unstable plaque volume was associated with ischemic complications.

Conclusion

The treatment selection based on plaque vulnerability and the treatment risk evaluation could provide good treatment outcome for high-risk patients, not only the perioperative stroke but also the systemic complications. It is ideal to select an appropriate treatment for ICAS by one neurovascular team.

Conflicts of Interest Disclosure

YM received honoraria from Medtronic Japan and Stryker Japan for lecture fees. The other authors have no conflicts of interest. The authors registered online Self-reported COI Disclosure Statement Forms through the website for Japan Neurosurgical Society members.

References

- Mas JL, Chatellier G, Beyssen B, et al.; EVA-3S Investigators: Endarterectomy versus stenting in patients with symptomatic severe carotid stenosis. *N Engl J Med* 355: 1660–1671, 2006
- Yadav JS, Wholey MH, Kuntz RE, et al.; Stenting and Angioplasty with Protection in Patients at High Risk for Endarterectomy Investigators: Protected carotid-artery stenting versus endarterectomy in high-risk patients. *N Engl J Med* 351: 1493–1501, 2004
- SPACE Collaborative Group, Ringleb PA, Allenberg J, Brückmann H, et al.: 30 day results from the SPACE trial of stent-protected angioplasty versus carotid endarterectomy in symptomatic patients: a randomised non-inferiority trial. *Lancet* 368: 1239–1247, 2006
- International Carotid Stenting Study Investigators, Ederle J, Dobson J, Featherstone RL, et al.: Carotid artery stenting compared with endarterectomy in patients with symptomatic carotid stenosis (International Carotid Stenting Study): an interim analysis of a randomised controlled trial. *Lancet* 375: 985–997, 2010
- Brott TG, Hobson RW, Howard G, et al.; CREST Investigators: Stenting versus endarterectomy for treatment of carotid-artery stenosis. *N Engl J Med* 363: 11–23, 2010
- Brott TG, Halperin JL, Abbara S, et al.; American College of Cardiology Foundation/American Heart Association Task Force on Practice Guidelines; American Stroke Association; American Association of Neuroscience Nurses; American Association of Neurological Surgeons; American College of Radiology; American Society of Neuroradiology; Congress of Neurological Surgeons; Society of Atherosclerosis Imaging and Prevention; Society for Cardiovascular Angiography and Interventions; Society of Interventional Radiology; Society of NeuroInterventional Surgery; Society for Vascular Medicine; Society for Vascular Surgery; American Academy of Neurology and Society of Cardiovascular Computed Tomography: 2011 ASA/ACCF/AHA/AANN/AANS/ACR/ASNR/CNS/SAIP/SCAI/SIR/SNIS/SVM/SVS guideline on the management of patients with extracranial carotid and vertebral artery disease: executive summary. *Stroke* 42: e420–e463, 2011
- Abbott AL, Paraskevas KI, Kakkos SK, et al.: Systematic review of guidelines for the management of asymptomatic and symptomatic carotid stenosis. *Stroke* 46: 3288–3301, 2015
- Bonati LH, Dobson J, Featherstone RL, et al.; International Carotid Stenting Study Investigators: Long-term outcomes after stenting versus endarterectomy for treatment of symptomatic carotid stenosis: the International Carotid Stenting Study (ICSS) randomised trial. *Lancet* 385: 529–538, 2015
- Fanous AA, Natarajan SK, Jowdy PK, et al.: High-risk factors in symptomatic patients undergoing carotid artery stenting with distal protection: Buffalo Risk Assessment Scale (BRASS). *Neurosurgery* 77: 531–542; discussion 542–543, 2015
- Sundt TM, Whisnant JP, Houser OW, Fode NC: Prospective study of the effectiveness and durability of carotid endarterectomy. *Mayo Clin Proc* 65: 625–635, 1990
- Brinjikji W, Huston J, Rabinstein AA, Kim GM, Lerman A, Lanzino G: Contemporary carotid imaging: from degree of stenosis to plaque vulnerability. *J Neurosurg* 124: 27–42, 2016
- Tanemura H, Maeda M, Ichikawa N, et al.: High-risk plaque for carotid artery stenting evaluated with 3-dimensional T1-weighted gradient echo sequence. *Stroke* 44: 105–110, 2013
- Yamada K, Yoshimura S, Kawasaki M, et al.: Embolic complications after carotid artery stenting or carotid endarterectomy are associated with tissue characteristics of carotid plaques evaluated by magnetic resonance imaging. *Atherosclerosis* 215: 399–404, 2011
- Yoshimura S, Yamada K, Kawasaki M, et al.: Selection of carotid artery stenting or endarterectomy based on magnetic resonance plaque imaging reduced periprocedural adverse events. *J Stroke Cerebrovasc Dis* 22: 1082–1087, 2013

- 15) Liapis CD, Bell PR, Mikhailidis D, et al.; ESVS Guidelines Collaborators: ESVS guidelines. invasive treatment for carotid stenosis: indications, techniques. *Eur J Vasc Endovasc Surg* 37: 1–19, 2009
- 16) Rogers RK, Bishu K: Optimal treatment of extracranial carotid artery disease: carotid endarterectomy, carotid stenting, or optimal medical therapy. *Curr Cardiol Rep* 17: 84, 2015
- 17) Sato K, Suzuki S, Yamada M, et al.: Selecting an appropriate surgical treatment instead of carotid artery stenting alone according to the patient's risk factors contributes to reduced perioperative complications in patients with internal carotid stenosis: a single institutional retrospective analysis. *Neurol Med Chir (Tokyo)* 55: 124–132, 2015
- 18) Iihara K, Murao K, Sakai N, Yamada N, Nagata I, Miyamoto S: Outcome of carotid endarterectomy and stent insertion based on grading of carotid endarterectomy risk: a 7-year prospective study. *J Neurosurg* 105: 546–554, 2006
- 19) North American Symptomatic Carotid Endarterectomy Trial Collaborators, Barnett HJM, Taylor DW, Haynes RB, et al.: Beneficial effect of carotid endarterectomy in symptomatic patients with high-grade carotid stenosis. *N Eng J Med* 325: 445–453, 1991
- 20) Saam T, Ferguson MS, Yarnykh VL, et al.: Quantitative evaluation of carotid plaque composition by in vivo MRI. *Arterioscler Thromb Vasc Biol* 25: 234–239, 2005
- 21) Yoshida K, Ogasawara K, Kobayashi M, Tsuboi J, Okabayashi H, Ogawa A: Scar formation in the carotid sheath identified during carotid endarterectomy in patients with previous cardiac surgery: significance of history of intraoperative Swan-Ganz catheter insertion. Clinical article. *J Neurosurg* 113: 885–889, 2010
- 22) Ikeda G, Tsuruta W, Nakai Y, et al.: Anatomical risk factors for ischemic lesions associated with carotid artery stenting. *Interv Neuroradiol* 20: 746–754, 2014
- 23) Kar S, Krishnaswamy A, Shishehbor MH, et al.: Safety and efficacy of carotid stenting in individuals with concomitant severe carotid and aortic stenosis. *EuroIntervention* 6: 492–497, 2010
- 24) Ito Y, Kato N, Matsumura A, Sonobe M: Hemodynamic instability increases new ischemic brain lesions on diffusion-weighted imaging after carotid artery stenting. *Neurol Med Chir (Tokyo)* 53: 375–380, 2013
- 25) Hosoda K, Kawaguchi T, Shibata Y, et al.: Cerebral vasoreactivity and internal carotid artery flow help to identify patients at risk for hyperperfusion after carotid endarterectomy. *Stroke* 32: 1567–1573, 2001
- 26) Nakazaki M, Nonaka T, Takahashi A, et al.: Double balloon protection during carotid artery stenting for vulnerable carotid stenosis reduces the incidence of new brain lesions. *Acta Neurochir (Wien)* 158: 1377–1386, 2016
- 27) Zhang L, Xing T, Geng F, Du L, Wang J: Preliminary application of hybrid operation in the treatment of carotid artery stenosis in patients with complex ischemic cerebrovascular diseases. *Int J Clin Exp Pathol* 7: 5355–5362, 2014
- 28) Zhang L, Zhao Z, Ouyang Y, et al.: Systematic review and meta-analysis of carotid artery stenting versus endarterectomy for carotid stenosis: a chronological and worldwide study. *Medicine (Baltimore)* 94: e1060, 2015

Address reprint requests to: Yoshiro Ito, MD, Department of Neurosurgery, Institute of Medicine, University of Tsukuba, 1-1-1 Tennodai, Tsukuba, Ibaraki 305-8575, Japan.
e-mail: yoshiro@apr.email.ne.jp