

## C A S E R E P O R T

# Hypercalcemia and acute pancreatitis in a male patient with acute promyelocytic leukemia and pulmonary tuberculosis

*Ali S Abdullah<sup>1</sup>, Ahmad M Adel<sup>2</sup>, Radwa M Hussein<sup>2</sup>, Mohammed AJ Abdullah<sup>3</sup>, Anil Yousaf<sup>3</sup>, Deena Mudawi<sup>3</sup>, Shehab F Mohamed<sup>3</sup>, Abdulqadir J. Nashwan<sup>4</sup>, Dina Soliman<sup>5</sup>, Feryal Ibrahim<sup>6</sup>, Mohamed A Yassin<sup>3</sup>*

<sup>1</sup> Resident, Internal Medicine, Hamad Medical Corporation (HMC), Doha, Qatar; <sup>2</sup> Pharmacists, Department of Pharmacy, NCCCR, Hamad Medical Corporation (HMC), Doha, Qatar; <sup>3</sup> Hematologists, Department of Hematology, NCCCR, Hamad Medical Corporation (HMC), Doha, Qatar; <sup>4</sup> Nurse Research Scientist, Cancer Clinical Trials Unit, NCCCR, Hamad Medical Corporation (HMC), Doha, Qatar; <sup>5</sup> Department of Laboratory Medicine and Pathology, National Center for Cancer Care and Research, Hamad Medical Corporation (HMC), Doha, Qatar and Department of Clinical Pathology, National Cancer Institute, Cairo University, Cairo, Egypt; <sup>6</sup> Consultant Hematopathologist Department of Laboratory Medicine and Pathology, National Center for Cancer Care and Research, Hamad Medical Corporation (HMC), Doha, Qatar

**Summary.** We report a rare case of hypercalcemia and acute pancreatitis in a subject with acute promyelocytic leukemia (APL) and pulmonary tuberculosis, during all-trans-retinoic acid (ATRA) treatment. Both associated complications were potentially due to several causes. A careful monitoring and exclusion of all causative factors must be addressed. Further research is necessary to improve our understanding of risk factors for these complications in patients with (APL). Studying these patterns may help us to improve outcomes for all children and young adults with hematologic malignancies. ([www.actabiomedica.it](http://www.actabiomedica.it))

**Key words:** acute promyelocytic leukemia, pulmonary tuberculosis, all-trans-retinoic acid (ATRA), hypercalcemia, acute pancreatitis

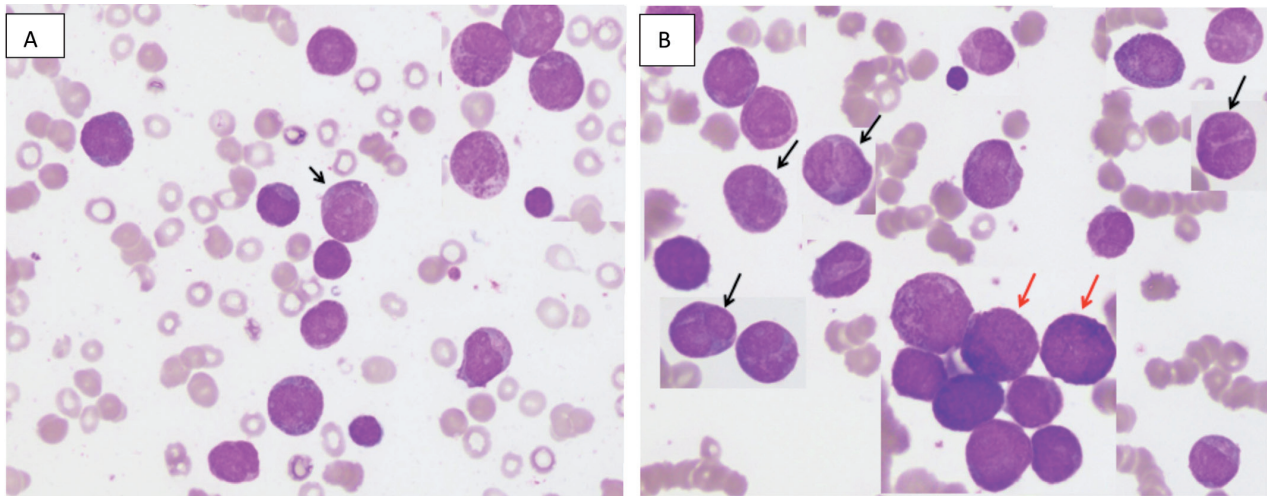
## Introduction

Acute promyelocytic leukemia (APL) is subtype of acute myeloid leukemia (AML). It represents 10% to 15% of all adult AML cases. APL is characterized by a balanced reciprocal translocation between chromosomes 15 and 17, which generates a fusion transcript joining the PML (*promyelocytic leukemia*) and RARA (*retinoic acid receptor- $\alpha$* ) genes. All-trans-retinoic acid (ATRA) has been successfully used in the treatment of APL (1, 2).

Herein, we report a rare case of hypercalcemia and acute pancreatitis in a subject with APL and pulmonary tuberculosis, during ATRA treatment.

## Case presentation

A 49-year-old Bangladeshi man diagnosed with APL presented with 3 days history of fever, dry cough and blurring of vision. His clinical examination revealed no obvious source of infection. The hemogram showed: white blood cells (WBCs)  $18 \times 10^3/\mu\text{L}$  (normal values: 4.0-10.0), hemoglobin (Hb) 6.7 gm/dL (normal values: 12.0-15.0), platelets count  $24 \times 10^3/\mu\text{L}$  (normal values: 150-400), prothrombin time (PT) 16.2 seconds (normal values: 9.4-12.5), activated partial thromboplastin time (aPTT) 30.8 seconds (normal values: 25.1-36.5), fibrinogen level: 5.1 gm/L (normal values: 2-4.1). The peripheral blood smear and the bone marrow aspirate are shown in figure 1 and were consistent with the diagnosis of acute promyelocytic



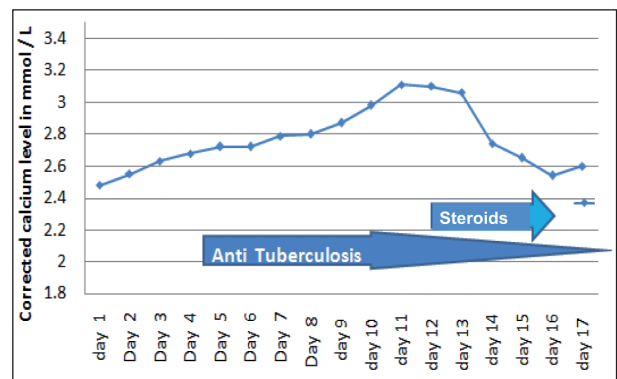
**Figure 1.** (A) Peripheral blood smear shows many circulating leukemic promyelocytes with few Faggot cells (black arrow) 100X. (B) Bone marrow aspirate infiltrated with many leukemic promyelocytes ranging from hypergranular (red arrows) to hypogranular forms with bilobed/dumb bell shaped (black arrows) 100X. Findings consistent with acute promyelocytic leukemia (APL)

leukemia (APL). Therefore, the patient was treated with PETHEMA protocol consisting of ATRA plus Idarubicin (8).

During the treatment he developed febrile neutropenia and right sided pleural effusion. Acid-Fast Bacilli (AFB) smear and culture from pleural fluid were negative. Patient underwent bronchoscopy and bronchoalveolar lavage (BAL). AFB resulted negative while aspergillus galactomannan testing was positive. The result was suggestive for a diagnosis of invasive aspergillosis and the patient was empirically treated with Voriconazole. For the persistence of the fever a lung biopsy was requested. An epithelioid granulomatous inflammation with focal necrosis, consistent with tuberculosis, was histologically present. After anti-TB treatment the patient fever subsided.

On day 5 of the hospital admission, the patient developed an asymptomatic hypercalcemia (corrected serum calcium level from 2.63 to 3.11 mmol/L - normal values: 2.1-2.6). Parathyroid hormone (PTH) level was normal and vitamin D level below the normal range (<3 pg/mL, normal values: 15-65 and 21 ng/mL, normal values: 30-80, respectively).

An adequate intravenous (i.v.) hydration and oral prednisolone (30 mg once a day) were given. Serum calcium level progressively dropped down to normal values on day 16 (Figure 2). Meanwhile, the patient



**Figure 2.** Corrected calcium level before and after treatment with i.v. idratation and oral steroids

developed constipation and left upper quadrant abdominal pain. Pancreatic serum enzymes resulted: lipase 260 U/L (normal values: 13-60) and amylase 56 U/L (normal values: 13-53). Both enzymes returned to normal values after 2 days of hydration and analgesia. The lipid profile and electrolyte levels were within the normal lab. ranges.

## Discussion

APL is a distinctive subtype of AML. APL is described by reciprocal translocation between chromo-

somes 15 and 17, which results in the fusion of the promyelocytic leukemia (PML) gene and the retinoic acid receptor  $\alpha$  (RAR $\alpha$ ). With advancement in treatment, including the introduction of ATRA initially as a single agent and later in combination with anthracyclines, and more recently by expansion of arsenic trioxide (ATO)-containing regimens, APL is currently considered a curable disease with complete remission rates of 90% and cure rates of ~80% (5).

AML may be associated with several complications including bleeding, disseminated intravascular coagulation (DIC), hyper-leukocytosis, infections occurring mainly when the patient is a neutropenic state. Complications arising from infection are the leading cause of death in patients with AML (6).

Infections represent a common complication of chemotherapy in AML patients and may lead to treatment discontinuation. Little is known about the management of APL in patients with tuberculosis infection. TB is endemic in many countries in Asia, North Africa and Middle East (7). Treatment of TB can be a dilemma in patient with acute leukemia as some anti-tuberculosis medication interacts with chemotherapy.

Our patient probably had an impaired immune response due to treatment that caused reactivation of a latent focus of tuberculosis (TB). Possible relationships between TB and blood dyscrasias can include: (a) activation and dissemination of latent TB focus due to loss of immune mechanism, particularly, cell-mediated immunity in bone marrow failure and leukemia; (b) blood dyscrasias might be an unusual immunological response to tubercle bacilli (8).

Our patient in the course of treatment developed two complications: hypercalcaemia and acute pancreatitis.

Hypercalcemia is defined as a serum calcium concentration that is greater than two standard deviations above the normal mean, which in adults is usually an ionized calcium above ~1.32 mmol/L (normal range, 1.16 to 1.32 mmol/L) and a total serum calcium, which comprises 55% to 60% ionized calcium plus 40% to 45% protein-bound (mainly to albumin) calcium, of ~2.60 mmol/L (normal range, 2.20 to 2.60 mmol/L, 8.5 to 10.5 mg/dL) (9-11).

Many diseases and drugs can cause hypercalcaemia, including hyperparathyroidism, malignancy, mul-

tiples myeloma, thyrotoxicosis, thiazide diuretic, supplements containing calcium, vitamin D intoxication, infections and granulomatous diseases (9-11).

In our patient the normal serum PTH concentration precluded the possibility of primary hyperparathyroidism or ectopic PTH secretion as a cause of hypercalcemia.

Haematological malignancies usually are not so commonly associated with hypercalcemia except in those cases of high tumour overload with high proliferative index.

Therefore, hypercalcemia could be also a manifestation of pulmonary TB even though it is rare. Mechanism of hypercalcemia in TB is considered to be due to the extra-renal production of 1,25(OH) $_2$ D $_3$  by alveolar macrophages and T lymphocytes possibly CD8 T lymphocytes and hence, limiting oral Vitamin D and calcium supplements is one of the major interventions in the treatment (12). Furthermore, it is known that bacterial infections can cause bone destruction resulting from the over-generation of osteoclasts. Inflammatory cytokines such as TNF-alpha, IL-1, IL-6 act by stimulating the RANKL receptor present in the osteoblast. This, in turn, couples with the RANK present in the pro-osteoclast, which becomes a mature osteoclast, promoting bone resorption with increased calcemia (13).

Moreover, some case reports describing hypercalcemia associated with APL have been reported in the literature (12-17). Multiple mechanisms of hypercalcemia secondary to ATRA therapy have been proposed, such as:

1. Direct effect of ATRA leading to enhanced osteoclastic activity leading to bone mineral resorption (17).
2. ATRA has been found to cause hypercalcemia via increasing PTH levels (12).
3. ATRA metabolism involves liver cytochrome P450 subtypes 2C9 and 3A4. Many drugs, especially anti-fungals are inhibitors (such as voriconazole used in our patient) of these enzymes causing increased plasma concentration of ATRA thereby potentiating the effect of ATRA on calcium metabolism (18).

In our patient, ATRA was not discontinued; i.v. hydration and corticosteroids were administered for 5

days with the normalization of serum calcium level.

The diagnosis of acute pancreatitis (AP) is most often established by the presence of two of the three following criteria: (i) abdominal pain consistent with the disease, (ii) serum amylase and/or lipase greater than three times the upper limit of normal, and/or (iii) characteristic findings from abdominal imaging.

Acute pancreatitis (AP) refers to inflammation of the pancreas, causing sudden and severe abdominal pain. There are many possible underlying causes of acute pancreatitis, but 60% to 75% of all cases are caused by gallstones or alcohol abuse. Other uncommon causes of AP include: metabolic disorders such as hyperlipidemia, hypercalcemia and medications. Idiopathic AP is defined as acute pancreatitis with no etiology established after initial laboratory (including lipid and calcium level) and imaging tests (trans-abdominal ultrasound, MRI and CT in the appropriate patient) (19). These patients do not have gallstones, or significant history of alcohol use, hypertriglyceridemia and a tumor.

The diagnosis of AP is most often established by the presence of two of the three following criteria: (i) abdominal pain consistent with the disease, (ii) serum amylase and/or lipase greater than three times the upper limit of normal, and / or (iii) characteristic findings from abdominal imaging (20).

The two most common causes of AP in general population, namely, alcohol and common bile duct obstruction by gallstone are not applicable here. However, our patient had 3 risk factors for developing AP: tumor, hypercalcemia and ATRA treatment.

AP is a rare adverse event in APL, which is primarily reported to be secondary to hypertriglyceridemia. ATRA-related AP has been previously reported by different authors (21,22). In all these cases, patients had hypertriglyceridemia. However, few case reports also described development of AP without hypertriglyceridemia (23).

In conclusion, this case shows a rare presentation of hypercalcemia and AP in a patients with APL and pulmonary tuberculosis, during ATRA treatment. Both associated complications are potentially due to several etiologic factors. Therefore, a careful monitoring and exclusion of all causative factors must be addressed. Further research is necessary to improve our

understanding of risk factors for these complications in patients with APL. Studying these patterns may help us to improve outcomes for all children and young adults with haematologic malignancies.

## References

1. Tallman MS, Altman JK. How I treat acute promyelocytic leukemia. *Blood* 2009;114: 5126-135.
2. de The H, Chen Z. Acute promyelocytic leukaemia: novel insights into the mechanisms of cure. *Nat Rev Cancer* 2010; 10: 775-783.
3. Hisatake J, Shimozuma J. Hypercalcemia associated with all-trans retinoic acid therapy for microgranular type acute promyelocytic leukemia. *Rinsho Ketsueki* 2008; 49: 408-412.
4. Sanz M. Risk-adapted treatment of acute promyelocytic leukemia with all-trans-retinoic acid and anthracycline monotherapy: a multicenter study by the PETHEMA group. *Blood* 2003; 103: 1237-1243.
5. Girmenia C, Lo Coco F, Breccia M, Latagliata R, Spadea A, D'Andrea M, Gentile G, Micozzi A, Alimena G, Martino P, Mandelli F. Infectious complications in patients with acute promyelocytic leukaemia treated with the AIDA regimen. *Leukemia* 2003; 17: 925-930.
6. Hou J, Wang S, Zhang Y, Fan D, Li H, Yang Y, Ge F, Hou W, Fu J, Wang P, Zhao H, Sun J, Yang K, Zhou J, Li X. Causes and prognostic factors for early death in patients with acute promyelocytic leukemia treated with single-agent arsenic trioxide. *Ann Hematol* 2017; 96: 2005-2013.
7. World Health Organization. Tuberculosis country profiles. Available at: <http://www.who.int/tb/country/data/profiles/en/> [Accessed 19 Nov. 2017].
8. Coburn RJ, England JM, Samson DM, Walford DM, Blowers R, Chanarin I, Levi AJ, Slavin G. Tuberculosis and blood disorders. *Br J Haematol* 1973; 25: 793-799.
9. Stokes VJ, Nielsen MF, Hannan FM, Thakker RV. Hypercalcemic Disorders in Children. *J Bone Miner Res* 2017; 32: 2157-2170.
10. Payne RB, Little AJ, Williams RB, Milner JR. Interpretation of serum calcium in patients with abnormal serum proteins. *BMJ*. 1973; 4:643-646.
11. Reynolds BC, Cheetham TD. Bones, stones, moans and groans: hypercalcaemia revisited. *Arch Dis Child Educ Pract* 2015; 100: 44-51.
12. Cadranel J, Garabedian M, Milleron B, Guillozo H, Akoun G, Hance AJ. 1,25(OH) 2D2 production by T lymphocytes and alveolar macrophages recovered by lavage from normocalcemic patients with tuberculosis. *J Clin Invest* 1990; 85: 1588-1593.
13. Kim J, Yang J, Park OJ, Kang SS, Kim WS, Kurokawa K, et al. Lipoproteins are an important bacterial component responsible for bone destruction through the induction of



- osteoclast differentiation and activation. *J Bone Miner Res* 2013; 28: 2381-2391.
14. Cordoba R, Ramirez E, Lei SH, Lopez de la Guia A, Sanjurjo MJ, Carcas AJ, Hernandez-Navarro F. Hypercalcemia due to an interaction of all-trans retinoic acid (ATRA) and itraconazole therapy for acute promyelocytic leukemia successfully treated with zoledronic acid. *Eur J Clin Pharmacol* 2008; 64: 1031-1032.
  15. Sakamoto O, Yoshinari M, Rikiishi T, Fujiwara I, Imaizumi M, Tsuchiya S, Iinuma K. Hypercalcemia due to all-trans retinoic acid therapy for acute promyelocytic leukemia: a case report of effective treatment with bisphosphonate. *Pediatr Int* 2001; 43: 688-690.
  16. Teng HW, Bai LY, Chao TC, Wang WS, Chen PM. Acute pancreatitis during all-trans-retinoic acid treatment for acute promyelocytic leukemia in a patient without overt hypertriglyceridemia. *Jpn J Clin Oncol* 2005; 35: 94-96.
  17. Sakakibara M, Ichikawa M, Amano Y, Matsuzawa S, Age-matsu K, Mori T, Koike K, Nakahata T, Komiyama A. Hypercalcemia associated with all-trans-retinoic acid in the treatment of acute promyelocytic leukemia. *Leuk Res* 1993; 17: 441-443.
  18. Bennett MT, Sirrs S, Yeung JK, Smith CA. Hypercalcemia due to all trans retinoic acid in the treatment of acute promyelocytic leukemia potentiated by voriconazole. *Leuk Lymphoma* 2005; 46: 1829-1831.
  19. Al-Haddad M, Wallace MB. Diagnostic approach to patients with acute idiopathic and recurrent pancreatitis, what should be done? *World J Gastroenterol* 2008; 14: 1007-1010.
  20. Tenner S, Baillie J, DeWitt J, Vege SS; American College of Gastroenterology. American College of Gastroenterology guideline: management of acute pancreatitis. *Am J Gastroenterol* 2013; 108: 1400-1415.
  21. Abou Chacra L, Ghosn M, Ghayad E, Honein K. A case of pancreatitis associated with all-trans-retinoic acid therapy in acute promyelocytic leukemia. *Hematol J* 2001; 2: 406-407.
  22. Izumi T, Hatake K, Miura Y. Acute promyelocytic leukemia. *N Engl J Med* 1994; 330: 141.
  23. Teng HW, Bai LY, Chao TC, Wang WS, Chen PM. Acute pancreatitis during all-trans-retinoic acid treatment for acute promyelocytic leukemia in a patient without overt hypertriglyceridemia. *Jpn J Clin Oncol* 2005; 35: 94-96.
- 
- Received: 11 January 2018  
Accepted: 8 February 2018  
Correspondence: Mohamed A Yassin, MD  
Department of Medical Oncology, Hematology Section  
National Center for Cancer Care and Research  
Hamad Medical Corporation  
Doha, Qatar  
Tel. 55037393  
E-mail: yassinmoha@gmail.com