

# Five Years' Outcomes of Trabeculectomy with Cross-linked Sodium Hyaluronate Gel Implantation for Chinese Glaucoma Patients

Xiao Wang<sup>1,2</sup>, Wan-Wei Dai<sup>1,2</sup>, Ya-Long Dang<sup>3</sup>, Ying Hong<sup>1,4</sup>, Chun Zhang<sup>1,4</sup>

<sup>1</sup>Department of Ophthalmology, Peking University Third Hospital, Beijing 100191, China

<sup>2</sup>Institute of Population Research/World Health Organization Collaborating Center, Peking University, Beijing 100871, China

<sup>3</sup>Department of Ophthalmology, University of Pittsburgh School of Medicine, Pittsburgh, PA 15213, USA

<sup>4</sup>Beijing Key Laboratory for Restoration of Damaged Ocular Nerve, Peking University Third Hospital, Beijing 100191, China

## Abstract

**Background:** Trabeculectomy is the most efficient surgical treatment. Prevention failure of bleb cicatrix would lead to unsatisfactory postoperative intraocular pressure (IOP) controlling and unsatisfactory success rate. The aim of this study was to evaluate the 5-year outcomes of trabeculectomy with a cross-linked sodium hyaluronate gel implantation for Chinese glaucoma patients.

**Methods:** This is a prospective, case-controlled study. Patients who were to be applied first-time trabeculectomy in the Department of Ophthalmology of Peking University Third Hospital between 2010 and 2012 were included in the study. Totally, 60 eyes were randomly assigned to the trabeculectomy group (TA group) or the trabeculectomy with cross-linked sodium hyaluronate gel implantation group (TH group). Follow-up was finished at 1 week, 1 month, 3 months, 1 year, 3 years, and 5 years after the operation. The statistical index of demographic data, IOP, bleb shape, and any complications or medications or surgical procedures were recorded and assessed by SPSS 19.0 software through independent *t*-test, one-way analysis of variance (ANOVA) and Pearson's Chi-square test, respectively.

**Results:** The baseline IOP was comparable between the two groups ( $t = -1.00$ ,  $P = 0.32$ ) while the postoperative IOP was significantly lower in the TH group at 1, 3 and 5 years' time points ( $P = 0.00$ ,  $P = 0.01$  and  $P = 0.01$ , respectively). According to the Indiana Bleb Appearance Grading Scale, the height and extent of bleb were better in the TH group at all follow-up time points ( $P < 0.05$ ), however, the comparison of bleb vascularity showed no statistical difference ( $P > 0.05$ ). TA group had a higher percentage of complications (13% vs. 3%) compared to TH group; however, there was no statistical difference in the comparison of each statistical item ( $P > 0.05$ , respectively). The complete success at 5 years was higher in the TH group than that in the TA group (78% vs. 54%,  $P = 0.03$ ).

**Conclusion:** Our results suggested that implantation of cross-linked sodium hyaluronate gel with trabeculectomy was more efficient and would improve the prognosis of glaucoma patients.

**Key words:** Cicatrix; Cross-linked Sodium Hyaluronate; Glaucoma; Trabeculectomy

## INTRODUCTION

Glaucoma is characterized by progressive optic nerve damage and visual field defect.<sup>[1]</sup> Vision loss in glaucoma resulting from retinal ganglion cell death is triggered by orbital cerebrospinal fluid pressure.<sup>[2]</sup> Even though neuroprotection strategy has been developed,<sup>[3,4]</sup> lowering intraocular pressure (IOP) is currently the most effective way to prevent the progression of glaucomatous optic neuropathy. A previous study showed that each mmHg (1 mmHg = 0.133 kPa) of IOP reduction would decrease the risk of optic nerve damage by approximately 10%.<sup>[5]</sup>

IOP management for glaucoma patients includes anti-glaucoma medication, laser therapy, needling procedures, and filtering surgery (or tube shunt implantation). Till now,

**Address for correspondence:** Prof. Chun Zhang,  
Department of Ophthalmology, Peking University Third Hospital,  
Peking University, Beijing 100191, China  
E-Mail: zhangc1@yahoo.com

This is an open access journal, and articles are distributed under the terms of the Creative Commons Attribution-NonCommercial-ShareAlike 4.0 License, which allows others to remix, tweak, and build upon the work non-commercially, as long as appropriate credit is given and the new creations are licensed under the identical terms.

**For reprints contact:** reprints@medknow.com

© 2018 Chinese Medical Journal | Produced by Wolters Kluwer - Medknow

**Received:** 28-04-2018 **Edited by:** Ning-Ning Wang  
**How to cite this article:** Wang X, Dai WW, Dang YL, Hong Y, Zhang C. Five Years' Outcomes of Trabeculectomy with Cross-linked Sodium Hyaluronate Gel Implantation for Chinese Glaucoma Patients. Chin Med J 2018;131:1562-8.

Access this article online

Quick Response Code:



Website:  
www.cmj.org

DOI:  
10.4103/0366-6999.233655

trabeculectomy is still the most efficient option for those with progressive glaucoma.<sup>[6]</sup> Cicatrix is the major cause of postoperative bleb failure and significantly affects the long-term success rate of trabeculectomy.<sup>[7-10]</sup> The use of antimetabolic agents such as 5-fluorouracil and mitomycin C (MMC) has been widely accepted as the golden standard of trabeculectomy, apparently reducing the incidence of scar formation and enhancing bleb surviving rate. However, the postoperative scarring process of filtering bleb would always get worse and affect long-term success rate.<sup>[11]</sup> Moreover, they have many terrible complications with high incidence rate, such as infection, thin-walled bleb, irregular edema of epithelium, and toxic effects to eyes.<sup>[12]</sup> Bleb leakage would also exert bad influence on normal filtering function. Those possible side effects which could not be easily cured radically and prevented would finally affect postoperative visual function and success rate. Those antimetabolic agents' complications are unignorable and the dosage and local action time are to be controlled strictly during surgery. However, some other medical materials such as sodium hyaluronate are nonimmunogenicity, and intraoperative implantation would not be restricted by local action time strictly. Therefore, rich experience in antimetabolic drug usage of ophthalmologist and prudent attitude are in great need which would increase difficulties in surgical technique learning. As a result, developing more efficient anti-scarring method for trabeculectomy has always been a clinical need.

Previous studies have shown that cross-linked sodium hyaluronate gel may have antifibrotic effects in trabeculectomy.<sup>[13-16]</sup> Other studies have also suggested that intraoperative implantation of sodium hyaluronate gel may prevent bleb scarring, fibrosis, adhesion and improve IOP.<sup>[17-20]</sup> However, limited randomized and case-controlled studies have been conducted to investigate the long-term outcomes of cross-linked sodium hyaluronate gel applied in trabeculectomy in patients with glaucoma.

## METHODS

### Ethical approval

This was a prospective, case-controlled study which had been approved by the Medical Ethics Committee of Peking University Third Hospital (No. 09-70, Nimo10-01-13) in compliance with the *Declaration of Helsinki*. All participants were informed of the whole surgical procedure and signed informed consent.

### Subjects

Glaucoma patients without prior intraocular surgeries were included and neovascular glaucoma were excluded from the study. All patients were enrolled at the Department of Ophthalmology of Peking University Third Hospital between 2010 and 2012. The patients were randomly assigned to the traditional trabeculectomy group (TA group) and the trabeculectomy with cross-linked hyaluronate gel implantation group (TH group). Random grouping number table was used as simple randomization.

## Trabeculectomy with cross-linked sodium hyaluronate implantation

Standard trabeculectomy was performed as previously described.<sup>[21,22]</sup> In brief, we made fornix-based conjunctival flap at 12 o'clock and a half-thickness sclera flap in 2 mm × 3 mm and then removed 1 mm × 2 mm corneal-sclera tissues and performed iridectomy. The scleral incision was sutured finally. For the TH group, 0.02 ml and 0.1 ml of 2.25% cross-linked sodium hyaluronate gel (HealaFlow, Anteis SA, Geneva, Switzerland) were injected under the scleral flap and the conjunctiva respectively before the closure of incisions. For the TA group, only standard trabeculectomy procedure was performed.

### Outcome evaluations

All the patients were followed up at 1-week, 1-month, 3-month, 1-year, 3-year, and 5-year postoperation. IOP, bleb shape, and best-corrected visual acuity were observed. Any complication or add-on remedial anti-glaucoma medications or procedures were recorded. The primary measurement objective was the IOP reduction. The secondary outcomes included reduction of glaucoma medication, bleb formation change, and surgical complications. Bleb formation was evaluated by Indiana Bleb Appearance Grading Scale (IBAGS).<sup>[23]</sup>

### Statistical analysis

Statistics were performed by SPSS 19.0 software (SPSS Inc. Chicago, IL, USA). Independent *t*-test and one-way analysis of variance (ANOVA) were used to evaluate the IOPs and numbers of glaucoma medication between the TH group and the TA group. Pearson's Chi-square test was used for demographic data.

The complete success was defined as IOP lower than 21 mmHg with no remedial glaucoma medication. Meanwhile, the qualified success was defined as IOP lower than 21 mmHg with glaucoma medication. Secondary glaucoma surgery was not included in the success rate investigation. Kaplan-Meier survival analysis was performed to calculate the 5-year success rate. All quantitative data were presented as mean ± standard deviation (SD). A *P* < 0.05 was considered statistically significant.

## RESULTS

### Demographics

A total of 60 cases were enrolled in this study, of which 30 cases in the TH group and 30 cases in the TA group accomplished the 5-year follow-up. The age, gender, and diagnosis between the two groups showed no statistical difference (all *P* > 0.05). About 90% of the patients in TA group and 83% of the patients in TH group were primary glaucoma [Table 1]. The number of cases of each follow-up time point in the TA group was 30, 29, 27, 27, 22, and 19 and that of the TH group was 30, 30, 29, 26, 23, and 21, respectively. The percentage of loss to follow-up was 33% (20 cases). The comparison of loss to follow-up between

**Table 1: Baseline characteristics of the glaucoma patients**

Characteristics	TA group (n = 30)	TH group (n = 30)	t or $\chi^2$	P
Age (years)				
Mean $\pm$ SD	67.0 $\pm$ 13.0	65.0 $\pm$ 13.2	-1.00*	0.69
Range	46–82	54–79		
Gender, n (%)				
Female	13 (43.3)	14 (46.7)	0.07	0.80
Male	17 (56.7)	16 (53.3)		
OD/OS, n	14/16	12/18	0.27	0.60
Diagnosis, n (%)				
Primary open angle glaucoma	5 (16.7)	7 (23.3)	0.83	0.66
Primary angle closure glaucoma	20 (66.7)	20 (66.7)		
Secondary glaucoma	5 (16.7)	3 (10.0)		

\*: t value. TA: Trabeculectomy alone; TH: Trabeculectomy with hyaluronate gel; OD: Oculus dexter; OS: Oculus sinister; SD: Standard deviation.

the two groups at each time point showed no statistical difference ( $P > 0.05$ ). Fifteen cases (75%) of the 20 loss cases were for the reason of inconvenience of nonlocal residence. Reasons of loss to follow-up of another five cases were as follows: one bone fracture, one out of touch, one receiving heart stent, and two deaths.

### Intraocular pressure

The preoperative IOP in the TH group was comparable to that of the TA group (30.60  $\pm$  7.31 mmHg vs. 32.56  $\pm$  7.80 mmHg,  $t = -1.00$ ,  $P = 0.32$ ). Both groups experienced dramatic IOP reductions at all follow-up time points (all  $P < 0.05$ , compared to each baseline). However, the IOPs in the TH group were significantly lower than that of the TA group at the 1, 3, and 5 years ( $t = -3.46$ ,  $P = 0.00$ ;  $t = -2.72$ ,  $P = 0.01$ ;  $t = -2.58$ ,  $P = 0.01$ ) [Figure 1a].

### Medication

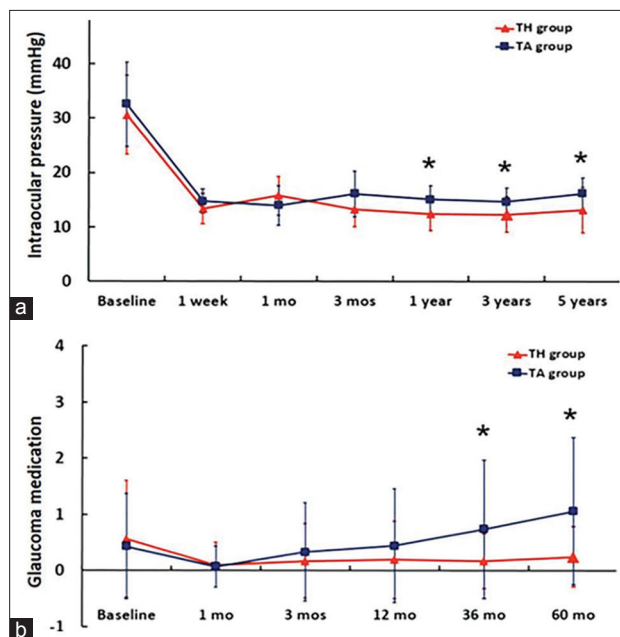
The baseline numbers of glaucoma medication between the two groups showed no statistically different (0.57  $\pm$  1.04 in the TH group vs. 0.43  $\pm$  0.94 in the TA group,  $P = 0.93$ ). However, the patients in the TH group had significantly less medication usage at the 3 and 5 years' time points, compared to the TA group ( $P = 0.01$  and  $P = 0.02$ , respectively) [Figure 1b].

### Bleb formation

The bleb formation was evaluated by one glaucoma specialist who used IBAGS.<sup>[23]</sup> The grading of bleb height and bleb extent in the TH group were significantly better at the 1, 3, and 5 years' time points (all  $P < 0.05$ ) while the bleb vascularization was similar in comparison with the TA group ( $P > 0.05$ ).

### Success rate investigation

The TH group had a higher complete success rate than the TA group. About 78% of patients in the TH group had postoperative IOP below 21 mmHg without glaucoma medication or secondary glaucoma surgery. Meanwhile, 54% of the TA group reached that goal at 5 years' time point ( $P = 0.03$ ) [Figure 2a]. However, the qualified success rate showed no statistical difference between TH and TA group (93% vs. 84%,  $P = 0.23$ ) [Figure 2b].



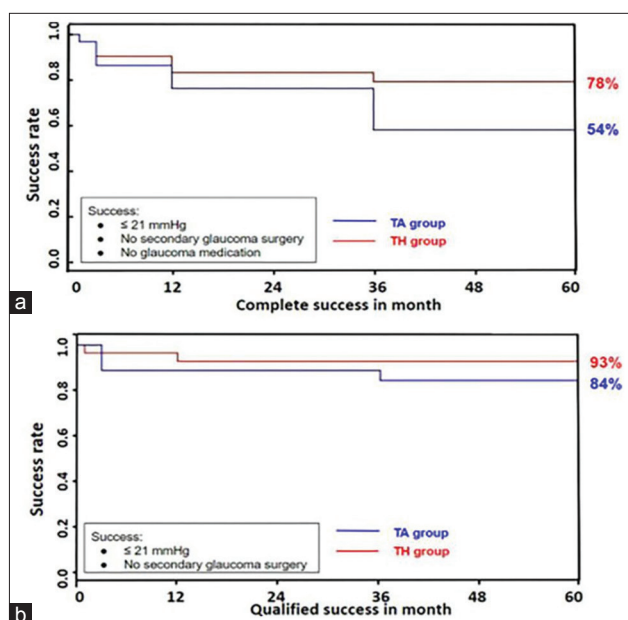
**Figure 1:** Reduction of IOP and glaucoma medications of the glaucoma patients. The changes of IOPs (a) and medicine required (b) between TH group and TA group. Number of cases at 1-week, 1-month, 3-month, 1-year, 3-year, and 5-year time point in the TA group was 30, 29, 27, 27, 22, 19 and that of the TH group was 30, 30, 29, 26, 23, 21, respectively. \* $P < 0.05$ . IOP: Intraocular pressure; TA: Trabeculectomy alone; TH: Trabeculectomy with hyaluronate gel.

### Complications and secondary glaucoma surgery

The statistics of surgical complications and secondary glaucoma surgery were summarized as well [Table 2]. A few complications were observed in both groups, and the TA group had higher percentage (13% vs. 3%); however, there was no statistical difference in the comparison of each statistical item of postoperative complications (all  $P > 0.05$ ). All complications were treated timely and effectively. No vision-threatening complication was encountered. Eight patients in the TA group required a bleb revision ( $n = 5$ ) or a secondary glaucoma surgery ( $n = 3$ ; two trabeculectomy and one transscleral cyclophotocoagulation). In contrast, only three patients in the TH group had remedial operations (two bleb revisions and one trabeculectomy).

## DISCUSSION

Cross-linked sodium hyaluronate gel is a non-animal origin, biodegradable sodium hyaluronate which has an excellent feature of anti-inflammation, anti-fibrosis without cytotoxicity. It was initially used for rheumatoid arthritis patients accompanied by knee osteoarthritis.<sup>[24,25]</sup> Recent studies suggested that the injection of cross-linked sodium hyaluronate gel under scleral flap and conjunctiva could inhibit the process of local fibrosis and vascularization and reduce the possibility of bleb failure, maintaining an effective filtration, and improving the long-term success rate of penetrating and nonpenetrating glaucoma surgeries.<sup>[15,20,26,27]</sup>



**Figure 2:** Five years' success rate of the glaucoma patients. The complete success without glaucoma medication (a) and the qualified success rate with glaucoma medication (b) between the TA group and the TH group. TH group had a higher complete success rate than TA group ( $P = 0.03$ ). The qualified success rate showed no statistical difference ( $P = 0.23$ ). Number of cases at 0, 12, 24, 36, 48, and 60 months in the TA group was 30, 27, 27, 22, 22, 19 and that of the TH group was 30, 26, 23, 23, 23, 21. TA: Trabeculectomy alone; TH: Trabeculectomy with hyaluronate gel.

In this prospective study, we compared the safety and efficiency of trabeculectomy with cross-linked sodium hyaluronate gel injection for Chinese glaucoma patients and followed up for 5 years. Our data indicated that both trabeculectomy alone and trabeculectomy with cross-linked sodium hyaluronate gel injection group witnessed efficient lowering of IOP, while the patients in the cross-linked sodium hyaluronate gel injection group achieved more IOP reduction at 1, 3, and 5 years after operation. In addition, the patients with cross-linked sodium hyaluronate gel injection had a better bleb formation and less consumption of glaucoma medications and higher 5-year success rate and fewer surgical complications, suggesting that trabeculectomy with cross-linked sodium hyaluronate gel injection is better than trabeculectomy alone. Our results suggested that implantation of cross-linked sodium hyaluronate gel with trabeculectomy is an efficient and a safe option for Chinese glaucoma patients which would improve postoperative prognosis.

As a kind of sodium hyaluronate gel, cross-linked sodium hyaluronate gel might benefit the outcomes of trabeculectomy from its anti-inflammatory effect. In an experimental dry eye model, 0.18% of sodium hyaluronate eye drop remarkably inhibited the interferon- $\gamma$  induced release of inflammatory factors, such as tumor necrosis factor- $\alpha$ , interleukin (IL)-1 $\beta$ , and reduced the percentages of CD4(+) CXCR3(+) cells in the conjunctiva.<sup>[28]</sup> In a double-blind and randomized clinical trial, Aragona *et al.*<sup>[29]</sup> also reported that sodium hyaluronate artificial tears reduced the ocular surface damage in patients with dry eye. Sodium hyaluronate also exhibited promising anti-inflammatory effects for the treatment of other diseases, especially for arthritis.<sup>[30,31]</sup> However, sodium hyaluronate with different molecular weight showed apparent heterogeneities in biological functions such as inflammation. In an *in vitro* study, Albano *et al.*<sup>[32]</sup> found that only high molecular weight form of sodium hyaluronate efficiently inhibited the IL-17A-mediated activation of ERK1/2 and nuclear factor kappa B and production of reactive oxygen species in human nasal epithelial cells. *In vivo*, Mihara *et al.*<sup>[33]</sup> suggested that high

**Table 2: Comparison of complications and secondary surgeries between the two group of glaucoma patients,  $n$**

Items	TA group ( $n = 30$ )	TH group ( $n = 30$ )	$\chi^2$	$P$
Sustained IOP <5 mmHg*	1	0	1.02	1.00
Aqueous misdirection	1	0	1.02	1.00
Infection	0	0	–	1.00
Wound leaks	2	1	0.00	1.00
Problematic pain	0	0	–	1.00
Choroidal effusion	0	0	–	1.00
Choroidal hemorrhage	0	0	–	1.00
Secondary surgery				
Bleb revision	5	2	0.65	0.42
Trabeculectomy	2	1	0.00	1.00
Transscleral cyclophotocoagulation	1	0	1.02	1.00

\*IOP <5 mmHg more than 1 month. IOP: Intraocular pressure; TA: Trabeculectomy alone; TH: Trabeculectomy with hyaluronate gel.



molecular weight of sodium hyaluronate had a better effect on the progression of cartilage degeneration in a rabbit model of knee osteoarthritis, compared to nonsteroidal anti-inflammatory drug. In contrast, low molecular weight of sodium hyaluronate seemed to be a potent stimulus for inflammation and scarring.<sup>[34]</sup> Notably, the molecular structure of sodium hyaluronate may also affect its biological properties. Cross-linked sodium hyaluronate was more stable in structure characteristic, thus having a longer biodegradation time than the noncross-linked product. Moreover, cross-linked and noncross-linked sodium hyaluronate also showed different effects on proliferation of fibroblast<sup>[35]</sup> and skin barrier function.<sup>[36]</sup>

Our data showed that both trabeculectomy alone and trabeculectomy combined with cross-linked sodium hyaluronate gel implantation were efficient to lower IOP. This result was consistent with but a bit different from a previous study by Papaconstantinou *et al.*<sup>[15]</sup> In their study, they failed to identify a higher IOP reduction by injection of cross-linked sodium hyaluronate gel in comparison with trabeculectomy alone while we did find more IOP reduction in cross-linked sodium hyaluronate gel injection group at 1, 3, and 5 years' points after following up. Besides trabeculectomy, cross-linked sodium hyaluronate gel injection was also effective in nonpenetrating glaucoma surgery.<sup>[20]</sup> Bettin *et al.*<sup>[20]</sup> reported that the POAG patients achieved an incredibly high success rates (89–92%) at 36 months after receiving deep sclerectomy with MMC and cross-linked sodium hyaluronate gel.

In addition to anti-inflammatory effect, cross-linked sodium hyaluronate gel may inhibit the postoperative fibrosis and scar formation by its space-occupying property through mechanically separating the subconjunctival and episcleral tissues. A similar product using a biodegradable collagen stent (Ologen<sup>®</sup>) had been developed and the implantation of this collagen device during trabeculectomy had a better IOP reduction than using MMC.<sup>[37-39]</sup> The reduction in glaucoma medication and surgical complication showed no statistical difference. Although no study was available to compare the efficiency and safety of these two implantable devices for glaucoma surgery, the satisfying IOP outcomes provided possibility for further research on those medial materials.

MMC is an antimitotic agent widely used in trabeculectomy, inhibiting the postoperative fibrosis. Bleb leak was the most common complication,<sup>[37-42]</sup> followed by aqueous misdirection, corneal abrasion, and Tenon's cyst formation. Choroidal detachment, choroidal hemorrhage, and endophthalmitis were occasionally reported, but vision-threatening complication had ever been reported.<sup>[13,24]</sup> Bindlish *et al.*<sup>[40]</sup> reported the 5-year retrospective study outcomes of trabeculectomy with MMC among 123 glaucoma patients. Six months after surgery, 42.3% of participants had ocular hypotony. About 14.6% participants had severe complications of bleb leakage, and 8.9% participants had secondary surgery at the 2-year time point. By contrast, 3.3%

participants in this study had secondary trabeculectomy, and the incidence rate of ocular hypotony and bleb leakage was lower than their study. Although our 5-year outcomes showed no statistical difference in single comparison of each postoperative side effect, the total amounts of the study group were fewer than the control group and bleb leakage times were fewer as well. Our results suggested that the implantation procedure had not enhanced the risk of occurrence of postoperative complications regarding the relatively low injection dosage and total sample size. The implantation of cross-linked sodium hyaluronate gel with trabeculectomy appeared to have a relatively safe profile. Although Rajiv Bindlish's study acquired higher 5<sup>th</sup> year success rate than our study (83% vs. 78%), our postoperative statistics of safety investigation were better, indicating that the relatively high safety of implantation was fit for surgical treatment.

There were several limitations for this study. First, due to the small sample size, it might not be able to detect the accurate differences in the incidence of complication and qualified success rate between the two groups. Second, 15 of 20 participants who lost from the follow-up are non-local residents. We knew that it was inevitable to have a certain portion of losing subjects for long-term follow-up trials. Among the 19 participants in the TA group two participants were nonlocal residents and others, and all participants in the TH group lived in the same city. We then did further investigation of the 5<sup>th</sup> year's follow-up between the two groups. Independent *t*-test results showed that mean IOP of the two groups were still standard normal distribution. IOP in the TH group was significantly lower than that of the TA group. The bleb height in the TH group was better while the bleb extent showed no significant difference. Vascularization level was similar in comparison with the TA group. So that we believed the lost rate did not affect the final success rate in our study. Third, an *in vivo* study using a rabbit model suggested that UV-cross-linked hyaluronate gel could be used as a vehicle to deliver and controlled-release tranilast for up to 26 h, facilitating the long-term success of IOP maintenance.<sup>[13]</sup> Futuristic studies using hyaluronate gel of different cross-linking rate implanted in trabeculectomy are expected.

In conclusion, our results suggested that implantation of cross-linked sodium hyaluronate gel with trabeculectomy appeared to be an efficient and safe option for glaucoma patients and could improve the prognosis of patients with glaucoma.

### Financial support and sponsorship

This study was supported by the grants from the National Science Foundation of China (No. 81670851), the Natural Science Foundation of Beijing (No. 7172231), and the Capital Public Health Project of Beijing (No. Z151100003915143).

### Conflicts of interest

There are no conflicts of interest.

## REFERENCES

- Li BB, Cai Y, Pan YZ, Li M, Qiao RH, Fang Y, *et al*. Corneal biomechanical parameters and asymmetric visual field damage in patients with untreated normal tension glaucoma. *Chin Med J* 2017;130:334-9. doi: 10.4103/0366-6999.198920.
- Jonas JB, Yang D, Wang N. Intracranial pressure and glaucoma. *J Glaucoma* 2013;22 Suppl 5:S13-4. doi: 10.1097/IJG.0b013e31829349bf.
- Dang Y, Mu Y, Wang K, Xu K, Yang J, Zhu Y, *et al*. Papaverine inhibits lipopolysaccharide-induced microglial activation by suppressing NF- $\kappa$ B signaling pathway. *Drug Des Devel Ther* 2016;10:851-9. doi: 10.2147/DDDT.S97380.
- Song W, Huang P, Zhang C. Neuroprotective therapies for glaucoma. *Drug Des Devel Ther* 2015;9:1469-79. doi: 10.2147/DDDT.S80594.
- Leske MC, Wu SY, Hennis A, Honkanen R, Nemesure B; BESs Study Group. Risk factors for incident open-angle glaucoma: The Barbados Eye Studies. *Ophthalmology* 2008;115:85-93. doi: 10.1016/j.ophtha.2007.03.017.
- Caprioli J, de Leon JM, Azarhod P, Chen A, Morales E, Nouri-Mahdavi K, *et al*. Trabeculectomy can improve long-term visual function in glaucoma. *Ophthalmology* 2016;123:117-28. doi: 10.1016/j.ophtha.2015.09.027.
- Addicks EM, Quigley HA, Green WR, Robin AL. Histologic characteristics of filtering blebs in glaucomatous eyes. *Arch Ophthalmol* 1983;101:795-8. doi: 10.1001/archophth.1983.01040010795021.
- Hitchings RA, Grierson I. Clinicopathological correlation in eyes with failed fistulizing surgery. *Trans Ophthalmol Soc U K* 1983;103(Pt 1):84-8.
- Jay JL. Rational choice of therapy in primary open angle glaucoma. *Eye (Lond)* 1992;6(Pt 3):243-7. doi: 10.1038/eye.1992.47.
- Migdal C, Gregory W, Hitchings R. Long-term functional outcome after early surgery compared with laser and medicine in open-angle glaucoma. *Ophthalmology* 1994;101:1651-6. doi: 10.1016/S0161-6420(94)31120-1.
- Na JH, Sung KR, Shin JA, Moon JI. Antifibrotic effects of pirfenidone on Tenon's fibroblasts in glaucomatous eyes: Comparison with mitomycin C and 5-fluorouracil. *Graefes Arch Clin Exp Ophthalmol* 2015;253:1537-45. doi: 10.1007/s00417-015-3068-1.
- Giampani J Jr., Borges-Giampani AS, Carani JC, Oltrogge EW, Susanna R Jr. Efficacy and safety of trabeculectomy with mitomycin C for childhood glaucoma: A study of results with long-term follow-up. *Clinics (Sao Paulo)* 2008;63:421-6.
- Spitzer MS, Sat M, Schramm C, Schnichels S, Schultheiss M, Yoeruek E, *et al*. Biocompatibility and antifibrotic effect of UV-cross-linked hyaluronate as a release-system for tranilast after trabeculectomy in a rabbit model – A pilot study. *Curr Eye Res* 2012;37:463-70. doi: 10.3109/02713683.2012.658593.
- Russo V, Scott IU, Stella A, Balducci F, Cosma A, Barone A, *et al*. Nonpenetrating deep sclerectomy with reticulated hyaluronate acid implant versus punch trabeculectomy: a prospective clinical trial. *Eur J Ophthalmol* 2008;18:751-7.
- Papaconstantinou D, Diagourtas A, Petrou P, Rouvas A, Vergados A, Koutsandrea C, *et al*. Trabeculectomy with healaflow versus trabeculectomy for the treatment of glaucoma: A case-control study. *J Ophthalmol* 2015;2015:836269. doi: 10.1155/2015/836269.
- Shoji N, Shimizu K, Takahashi K, Nemoto R, Kawai H, Tomioka T, *et al*. The application of cross-linked hyaluronate hydrogel to trabeculectomy. *Nippon Ganka Gakkai Zasshi* 2004;108:277-82.
- Lopes JF, Moster MR, Wilson RP, Altangerel U, Alvim HS, Tong MG, *et al*. Subconjunctival sodium hyaluronate 2.3% in trabeculectomy: A prospective randomized clinical trial. *Ophthalmology* 2006;113:756-60. doi: 10.1016/j.ophtha.2006.01.040.
- Stürmer J, Mermoud A, Sunaric Mégevand G. Trabeculectomy with mitomycin C supplemented with cross-linking hyaluronate acid: A pilot study. *Klin Monbl Augenheilkd* 2010;227:273-6. doi: 10.1055/s-0029-1245186.
- Roy S, Thi HD, Feusier M, Mermoud A. Crosslinked sodium hyaluronate implant in deep sclerectomy for the surgical treatment of glaucoma. *Eur J Ophthalmol* 2012;22:70-6. doi: 10.5301/ejo.5000054.
- Bettin P, Di Matteo F, Rabiolo A, Fiori M, Ciampi C, Bandello F, *et al*. Deep sclerectomy with mitomycin C and injectable cross-linked hyaluronate acid implant: Long-term results. *J Glaucoma* 2016;25:e625-9. doi: 10.1097/IJG.0000000000000309.
- Schlenker MB, Gulamhusein H, Conrad-Hengerer I, Somers A, Lenzhofer M, Stalmans I, *et al*. Efficacy, safety, and risk factors for failure of standalone ab interno gelatin microstent implantation versus standalone trabeculectomy. *Ophthalmology* 2017;124:1579-88. doi: 10.1016/j.ophtha.2017.05.004.
- Tseng VL, Kim CH, Romero PT, Yu F, Robertson-Brown KW, Phung L, *et al*. Risk factors and long-term outcomes in patients with low intraocular pressure after trabeculectomy. *Ophthalmology* 2017;124:1457-65. doi: 10.1016/j.ophtha.2017.05.014.
- Cantor LB, Mantravadi A, WuDunn D, Swamynathan K, Cortes A. Morphologic classification of filtering blebs after glaucoma filtration surgery: The Indiana Bleb Appearance Grading Scale. *J Glaucoma* 2003;12:266-71. doi: 10.1097/00061198-200306000-00015.
- Chou CL, Li HW, Lee SH, Tsai KL, Ling HY. Effect of intra-articular injection of hyaluronate acid in rheumatoid arthritis patients with knee osteoarthritis. *J Chin Med Assoc* 2008;71:411-5. doi: 10.1016/S1726-4901(08)70092-3.
- Egelius N, Jonsson E, Sunblad L. Studies of hyaluronate acid in rheumatoid arthritis. *Ann Rheum Dis* 1956;15:357-63. doi: 10.1136/ard.15.4.357.
- Mohamed MH, Abdelshafik MA, El Ibiary HM, Mohammed TH. Evaluation of the efficacy and safety of injectable cross-linked hyaluronate acid compared with mitomycin C in trabeculectomy surgery. *J Egypt Ophthalmological Soc* 2015;108:173. doi: 10.4103/2090-0686.174654.
- Roy S, Thi HD, Feusier M, Mermoud A. Crosslinked sodium hyaluronate implant in deep sclerectomy for the surgical treatment of glaucoma. *Eur J Ophthalmol* 2012;22:70-6. doi: 10.5301/ejo.5000054.
- Oh HJ, Li Z, Park SH, Yoon KC. Effect of hypotonic 0.18% sodium hyaluronate eyedrops on inflammation of the ocular surface in experimental dry eye. *J Ocul Pharmacol Ther* 2014;30:533-42. doi: 10.1089/jop.2013.0050.
- Aragona P, Papa V, Micali A, Santocono M, Milazzo G. Long term treatment with sodium hyaluronate-containing artificial tears reduces ocular surface damage in patients with dry eye. *Br J Ophthalmol* 2002;86:181-4. doi: 10.1136/bjo.86.2.181.
- Masuko K, Murata M, Yudoh K, Kato T, Nakamura H. Anti-inflammatory effects of hyaluronan in arthritis therapy: Not just for viscosity. *Int J Gen Med* 2009;2:77-81. doi: 10.2147/IJGM.S5495.
- Triantafyllidou K, Venetis G, Bika O. Efficacy of hyaluronate acid injections in patients with osteoarthritis of the temporomandibular joint. A comparative study. *J Craniofac Surg* 2013;24:2006-9. doi: 10.1097/SCS.0b013e3182a30566.
- Albano GD, Bonanno A, Cavalieri L, Ingrassia E, Di Sano C, Siena L, *et al*. Effect of high, medium, and low molecular weight hyaluronate on inflammation and oxidative stress in an *in vitro* model of human nasal epithelial cells. *Mediators Inflamm* 2016;2016:8727289. doi: 10.1155/2016/8727289.
- Mihara M, Higo S, Uchiyama Y, Tanabe K, Saito K. Different effects of high molecular weight sodium hyaluronate and NSAID on the progression of the cartilage degeneration in rabbit OA model. *Osteoarthritis Cartilage* 2007;15:543-9. doi: 10.1016/j.joca.2006.11.001.
- Gulkilik G, Kocabora S, Engin G, Taskapili M, Yilmazli C, Kucuksahin H, *et al*. Sodium hyaluronate in trabeculectomy: Effect on early complications. *Clin Exp Ophthalmol* 2006;34:421-4.
- Wohlrab J, Wohlrab D, Neubert RH. Comparison of noncross-linked and cross-linked hyaluronate acid with regard to efficacy and proliferative activity of cutaneous fibroblasts and keratinocytes *in vitro*. *J Cosmet Dermatol* 2013;12:36-40. doi: 10.1111/jocd.12024.
- Sundaram H, Mackiewicz N, Burton E, Penno-Mazzarino L, Lati E, Meunier S, *et al*. Pilot comparative study of the topical action of a novel, crosslinked resilient hyaluronate acid on skin hydration and barrier function in a dynamic, three-dimensional human explant model. *J Drugs Dermatol* 2016;15:434-41.
- Senthil S, Rao HL, Babu JG, Mandal AK, Garudadri CS. Comparison

- of outcomes of trabeculectomy with mitomycin C vs. ologen implant in primary glaucoma. *Indian J Ophthalmol* 2013;61:338-42. doi: 10.4103/0301-4738.109520.
38. Cillino S, Casuccio A, Di Pace F, Cagini C, Ferraro LL, Cillino G, *et al.* Biodegradable collagen matrix implant versus mitomycin-C in trabeculectomy: Five-year follow-up. *BMC Ophthalmol* 2016;16:24. doi: 10.1186/s12886-016-0198-0.
39. He M, Wang W, Zhang X, Huang W. Ologen implant versus mitomycin C for trabeculectomy: A systematic review and meta-analysis. *PLoS One* 2014;9:e85782. doi: 10.1371/journal.pone.0085782.
40. Bindlish R, Condon GP, Schlosser JD, D'Antonio J, Lauer KB, Lehrer R, *et al.* Efficacy and safety of mitomycin-C in primary trabeculectomy: Five-year follow-up. *Ophthalmology* 2002;109:1336-41. doi: 10.1016/S0161-6420(02)01069-2.
41. Khairy HA1, Elsawy MF. Trabeculectomy With Mitomycin-C Versus Trabeculectomy With Amniotic Membrane Transplant: A Medium-term Randomized, Controlled Trial. *J Glaucoma* 2015;24:556-9. doi: 10.1097/IJG.0000000000000060.
42. Sarker BK, Abdullahi SM, Hassan Z, Kabir J, Badmus S, Alam S, Rahman M, *et al.* Outcome of trabeculectomy with Ologen versus Mitomycin C: A comparative prospective study in Bangladesh. *Eur J Ophthalmol* 2018 Apr 1:1120672118771841. [Epub ahead of print]. doi: 10.1177/1120672118771841.

# 交联透明质酸钠凝胶应用于中国青光眼病人小梁切除术 五年疗效观察

## 摘要

**背景：**青光眼是首位不可逆致盲眼病，小梁切除术仍是使用最广泛术式。青光眼术后滤过泡瘢痕化仍然没有十分完善的解决方案，瘢痕化的防治失败会导致术后眼压控制不良，影响手术成功率。因此，该前瞻性临床随机对照研究目的是评价将一种交联透明质酸钠凝胶应用于初次接受小梁切除术的中国青光眼病人的术后五年疗效。

**方法：**这是一项前瞻性病例对照研究。本研究以北京大学第三医院眼科2010~2012年间收治的接受初次小梁切除术青光眼患者为研究对象。60例患眼随机分为单纯小梁切除术组（TA组）和小梁切除术联合交联透明质酸钠凝胶植入组（TH组）。在术后1周、1月、3月、1年、3年和5年时间点对受试者进行随访观察，调查指标包括人口基线资料、眼压、滤过泡形态、并发症以及术后抗青光眼药物使用和额外操作情况。采用SPSS 19.0软件对统计资料分别进行独立样本 $t$ 检验、单因素方差分析和皮尔逊卡方检验。

**结果：**两组间基线眼压（IOP）没有差别（ $P > 0.05$ ），但术后随访的1年、3年和5年两个时间点，TH组病人IOP显著低于TA组（ $P = 0.00$ ， $P = 0.01$ ， $P = 0.01$ ）。根据印第安娜BLEB外观分级量表，TH组在所有随访时间点BLEB高度和范围均较好（ $P < 0.05$ ），而BLEB血管的比较无统计学差异（ $P > 0.05$ ）。另一方面，两组术后并发症的统计差别明显（13% vs. 3%），TH组相对较少，并且TH组5年完全手术成功率高于TA组，差异有统计学意义（78% vs. 54%， $P = 0.03$ ）

**结论：**交联透明质酸钠凝胶联合小梁切除术是一种安全有效的选择，可改善青光眼患者的预后。