

CLINICAL RESEARCH ARTICLE

The modified Pirogoff's amputation in treating diabetic foot infections: surgical technique and case series

Aziz Nather, FRCS (Ed)*, Keng Lin Wong, MRCS (Ed),
 Amaris Shumin Lim, Med. Student, Dennis Zhaowen Ng, MMed (Ortho) and
 Hwee Weng Hey, MMed (Ortho)

Department of Orthopaedic Surgery, University Orthopaedic, Hand and Reconstructive Microsurgery Cluster,
 National University Health System, Singapore

Background: This paper describes the surgical technique of a modified Pirogoff's amputation performed by the senior author and reports the results of this operation in a single surgeon case series for patients with diabetic foot infections.

Methods: Six patients with diabetic foot infections were operated on by the National University Hospital (NUH) diabetic foot team in Singapore between November 2011 and January 2012. All patients underwent a modified Pirogoff's amputation for diabetic foot infections. Inclusion criteria included the presence of a palpable posterior tibial pulse, ankle brachial index (ABI) of more than 0.7, and distal infections not extending proximally beyond the midfoot level. Clinical parameters such as presence of pulses and ABI were recorded. Preoperative blood tests performed included a glycated hemoglobin level, hemoglobin, total white blood cell count, C-reactive protein, erythrocyte sedimentation rate, albumin, and creatinine levels. All patients were subjected to 14 sessions of hyperbaric oxygen therapy postoperatively and were followed up for a minimum of 10 months.

Results: All six patients had good wound healing. Tibio-calcaneal arthrodesis of the stump was achieved in all cases by 6 months postoperatively. All patients were able to walk with the prosthesis.

Conclusions: The modified Pirogoff's amputation has been found to show good results in carefully selected patients with diabetic foot infections. The selection criteria included a palpable posterior tibial pulse, distal infections not extending proximally beyond the midfoot level, ABI of more than 0.7, hemoglobin level of more than 10 g/dL, and serum albumin level of more than 30 g/L.

Keywords: *Pirogoff amputation; diabetes; diabetic foot complications; clinical outcome; prosthesis*

*Correspondence to: Aziz Nather, Department of Orthopaedic Surgery, National University of Singapore and National University Hospital, 119074 Singapore, Email: aziz_nather@nuhs.edu.sg

Received: 14 November 2013; Revised: 8 March 2014; Accepted: 10 March 2014; Published: 3 April 2014

Syme's amputation has been advocated for trauma cases (1) but in patients with diabetic foot infections some of the results have been poor (2, 3). However, in careful and strict selection of cases with diabetic foot infections, Syme's amputation can provide good results (2). For patient selection in the diabetic group of patients, it is well known that Syme's amputation should be reserved for patients with a palpable posterior tibial pulse and ankle brachial index (ABI) of more than 0.5 (2–4). There are, however, several disadvantages to this operation, such as instability of the calcaneal flap leading to poor adherence to the raw tibial surface, and possible devascularization from the dissection of the calcaneum from the underlying flap (5). Other disadvantages include significant limb length discrepancy, which makes walking barefoot difficult (6).

The Boyd's and Pirogoff's amputation are postulated to give better results than the Syme's amputation (6–9). In these types of surgeries, the tibio-calcaneal bony arthrodesis provides added stability to the flap. There is also minimal devascularization of the flap because the calcaneum is not dissected. It is also easier for the patient to walk without a prosthesis because this surgery allows for a full weight-bearing stump and limb length discrepancy is minimized (8). In these amputations, part of the medial and lateral malleolus is preserved and thus a prosthesis may be worn with less friction and be more rotationally stable compared to the prostheses used following a standard transtibial amputation (9).

In 1854, Russian surgeon Nikolai Pirogoff first described the surgical technique for the amputation (10). Modifications have been made to the original Pirogoff's

amputation to improve outcomes and reduce risks of complications (6, 11). Langeveld et al. in 2010 reported good results of a modified Pirogoff's amputation for a case with necrosis and infection of the right forefoot in a 74-year-old male with peripheral vascular disease (8). In another publication, he described his own technique of doing a modified Pirogoff's amputation using a 60-degree oblique cut (11). In 2010, den Bakker et al. described the results of a Pirogoff's amputation in a 26-year-old man, with no medical history, who was run over by a bus (9). Currently, there is limited literature reporting the results of a modified Pirogoff's amputation in diabetic foot infections. The objective of this paper was to report the results of a single surgeon case series of a modified Pirogoff's amputation for patients with diabetic foot infections.

Methods

We studied the results of six patients operated on by the National University Hospital (NUH) diabetic foot team in Singapore between October 2011 and January 2012. All patients had type 2 diabetes mellitus. There were five females and one male. There were four Malays, one Indian, and one Chinese ranging in age 47–67, the average being 54 years old. The diabetic foot infections were abscesses (two cases), wet gangrene (three cases), and necrotizing fasciitis of the foot (one case). All infections did not extend beyond the midfoot level to allow for adequate management of the infection during the surgery. Clinical evaluation included the examination for presence or absence of palpable posterior tibial and dorsalis pedis pulses along with ABI. Preoperative blood tests performed included glycated hemoglobin (HbA1c), hemoglobin (Hb), total white cell count (WBC), C-reactive Protein (CRP), erythrocyte sedimentation rate (ESR), albumin, and creatinine (Cr) levels. A total of 14 sessions of hyperbaric oxygen therapy postoperatively was also administered for all patients.

Operative technique

The patient is positioned supine on a radiolucent operating table. A well-padded pneumatic thigh tourniquet is then applied and the ipsilateral buttock is raised slightly with a sandbag to ensure the foot is in neutral position. The malleoli, sustentaculum tali, and posterior tibial artery are palpated and the incision is marked (Fig. 1a and b). The anterior flap runs from one-finger breadth below the distal tip of the medial malleolus (Fig. 1a, Point A) over the anterior aspect of the ankle to the tip of the lateral malleolus (Fig. 1b, Point B). The posterior flap runs vertically downwards from the distal tip of the medial malleolus to the sole of the foot to the lateral border of the foot. It runs vertically upwards to join the tip of the lateral malleolus. The vessels (saphenous vein and dorsalis

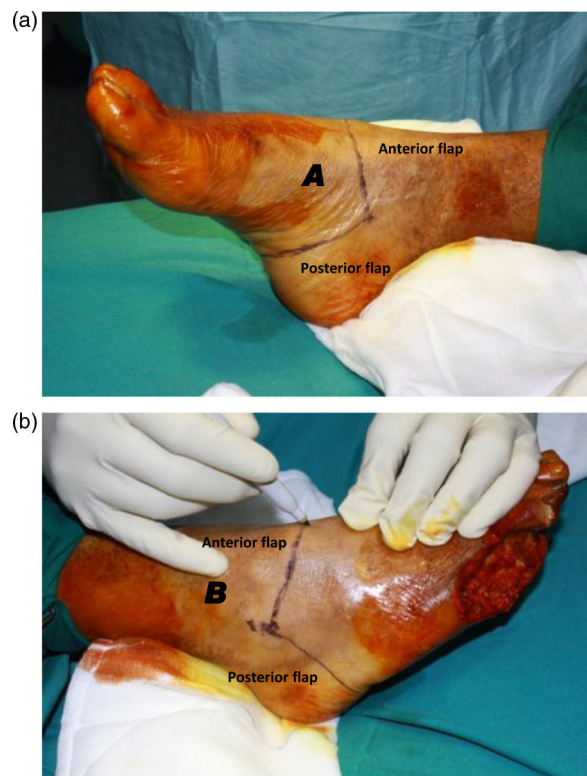


Fig. 1. (a) Skin flaps are marked (medial view). Point A represents a 1-finger breadth vertically below the tip of the medial malleolus. (b) Skin flaps are marked (lateral view). Point B marks the tip of the lateral malleolus.

pedis artery) are ligated and divided while the extensor and peroneal tendons are transected along the line of incision.

The anterior capsule is incised to expose the articular surfaces of the tibia and talus. The deltoid ligament of the ankle is sectioned on the medial side, with care to preserve the posterior tibial artery, and the talus is then excised and removed. The anterior talar articular surface, middle talar articular surface, and posterior talar articular surface of the calcaneum are then exposed. The distal part

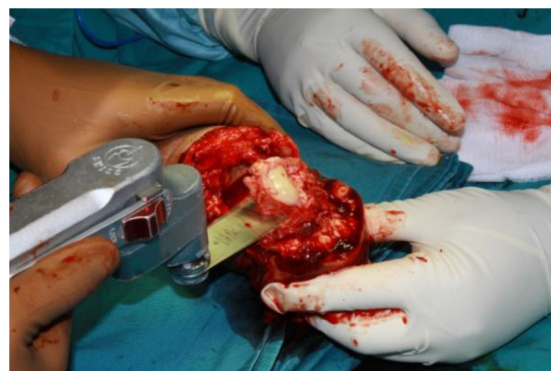

Fig. 2. Oscillating saw used for osteotomizing the distal quarter of the calcaneum. The calcaneum is left behind in the posterior flap.

of the foot containing the cuboid is then excised by leaving the calcaneum in the plantar flap (Fig. 2).

Using an oscillating saw, a vertical osteotomy is performed on the calcaneum just behind the anterior talar articular surface. The distal one quarter of the calcaneum is then osteotomized (Figs. 2 and 3a) with the line of osteotomy (Point C to D) being perpendicular to the calcaneum (Fig. 3a). An oblique osteotomy is then performed from Point D to E at the posterior border of the upper end of the calcaneum (Fig. 3a). The osteotomized wedge of bone is then removed. This osteotomy gives a 60-degree cut (Fig. 3a) to the remaining calcaneum left behind in the flap.

Using an oscillating saw, the distal end of the tibia is then osteotomized. The line of osteotomy (line FG) is perpendicular to the tibia (Fig. 3b). The medial malleolus (Point F) and the lower part of the fibula (Point G) are osteotomized along the line of the tibial osteotomy (Fig. 3b).

Two Kirschner wires are inserted through the stump in a crossed manner. Two 7.0-mm partially threaded

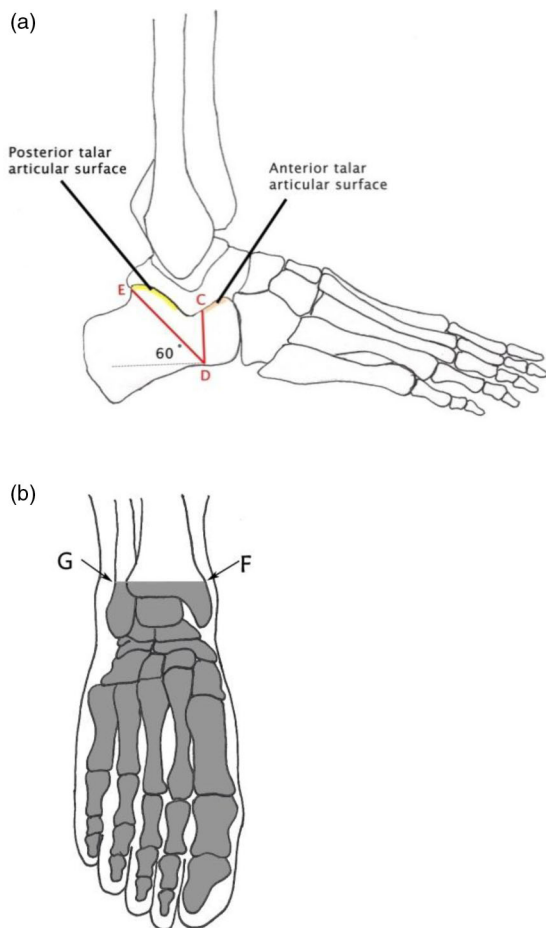


Fig. 3. (a) Lateral view of the foot showing the two lines of osteotomy (CD and DE) at the calcaneum. (b) Diagram showing the line of tibial osteotomy (FG) and the bones removed (shaded) in a modified Pirogoff's amputation.

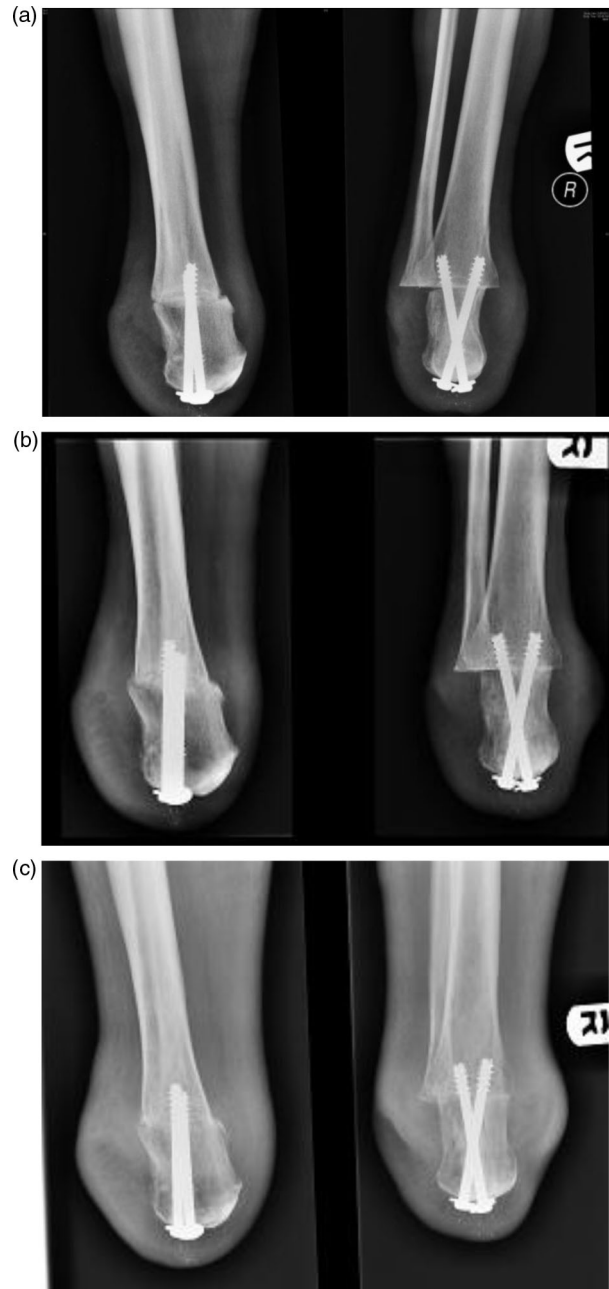


Fig. 4. (a) Lateral and anteroposterior radiographic views of immediate postoperative modified Pirogoff's amputation showing compression of the tibio-calcaneal surfaces by two partially threaded cannulated screws. (b) Lateral and anteroposterior radiographic views of a Pirogoff's amputation showing the presence of initial union at the tibio-calcaneal arthrodesis at 3 months postoperatively. (c) Lateral and anteroposterior radiographic views of a Pirogoff's amputation showing the presence of significant union at the tibio-calcaneal arthrodesis at 6 months postoperatively.

cannulated screws are then inserted over the Kirschner wires. To achieve compression, partially threaded cancellous screws are inserted according to the lag fashion. The screws are tightened, and their positions are confirmed

Table 1. Patient characteristics

Patient	Age	Gender	Ethnicity	Type of diabetes	Duration of diabetes	Type of diabetic foot problem	Other significant comorbidities
1.	52	Female	Malay	2	14 years	Abscess right foot	Hypertension, hyperlipidemia, ischemic heart disease, end-stage renal failure
2.	49	Male	Malay	2	1 year	Necrotizing fasciitis left foot	None
3.	67	Female	Chinese	2	7 years	Wet gangrene right Foot	Hypertension, ischemic heart disease
4.	54	Female	Malay	2	> 10 years	Abscess right 4th toe	Hypertension, hyperlipidemia
5.	47	Female	Indian	2	17 years	Wet gangrene right 1st toe	Hypertension, hyperlipidemia
6.	50	Female	Malay	2	1 year	Wet gangrene 4th and 5th toes	None

to be satisfactory via intra-operative fluoroscopy (Fig. 4a). The anterior and posterior flaps are opposed with one single layer of 3-0 Prolene sutures, and Tulle Gras dressing is applied over the wound. Gauze and cotton wool is then used to wrap the lower extremity stump before a Crepe bandage is applied in a figure-of-eight fashion followed by a stockinette. Postoperatively, once the wound is healed, the lower extremity stump is fitted with a prosthesis at 2 months. Patients are then allowed to ambulate in full weight-bearing status by using the prosthesis. In our study, all patients were able to walk with the prosthesis in 3 months postoperatively.

Results

Table 1 shows the patient's characteristics, whereas Table 2 shows the clinical parameters documented. All of the studied patients had palpable posterior tibial and dorsalis pedis pulses except one patient (case 2) who had a palpable posterior tibial pulse but absent dorsalis pedis pulse. The ABI of all patients was more than 0.7. Case 4 was initially an abscess of the toe, and cases 5 and 6 were initially presented with wet gangrene of the toes. The above cases further progressed to the associated rays, and the infection was spreading towards the midfoot by the time of surgery while there was no viable flap coverage possible for more distal operations, such as a transmetatarsal or Chopart's amputation. The Pirogoff's amputation was hence performed for adequate management of the infection with resultant viable local flap coverage.

All patients had received intravenous broad-spectrum antibiotic coverage from time of diagnosis to the time prior to surgery. Intravenous antibiotic coverage was then continued for another 5 days after surgery before converting to appropriate oral antibiotics for a total of 2 weeks in duration depending on sensitivity results of available intra-operative cultures.

Table 3 shows all of the preoperative blood parameters recorded. All six patients had albumin levels of at least

30 g/L and Hb levels of at least 10 g/dL. All patients completed 14 sessions of hyperbaric oxygen therapy sessions and were followed up for a period of 10 months. All cases achieved bony fusion confirmed with plain radiographs at 6 months postoperatively (Fig. 4b and c) and showed good wound healing (Fig. 5). There were no postoperative morbidity issues such as heel ulcers or hardware exposure reported. Prostheses were fitted at 3 months postoperatively, and patients were able to ambulate in full weight-bearing status with the prosthesis.

Discussion

This study has shown that the modified Pirogoff's amputation can achieve good results, even when used for surgery in the management of diabetic foot complications. In our study, patient selection criteria included the presence of a palpable posterior tibial pulse and an ABI of more than 0.7. Pinzur et al. in 2003 have emphasized the importance of wound healing parameters, which included an ABI of more than 0.5 (4). In addition a Hb level of more than 10 g/dL and serum albumin level of more than 30 g/L was also recorded in our patient population because the importance of serum albumin of more than 2.5 g/dL was also emphasized by Pinzur et al. in 2003 (4).

Table 2. Clinical vascular examination

Patient	Dorsalis pedis pulse	Posterior tibial pulse	Ankle	
			brachial index (ABI)	Toe brachial index (TBI)
1.	Present	Present	1.2	0
2.	Absent	Present	1.03	0.55
3.	Present	Present	0.8	0.55
4.	Present	Present	1.26	0
5.	Present	Present	1.2	0.97
6.	Present	Present	1.23	0.62

Table 3. Preoperative blood parameters

Patient	HbA1c (%)	WBC ($\times 10^9/L$)	Hb (g/dL)	CRP (mg/L)	ESR (mm/hr)	Alb (g/L)	Cr ($\mu\text{mol/L}$)
1.	8.2	28.97	11.8	266	81	33	810
2.	7.1	17.48	12.0	296	69	31	73
3.	8.4	9.55	11.8	<5	27	38	45
4.	9.4	25.01	11.1	260	90	32	50
5.	13.6	24.31	11.8	391	106	30	46
6.	6.6	10.0	9.7	75	70	33	84

The authors have also utilized hyperbaric oxygen therapy to improve wound healing in all of the patients postoperatively. There is increasingly strong evidence that hyperbaric oxygen therapy can significantly improve the healing of diabetic wounds in the short term (12, 13) and the authors used this modality as an adjunctive therapy to improve wound healing in the postoperative period.

One of the most important aims of early surgical intervention for diabetic foot infections is to prevent major amputation and limb loss. When the modified Pirogoff's amputation is successfully performed, its various advantages include a weight-bearing stump, minimal limb length discrepancy, and easier fitting of prosthesis when compared to that of Syme's amputation (14). The modified Pirogoff's amputation is a viable option as a distal hindfoot or minor amputation for the diabetic foot, as classified by Nather and Wong in order to prevent limb loss in patients with diabetic foot problems (14).

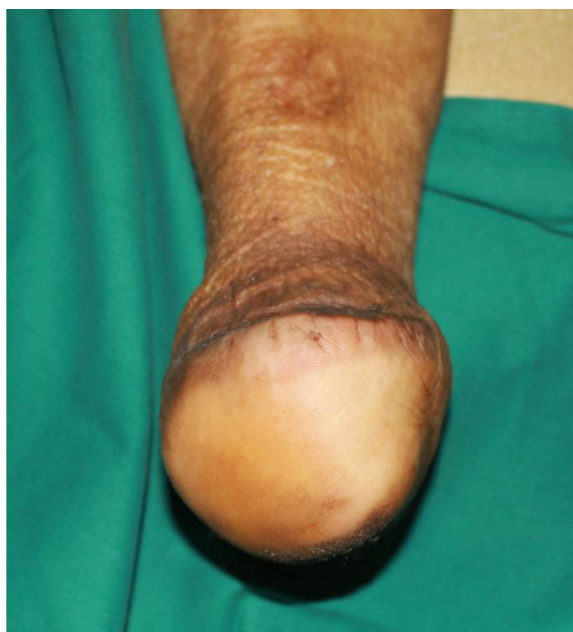

Fig. 5. Clinical picture of a Pirogoff's lower extremity stump showing good wound healing.

Limitations of this study include a lack of comparison of results with and without hyperbaric oxygen therapy, and lack of comparison of the modified Pirogoff's amputation versus other surgical amputation modalities. Future progress in this field should include a prospective trial comparing the modified Pirogoff's operation versus other surgical modalities and an evaluation of the efficacy of hyperbaric oxygen therapy in diabetic patients undergoing an amputation.

Conclusion

The modified Pirogoff's amputation has shown good results in carefully selected patients with diabetic foot infections. The selection criteria included a palpable posterior tibial pulse, distal infections not extending proximally beyond the midfoot level, ABI of more than 0.7, Hb level of more than 10 g/dL, and a serum albumin level of more than 30 g/L.

Conflict of interest and funding

The authors declare that they have no conflict of interest and have not received any funding or benefits from industry to conduct this study.

References

1. Pinzur MS. Restoration of walking ability with Syme's ankle disarticulation. *Clin Orthop Related Res* 1999; 361: 71–5.
2. Jany RS, Burkus JK. Long-term follow up of Syme amputations for peripheral vascular disease associated with diabetes mellitus. *Foot Ankle* 1988; 9: 107–10.
3. Laughlin RT, Chambers RB. Syme amputation in patients with severe diabetes mellitus. *Foot Ankle* 1993; 14: 65–70.
4. Pinzur MS, Stuck RM, Sage R, Hunt N, Rabinovich Z. Syme ankle disarticulation in patients with diabetes. *J Bone Joint Surg Am* 2003; 85: 1667–72.
5. Harris RI. Syme's amputation: the technical details essential for success. *J Bone Joint Surg Br* 1956; 38: 614–32.
6. Taniguchi A, Tanaka Y, Kadono K, Inada Y, Takakura Y. Pirogoff ankle disarticulation as an option for ankle disarticulation. *Clin Orthop Relat Res* 2003; 414: 322–8.
7. Altindas M, Kilic A. Is Boyd's operation a last solution that may prevent major amputations in diabetic foot patients? *J Foot Ankle Surg* 2008; 47: 307–12.
8. Langeveld AR, Oostenbroek RJ, Wijffels MP, Hoedt MT. The Pirogoff amputation for necrosis of the forefoot: a case report. *J Bone Joint Surg Am* 2010; 92: 968–72.

9. den Bakker FM, Holtslag HR, van den Brand JG. Pirogoff amputation for foot trauma: an unusual amputation level: a case report. *J Bone Joint Surg Am* 2010; 92: 2462–5.
10. Pirogoff NI. Resection of bones and joints and amputations and disarticulations of joints. 1864. *Clin Orthop Relat Res* 1991; 266: 3–11.
11. Langeveld AR, Meuffels DE, Oostenbroek RJ, Hoedt MT. The Pirogoff amputation for necrosis of the forefoot: surgical technique. *J Bone Joint Surg Am* 2011; 93: 21–9.
12. Kranke P, Bennett MH, Martyn-St James M, Schnabel A, Debus SE. Hyperbaric oxygen therapy for chronic wounds. *Cochrane Database Syst Rev* 2012; 4: CD004123.
13. Löndahl M. Hyperbaric oxygen therapy as treatment of diabetic foot ulcers. *Diabetes Metab Res Rev* 2012; 28: 78–84.
14. Nather A, Wong KL. Distal amputations for the diabetic foot. *Diabet Foot Ankle* 2013; 4: 1–4.