

High-dose short-course oral corticosteroid protocol for treatment of primary frozen shoulder: a retrospective cohort study

Teoman Atici¹ , Cenk Ermutlu¹,
Selcan Akesen²  and Ali Özyalçın¹ 

Abstract

Objective: To evaluate the effect of high-dose prednisolone on the functional outcome of patients with early-stage primary frozen shoulder.

Methods: Eighteen patients treated with oral prednisolone at an initial dose of 1 mg/kg/day for primary frozen shoulder were retrospectively evaluated. The patients' range of motion, Disabilities of the Arm, Shoulder, and Hand (DASH) score, Constant–Murley score, American Shoulder and Elbow Surgeons (ASES) score, and visual analog scale score were recorded at baseline and at 4 weeks and 6 months after treatment.

Results: Rapid recovery of shoulder motion was noted at 4 weeks with the exception of abduction, which was maintained at 6 months. Significant improvement in pain perception and the Constant–Murley score was evident at 4 weeks and extended to 6 months. The DASH and ASES scores did not show significant improvement in the first 4 weeks but were significantly improved at 6 months.

Conclusion: High-dose oral prednisolone treatment provides rapid symptom resolution that persists long after drug discontinuation. The early treatment period is characterized by marked reduction in pain and rapid recovery of shoulder motion. Improvements in functional outcomes and disability indices tend to be more subtle in the early period but significantly improve during late treatment.

¹Department of Orthopaedics and Traumatology, Uludag University Faculty of Medicine, Bursa, Turkey

²Department of Anesthesiology and Intensive Care, Uludag University Faculty of Medicine, Bursa, Turkey

Corresponding author:

Cenk Ermutlu, Department of Orthopaedics and Traumatology, Uludag University Faculty of Medicine, University Street, Görükle, Nilüfer/Bursa 16045, Turkey. Email: cermutlu@uludag.edu.tr



Keywords

Frozen shoulder, adhesive capsulitis, prednisolone, corticosteroid, functional outcome, disability index

Date received: 26 March 2021; accepted: 20 May 2021

Introduction

Frozen shoulder, often referred to as adhesive capsulitis, stiff shoulder, or scapulo-humeral periarthritis, is a debilitating condition of the shoulder characterized by serious restriction in both active and passive joint motion.¹⁻⁴ Although the condition itself is a self-limiting disease with mild residual disability, it follows a protracted course and has profound effects on daily living during the course of disease progression.⁵

Most affected patients have primary idiopathic frozen shoulder with no identified underlying cause. Those with predisposing metabolic disease such as diabetes mellitus or with a primary pathology in the shoulder prior to the development of adhesive capsulitis are considered to have secondary frozen shoulder.^{6,7} Tertiary frozen shoulder arises as a grave complication of fracture treatment in the shoulder girdle or rotator cuff repair and may occur despite early rehabilitation.

The disease process follows three stages based on clinical findings.⁸ The initial phase is the “painful” stage and might last for months. It is characterized by persistent pain that is evident even at rest. As the pain wanes, the shoulder gradually becomes stiffer and patients enter the “stiffness” stage. The final stage (i.e., the “recovery” phase) is characterized by resolution of symptoms and may extend into a 2- to 3-year time span.^{9,10}

The treatment of frozen shoulder is generally conservative. Oral nonsteroidal

anti-inflammatory drugs, intra-articular or oral glucocorticoids, narcotic analgesics, physical therapy, capsular distention, and interscalene block-assisted physical therapy may be used.^{11,12} Surgical treatment is generally reserved for patients who do not respond to conservative treatment. The final long-term results are similar between different treatment modalities and no treatment at all, suggesting the concept of supervised neglect as an option.¹³

Use of glucocorticoids as disease-modifying agents has long been established with improvements in range of motion (ROM), pain management, and functional outcomes in the early phase.^{9,14} Patients are likely to benefit from both the anti-inflammatory properties of the drug on synovial tissue and from the antifibrotic effects during collagen remodeling.¹⁵ Intra-articular and periarticular injections are the most common routes of administration of glucocorticoids for frozen shoulder.¹⁶⁻¹⁹

Reports on oral use of drugs in the treatment of frozen shoulder are very rare, with fewer than 10 studies published since the initial paper by Blockley et al.¹⁴ in 1954. The methodologies in these reports are far from uniform, using different outcome measures and alternating forms of steroids with different potencies and dosages. Although this makes interpreting the efficacy of different glucocorticoids and dose regimens rather inconclusive, a pattern of rapid recovery in the early treatment period is well established.^{5,9,14,20-23}

Earlier reports indicate a slowing down of improvement or even a setback with rebound of symptoms after cessation of the drug.^{5,14,21} Recent studies by Canbulat et al.⁹ and Lorbach et al.²² showed that the improvements may be maintained with higher doses and gradual tapering of the drug.

Although oral glucocorticoids can be safely used up to a 1-mg/kg dose equivalent of prednisolone for inflammatory disease, the maximum daily dose reported in the literature for treatment of frozen shoulder is 40 mg/day^{5,9,14,15,22,23} (Table 1). We designed this retrospective study to evaluate the effect of high-dose oral prednisolone, an intermediate-acting corticosteroid, on functional outcomes of patients with early-stage primary frozen shoulder and to report the adverse effects.

Materials and methods

Patients who were treated with high-dose oral glucocorticoids for frozen shoulder from 1 January 2017 and 31 July 2019 in our institution were retrospectively evaluated. Following approval from the institutional review board (decision number 2020-1/50), patient records were retrieved and analyzed. The study was conducted in accordance with the principles set forth in the Helsinki Declaration 2008 and conforms to the STROBE statement.²⁴ Informed consent was not required because of the retrospective nature of the study. The inclusion criteria were primary frozen shoulder with persistent pain at rest for the last 2 months, the “painful” stage of the disease, >75% loss of shoulder motion in any two directions, and age of >18 years. The exclusion criteria were the mid to late stages of the disease, secondary or tertiary frozen shoulder, contraindications to glucocorticoid use (e.g., peptic ulcer, hypertension, or diabetes mellitus), degenerative changes in the shoulder joint, history of

surgery or fracture in the shoulder girdle, <6 months of follow-up, pregnancy, and lack of compliance with the treatment algorithm.

Patients’ active and passive ROM, pain at rest, and functional status prior to treatment; at 4 weeks and 6 months after treatment; and at the last follow-up were noted. Any adverse effects that necessitated termination of medication and patients whose condition did not respond to treatment and thus required surgery were noted.

Diagnosis

Diagnosis of frozen shoulder was made clinically. Patients with severe restriction of both active and passive shoulder motion were considered to have frozen shoulder. Patients were questioned about the course of their symptoms to verify the stage of the disease. Plain radiographs; oblique, axillary, and outlet radiographs; and magnetic resonance imaging scans were used for differential diagnosis.

Treatment

The patients were started on oral prednisolone (Deltacortril® tablet 5 mg; Pfizer, İstanbul, Turkey) at 1 mg/kg/day divided into two separate doses (twice a day) for the first 3 days. The daily dose was tapered in decrements of 10 mg every 3 days. The last three doses were given as single regimen at night. The daily and total doses for an 80-kg adult and the medication protocol are outlined in Table 2. Proton pump inhibitors and calcium/vitamin D supplements were begun to prevent gastrointestinal symptoms and osteopenia, and patients were put on a low-salt and low-sugar diet. Patients were also instructed to begin a home exercise program involving pendulum swings for 10 minutes three times a day. After 2 weeks, active-assisted exercise (mainly finger walking up the wall with the support

Table 1. Use of oral glucocorticoids for treatment of frozen shoulder.

Authors	Drug and dose	Prednisolone equivalent	Taper-off	Total duration	Total dose (prednisolone equivalent)
Canbulat et al. ⁹	Methylprednisolone, 0.5 mg/kg/day	0.6 mg/kg/day	Dose halved each following week	4 weeks	395 mg
Widiastuti-Samekto and Sianturi, ²³	Triamcinolone, 12 mg/day	15 mg/day	Dose decreased by 4 mg each following week	3 weeks	210 mg
Lorbach et al. ²²	Prednisolone, 40 mg/day	40 mg/day	Dose decreased by 10 mg each 5 days and 5 mg for the last 5 days	25 days	525 mg
Blockey et al. ¹⁴	Cortisone acetate, 200 mg/day	40 mg/day	Dose reduced to 10 mg after 3 days and in decrements of 12.5 mg every 2 days after the second week	4 weeks	500 mg
Buchbinder et al. ⁵	Prednisolone, 30 mg/day	30 mg/day	None	3 weeks	630 mg
Chen et al. ²¹	Prednisolone, 30 mg/day	30 mg/day	Dose reduced to 15 mg/day after 2 weeks	4 weeks	630 mg

Table 2. Medication protocol for an 80-kg patient.

Dose	Administration protocol
80 mg/day	40 mg (eight 5-mg tablets) twice a day for the first 3 days
70 mg/day	35 mg (seven 5-mg tablets) twice a day for 3 days
60 mg/day	30 mg (six 5-mg tablets) twice a day for 3 days
50 mg/day	25 mg (five 5-mg tablets) twice a day for 3 days
40 mg/day	20 mg (four 5-mg tablets) twice a day for 3 days
30 mg/day	15 mg (three 5-mg tablets) twice a day for 3 days
20 mg/day	10 mg (two 5-mg tablets) twice a day for 3 days
10 mg/day	10 mg (two 5-mg tablets) in the morning for 3 days
Total dose: 1080 mg	Total time: 24 days

of the healthy arm) was added to the rehabilitation protocol. No aggressive physical therapy was advised because such therapy has not been shown to be superior to mild exercise. The main aim of home therapy was to gradually regain shoulder mobility without exacerbating symptoms. Patients were prescribed tramadol hydrochloride 37.5 mg/acetaminophen 325 mg (Zaldiar® tablet; Abdi İbrahim, İstanbul, Turkey) and were instructed to use this medication if the exercises induced pain that was severe enough to require medication.

Outcome measurement

Three patient-reported outcome measures were used to assess the patients' response to treatment: the Disabilities of the Arm, Shoulder, and Hand (DASH) score, the American Shoulder and Elbow Surgeons (ASES) score, and the Constant–Murley (CM) score. The DASH questionnaire is a frequently used questionnaire that was developed in 1996 as a collaboration among the American Academy of Orthopedic Surgeons, the Council of Musculoskeletal Specialty Societies, and the Institute for Work and Health (Toronto, Ontario).²⁵ It focuses on the effect of underlying conditions on the function of the entire limb. The cumulative result is scaled from 0 to 100, with 100

indicating maximum disability. It is completely self-assessed and relies on the patients' perceived disability in their activities of daily living. The ASES score is a shoulder-specific outcome measurement tool adopted by the American Shoulder and Elbow Surgeons Research Committee and published by Richards et al.²⁶ in 1994. It has both patient self-evaluation and physician assessment sections, although only the patient-reported section is included in the final score. The ASES score has found widespread usage in documentation of both baseline impairment and treatment results of shoulder pathologies. Finally, described by Constant and Murley²⁷ in 1987, the CM score is currently the most widely used assessment tool for shoulder pathologies with high responsiveness. It is joint-specific and has four domains: pain, activities of daily living, strength, and ROM. It combines both examiner- and self-assessed items. Unlike the ASES score, both domains are included in the cumulative index. Its high responsiveness and ease of use have made it an essential assessment tool for shoulder pathologies.

Patients' active and passive ROM; presence of night pain; and DASH, CM, ASES, and visual analog scale (VAS) scores were recorded at baseline and at each visit. A blinded outcome assessor evaluated the patients, performed the aforementioned

measurements, and assisted with filling in the self-assessment questionnaires. A simple goniometer was used to measure the shoulder arc of movement with the patient standing. Patients were considered to have achieved full recovery and the treatment was considered successful if their VAS score for pain was <4 and shoulder ROM was within 90% of the uninvolved limb. The number of patients who recovered at 4 weeks and improvements in patient-reported outcomes and shoulder motion at 4 weeks and 6 months were noted.

Statistical analysis

Improvements at each follow-up compared with baseline and the previous visit were analyzed for statistical significance. The results are presented as mean \pm standard deviation or median (minimum–maximum) for continuous variables. Categorical variables are presented as frequency and percentage. The Shapiro–Wilk test was used as a normality test. Continuous variables were compared between two groups using the Mann–Whitney U test when the data were not normally distributed. Friedman tests were used to assess the overall change in the variables over time within groups. Dunn–Bonferroni post hoc tests were carried out, and there were significant differences between times. Correlations between variables were tested using Spearman correlation coefficients. Categorical variables were compared using Fisher’s exact test. A p-value of <0.05 was considered significant. All statistical analyses were performed with IBM SPSS Statistics for Windows, Version 23.0 (IBM Corp., Armonk, NY, USA).

Results

Thirty-one patients received oral prednisolone treatment for frozen shoulder. Eight patients had underlying systemic disease, three had a previous fracture in the

involved shoulder, and two had a massive rotator cuff tear diagnosed with magnetic resonance imaging and were excluded from the study. Eighteen patients (13 female, 5 male) with primary frozen shoulder were available for the final analysis. The patient demographics and baseline ROM, VAS scores, and patient-reported outcome measures are shown in Table 3. The patients’ age, body mass index, sex, and occupation status had no effect on improvements in the VAS score, ROM, or functional outcome scores at any time points. Similarly, involvement of the dominant or non-dominant side did not affect the outcome. No patients developed adverse effects that required treatment cessation. No patients required manipulation under anesthesia or arthroscopic release. In 13 patients, shoulder ROM reached 90% of the contralateral side at 4 weeks, and the treatment was considered successful. Five patients had no pain at rest; however, they had mild residual restriction of shoulder motion.

Following initiation of treatment, the patients experienced rapid recovery of shoulder motion at 4 weeks, and this recovery was maintained at 6 months (Figures 1 and 2). Similarly, there was significant improvement in perception of pain and functional outcomes that was evident at 4 weeks and extended to 6 months (Figure 3). At the first follow-up at 4 weeks, significant improvement in shoulder ROM was noted in all directions except active and passive abduction. There was a significant reduction in the VAS scores ($p=0.018$) and a significant increase in the CM scores ($p=0.023$). The DASH and ASES scores did not show significant improvement in the first 4 weeks. At 6 months, there was a significant improvement in shoulder ROM in all directions compared with the previous visit, except external rotation. There were significant improvements in the DASH ($p=0.001$), VAS ($p=0.008$),

Table 3. Patient demographics and baseline shoulder range of motion and functional status.

Number of patients		18	
Sex	Female	13	
	Male	5	
Age, years		55 (24–82)	
Follow-up, months		16.4 (6–30)	
Body mass index, kg/m ²		27.6 (20.6–36.6)	
With occupation (employed)		12	
Systemic disease		8	
Affected shoulder	Dominant	12	
	Non-dominant	6	
Clinical scores	ASES score	32.9 (5–91.6)	
	DASH score	53.3 (22.7–70.5)	
	CM score	33 (12–96)	
	VAS score	7.5 (4–10)	
Range of motion	Flex.	Active	84.1° (60°–120°)
		Passive	94.4° (75°–120°)
	Abd.	Active	68.8° (45°–110°)
		Passive	80.5° (45°–120°)
	Ext. Rot.	Active	23° (10°–45°)
		Passive	33.3° (15°–45°)
	Int. Rot.	Active	19.7° (10°–45°)
		Passive	35.5° (20°–50°)

Data are presented as n or median (minimum–maximum).

ASES, American Shoulder and Elbow Surgeons; DASH, Disabilities of the Arm, Shoulder, and Hand; CM, Constant–Murley; VAS, visual analog scale; Flex., flexion; Abd., abduction; Ext. Rot., external rotation; Int. Rot.; internal rotation.

CM ($p=0.047$), and ASES ($p=0.023$) scores compared with the previous visit (Table 4). The significance of changes in shoulder motion, pain, and self-assessment scores compared with baseline and the previous follow-up are shown in Table 5.

The patients developed no adverse effects requiring termination of the medication. At the final follow-up, no patients had joint symptoms suggesting avascular necrosis. No patients required intra-articular injection, manipulation under anesthesia, capsular distention, or arthroscopic release during the treatment course or at the follow-up visits.

Discussion

The results of our study indicate that high-dose oral prednisolone treatment

(1 mg/kg/day) provided rapid recovery of shoulder function and resolution of symptoms, and the improvements extended into the mid-term. Most of the patients (72%) regained a functional level similar to that of the uninvolved extremity as early as 4 weeks, and the remaining patients had only mild residual disability with no pain at rest. This rapid recovery is consistent with the findings of previous studies on oral glucocorticoid use for frozen shoulder, which revealed significant improvement in functional outcomes and ROM as early as 3 weeks.^{5,21,22} Canbulat et al.⁹ noted a significant reduction in pain scores and recovery of shoulder motion as early as 1 week and improvement in the CM, ASES, and DASH scores in 6 weeks. Similarly, Blockey et al.¹⁴ compared oral glucocorticoids and placebo and noted superior recovery with oral

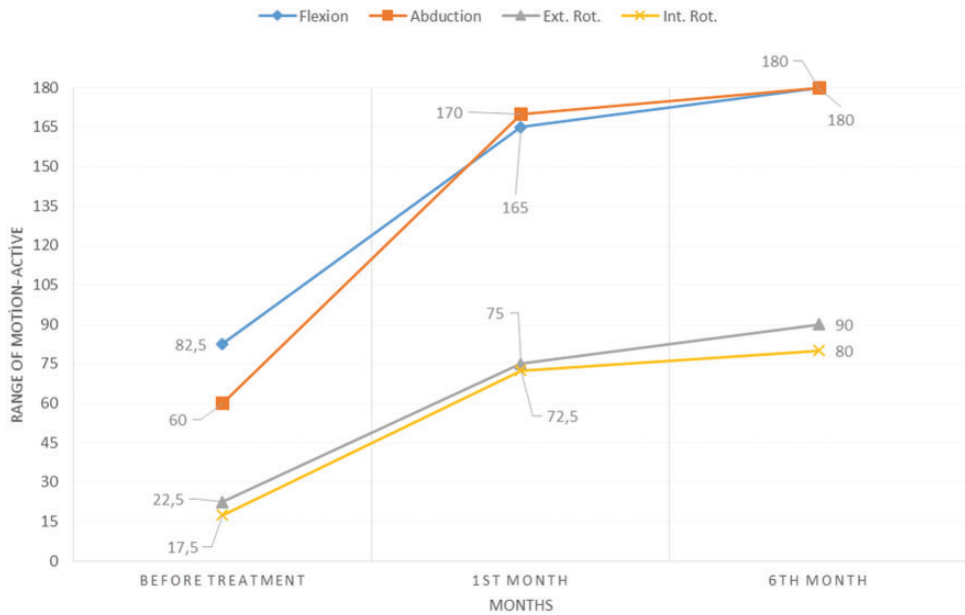


Figure 1. Change in active shoulder motion in all directions.

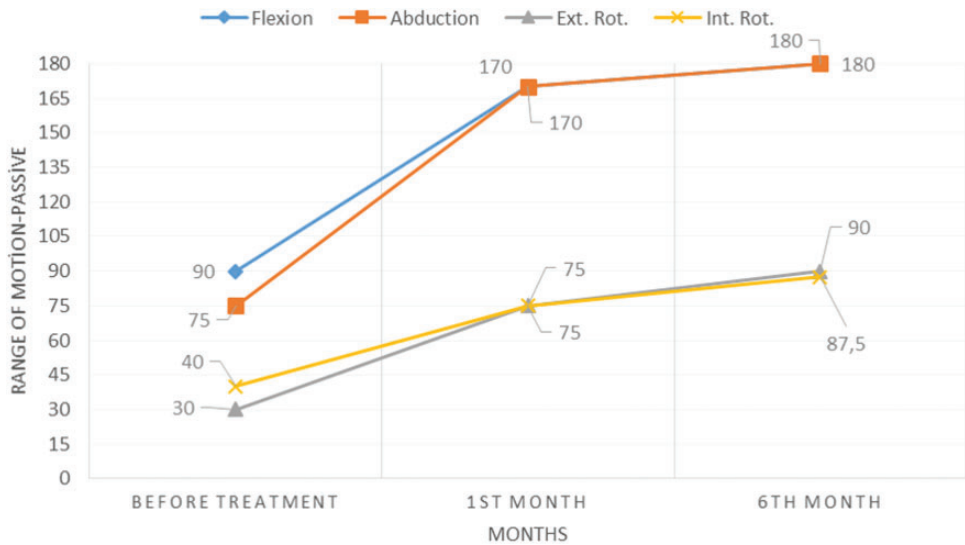


Figure 2. Change in passive shoulder motion in all directions.

glucocorticoid in the first few weeks. Widiastuti-Samekto and Sianturi²³ described 91% of their patients as “cured” at the end of 3 weeks.

All of the patient-reported outcome measurement scores showed marked improvement in the first 4 weeks. However, only the CM scores reached statistical

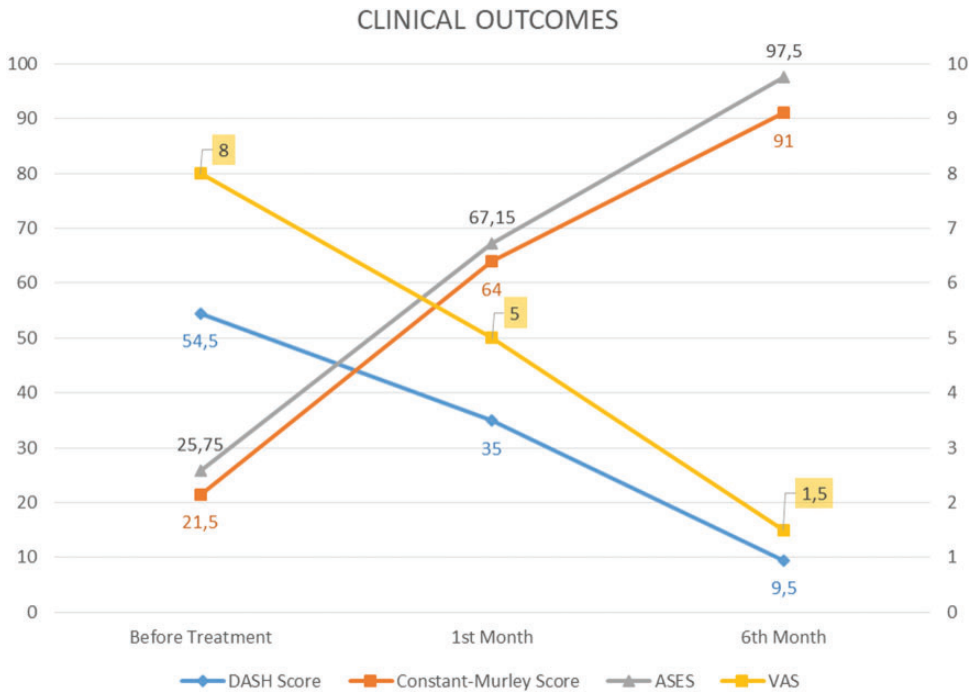


Figure 3. Change in pain and functional status throughout the study period.

significance in this early period. The ASES and DASH scores improved between 4 weeks and 6 months. This difference between assessment of functional recovery with the ASES, DASH, and CM scores may have been a result of the design of the individual questionnaires. A delayed response in the DASH score can be expected because this score is not a shoulder-specific disability measure and includes questions regarding several points irrelevant to frozen shoulder, such as tingling and wrist function. The difference between the CM and ASES scores was more surprising because both of these instruments are joint-specific. Although the mean ASES score improved from 26 to 65 in 4 weeks, this change did not reach statistical significance. The small sample size may explain why the null hypothesis could not be rejected. Another possible explanation is the alternating responsiveness of the CM and

ASES domains. Angst et al.²⁸ noted that the CM score had the highest responsiveness in the pain/symptoms domain, whereas the ASES score had superior responsiveness in functionality. It is possible that time is needed for the improvement in pain and ROM to reflect to the activities of daily living and perception of functionality.

The rapid recovery following the short-term high-dose oral prednisolone treatment in this study persisted long after discontinuation of the drug. There was significant improvement in pain scores, ROM, and all of the patient-reported outcomes at 6 months compared with both baseline and the previous visit. This finding contradicts most studies in the literature, which revealed a slowing down of rapid recovery or sometimes even deterioration after cessation of the drug. In a study by Chen et al.,²¹ the acceleration of improvement declined with time, and there was no improvement

Table 4. Change in shoulder range of motion, pain, and functional status throughout the study period.

	Before treatment	Fourth week	Sixth month
ROM-Active Group			
Flexion	82.5 (60–120)	165 (75–170)	180 (90–180)
Abduction	60 (45–110)	170 (90–170)	180 (90–180)
Internal rotation	17.5 (45–10)	72.5 (80–60)	80 (70–85)
External rotation	22.5 (10–45)	75 (30–90)	90 (45–90)
ROM-Passive Group			
Flexion	90 (75–120)	170 (120–170)	180 (120–180)
Abduction	75 (45–120)	170 (90–170)	180 (100–180)
Internal rotation	40 (20–50)	75 (65–85)	87.5 (80–90)
External rotation	30 (15–45)	75 (30–90)	90 (45–90)
Clinical outcomes			
DASH score	54.5 (22.7–70.5)	35 (10–40)	9.5 (2.5–28.3)
CM score	21.5 (12–90)	64 (48–72)	91 (54–100)
ASES score	25.75 (5–91.6)	67.15 (44.9–83.3)	97.5 (40–100)
VAS score	8 (4–10)	5 (3–6)	1.5 (0–4)

Data are expressed as median (minimum–maximum).

ROM, range of motion; DASH, Disabilities of the Arm, Shoulder, and Hand; CM, Constant–Murley; ASES, American Shoulder and Elbow Surgeons; VAS, visual analog scale.

between weeks 6 and 12. Similarly, Buchbinder et al.⁵ reported that improvements in pain, ROM, and functional scores at 3 weeks were not sustained beyond 6 weeks. The clinical status began to deteriorate following cessation of the drug, and the results were inferior to placebo at 12 weeks. The authors concluded that this may have been due to the rebound effect of sudden withdrawal of oral steroids. Similar to the study by Buchbinder et al.,⁵ Blockley et al.¹⁴ noted that the rapid and significant recovery in the first weeks declined after 4 weeks and that there was no difference compared with placebo at 18 weeks.

Studies by Lorbach et al.²² and Canbulat et al.⁹ showed more persistent recovery than the aforementioned reports. Their findings bear a closer resemblance to ours. Lorbach et al.²² reported rapid pain relief and improved ROM at 4 weeks. The significant improvement in the CM scores in 4 weeks was maintained throughout the study period (up to 12 months), and although

the pace of recovery slowed down, the pain levels were significantly lower at all time points compared with baseline. In the study by Canbulat et al.,⁹ the change in VAS scores with motion and the improvements in the CM, DASH, and ASES scores were statistically significant compared with subsequent measurements until the end of the first year.

Our treatment protocol involves the highest dose regimen to date. Typical treatment of an 80-kg patient would be initiated with a daily dose of 80 mg of prednisolone, which is more than double the maximum prednisolone-equivalent dose reported in the literature^{14,22} (Table 1). In most of the studies on oral administration of glucocorticoids for the treatment of frozen shoulder, the daily drug dose is given as a single dose in the morning to mimic the physiologic cortisone cycle. However, administering two-thirds of the total dose in the morning and one-third in the evening is also proposed to simulate the circadian cortisone rhythm.¹⁵ We preferred to give the drug

Table 5. Significance of improvement in shoulder ROM, pain, and functional outcomes throughout the study period.

	Clinical outcomes					ROM-Active					ROM-Passive				
	DASH score	CM score	ASES score	VAS score		Flexion	Abd	ER	IR		Flexion	Abd	ER	IR	
0 to 4 weeks	p = 0.137	p = 0.023*	p = 0.091	p = 0.018*	p = 0.037*	p = 0.008*	p = 0.059	p = 0.002*	p = 0.006*	p = 0.011*	p = 0.073	p = 0.018*	p = 0.008*		
4 weeks to 6 months	p = 0.001*	p = 0.047*	p = 0.023*	p = 0.008*	p = 0.008*	p = 0.014*	p = 0.287	p = 0.014*	p = 0.003*	p = 0.011*	p = 0.137	p = 0.008*			

*Statistically significant (p < 0.05).

ROM, range of motion; DASH, Disabilities of the Arm, Shoulder, and Hand; CM, Constant-Murley; ASES, American Shoulder and Elbow Surgeons; VAS, visual analog scale; Abd, abduction; ER, external rotation; IR, internal rotation.

twice a day in two equal doses for better patient compliance. Dividing the daily dose into two administrations along with prophylactic treatment with proton pump inhibitors and dietary restrictions probably helped to prevent adverse effects of glucocorticoids.

In our study, the medication regimen lasted approximately 24 days, including the period during which the daily dose was tapered. Treatment lasted 3 to 4 weeks in previous studies; our study used one of the shortest medication durations. Although the patients in our series received the highest total dose of prednisolone reported in the literature to date (1080 mg for an 80-kg adult), we observed no rebound affect, and there was steady improvement in shoulder function throughout the follow-up period (Tables 4 and 5). This may be because we began tapering the dose as early as the third day. Buchbinder et al.⁵ abruptly ceased the medication at 4 weeks without tapering the doses and observed symptom rebound.

The main strengths of this study are its homogenous patient sample, strictly defined exclusion criteria, and standardized treatment protocol. The two major limitations are the retrospective design of the study and the absence of a control group. A prospective design would have enabled us to form a placebo or supervised neglect group that did not receive any treatment; however, depriving a patient from treatment raises ethical concerns. The small sample size is another limiting factor, increasing the risk of type 2 statistical error.

Conclusion

High-dose oral prednisolone treatment (1 mg/kg/day) provides rapid resolution of symptoms, and this resolution persists long after discontinuation of the drug. The early treatment period is characterized by marked reduction in pain and rapid

recovery of shoulder motion. Improvements in functional outcome and disability indices tend to be more subtle in this period but improve significantly during the late course of treatment.

Declaration of conflicting interest

The authors declare that there is no conflict of interest.

Funding

This research received no specific grant from any funding agency in the public, commercial, or not-for-profit sectors.

ORCID iDs

Teoman Atici  <https://orcid.org/0000-0003-3063-1930>

Selcan Akesen  <https://orcid.org/0000-0002-9518-541X>

Ali Özyalçın  <https://orcid.org/0000-0003-3772-1699>

References

1. Abrassart S, Kolo F, Piotton S, et al. 'Frozen shoulder' is ill-defined. How can it be described better? *EFORT Open Rev* 2020; 5: 273–279. doi: 10.1302/2058-5241.5.190032.
2. Le HV, Lee SJ, Nazarian A, et al. Adhesive capsulitis of the shoulder: review of pathophysiology and current clinical treatments. *Shoulder Elbow* 2017; 9: 75–84. doi: 10.1177/1758573216676786
3. Neviasser JS. Adhesive capsulitis of the shoulder: a study of the pathological findings in peri-arthritis of the shoulder. *J Bone Joint Surg* 1945; 27: 211–222.
4. Rangan A, Brealey SD, Keding A, et al. UK FROST Study Group. Management of adults with primary frozen shoulder in secondary care (UK FROST): a multicentre, pragmatic, three-arm, superiority randomised clinical trial. *Lancet* 2020; 396: 977–989. doi: 10.1016/S0140-6736(20)31965-6.
5. Buchbinder R, Green S, Youd JM, et al. Oral steroids for adhesive capsulitis. *Cochrane Database Syst Rev* 2006; (4): CD006189. doi: 10.1002/14651858.CD006189.
6. Atıcı T, Şahin N, Mocan M, et al. Donuk Omuz: Tanı-Tedavi. *Uludağ Tıp Derg* 2013; 39: 211–218.
7. Cho CH, Jin HJ and Kim DH. Comparison of clinical outcomes between idiopathic frozen shoulder and diabetic frozen shoulder after a single ultrasound-guided intra-articular corticosteroid injection. *Diagnostics (Basel)* 2020; 10: 370. doi: 10.3390/diagnostics10060370.
8. Reeves B. The natural history of the frozen shoulder syndrome. *Scand J Rheumatol* 1975; 4: 193–196. doi: 10.3109/03009747509165255
9. Canbulat N, Eren I, Atalar AC, et al. Nonoperative treatment of frozen shoulder: oral glucocorticoids. *Int Orthop* 2015; 39: 249–254. doi: 10.1007/s00264-014-2650-1
10. Hannafin JA and Chiaia TA. Adhesive capsulitis. A treatment approach. *Clin Orthop Relat Res* 2000; 372: 95–109.
11. Neviasser AS and Neviasser RJ. Adhesive capsulitis of the shoulder. *J Am Acad Orthop Surg* 2011; 19: 536–542. doi: 10.5435/00124635-201109000-00004
12. Yilmazlar A, Türker G, Atıcı T, et al. Functional results of conservative therapy accompanied by interscalane brachial plexus block and patient-controlled analgesia in cases with frozen shoulder. *Acta Orthop Traumatol Turc* 2010; 44: 105–110. doi: 10.3944/AOTT.2010.2144
13. Diercks RL and Stevens M. Gentle thawing of the frozen shoulder: a prospective study of supervised neglect versus intensive physical therapy in seventy-seven patients with frozen shoulder syndrome followed up for two years. *J Shoulder Elbow Surg* 2004; 13: 499–502. doi: 10.1016/j.jse.2004.03.002
14. Blockey NJ, Wright JK and Kellgren JH. Oral cortisone therapy in peri-arthritis of the shoulder; a controlled trial. *Br Med J* 1954; 1: 1455–1457. doi: 10.1136/bmj.1.4877.1455
15. Miller M, Cho JY, McElwain K, et al. Corticosteroids prevent myofibroblast accumulation and airway remodeling in mice. *Am J Physiol Lung Cell Mol Physiol*

- 2006; 290: L162–L169. doi: 10.1152/ajplung.00252.2005.
16. Hagiwara Y, Sugaya H, Takahashi N, et al. Effects of intra-articular steroid injection before pan-capsular release in patients with refractory frozen shoulder. *Knee Surg Sports Traumatol Arthrosc* 2015; 23: 1536–1541. doi: 10.1007/s00167-014-2936-2
 17. Kim YS, Lee HJ, Lee DH, et al. Comparison of high- and low-dose intra-articular triamcinolone acetonide injection for treatment of primary shoulder stiffness: a prospective randomized trial. *J Shoulder Elbow Surg* 2017; 26: 209–215. doi: 10.1016/j.jse.2016.09.034
 18. Ranalletta M, Rossi LA, Bongiovanni SL, et al. Corticosteroid injections accelerate pain relief and recovery of function compared with oral NSAIDs in patients with adhesive capsulitis: a randomized controlled trial. *Am J Sports Med* 2016; 44: 474–481. doi: 10.1177/0363546515616238
 19. Sun Y, Liu S, Chen S, et al. The effect of corticosteroid injection into rotator interval for early frozen shoulder: a randomized controlled trial. *Am J Sports Med* 2018; 46: 663–670. doi: 10.1177/0363546517744171. Epub 2017 Dec 21.
 20. Buchbinder R, Hoving JL, Green S, et al. Short course prednisolone for adhesive capsulitis (frozen shoulder or stiff painful shoulder): a randomised, double blind, placebo controlled trial. *Ann Rheum Dis* 2004; 63: 1460–1469. doi: 10.1136/ard.2003.018218
 21. Chen CY, Hu CC, Weng PW, et al. Extracorporeal shockwave therapy improves short-term functional outcomes of shoulder adhesive capsulitis. *J Shoulder Elbow Surg* 2014; 23: 1843–1851. doi: 10.1016/j.jse.2014.08.010
 22. Lorbach O, Anagnostakos K, Scherf C, et al. Nonoperative management of adhesive capsulitis of the shoulder: oral cortisone application versus intra-articular cortisone injections. *J Shoulder Elbow Surg* 2010; 19: 172–179. doi: 10.1016/j.jse.2009.06.013
 23. Widiastuti-Samekto M and Sianturi GP. Frozen shoulder syndrome: comparison of oral route corticosteroid and intra-articular corticosteroid injection. *Med J Malaysia* 2004; 59: 312–316.
 24. Von Elm E, Altman DG, Egger M, et al. The Strengthening the Reporting of Observational Studies in Epidemiology (STROBE) statement: guidelines for reporting observational studies. *Ann Intern Med* 2007; 147: 573–577. doi: 10.7326/0003-4819-147-8-200710160-00010. Erratum in: *Ann Intern Med*. 2008 Jan 15; 148(2): 168.
 25. Hudak PL, Amadio PC and Bombardier C. Development of an upper extremity outcome measure: the DASH (disabilities of the arm, shoulder and hand) [corrected]. The Upper Extremity Collaborative Group (UECG). *Am J Ind Med* 1996; 29: 602–608. doi: 10.1002/(SICI)1097-0274(199606)29:6<602::AID-AJIM4>3.0.CO; 2-L. Erratum in: *Am J Ind Med* 1996 Sep; 30(3): 372.
 26. Richards RR, An KN, Bigliani LU, et al. A standardized method for the assessment of shoulder function. *J Shoulder Elbow Surg* 1994; 3: 347–352. doi: 10.1016/S1058-2746(09)80019-0. Epub 2009 Feb 13.
 27. Constant CR and Murley AH. A clinical method of functional assessment of the shoulder. *Clin Orthop Relat Res* 1987; (214): 160–164.
 28. Angst F, Goldhahn J, Drerup S, et al. Responsiveness of six outcome assessment instruments in total shoulder arthroplasty. *Arthritis Rheum* 2008; 59: 391–398. doi: 10.1002/art.23318.