

## CASE REPORT

# Glanzmann Thrombasthenia: Use of the Soft Splint with Tranexamic Acid Paste to Reduce Spontaneous Oral Bleeding

R Bhavyaa<sup>1</sup>, KC Vignesh<sup>2</sup>, MS Muthu<sup>3</sup>, Selvakumar Haridoss<sup>4</sup>, S Abirami<sup>5</sup>

### ABSTRACT

**Background:** Glanzmann thrombasthenia is a rare bleeding disorder due to defects in the glycoprotein IIb/IIIa complex present on the platelet membrane. The most common mode of treatment for this disorder is platelet transfusion. However, scientific evidence does state that repeated transfusions could lead to auto immunization making transfusions ineffective.

**Aim and objective:** To describe the use of a novel technique of soft splint with tranexamic acid paste to stop oral bleeding in a patient with Glanzmann thrombasthenia (GT).

**Case description:** A 7-year-old female patient with a known history of GT was referred to the pediatric department. The chief complaint of the patient revealed a history of spontaneous bleeding from the oral cavity. The patient required multiple teeth extractions due to severely carious teeth. History revealed that the patient was admitted to the hospital (casualty) three times within 1 month due to a similar complaint leading to hypovolemic shock. Several transfusion procedures were done to stop the spontaneous bleeding. To stop the intraoral bleeding without transfusions, a novel method of using a soft splint with tranexamic acid paste (500 mg tablet crushed and mixed with saline) in the area of spontaneous bleeding was employed with a successful follow-up of 7 months.

**Conclusion:** Soft splint with the tranexamic acid paste can serve as an effective method of treatment for patients with spontaneous oral bleeding due to medical conditions like GT.

**Clinical relevance:** This case report highlights the need for awareness among all the healthcare providers about the importance of regular dental visits. The healthcare providers also need to emphasize the same to all patients with medical conditions to avoid such life-threatening situations.

**Keywords:** Glanzmann thrombasthenia, Oral bleeding, Soft splint, Tranexamic acid.

*International Journal of Clinical Pediatric Dentistry* (2021): 10.5005/jp-journals-10005-1973

### BACKGROUND

Glanzmann's thrombasthenia (GT) (OMIM-#273800) was first described by Dr Eduard Glanzmann, a German pediatrician in 1918 as "Hereditary Haemorrhagic Thrombasthenia".<sup>1</sup> It is a rare inherited autosomal recessive platelet disorder with an incidence of about 1 in 1,000,000.<sup>2</sup> High incidence rate is found to be in consanguineous populations like French Gypsies, Iraqi Jews, Jordanian Arabs, and South Indians where intermarriage is common.<sup>3</sup> Both the genders are equally affected since the gene responsible for GT is carried on the long arm of chromosome 17 (17; q 21-22) one of the 22 pairs of autosomal chromosomes, in humans.<sup>4</sup>

Glanzmann thrombasthenia is a qualitative and/or a quantitative defect in the GP IIb/IIIa glycoprotein complex.<sup>5</sup> Diagnosis of GT usually occurs at a very early age due to spontaneous and unexplained bleeding. It is characterized by prolonged bleeding time, while platelet count, and morphology, as well as prothrombin time (PT) and partial thromboplastin time (PTT), remain unaffected.<sup>4</sup> Key clinical features include purpura, epistaxis, gingival hemorrhage, and menorrhagia.<sup>6</sup> For extraction of teeth or hemorrhage associated with loss of deciduous teeth, control of bleeding becomes a complex process. Antifibrinolytic agents, tranexamic acid had been broadly used in oral surgery. It blocks bleeding by inhibiting the degradation of the thrombus.<sup>7</sup>

Management of GT usually includes supportive measures and transfusions. However, repeated transfusions can lead to the development of self anti-GPIIb/IIIa antibodies making it ineffective and further complicating the treatment.<sup>5</sup> Thus, the purpose of this report is to highlight the use of soft splint along with tranexamic acid paste to reduce the bleeding episodes in a 7-year-old female

<sup>1,2,4,5</sup>Department of Pediatric and Preventive Dentistry, Sri Ramachandra Dental College and Hospital, Sri Ramachandra Institute of Higher Education and Research, Chennai, Tamil Nadu, India

<sup>3</sup>Centre for Early Childhood Caries Research (CECCR), Department of Pediatric and Preventive Dentistry, Sri Ramachandra Dental College and Hospital, Sri Ramachandra Institute of Higher Education and Research, Chennai, Tamil Nadu, India; Centre of Medical and Bio-Allied Health Sciences Research, Ajman University, Ajman, United Arab Emirates

**Corresponding Author:** MS Muthu, Centre for Early Childhood Caries Research (CECCR), Department of Pediatric and Preventive Dentistry, Sri Ramachandra Dental College and Hospital, Sri Ramachandra Institute of Higher Education and Research, Chennai, Tamil Nadu, India; Centre of Medical and Bio-Allied Health Sciences Research, Ajman University, Ajman, United Arab Emirates, Phone: +91 9444045094, e-mail: muthumurugan@gmail.com

**How to cite this article:** Bhavyaa R, Vignesh KC, Muthu MS, *et al.* Glanzmann Thrombasthenia: Use of the Soft Splint with Tranexamic Acid Paste to Reduce Spontaneous Oral Bleeding. *Int J Clin Pediatr Dent* 2021;14(4):580-585.

**Source of support:** Nil

**Conflict of interest:** None

patient with spontaneous bleeding accompanying the eruption of teeth. The child also required multiple tooth extraction due to grossly decayed teeth. The patient was admitted to the casualty three times within 1 month due to bleeding from the oral cavity leading to hypovolemic shock owing to a severe fall in Hb levels. This case report also enlightens the need for awareness of such

patients about the importance of oral hygiene maintenance and regular dental visit.

### CASE DESCRIPTION

A 7-year-old female patient admitted to the pediatric intensive care unit (ICU) with a known medical history of GT was referred to a pediatric dentist for opinion and management for bleeding gums. The patient presented with a chief complaint of severe bleeding from the upper left back tooth region since the previous night. History of presenting illness revealed that the patient was apparently normal the previous day morning, after which spontaneous bleeding started by afternoon leading to severe blood loss and hypovolemic shock for which she was admitted to the ICU. Bleeding was continuous; there were no aggravating or relieving factors. Previous hospitalization history revealed she was admitted twice earlier within a period of 30 days, with a similar complaint of bleeding from the oral cavity leading to a significant decrease in the hemoglobin (Hb) levels. No dental treatment was performed in the earlier visits, as it was advised by the pediatrician to wait for a month for the complete recovery of the patient. The parent also gave a history of a similar episode of bleeding from gums, vomiting containing clots of blood 1 year back with decreased Hb level at the time of hospitalization. The patient was discharged without being referred to the dentist one year back. A family history of consanguineous marriage was present. On extraoral examination, purpuric spots were seen in the left leg along with crusting and bleeding from the lips. Intraoral examination revealed root stump in relation to 54, 65, dental caries in relation to 53, 74, 36, and mobile crown structure in relation to 75, 55. Spontaneous bleeding was evident from 54, 55, 21, 11, 12, 22, and 46 and the patient also had anterior tooth crossbite in relation to 11, 21 (Fig. 1). The provisional diagnosis was given as gingivitis and chronic irreversible pulpitis in relation to 55, 54, 65, 75.

### Investigation

Laboratory investigation revealed a hemoglobin level of 1.3 g/dL on the night of admission. The next day the prothrombin time was 18.2 seconds, partial thromboplastin time was 22.8 seconds, international normalized ratio (INR) was 1.70, and hemoglobin was 6 g/dL. On the day of performing the dental procedure (fourth day of admission) as mentioned below, the hemoglobin level was 11 mg/dL, platelet count was 141,000, and bleeding time was 16.5 seconds. Orthopantomogram (OPG) revealed root stump

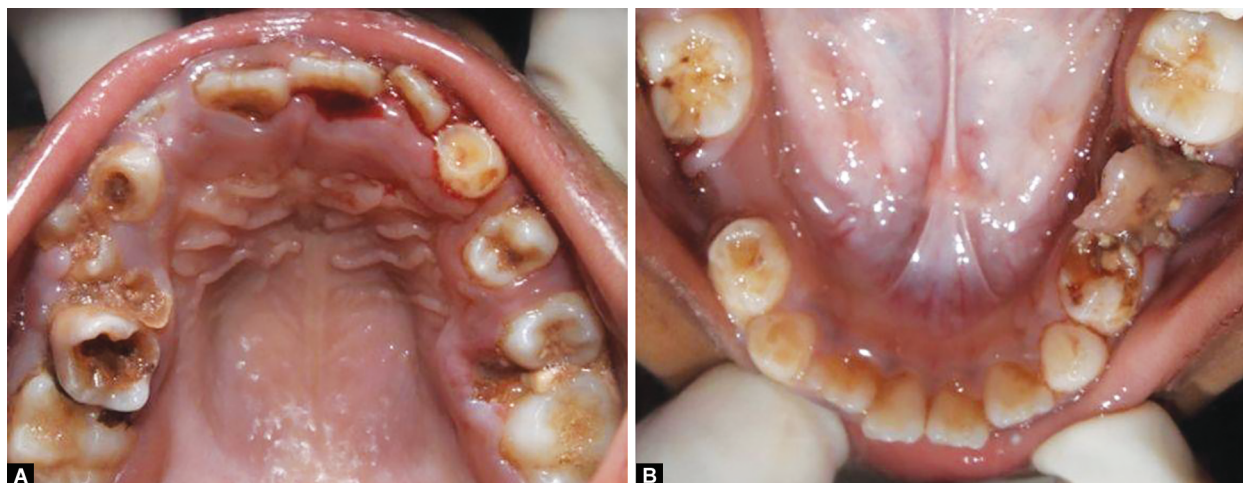
in relation to 54, 65, dental caries involving enamel, dentin, and approximating pulp in relation to 53, 74, and resorbed roots in relation to 75, 55 (Fig. 2).

### Treatment Planned

Consent was taken from the pediatrician and hematologist. Treatment planned was oral prophylaxis followed by extraction of 55, 54, 65, and 75. Placement of soft splint with absorbable gelatin sponge (Ab gel, Sri Gopal Krishna Lab Private Limited, India) after extraction. Restorative treatment included deep caries management in relation to 53 and 74, followed by stainless steel crown in 74, glass ionomer restoration in 36, pit and fissure sealants in 16, 46, 26.

### Treatment Rendered

After being admitted to the ICU, two units of random donor platelet and two units of packed cell volume transfusions were performed and the patient was shifted to the ward after an increase in the Hb levels. Two units of random donor platelets transfusion were performed on the next day. The patient was advised to use tranexamic acid mouth wash (500 mg tablet mixed with 10 mL of water—5%) 6 times a day for 2 days before the procedure. Instructions regarding maintenance of good oral hygiene and use of a soft-bristled toothbrush with fluoridated toothpaste and brushing using the Fones technique were emphasized. The dental procedure was planned for the fourth day. Half a unit of single donor platelets was infused pre- and postoperatively. Impression was made using putty and a soft splint (1.5 mm thick) was prepared. Following buccal infiltration, extraction of 55, 54, 65, and 75 was done. Tranexamic acid (500 mg tablet) was then powdered using mortar and pestle, mixed with saline, and packed into the socket. A paste of tranexamic acid was made, placed on gauze, and held with pressure for ten minutes on the socket after which the gauze was removed. The patient was advised to swallow the remaining tranexamic acid paste. An absorbable gelatin sponge (Ab gel, Sri Gopal Krishna Lab Private Limited, India) was then packed into the socket (Fig. 3) followed by splint placement. Post extraction instructions were given and the patient was advised to keep the splint in place. The patient has advised a liquid diet until the next day and intravenous (IV) paracetamol and tranexamic acid (200 mg) 6 hours once were prescribed to the patient. After 2 hours, the patient did not show any signs of active bleeding. The splint was removed, the next day. No active bleeding was evident from the



Figs 1A and B: Preoperative intraoral photographs: (A) Maxillary arch; (B) Mandibular arch

extraction socket. The patient was advised to wear a soft splint for two more days except during meals.

The patient was instructed to stop using the splint from the seventh day of admission (3 days after the dental procedure) and no active bleeding was evident from the extraction sockets. Few hours after removal of the splint, there was spontaneous bleeding from 12, 11, 21, 22, 46 and an extraction socket of 55. One unit of random donor platelets was infused on that day followed by infusion of half unit of single donor platelets the next day. Intermittent spontaneous bleeding was evident from the 11, 12, 21, 22, and 46 region. On the tenth day (sixth day of dental procedure),

the remaining dental procedures were performed after infusion of one unit of random donor platelets pre- and postoperatively. Oral prophylaxis followed by deep caries management in 53, 74 with stainless steel crown in 74, glass ionomer restoration in 36, and type VII glass ionomer sealant in 16, 26, 46. Postoperatively, oral hygiene instructions were reinforced and IV tranexamic acid 200 mg once in 6 hours was prescribed. Spontaneous bleeding was still evident from 11, 12, 21, 22, and 46 the next day. The pediatrician advised stopping the oral bleeding to discharge the patient. Hence, on the eleventh day (the seventh day after the dental procedure), it was decided to use tranexamic acid paste (crush 500 mg of tranexamic acid and mix with saline) in the area of bleeding on the splint (Fig. 4) and then place the splint intraorally. The patient was advised to keep the splint in place for 2 hours after which they were instructed to remove the splint and swallow the remaining tranexamic acid paste. The parent was advised to do the same whenever spontaneous bleeding occurred. The parent was also advised not to use more than two tablets of tranexamic acid (500 mg) each per day based on its maximum permissible dosage. Bleeding was completely reduced after 2 days of using this technique and the patient was discharged from the hospital.

**Home Measures**

Diet counseling was done. Stringent oral hygiene instructions were advocated by the patient. The patient was advised to use a

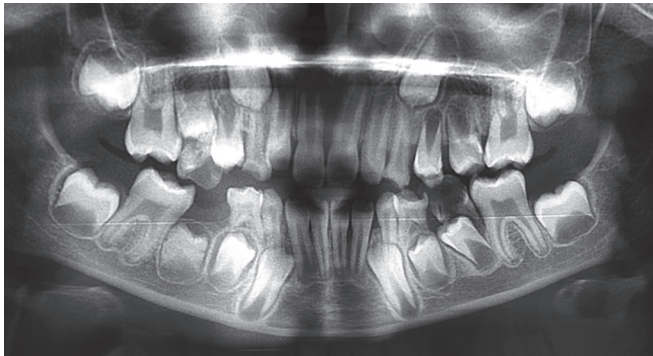
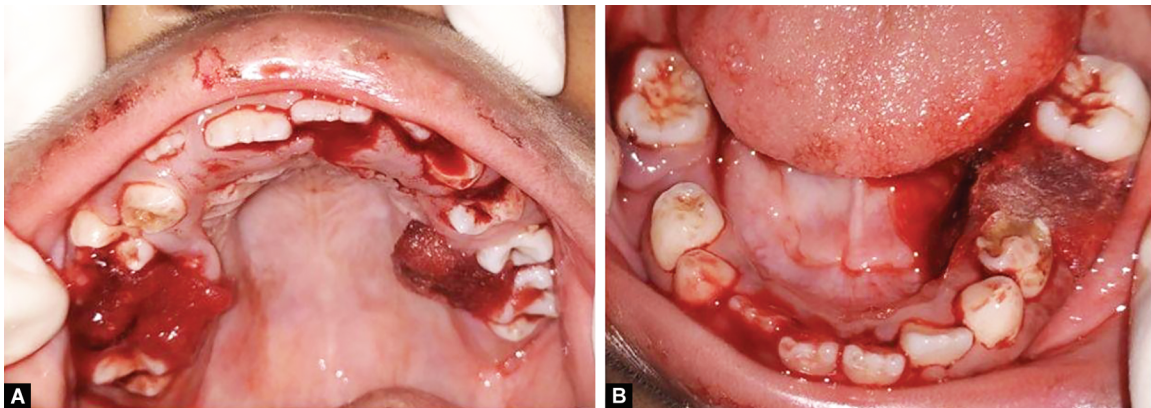
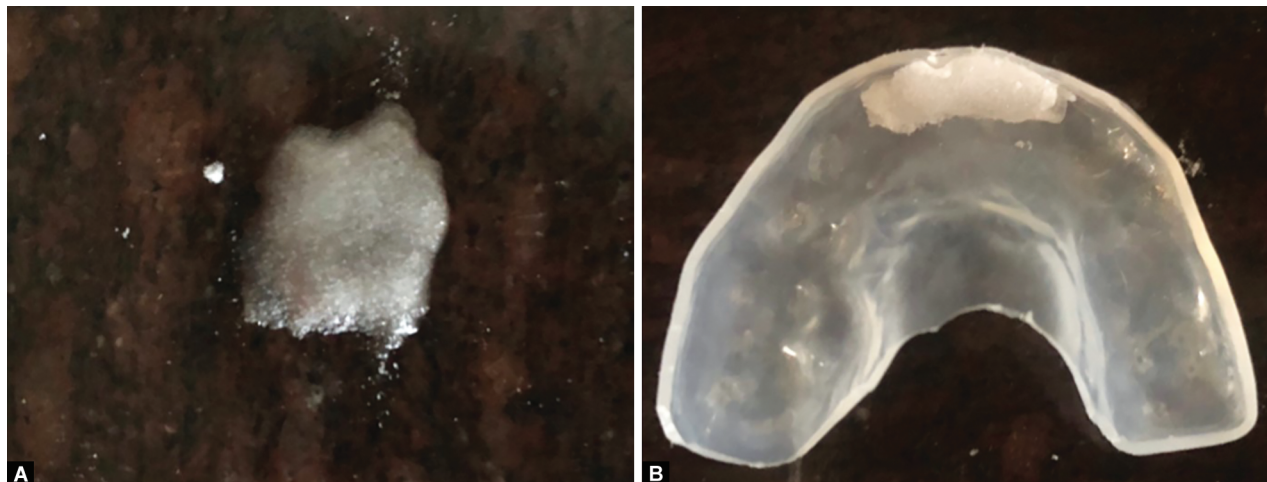


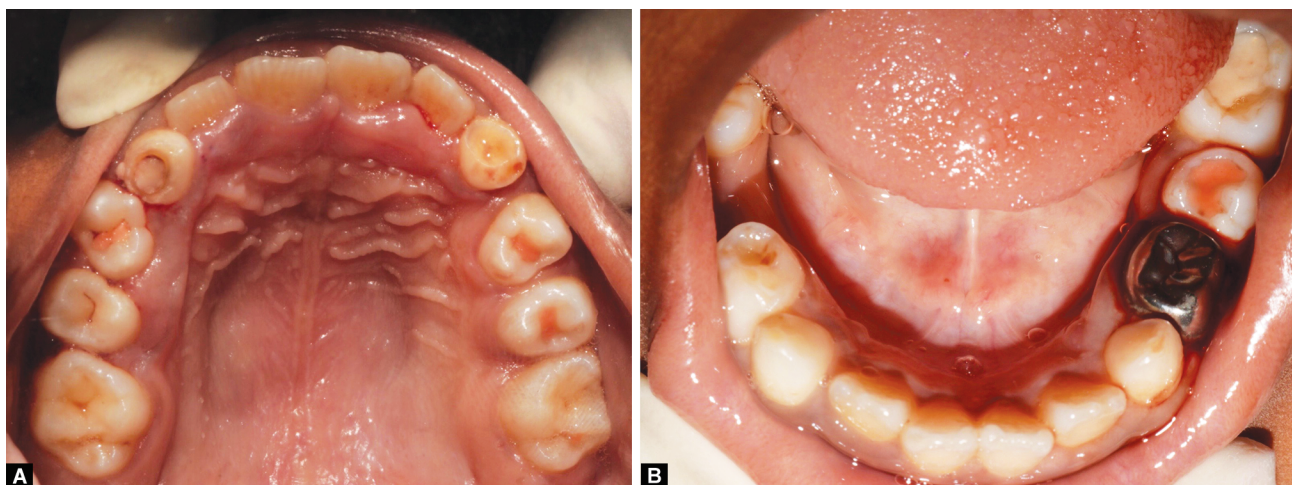
Fig. 2: Preoperative radiograph-orthopantomogram



Figs 3A and B: Placement of Ab gel foam inside the extraction socket



Figs 4A and B: Tranexamic acid paste and its placement in the area of spontaneous bleeding



**Figs 5A and B:** Seven months follow-up—intraoral photographs: (A) Maxillary arch; (B) Mandibular arch

soft-bristled toothbrush, fluoridated toothpaste, and gargle after every meal. Also, the parent was advised to use the soft splint with tranexamic acid paste whenever bleeding occurred.

### Outcome and Follow-up

Postoperatively, a 1-week follow-up revealed no active bleeding from gums. The patient has been reviewed every month for 4 months. The parent gave a history of using soft splint with tranexamic acid paste in the first 2 months during the eruption of the premolars with no history of hospitalization. Sealants were placed in relation to the premolars in the subsequent follow-up visits. At 7 months follow-up, there was no active bleeding and no history of hospitalization (Fig. 5). Loss of sealants was evident in relation to 16, 15, and 26 which was replaced.

### DISCUSSION

Glanzmann thrombasthenia is a rare inherited platelet disorder that occurs due to the mutation of glycoprotein (GP) IIb–IIIa that is present on the surface of platelets.<sup>1</sup> The primary target area of this glycoprotein is fibrinogen, which is responsible for platelet aggregation. Thus, this condition manifests as defective platelet aggregation and decreased or absence of clot retraction, while the platelet count and morphology remain normal<sup>8</sup> as observed in our case. Platelet aggregation and flow cytometry are the most important diagnostic test for this condition. In GT, platelet does not aggregate to adenosine diphosphate (ADP), thrombin, epinephrine, collagen, and arachidonic acid as these depend on fibrinogen attachment to the platelet for aggregation.<sup>3</sup> Flow cytometry helps in detecting the quantity of the GP IIb–IIIa complex based on which GT can be classified by George et al.<sup>9</sup> into three types. While GT type (I and II) have some amount of GP IIb–IIIa, patients could still have severe recurrent hemorrhagic episodes while patients with type III (inactive GP IIb–IIIa) may have mild clinical manifestations. This makes both the test and classification indecisive in diagnosing the severity of the condition.<sup>9</sup> The bleeding conditions are clearly defined which include purpura, epistaxis, gingival hemorrhage, and menorrhagia. Gingival hemorrhage is usually associated with poor oral hygiene and is not present in patients with regular dental visits. Although it is said to be rarely associated with major acute blood loss,<sup>9</sup> it is contrary to our case report where the child suffered from acute blood loss, leading to hypovolemic shock due to poor oral

hygiene. Spontaneous oral bleeding could also be associated with severely decayed teeth and eruption of permanent teeth<sup>9</sup> which were contributing factors in this case leading to severe fall in Hb level. Gastrointestinal hemorrhage, hematuria, and hemarthroses have also been reported in the literature although not positive in our case.<sup>9</sup>

The differential diagnosis for this condition includes other bleeding disorders like Bernard–Soulier syndrome, a disorder of adhesion.<sup>8</sup> The presence of normal platelet size and ristocetin-induced aggregation rules out the above syndrome.<sup>8</sup> Similarly, thrombocytopenia is eliminated by normal platelet count while the presence of normal clotting factors excludes the other clotting disorders like hemophilia and Von Willebrand's disease.<sup>8</sup> Since, our case was diagnosed at 1 year of age, no test was performed at the time of admission.

Management is provided by supportive care and most importantly by hemostatic measures along with platelet transfusions.<sup>9</sup> Definitive treatment is by hematopoietic transplantation (HSBT) from the siblings,<sup>10</sup> however, due to the increased risk associated with the procedure, it is recommended only in cases of severe hemorrhage or development of autoimmunization.<sup>11</sup> Bleeding in GT is usually unpredictable<sup>9</sup> and hence platelet transfusions before any invasive procedure is indicated even if minimal bleeding is expected and advised until wound healing is incomplete. Thus, platelet transfusions were performed before and after restorative procedures in our case. Traditionally after extraction, bleeding is controlled by three methods, antifibrinolytic drugs, hemostatic agents, and physical barriers. Spontaneous bleeding is usually treated by oral prophylaxis and maintenance of meticulous oral hygiene<sup>2,5,6</sup> which was followed in our case as well. Drugs that affect the platelet function like non-steroidal anti-inflammatory drugs (NSAID) and aspirin are contraindicated<sup>9</sup> thereby, paracetamol<sup>7,12</sup> was used as an analgesic after extraction in our case. Tramadol<sup>14</sup> is also considered an ideal analgesic that can be used safely in GT patients with severe pain.

The antifibrinolytic agents recommended for bleeding disorders are Epsilon aminocaproic acid (EACA),<sup>4</sup> tranexamic acid,<sup>13</sup> and desmopressin.<sup>14</sup> Desmopressin has been tested as a therapeutic measure for GT, but due to a lack of clinical evidence in the literature, it was not used in our case.<sup>14</sup> Tranexamic acid is a derivative of amino acid lysine. It acts primarily by blocking the lysine binding

sites on plasminogen molecules. This in turn inhibits the formation of plasmin that interferes with fibrinolysis, thereby preventing the breaking down of the clot.<sup>15</sup> Mannucci and Levi<sup>16</sup> proved that tranexamic acid was ten times more potent than EACA. Thus, tranexamic acid was used in our case. Preoperatively, tranexamic acid mouth wash was prepared freshly and used two days before the procedure as recommended by Nuvvula et al.<sup>17</sup> to decrease the episodes of spontaneous bleeding. After the extraction procedure, tranexamic acid was crushed and mixed with saline, and placed on a gauze piece. It was held on to the socket for 10 minutes. Coetzee<sup>18</sup> had recommended the same procedure for a duration of 30 minutes, but due to multiple extractions in different sites, we had placed tranexamic acid only for 10 minutes. Tranexamic acid was also effectively used postoperatively and as a home remedy to stop bleeding by placing it on the splint in the area of bleeding. The commonly advocated hemostatic agents are microfibrillar collagen,<sup>19</sup> resorbable oxidized cellulose,<sup>4,7</sup> and gel foam soaked in topical thrombin.<sup>9</sup> In our case, resorbable oxidized cellulose (Ab foam gel) was placed inside the sockets after extraction to achieve hemostasis.

Acrylic splints<sup>20,21</sup> and soft splints<sup>8,9,22</sup> can be used as physical barriers to preserve the blood clot in its position and reduce bleeding. Due to the presence of clasp in acrylic splints that could irritate, the soft splint was used in this case. As per the evidence stated in the literature, soft splint has been used widely to act as a physical barrier after any surgical procedures in patients with GT.<sup>8,9,22</sup> Therefore, we developed this novel technique of using a paste of tranexamic acid (500 mg tablet powdered with mortar and pestle and mixed with saline)<sup>23</sup> to reduce the spontaneous bleeding, postoperatively. The patient was instructed to apply the paste on the soft splint in the area where spontaneous bleeding was occurring then place the splint intraorally and leave it in place for 30 minutes<sup>18</sup> followings which they were advised to remove the soft splint and swallow the remaining paste. In our case report, it was noted that the patient continued to have spontaneous gingival bleeding from areas other than the extraction socket even after oral prophylaxis which could be due to the eruption of permanent teeth. This perhaps would have led to the patient requiring multiple transfusions. According to the literature, it was found that multiple transfusions could lead to the development of alloimmunization which is noted in 30 to 70% of the cases.<sup>24</sup> This is due to the development of self anti-GP IIb-IIIa antibodies<sup>5</sup> which can be detected by complement fixation, ELISA, and flow cytometry,<sup>25-28</sup> leading to massive bleeding. This could further complicate the treatment as it makes transfusions ineffective. A case report by Ghosh et al.<sup>29</sup> performed a full mouth extraction for a patient with GT to avoid repeated transfusions, where spontaneous bleeding continued to occur even after oral prophylaxis leading to severe fall in hemoglobin level which was similar to our case. Considering the young age of the patient, mixed dentition stage, and effects of repeated transfusions, a novel technique of using a paste of tranexamic acid did seem to reduce bleeding from the oral cavity, thus avoiding repeated transfusions.

As a home remedy measure, the patient was taught how to prepare the paste and place it on the splint. This was done as a precautionary measure, as chances of spontaneous bleeding were high due to the extraction of multiple teeth and eruption of permanent teeth. According to the guidelines,<sup>30</sup> the recommended dosage for tranexamic acid (orally) is 15 to 25 mg/kg, 3 to 4 times a day with a maximum dose of 1.5 g. Thus, the patient was advised

not to use more than two tablets per day. Soft splints also have the added advantage of snugly fitting on the teeth and hence do not induce bleeding.<sup>9</sup> Follow-up was done every month, and the patient gave a history of using this technique of soft splint with tranexamic acid paste twice in the first 2 months. Seven months follow-up revealed no history of any need for hospitalization.

## CONCLUSION

This case report paves a way for further research to prove if this novel technique could act as an effective treatment option to stop spontaneous bleeding from the oral cavity in patients with GT. Also, as the patient was in the mixed dentition phase, soft splint aided both as a physical barrier to achieve hemostasis during extraction and during the shedding of deciduous teeth. However, the need for repeated splint fabrication is still questionable as this patient is in the mixed dentition phase.

## CLINICAL SIGNIFICANCE

Due to the severity of the condition, a multidisciplinary team approach is needed comprising of pediatrician, hematologist, and pediatric dentist for effective management. Maintenance of good oral hygiene and regular dental visits could have prevented this child from requiring multiple transfusions. Hence, it is the need of the hour to create awareness among pediatricians, hematologists, and other healthcare providers about the importance of emphasizing regular dental visits to all patients with severe medical conditions. The authors also recommend that the usage of this technique could reduce bleeding in patients with other bleeding disorders.

## REFERENCES

1. Bisch FC, Bowen KJ, Hanson BS, et al. Dental considerations for a Glanzmann's thrombasthenia patient: case report. *J Periodontol* 1996;67(5):536-540. DOI: 10.1902/jop.1996.67.5.536.
2. Venkat V, Kalluri S, Bandalore Hanumantha SR. Glanzmann's thrombasthenia – a rare case report of spontaneous gingival bleeding. *J Indian Acad Oral Med Radiol* 2018;30(1):88-91. DOI: 10.4103/jiaomr.jiaomr\_43\_17.
3. Sebastiano C, Bromberg M, Breen K, et al. Glanzmann's thrombasthenia: report of a case and review of the literature. *Int J Clin Exp Pathol* 2010;3(4):443-447.
4. Gopalakrishnan A, Veeraraghavan R, Panicker P. Hematological and surgical management in Glanzmann's thrombasthenia: a case report. *J Indian Soc Pedod Prev Dent* 2014;32(2):181-184. DOI: 10.4103/0970-4388.131000.
5. Kantarci A, Cebeci I, Firatli E, et al. Periodontal management of Glanzmann's thrombasthenia: report of 3 cases. *J Periodontol* 1996;67(8):816-820. DOI: 10.1902/jop.1996.67.8.816.
6. Yadalam U, Kranti K, Seshan H. Periodontal considerations for Glanzmann's thrombasthenic patient. *J Indian Soc Periodontol* 2008;12(1):26-27. DOI: 10.4103/0972-124X.44095.
7. Franco R, Miranda M, Di Renzo L, et al. Glanzmann's thrombasthenia: the role of tranexamic acid in oral surgery. *Case Rep Dent* 2018;2018:9370212. DOI: 10.1155/2018/9370212.
8. Nurden AT. Glanzmann thrombasthenia. *Orphanet J Rare Dis* 2006;1(1):10. DOI: 10.1186/1750-1172-1-10.
9. George JN, Caen JP, Nurden AT. Glanzmann's thrombasthenia: the spectrum of clinical disease. *Blood* 1990;75(7):1383-1395. DOI: 10.1182/blood.V75.7.1383.1383.
10. Bellucci S, Devergie A, Gluckman E, et al. Complete correction of Glanzmann's thrombasthenia by allogeneic bone-marrow transplantation. *Br J Haematol* 1985;59(4):635-641. DOI: 10.1111/j.1365-2141.1985.tb07358.x.

11. Ishaqi MK, El-Hayek M, Gassas A, et al. Allogeneic stem cell transplantation for Glanzmann thrombasthenia. *Pediatr Blood Cancer* 2009;52(5):682–683. DOI: 10.1002/pbc.21888.
12. Varkey I, Rai K, Hegde AM, et al. Clinical management of Glanzmann's thrombasthenia: a case report. *J Dent (Tehran)* 2014;11(2):242–247.
13. Ogston D. Current status of antifibrinolytic drugs. *Blood Rev* 1989;3(1):1–4. DOI: 10.1016/0268-960x(89)90019-2.
14. Lethagen S, Nilsson IM. DDAVP-induced enhancement of platelet retention: its dependence on platelet-von Willebrand factor and the platelet receptor GP IIb/IIIa. *Eur J Haematol* 1992;49(1):7–13. DOI: 10.1111/j.1600-0609.1992.tb00906.x.
15. Okamoto S, Hijikata-Okunomiya A, Wanaka K, et al. Enzyme-controlling medicines: introduction. *Semin Thromb Hemost* 1997;23(6):493–501. DOI: 10.1055/s-2007-996127.
16. Mannucci PM, Levi M. Prevention and treatment of major blood loss. *N Engl J Med* 2007;356(22):2301–2311. DOI: 10.1056/NEJMra067742.
17. Nuvvula S, Gaddam KR, Kamatham R. Efficacy of tranexamic acid mouthwash as an alternative for factor replacement in gingival bleeding during dental scaling in cases of hemophilia: a randomized clinical trial. *Contemp Clin Dent* 2014;5(1):49–53. DOI: 10.4103/0976-237X.128663.
18. Coetzee MJ. The use of topical crushed tranexamic acid tablets to control bleeding after dental surgery and from skin ulcers in haemophilia. *Haemophilia* 2007;13(4):443–444. DOI: 10.1111/j.1365-2516.2007.01479.x.
19. Perkin RF, White GC, Webster WP. Glanzmann's thrombasthenia. Report of two oral surgical cases using a new microfibrillar collagen preparation and EACA for hemostasis. *Oral Surg Oral Med Oral Pathol* 1979;47(1):36–39. DOI: 10.1016/0030-4220(79)90098-7.
20. Wood N. Management of extractions in a case of Glanzmann's disease. *Br J Oral Surg* 1973;11(2):152–154. DOI: 10.1016/0007-117x(73)90034-6.
21. Mehta DN, Bhatia R. Dental considerations in the management of Glanzmann's thrombasthenia. *Int J Clin Pediatr Dent* 2010;3(1):51–56. DOI: 10.5005/jp-journals-10005-1054.
22. Sugimura M, Yoshioka A, Morishita M, et al. Tooth extraction in a patient with Glanzmann's thrombasthenia. *Int J Oral Surg* 1975;4(3):130–135. DOI: 10.1016/s0300-9785(75)80005-6.
23. Devan K, Peedikayil FC, Dhanesh N. Dental management of Glanzmann's thrombasthenia patient: a case report. *Int J Med Health Res* 2018;4(9):131–133.
24. Murphy MF, Waters AH. Immunological aspects of platelet transfusions. *Br J Haematol* 1985;60(3):409–414. DOI: 10.1111/j.1365-2141.1985.tb07437.x.
25. Levy-Toledano S, Tobelem G, Legrand C, et al. Acquired IgG antibody occurring in a thrombasthenic patient: its effect on human platelet function. *Blood* 1978;51(6):1065–1071. DOI: 10.1182/blood.V51.6.1065.1065.
26. Newman PJ. Platelet GPIIb-IIIa: molecular variations and alloantigens. *Thromb Haemost* 1991;66(1):111–118. DOI: 10.1055/s-0038-1646378.
27. Jennings LK, Wang WC, Jackson CW, et al. Hemostasis in Glanzmann's thrombasthenia (GT): GT platelets interfere with the aggregation of normal platelets. *Am J Pediatr Hematol Oncol* 1991;13(1):84–90. DOI: 10.1097/00043426-199121000-00018.
28. Yamaguchi K, Kawakatsu T, Kido H, et al. Platelet transfusion for patients with Glanzmann's thromboasthenia. *Vox Sang* 1992;63(4):290. DOI: 10.1111/j.1423-0410.1992.tb01241.x.
29. Ghosh A, Kumar S, Chacko R, et al. Total extraction as a treatment for anaemia in a patient of Glanzmann's thrombasthenia with chronic gingival bleed: case report. *J Clin Diagn Res* 2016;10(1):ZD11–ZD12. DOI: 10.7860/JCDR/2016/16383.7123.
30. Pabinger I, Fries D, Schöch H, et al. Tranexamic acid for treatment and prophylaxis of bleeding and hyperfibrinolysis. *Wien Klin Wochenschr* 2017;129(9-10):303–316. DOI: 10.1007/s00508-017-1194-y.