


CASE REPORT

Open Access



# Pediatric lumbar disc herniation: a report of two cases and review of the literature

Yi Wang<sup>1\*†</sup> , Yan Xu<sup>2†</sup>, Guogang Tian<sup>1</sup> and Guogang Dai<sup>1</sup>

## Abstract

**Background:** Lumbar disc herniation (LDH) is not a common condition in children. Most reports on pediatric LDH concern the outcomes of surgeries performed in children in whom nonsurgical treatment failed while the outcome of nonsurgical treatment of LDH in children was rarely reported.

**Cases presentation:** Case 1: a 10-year-old girl presented with back pain and sciatica in her left leg for over 3 months. The physical examination revealed exacerbation of back pain by waist extension or flexion, and a positive Lasegue's sign was revealed in her left leg. Magnetic resonance imaging (MRI) revealed lumbar disc herniation at the L5/S1 level. She was diagnosed with LDH. After receiving nonsurgical treatment of traditional Chinese medicine (TCM) for 30 days, the girl had mild low back pain and sciatica and the symptoms had resolved completely at the 3-month follow-up. There was no recurrence within the following 2 years. MRI performed 30 months later revealed that the herniated disc did not shrink significantly. However, she was totally asymptomatic at the follow-up performed 30 months later. Case 2: a 13-year-old boy presented with sciatica in his left leg for over 3 months. The physical examination revealed that Lasegue's sign was positive in the left leg, the level of muscle strength in the left ankle plantar flexors was grade 4. MRI revealed a lumbar disc herniation at the L5/S1 level. He was diagnosed with LDH. The boy underwent 2 weeks of TCM treatment, and exhibited a favorable outcome: only mild pain was noticed in his left buttocks after walking for more than 15 min. He was asymptomatic at the 3-month follow-up and there was no recurrence within the next 3 years. MRI scan performed at 40 months later showed no significant resorption of the herniated disc. However, he was totally asymptomatic at the follow-up performed 40 months later.

**Conclusions:** For the nonsurgical treatment of pediatric LDH, resorption of herniated discs is not necessary for favorable long-term outcomes, and children with symptomatic LDH may become asymptomatic without resorption.

**Keywords:** Pediatric, Lumbar disc herniation, Nonsurgical treatment

## Background

Lumbar disc herniation (LDH) is not a common condition in children. The overall incidence of LDH in children is unknown, and the diagnosis of LDH is usually delayed

in children compared with adults [1, 2]. Since the first case of pediatric LDH was reported in 1945 [3], many surgeons have reported pediatric patients undergoing surgery for LDH [4–11], and pediatric patients have been reported to constitute 0.4–15.4% of surgically treated patients with LDH [2]. Most reports on pediatric LDH concern the outcomes of surgeries performed in children in whom nonsurgical treatment failed while the outcome of nonsurgical treatment of LDH in children was rarely reported [4–11]. We reported a follow-up study of two pediatric LDH cases treated with nonsurgical treatment

<sup>†</sup>Yi Wang and Yan Xu have contributed equally to this work and share first authorship

\*Correspondence: [yiwang1984@hotmail.com](mailto:yiwang1984@hotmail.com)

<sup>1</sup> Cervicodynia/Omalgia/Lumbago/Sciatica Department 2, Sichuan Province Orthopedic Hospital, 132 West First Section First Ring Road, Chengdu 610041, Sichuan, China

Full list of author information is available at the end of the article



of traditional Chinese medicine (TCM) to present the long-term outcomes of LDH in children.

## Cases presentation

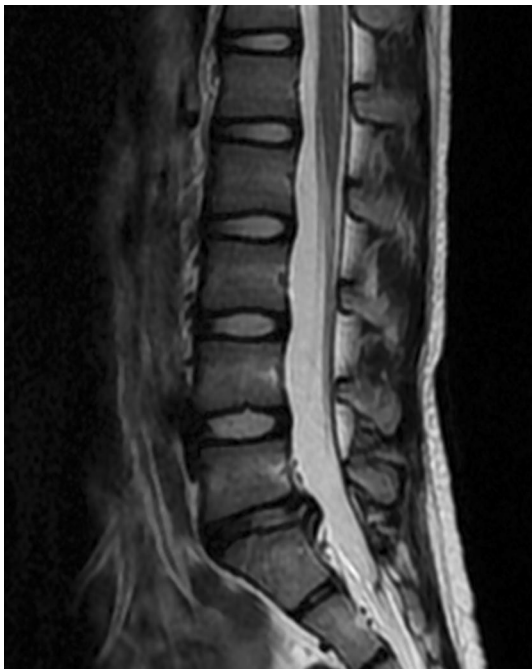### Case 1

A 10-year-old girl presented with back pain and sciatica in her left leg for over 3 months. The girl did not experience trauma, and she began to feel pain when she was sitting on a bench doing homework. She was hospitalized for persistent pain and limp caused by pain when walking. The physical examination revealed exacerbation of back pain by waist extension or flexion, and a positive Lasegue's sign was revealed in her left leg. There was no sign of hypoesthesia or decreases in muscle strength or bowel or bladder dysfunction. Magnetic resonance imaging (MRI) revealed Schmorl's node at L4 and S1, platyspondyly of the lumbar vertebrae, and a lumbar disc herniation at the L5/S1 level (Fig. 1). The girl was diagnosed with LDH at the L5/S1 level. Nonsurgical treatment of TCM was administered for 30 days, which included bed rest, electroacupuncture, Chinese Tuina, Chinese herbal fumigation, and moxibustion at the lumbosacral area. She had mild low back pain and sciatica when she was discharged from the hospital, and the symptoms had resolved completely at the 3-month follow-up. There was no recurrence within the following

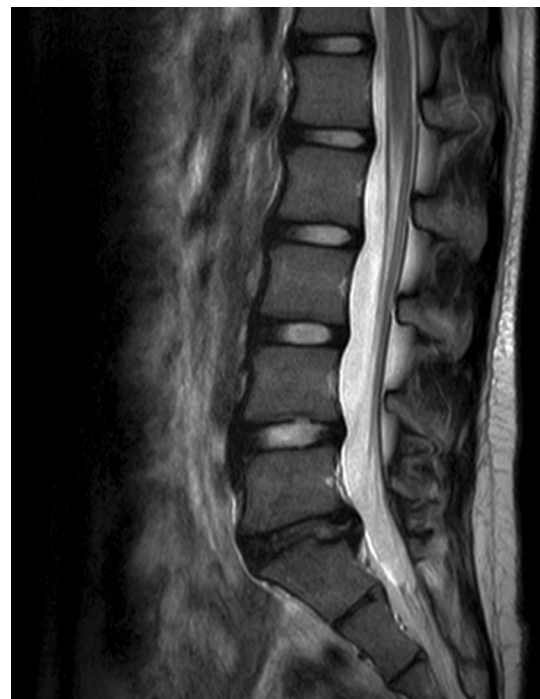2 years. MRI performed 30 months later revealed that the Schmorl's node and the platyspondyly of the lumbar vertebrae did not change significantly, and that the herniated disc did not shrink significantly (Fig. 2). However, she was totally asymptomatic at the follow-up performed 30 months later.

### Case 2

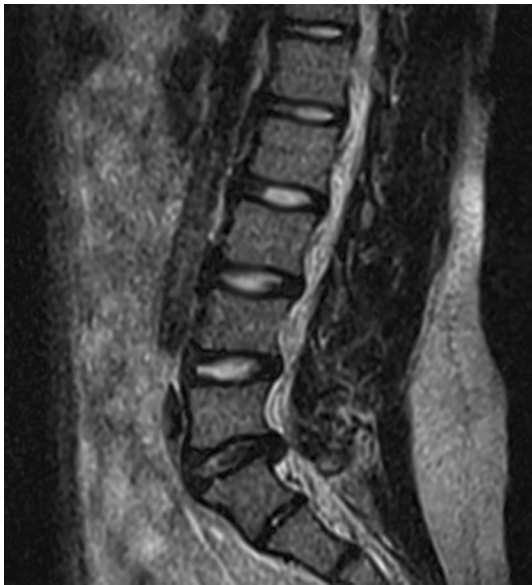A 13-year-old boy was hospitalized for sciatica in his left leg for over 3 months. He felt pain in the distribution of the sciatic nerve when sitting, standing, and walking. The physical examination revealed that Lasegue's sign was positive in the left leg, the level of muscle strength in the left ankle plantar flexors was grade 4, and the levels of lower limb sensation and bowel and bladder function were normal. MRI revealed platyspondyly of the lumbar vertebrae and a lumbar disc herniation at the L5/S1 level (Fig. 3). The boy was diagnosed with LDH at the L5/S1 level. The patient underwent 2 weeks of nonsurgical treatment of TCM, as case 1 did, and exhibited a favorable outcome: only mild pain was noticed in his left buttocks after walking for more than 15 min. He was asymptomatic at the 3-month follow-up and did not experience back pain or sciatica within the next 3 years; the MRI scan performed at 40 months



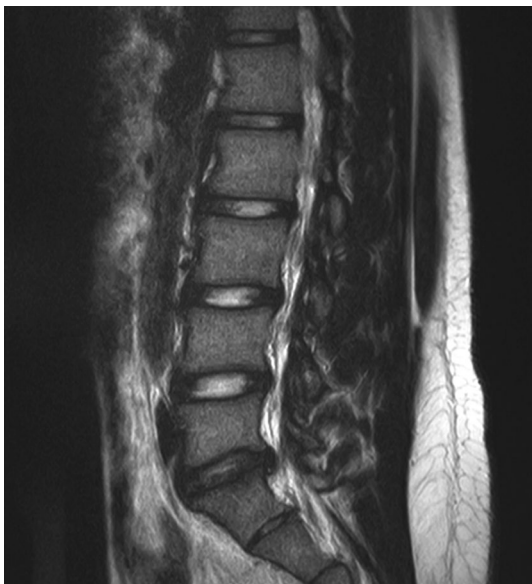**Fig. 1** MRI of the lumbar spine obtained at the 10-year-old girl's initial visit revealed Schmorl's node at L4 and S1, platyspondyly of the lumbar vertebrae, and a lumbar disc herniation at the L5/S1 level



**Fig. 2** MRI obtained at the girl's 30-month follow-up showed no significant changes in Schmorl's node at L4 and S1, platyspondyly of the lumbar vertebrae, and no significant resorption of the herniated L5/S1 lumbar disc



**Fig. 3** MRI of the lumbar spine obtained at the 13-year-old boy's initial visit revealed platyspondyly of the lumbar vertebrae, and a lumbar disk herniation at the L5/S1 level



**Fig. 4** MRI obtained at the boy's 40-month follow-up showed no significant changes of platyspondyly of the lumbar vertebrae and no significant resorption of the herniated L5/S1 lumbar disc

after the first MRI scan showed no significant changes of platyspondyly of the lumbar vertebrae and no significant resorption of the herniated disc (Fig. 4).

## Discussion and conclusions

LDH is based on disc degeneration, which occurs with ageing [12]. Early histopathologic degeneration of the lumbar disc initiates at the age of 11 [13], and the water content of the disc begins to decrease in early childhood [14]. Other risk factors for LDH include trauma, physical loading, obesity, socioeconomic status, and genetic and behavioral influences [14–17]. The main causes of LDH in children are traumatic and sports injuries [1]. The youngest child reported to have LDH was 13 months old [18], and there are reports on cauda equina syndrome symptoms caused by LDH in children [19, 20].

The prevalence of Schmorl's node in children and adolescents is 2.68%, whether symptomatic or asymptomatic [21]. In all age groups of patients with suspicion of lumbar lesions, the incidence of Schmorl's node is the highest in teenagers, at 57%, and most of these teenagers complain about back pain [22]. In the present study, the child presented with Schmorl's node and platyspondyly of the lumbar vertebrae, which is mostly related to skeletal dysplasia. In skeletal dysplasia, the vertebral body is prone to intraosseous fractures, resulting in Schmorl's node formation and causing pain. As the intraosseous fractures heal, Schmorl's nodes become asymptomatic [23]. Although Schmorl's node was present in case 1, there were no inflammatory changes in the vertebral body marrow on MRI, and we believe it is not a cause of pain, analogous to old fractures.

In skeletal dysplasia, rupture of the annulus fibrosus is also more likely to present in children, resulting in disc herniation and leading to back pain or sciatica. Pediatric LDH is managed similarly to adult LDH, which includes nonsurgical and surgical treatment [1]. For adult patients with LDH, surgery relieves pain quickly within a short period, with an incidence of complications of up to 12.5% [24], while nonsurgical treatment is usually performed for more than 6 months [25, 26]. Randomized clinical trials have suggested that surgery relieves pain faster than nonsurgical treatment at 6 months [25–27]; subsequently, the results of the two treatments tend to be similar between 6 and 12 months after the start of treatment [25, 27]. A one year after treatment, resorption of LDH was observed in 91% of nonsurgically treated patients, while LDH was unchanged or enlarged in 5% of patients who underwent surgery; not all patients with resorption achieved favorable outcomes, while not all patients with unchanged or enlarged LDH had unfavorable outcomes [28]. From 1–2 years, there was no difference between the outcomes of the patients treated by the two methods [25, 27, 28]. However, a limitation of these trials was nonadherence to the treatment assignment, as patients sometimes received both treatments or switched groups, and the conclusions of these trials need to be interpreted

with caution. One randomized clinical trial suggested that both surgically and nonsurgically treated patients achieved substantial relief within 2 years, with no statistically significant difference between the patient groups [29]. In a cohort study, surgery was reported to improve LDH better than nonsurgical treatment within 2–4 years according to combined as-treated analysis [30, 31]. There was no consensus on whether surgical treatment or nonsurgical treatment for LDH is more efficacious in adults, and there is no evidence that these conclusions apply to children.

Surgery is not a first-line treatment for children with LDH; it is performed only when progressive neurological deficits and bowel or bladder dysfunction are present or nonsurgical treatment has failed [32]. Nonsurgical treatment failed in most pediatric patients reported in the literature, and thus, surgery was performed for these children [4–11]. In the long term, one mechanism of relief after nonsurgical treatment is resorption of the herniated disc, which reduces the pressure on the nerve root, the source of inflammation and the immune response. Resorption is a common phenomenon in the natural history of LDH [33, 34], and most herniated discs shrink over time [35]. Our previous study revealed that the overall incidence of resorption of symptomatic LDH after nonsurgical treatment was 63% [36]. However, pediatric LDH is less likely to resorb than is adult LDH [37], which may explain why children were less responsive to nonsurgical treatment than adults.

Few studies have reported nonsurgical treatment for children with LDH to be successful. The commonly used nonsurgical treatments for pediatric LDH are similar to those for adults, including bed rest, rest, physical therapy, NSAIDs, and analgesic agents [32]. Many studies have confirmed that TCM is effective in treating LDH in adults [38–41]. A randomized controlled clinical trial suggested that TCM has good clinical efficacy for LDH by improving local inflammation, circulation, and edema of the nerve root [41]. Yu et al. suggested that nonsurgical treatment of TCM was effective for ruptured LDH and can promote herniated disc resorption [40]. Acupuncture and Chinese Tuina relieve pain and improve lumbar dysfunction in LDH [38, 42]. Animal experiments have shown that electroacupuncture reduces the release of inflammatory cytokines, including TNF- $\alpha$ , IL-1 $\beta$ , IL-10 and TGF- $\beta$  [39]. Our previous study suggested that integrated TCM relieved pain due to LDH by downregulating inflammation-related factors, such as TLR5, IL1RN and IL-27 [43]. However, the underlying mechanism by which TCM decreases the symptoms of LDH remains largely unknown. TCM has seldom been reported for the treatment of pediatric LDH. In the present study, two children with LDH achieved favorable outcomes after

nonsurgical treatment of TCM treatment; there was no recurrence or aggravation within a period of more than 2 years, and both patients were asymptomatic at the last follow-up, although no resorption of the herniated discs was observed on MRI (in the present report “significant resorption” refers to a reduction in size of more than 50% as defined by Takada [44]).

In conclusion, for the nonsurgical treatment of pediatric LDH, resorption of herniated discs is not necessary for favorable long-term outcomes, and children with symptomatic LDH may become asymptomatic without resorption after nonsurgical treatment.

#### Abbreviations

LDH: Lumbar disc herniation; TCM: Traditional Chinese medicine; MRI: Magnetic resonance imaging.

#### Acknowledgements

Not applicable.

#### Author contributions

YW and YX conceived of the case report, contributed the facts from the perspective of treatment and follow-up. YW, YX, GT and GD gleaned the facts and drafted the manuscript. YX, GT and GD revised it critically and contributed substantially to the discussion. All authors read and approved the final manuscript.

#### Funding

No external funding was solicited or used.

#### Availability of data and materials

Not applicable.

#### Declarations

#### Ethics approval and consent to participate

Not applicable.

#### Consent for publication

Written informed consent was obtained from patients and their guardians for publication of this case report and any accompanying images.

#### Competing interests

The authors declare that they have no conflicts of interest.

#### Author details

<sup>1</sup>Cervicodynia/Omalgia/Lumbago/Sciatica Department 2, Sichuan Province Orthopedic Hospital, 132 West First Section First Ring Road, Chengdu 610041, Sichuan, China. <sup>2</sup>Experiment Teaching Center for Preclinical Medicine, Chengdu Medical College, Xindu District, 783 Xindu Avenue, Chengdu, Sichuan, China.

Received: 13 August 2021 Accepted: 29 April 2022

Published online: 03 June 2022

#### References

- Haidar R, Ghanem I, Saad S, Uthman I. Lumbar disc herniation in young children. *Acta Paediatr*. 2010;99(1):19–23.
- Lavelle WF, Bianco A, Mason R, Betz RR, Albanese SA. Pediatric disk herniation. *J Am Acad Orthop Surg*. 2011;19(11):649–56.
- Wahren H. Herniated nucleus pulposus in a child of twelve years. *Acta Orthop Scand*. 1945;16(1):40–2.

4. Bradford DS, Garcia A. Herniations of the lumbar intervertebral disk in children and adolescents. a review of 30 surgically treated cases. *JAMA*. 1969;210(11):2045–51.
5. Webb JH, Svien HJ, Kennedy RL. Protruded lumbar intervertebral disks in children. *J Am Med Assoc*. 1954;154(14):1153–4.
6. Parisini P, Di Silvestre M, Greggi T, Miglietta A, Paderni S. Lumbar disc excision in children and adolescents. *Spine*. 2001;26(18):1997–2000.
7. Stromqvist F, Stromqvist B, Jonsson B, Gerdhem P, Karlsson MK. Lumbar disc herniation surgery in children: outcome and gender differences. *Eur Spine J*. 2016;25(2):657–63.
8. Kurihara A, Kataoka O. Lumbar disc herniation in children and adolescents. a review of 70 operated cases and their minimum 5-year follow-up studies. *Spine*. 1980;5(5):443–51.
9. Ferrante L, Mastronardi L, Lunardi P, Puzilli F, Fortuna A. Lumbar disc herniation in teenagers. *Eur Spine J*. 1992;1(1):25–8.
10. McAvoy M, McCreagh HJ, Chavakula V, Choi H, Bi WL, Mekary RA, et al. Long-term outcomes of lumbar microdiscectomy in the pediatric population: a large single-institution case series. *J Neurosurg Pediatr*. 2019. <https://doi.org/10.3171/2019.6.PEDS18716>.
11. Zheng C, Wu F, Cai L. Transforaminal percutaneous endoscopic discectomy in the treatment of far-lateral lumbar disc herniations in children. *Int Orthop*. 2016;40(6):1099–102.
12. Martin MD, Boxell CM, Malone DG. Pathophysiology of lumbar disc degeneration: a review of the literature. *Neurosurg Focus*. 2002;13(2):E1.
13. Boos N, Weissbach S, Rohrbach H, Weiler C, Spratt KF, Nerlich AG. Classification of age-related changes in lumbar intervertebral discs: 2002 Volvo award in basic science. *Spine*. 2002;27(23):2631–44.
14. Battie MC, Videman T. Lumbar disc degeneration: epidemiology and genetics. *J Bone Joint Surg Am*. 2006;88(Suppl 2):3–9.
15. Katz JN. Lumbar disc disorders and low-back pain: socioeconomic factors and consequences. *J Bone Joint Surg Am*. 2006;88(Suppl 2):21–4.
16. Shiri R, Lallukka T, Karppinen J, Viikari-Juntura E. Obesity as a risk factor for sciatica: a meta-analysis. *Am J Epidemiol*. 2014;179(8):929–37.
17. Huang W, Qian Y, Zheng K, Yu L, Yu X. Is smoking a risk factor for lumbar disc herniation? *Eur Spine J*. 2016;25(1):168–76.
18. Benifla M, Melamed I, Barrely R, Aloushin A, Shelef I. Unilateral partial hemilaminectomy for disc removal in a 1-year-old child. *J Neurosurg Pediatr*. 2008;2(2):133–5.
19. Klug N, Samii M. Herniation of an intervertebral disc with cauda compression syndrome in childhood. *J Neurol*. 1979;221(3):209–11.
20. Kotil K, Akcetin M, Bilge T. Cauda equina compression syndrome in a child due to lumbar disc herniation. *Childs Nerv Syst*. 2004;20(6):443–4.
21. Wan ZY, Zhang J, Shan H, Liu TF, Song F, Samartzis D, et al. Epidemiology of lumbar degenerative phenotypes of children and adolescents: a large-scale imaging study. *Global Spine J*. 2021. <https://doi.org/10.1177/21925682211000707>.
22. Hamanishi C, Kawabata T, Yosii T, Tanaka S. Schmorl's nodes on magnetic resonance imaging their incidence and clinical relevance. *Spine*. 1994;19(4):450–3.
23. Takahashi K, Miyazaki T, Ohnari H, Takino T, Tomita K. Schmorl's nodes and low-back pain. Analysis of magnetic resonance imaging findings in symptomatic and asymptomatic individuals. *Eur Spine J*. 1995;4(1):56–9.
24. Shriver MF, Xie JJ, Tye EY, Rosenbaum BP, Kshetry VR, Benzel EC, et al. Lumbar microdiscectomy complication rates: a systematic review and meta-analysis. *Neurosurg Focus*. 2015;39(4):E6.
25. Peul WC, van den Hout WB, Brand R, Thomeer RT, Koes BW. Leiden-the Hague spine intervention. Prognostic Study G Prolonged conservative care versus early surgery in patients with sciatica caused by lumbar disc herniation: two year results of a randomised controlled trial. *BMJ*. 2008;336(7657):1355–8.
26. Bailey CS, Rasoulinejad P, Taylor D, Sequeira K, Miller T, Watson J, et al. Surgery versus conservative care for persistent sciatica lasting 4 to 12 months. *N Engl J Med*. 2020;382(12):1093–102.
27. Peul WC, van Houwelingen HC, van den Hout WB, Brand R, Eekhof JA, Tans JT, et al. Surgery versus prolonged conservative treatment for sciatica. *N Engl J Med*. 2007;356(22):2245–56.
28. el Barzouhi A, Vleggeert-Lankamp CL, a LycklamaNijeholt GJ, Van der Kallen BF, van den Hout WB, Jacobs WC, et al. Magnetic resonance imaging in follow-up assessment of sciatica. *N Engl J Med*. 2013;368(11):999–1007.
29. Weinstein JN, Tosteson TD, Lurie JD, Tosteson AN, Hanscom B, Skinner JS, et al. Surgical vs nonoperative treatment for lumbar disk herniation: the spine patient outcomes research trial (SPORT): a randomized trial. *JAMA*. 2006;296(20):2441–50.
30. Weinstein JN, Lurie JD, Tosteson TD, Skinner JS, Hanscom B, Tosteson AN, et al. Surgical vs nonoperative treatment for lumbar disk herniation: the spine patient outcomes research trial (SPORT) observational cohort. *JAMA*. 2006;296(20):2451–9.
31. Weinstein JN, Lurie JD, Tosteson TD, Tosteson AN, Blood EA, Abdu WA, et al. Surgical versus nonoperative treatment for lumbar disc herniation: four-year results for the spine patient outcomes research trial (SPORT). *Spine*. 2008;33(25):2789–800.
32. Slotkin JR, Mislow JM, Day AL, Proctor MR. Pediatric disk disease. *Neurosurg Clin N Am*. 2007;18(4):659–67.
33. Wang Y, Liao SC, Dai GG, Jiang L. Resorption of upwardly displaced lumbar disk herniation after nonsurgical treatment: a case report. *World J Clin Cases*. 2020;8(19):4609–14.
34. Hong J, Ball PA. IMAGES IN CLINICAL MEDICINE. Resolution of lumbar disk herniation without surgery. *N Engl J Med*. 2016;374(16):1564.
35. Kreiner DS, Hwang SW, Easa JE, Resnick DK, Baisden JL, Bess S, et al. An evidence-based clinical guideline for the diagnosis and treatment of lumbar disc herniation with radiculopathy. *Spine J*. 2014;14(1):180–91.
36. Wang Y, Dai G, Jiang L, Liao S. The incidence of regression after the non-surgical treatment of symptomatic lumbar disc herniation: a systematic review and meta-analysis. *BMC Musculoskelet Disord*. 2020;21(1):530.
37. Dang L, Liu Z. A review of current treatment for lumbar disc herniation in children and adolescents. *Eur Spine J*. 2010;19(2):205–14.
38. Xu M, Yan S, Yin X, Li X, Gao S, Han R, et al. Acupuncture for chronic low back pain in long-term follow-up: a meta-analysis of 13 randomized controlled trials. *Am J Chin Med*. 2013;41(1):1–19.
39. Yu JN, Guo CQ, Hu B, Liu NG, Sun HM, Xu H, et al. Effects of acupuncture knife on inflammatory factors and pain in third lumbar vertebrae transverse process syndrome model rats. *Evid Based Complement Alternat Med*. 2014;2014: 892406.
40. Yu PF, Jiang H, Liu JT, Li XC, Qian X, Han S, et al. Traditional Chinese medicine treatment for ruptured lumbar disc herniation: clinical observations in 102 cases. *Orthop Surg*. 2014;6(3):229–35.
41. Yuan WA, Huang SR, Guo K, Sun WQ, Xi XB, Zhang MC, et al. Integrative TCM conservative therapy for low back pain due to lumbar disc herniation: a randomized controlled clinical trial. *Evid Based Complement Alternat Med*. 2013;2013: 309831.
42. Wu B, Yang L, Fu C, Jian G, Zhuo Y, Yao M, et al. Efficacy and safety of acupuncture in treating acute low back pain: a systematic review and bayesian network meta-analysis. *Ann Palliat Med*. 2021;10(6):6156–67.
43. Wang Y, Dai G, Xu Y, Jiang L, Fu Z, Xia J, et al. Integrated traditional Chinese medicine alleviates sciatica while regulating gene expression in peripheral blood. *J Orthop Surg Res*. 2021;16(1):130.
44. Takada E, Takahashi M, Shimada K. Natural history of lumbar disc hernia with radicular leg pain: spontaneous MRI changes of the herniated mass and correlation with clinical outcome. *J Orthop Surg*. 2001;9(1):1–7.

## Publisher's Note

Springer Nature remains neutral with regard to jurisdictional claims in published maps and institutional affiliations.