

Long-term outcome of a cohort of Italian patients affected with alpha-Mannosidosis

Anna Bertolini^a, Miriam Rigoldi^b, Annalia Cianflone^a, Raffaella Mariani^a, Alberto Piperno^a, Francesco Canonico^c, Graziella Cefalo^d, Francesca Carubbi^e, Alessandro Simonati^f, Maria Letizia Urban^g, Tommaso Beccari^h and Rossella Parini^a

Alpha-mannosidosis (MIM #248500) is an ultra-rare autosomal recessive lysosomal storage disease with multi-system involvement and a wide phenotypic spectrum. Information on long-term outcomes remains poor. We present the long-term outcomes (median, 19 years) of nine patients with alpha-mannosidosis, three females and six males, followed at a single center. The findings of the nine patients were collected from medical records and reported as mean \pm SD or median, and range. The age of onset of the first symptoms ranged from 0–1 to 10 years. The diagnostic delay ranged from 2 to 22 years (median= 11 years). Coarse face, hearing, heart valves, joints, gait, language, dysarthria, psychiatric symptoms, I.Q., MRI, walking disabilities, orthopedic disturbances and surgeries showed a slow worsening over the decades. Our patients showed a slowly worsening progressive outcome over the decades. Psychiatric symptoms were present in 100% of our population and improved with the appropriate pharmacological intervention. This aspect requires attention when following up on these patients. Our description of the long-term evolution

of alpha-mannosidosis patients may provide basic knowledge for understanding the effects of specific treatments. *Clin Dysmorphol* 33: 1–8 Copyright © 2023 The Author(s). Published by Wolters Kluwer Health, Inc.

Clinical Dysmorphology 2024, 33:1–8

Keywords: alpha-mannosidosis, lysosomal storage disorders, *MAN2B1* (MIM*609458), mannosidase, Mannosidosis, MIM#248500

^aRare Diseases Unit, Department of Medicine and Surgery, San Gerardo Hospital IRCCS, University of Milano-Bicocca, Monza, Italy; ^bIstituto di Ricerche Farmacologiche Mario Negri IRCCS, Clinical Research Center for Rare Diseases Aldo e Cele Daccò, Bergamo, Italy; ^cDepartment of Radiology, San Gerardo Hospital IRCCS, University of Milano-Bicocca, Monza, Italy; ^dClinical Department of Pediatrics, San Paolo Hospital, ASST Santi Paolo e Carlo, University of Milan, Milan, Italy; ^eDepartment of Biomedical, Metabolic and Neural Sciences, University of Modena and Reggio Emilia, NOCSAE Hospital, AOU Modena, Modena, Italy; ^fDepartment of Surgery, Dentistry, Paediatrics and Gynaecology, University of Verona School of Medicine, Verona, Italy; ^gDepartment of Experimental and Clinical Medicine, University of Florence, Firenze, Italy and ^hDepartment of Pharmaceutical Sciences, University of Perugia, Perugia, Italy

Correspondence to Dr. Rossella Parini, MD, Rare Diseases Unit, Department of Medicine and Surgery, University of Milano-Bicocca, Monza, Italy
Tel: +39 3355603805; e-mail: parini.hsg@gmail.com

Received 21 April 2023 Accepted 28 July 2023.

Introduction

Alpha-mannosidosis (AM; MIM #248500) is an ultra-rare, autosomal recessive, lysosomal storage disorder caused by a deficiency in the lysosomal hydrolase alpha-mannosidase (LAMAN - EC 3.2.1.24). Deficiency of this enzyme leads to the accumulation of mannose-rich, partially degraded oligosaccharides in neural and visceral tissues. Alpha-mannosidase is encoded by the gene *MAN2B1* (MIM*609458), which is located close to the centromere of chromosome 19 (19p13.2).

The prevalence of AM is estimated to be between 1 in 250 000 and 1 in 1 000 000 live births. Affected patients typically show hearing impairment, progressive neuropsychological decline, ataxia, dysarthria, dyspraxia,

coarse facial features and skeletal abnormalities such as spine and vertebral deformities, scoliosis, pes planus, hip dysplasia and knock knees (genu valgus) which often lead to arthropathy, splenomegaly, frequent infections and psychiatric symptoms. (Malm *et al.*, 2000, 2005; Malm and Nilssen, 2008).

Although three subtypes of mannosidosis have been previously identified and classified based on severity (Malm and Nilssen, 2008), this condition is currently preferably described as a continuum of clinical phenotypes: from the most severe, with infantile onset, rapid progression, and death between 3 and 12 years of age, to the mildest one, with few symptoms becoming evident in adolescence, and long survival into adulthood (Guffon *et al.*, 2019).

The diagnosis of AM is based on clinical evaluation, determination of enzyme activity in various nucleated cell types and molecular analysis of *MAN2B1* gene. Moreover, while the detection of mannose-rich oligosaccharides in urine is suggestive, it is not diagnostic.

This is an open-access article distributed under the terms of the Creative Commons Attribution-Non Commercial-No Derivatives License 4.0 (CCBY-NC-ND), where it is permissible to download and share the work provided it is properly cited. The work cannot be changed in any way or used commercially without permission from the journal.

Table 1 Demographic, biochemical and genetic data, first symptoms noted, age of diagnosis and diagnostic delay of 9 Italian patients affected with Mannosidosis

Patient	Sex/ age at latest evaluation (years)	Leukocyte enzyme activity %	Genotype <i>MAN2B1</i> gene	Birth	First noted symptoms (age in y)	Age of walking (m)	Age of speech with brief sentences (y)	Age at diagnosis (y)	Diagnostic delay (y)	Years of follow-up
1	F/38	3.2	c.157G>T/ c.2402G>A	Hypotonia	Hypotonia, psychomotor delay, hip dysplasia (0–1)	17	5	19	19	19
2 ^a	M/38	12.7	c.164G>T/ c.599A>T	normal	Flat feet (0–1), recurrent otitis (1–7)	13	3	10	9	20
3 ^a	M/32	12.0	c.164G>T/ c.599A>T	normal	Flat feet (0–1); developmental delay (3)	24	5	3	2	20
4	F/39	2.9	c.2248C>T/ c.2248C>T	normal	Club feet, hepatomegaly, hip dysplasia, RURTI (0–1)	14	3	5	4	17
5 ^b	M/51 (52 ^c)	4.5	c.293_294InsA/ c.293_294InsA	normal	cognitive delay (4)	nr	Speech delay	18	14	20
6 ^b	M/57	4.5	c.293_294InsA/ c.293_294InsA	normal	cognitive delay (10)	nr	Speech delay	21	11	20
7	M/22	–	c.2248C>T/ c.164G>T	normal	RURTI (0–1), severe hearing loss (3), ADHD (7)	18	3	19	16	3
8	M/43	2.5	c.1420-1G>A/ c.599A>T	normal	Inguinal and umbilical hernia (0–1); mild hearing loss and learning problems (7)	14	3	29	22	4
9	F/40	0	c.2248C>T/ c.2248C>T	normal	Hip dysplasia (0–1), severe hearing loss (3)	36	4	13	10	19
Range (median); Mean		0–12.7 (3.8); 5.2			0.1–10 (0.5); 1.9	^d 13–36 (17); 19.4	^d 3–5 (3); 3.7	3–29 (18); 15.3	2–22 (11.0); 11.8	3–20 (19.0); 9.0

F, female; RURTI, recurrent upper respiratory tract infections; M, male; nr, not reported.

^aCouple of siblings.

^bCouple of siblings.

^cDied at 52 years for colon cancer, same Italian patient reported by Hennermann *et al.* (2022).

^dOnly 7 patients.

Since its first description in 1967 (Öckerman, 1967), some isolated clinical cases have been reported in the Seventies, mostly cited by Desnick *et al.* (1976). Chester *et al.* (1982) described 67 patients in a meta-analysis of 35 different reports. More recently, retrospective studies, based on the literature (Zielonka *et al.*, 2019), questionnaires dispensed by physicians (Malm *et al.*, 2014; Adam *et al.*, 2019) or multicenter longitudinal studies (24 months) (Beck *et al.*, 2013) have been published. However, information on the long-term outcomes of individuals with mannosidosis is still poor (Beck *et al.*, 2013). Recently, Lipinski *et al.* (2021) reported on the long-term clinical outcomes of 12 patients with mannosidosis followed up by a single center in Poland.

Here we describe the longitudinal outcomes of nine patients followed up at our center for many years. Detailed information about the natural history of individuals affected by AM is useful to understand the role of available [enzyme replacement therapy (ERT) or hematopoietic stem cell transplantation (HSCT)] or future treatments (e.g. gene therapy), which ultimately impact the course of disease.

Patients and methods

This retrospective study involved all the newly diagnosed patients or patients followed up for alpha-mannosidosis, since 2000 at the Center for Rare Metabolic Diseases of San Gerardo Hospital, Monza. Inclusion criteria included

confirmation of clinical diagnosis through leukocyte assay of enzyme activity and/or molecular analysis of the *MAN2B1* gene. Enzyme assay and molecular analysis of the *MAN2B1* gene (NM-000528.3) were performed as described in Sbaragli *et al.* (2005) (Table 1). These mutations were submitted to the Human Gene Mutation DataBase. Some of the patients received clinical assistance at centers closer to their homes, mainly during the pandemics of SARS-CoV-2.

All the patients or their caregivers gave an informed consent for the description of their clinical history in a scientific paper. The clinical records were thoroughly reviewed from September 2020 to August 2021. Patient data were obtained by consulting medical records and collected in a dedicated database.

Specifically, the following indicators were considered for each patient:

- (1) Anagraphic data: year of birth, present age and sex.
- (2) Historical data: age at diagnosis, age at first symptoms, detailed description of first symptoms and diagnostic delay.
- (3) Growth.
- (4) Progression of the typical features of the disease: intellectual disability, ataxic gait, dysarthria, dysphagia, dyspraxia, hearing impairment, sight impairment, heart valve disease, coarse facial features, orthopedic problems, frequent infections,

Table 2 Signs and symptoms of disease: numbers represent the age (in years) when sign or symptom was first noticed and at progression

Patient number	1	2 ^a	3 ^a	4	5 ^b	6 ^b	7	8	9	Range, (median); mean
Coarse face	19	6	1.8	5	18	39	19	30	14	1.8–38, (14); 15.3
Severe bilateral hearing loss	5	19	13	4	18	25	3	15	3	3–25, (13); 11.6
Hearing aids	No at 38	19	13	4	23	25	3	15	3	°3–25, (14); 13.1
Poor language	5	4	4	4	5	10	4	30	5	4–30, (5); 7.9
Dysarthria	33	10 34–39: progressive worsening with scanned speech	21	35	45	48	19	38	25	10–48 (33); 30.4
Dysphagia	29: occasional for liquids	Absent at 38	Absent at 32	23: mild	41: occasional	Absent at 44	Absent at 22	37	onset at 25; 36: worsening	°23–41, (29); 31
Gait and upper limbs motricity	10: balance instability; 12: ataxia, walking aids; 21: worsening ataxia with frequent falls; 33: wheelchair	7: poor fine motricity; 22: mild ataxia; 36: severe ataxia	15: clumsy gait; 28: ataxia	10: ataxia; 22: dysmetria; 26: walking aids; 27: wheelchair; 30: upper limbs apraxia; 4: cognitive delay with slow progression	43: ataxia; 51: walking aids and upper limbs apraxia	48: clumsy gait and ataxia	19: ataxia	26: ataxia; 30: walking aids; 39: wheelchair	13: walking aids; 14: ataxia; 14: wheelchair	-Ataxic gait: 10–48, (22); 24.6, ° Walking aids: 12–51, (26); 26.4, ° -°wheelchair: 14–40, (30); 28 3–10, (5.5); 4.5
Psychomotor development	3: delay	6: cognitive delay with slow progression	4: cognitive delay with slow progression	4: cognitive delay with slow progression	4: cognitive delay with slow progression	10: cognitive delay with slow progression	4: mild cognitive delay with slow progression	10: cognitive delay with slow progression	5: cognitive delay with slow progression	
WAIS-R VIQ/ PIQ	29 : 49/na	23 : 57/57 35: <45/57	17 : 63/53; 23: <45/53; 29: <45/45	23 : 59/62; 36 : 46/62	48 : 57/65	na	na	34 : 52/56; 39 : 52/52	na	
Psychiatric symptoms	29: anticipatory anxiety	24: anxiety and inversion of the sleep-wake rhythm	17: pseudo-hallucinations and intrusive thoughts. 21: aggressiveness.	33: restlessness, aggressiveness, depression	18: acute psychosis with delirium and restlessness. 45: apathy and severe aggressiveness; 50 agoraphobia	40: aggressiveness, phobias, irritability.	7: ADHD and oppositional traits	38: depression, social withdrawal; 42: abdominal, hypersomnia alternated with irritability	31: anxiety, depression; 37: severe depression	7–40, (29); 26.3
Brain MRI	9: CA and BA WMA; 19: worsened CA and BA with stable abnormal WMA	24: normal C and B morphology, WMA; 34: CH	17: normal. 28: CH main left hemisphere, and occipital lobes hypoplasia	23: CA	18: normal, mild CVH; 47: CA, BA	37: CA, diffuse WMA	na	25: CH, WMA	26: WMA	
Heart Valve disease	27: mild ASI and MI.	27: mild MI and TI	14: ASI, 21: MI 21: TI	35: Mild MI and TI	38: Mild MI and TI	44: MI	18: MI	38: MI and TI	27: mild ASI; 30: mild MI	
Sight	8 : M; 8 : As Glasses	25: mild As; 38: R	13 : M, As glasses; 16: bilateral KC; childhood RURT12: abscessed adenitis; 18: erysipelas; 18: flegmon with fasciitis; 21: furunculosis hydrosadenitis	Since childhood: M, glasses 0–1 : RURT1; 33 : recurrent vaginitis; 36: groin furunculosis; 37: genital-to-furunculosis; 38: axillary furunculosis; 39: hydrosadenitis	Mild M	41: Am, 50: R	No at 22	26: R	na	
Infections	childhood RURT1; 32: periarticular hip abscess with sepsis	childhood RURT1	childhood RURT12: abscessed adenitis; 18: erysipelas; 18: flegmon with fasciitis; 21: furunculosis hydrosadenitis	0–1 : RURT1; 33 : recurrent vaginitis; 36: groin furunculosis; 37: genital-to-furunculosis; 38: axillary furunculosis; 39: hydrosadenitis	40–52: RURT1	no	0–20: RURT1	5–20: RURT1, recurrent urinary tract infections	30–40: RURT1	

(Continued)

Table 2
(Continued)

Immune deficiency and auto-immunity	19: autoimmune thrombocytopenia and neutropenia; 25: autoimmune hypothyroidism	Childhood low IgG and IgM; 10: thrombocytopenia; 35: low IgM	27: low IgM, neutropenia and thrombocytopenia	20: IgA deficiency	42: low IgG and IgM. ANA Ab	No at 57	na	42: low IgG and IgM, thrombocytopenia, hyperferritinemia.	No autoantibodies
Orthopedic issues	0-1: hip dysplasia; 3: flat feet and genu valgum; 32: hip bone sclerosis, coxarthrosis, D12-L1 pathologic fractures	Childhood flat feet; 20: dorsolumbar scoliosis, ilium hypoplasia and coxa valga; 27 multiple vertebral disc protrusion and osteophytosis, L5 anterolisthesis	0: flat feet; 4: L2 spondylolisthesis, scoliosis; 14: coxa valga; 20: knee villonodular synovitis; 28: joint stiffness	0: clubfoot; 0-1: hip dysplasia; 9 flat feet; 23: genu valgum; 25: spine degenerative changes; 28: anterolisthesis and vertebral disc protrusion	20: flat valgus feet; 25: dorsolumbar scoliosis, bulging disc, deformities of vertebral bodies; 30: joint and spine pain; 32: bilateral coxarthrosis and gonarthrosis	39: scoliosis, bilateral coxarthrosis, joint stiffness, bilateral flat valgus feet	19: Scoliosis, flat feet	Bilateral genu valgum, hammer toes, 20-38:L4-L5 retrolisthesis, L5 wedge deformity	1: hip dysplasia; 22: gonarthrosis coxarthrosis, femoral head osteonechrosis; 25: joint stiffness and pain; 26: scoliosis, lumbar kyphosis, L2 wedge deformity and disc protrusion
Surgery	6 : adenoidectomy, 12 : genu valgum; 23: dental implant	3: right and 24: left inguinal hernioplasty, 3 and 4: flat feet; 7:adenoidectomy; 29:cholecystectomy; 31: bilateral carpal tunnel and bilateral flexor tenotomy 2 nd , 3 rd , 4 th finger	7:adenoidectomy; childhood flat feet; 21: necrotizing fasciitis bonification; 24: hallux valgus correction; percutaneous osteotomy of the II, III, IV metatarsal for instability; 28: umbilical hernioplasty	12 and 13: flat feet; 20: sacro-coccygeal fistula; 25: inguinal hernioplasty; 38: hysterolamnectomy	1: bilateral inguinal hernioplasty; 40 and 45: arthrocentesis left knee	47: umbilical hernioplasty	2:adenoidectomy; trans-tymppanic drainage	1: inguinal and umbilical hernioplasty, 4: adenoidectomy; 6: tonsillectomy, 39: removal of two small colon tubular adenomas	4:adenoidectomy; 13y arthrocentesis right knee; 27: umbilical hernioplasty; 28: laparoscopic removal of gallbladder stones; 30 and 33: bilateral carpal tunnel
Latest height in cm	33 : 152 (-2)	35 : 175 (-0.3)	30 : 170 (-1)	37 : 156 (-1.1)	51 : 169 (-1.3)	47: (-2.4)	19 : 164 (-2)	42 : 174 (-0.5)	32 : 165 (0.4)
Age at latest evaluation	38	38	32	39	51 (52 died)	57	22	43	40

^aCouple of siblings.

^bCouple of siblings.

^cCalculated on 8 patients.

^dCalculated on 5 patients.

^eCalculated on 4 patients.

Brain MRI: A, atrophy, B, brain, C, cerebellar, H, hypoplasia, V, vermis; Heart: MI, mitral insufficiency; TI, tricuspid insufficiency; ASI, aortic steno-insufficiency; Infections: RUTI: recurrent upper respiratory tract infection; na, not available; Sight: M, myopia; As, astigmatism; Am, amblyopia; R, retinopathy; KC, keratoconus; WAIS-R VIQ/ PIQ, WAIS-R verbal intelligence quotient/performance intelligence quotient; WMA, white matter abnormalities.

immunodeficiency, neuroimaging characteristics and psychiatric symptoms.

- (5) Other clinical issues that required a specialistic consultancy or surgery.
- (6) Immunological assessment.
- (7) Neuroradiological examination.

A longitudinal overview of disease progression in each patient in multiple organs and systems was conducted based on the data extracted from the clinical records, subdivided into decades.

Data analysis

Categorical variables were reported as counts and percentages; continuous variables were reported as mean \pm SD or median, and range [minimum-maximum] as appropriate.

Results

Nine Italian patients were enrolled, whose age was 22–57 years (mean, 40.1 ± 10.2 ; median, 39 years). They were followed up for a period ranging from 3 to 20 years (median, 19 years). The cohort consisted of three females and six males and included two pairs of siblings (Table 1). Seven patients were born from non-consanguineous parents after healthy pregnancies, and two were from consanguineous parents (first cousins). Only one high-risk pregnancy with an abortion threat was reported.

Both enzyme activity and genetic testing were carried out, except for patient 7, who only had genetic diagnosis. Leukocyte enzyme activity was assayed by different laboratories and was expressed as nm/mg/h. The results are reported in Table 1, as percentages of the mean normal values. Table 1 shows the more relevant clinical and biochemical data, and genotypes of each patient. Table 2 reports the main signs and symptoms of each patient with the age of onset. The progression of the walking disability is shown in Fig. 1.

Coarse face

Patients showed signs such as bitemporal constriction, prognatism, dolichocephaly, macrocrania, macroglossia, hypertelorism, large ears and flat occiput. These signs became increasingly evident throughout the patients' life.

Hearing loss

Most of the patients had mild hyperacusis earlier in life. At the latest examination, all patients showed severe, bilateral, sensorineural and pantonal hearing loss, corrected with hearing aids in eight patients.

Language and dysarthria

All patients had language difficulties from their first years of life except for patients 6 and 8 according to reports by

their parents. Dysarthria appeared later and progressively worsened, paralleling the trend of walking disability.

Dysphagia

Only five patients showed dysphagia from the third–fourth decade of life.

Gait

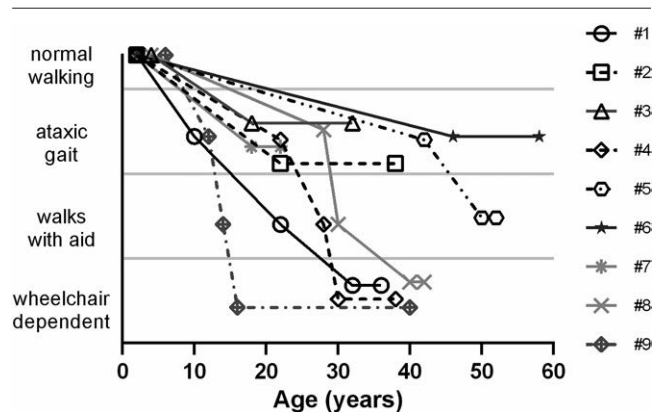
All patients initially showed normal walking, although six of the nine patients displayed a delay in the acquisition of motor stages. At a median of 22 years, all patients developed an ataxic gait with choreic and atetoid movements of the upper limbs. In later years, walking aids or support provided by the caregiver became necessary for five patients. Four patients became wheelchair users (Table 2 and Fig. 1).

Psychomotor development and cognitive delay

All nine patients showed a slow progressive decline in cognitive functions, affecting analytical and logical reasoning, short- and long-term verbal memory, problem solving and executive functions (working memory, planning, attention).

They all attended primary school, and most of them had a support teacher, one starting from the kindergarten (patient $n = 1$). Three patients ($n = 4, 7, 8$) also attended three years of secondary vocational school with a support teacher. 4 patients (patient $n = 2, 3, 4, 8$) were administered WAIS-R development test for verbal and performance IQ evaluation more than once. In patients 2, 3, 4, tested in the second and third decades of life, the verbal IQ dropped consistently over a period of 10–13 years, while the performance IQ remained stable. Patient 8, tested in the fourth decade, had a stable verbal IQ after 5 years with a slight reduction in performance.

Fig. 1



Progression of walking disabilities over the decades of age in each patient.

Psychiatric symptoms

All patients had a variable combination of psychiatric symptoms including anticipatory anxiety, depression, phobias, hallucinations, intrusive thoughts, aggression, and sleep-wake rhythm inversion. Five patients were treated with antipsychotic drugs, 2 patients with selective serotonin reuptake inhibitors (SSRI) and 2 patients were not treated. Pharmacological therapy led to a stabilization over time.

Neuroimaging

MRI was available for 8 patients in our cohort. Only 2 patients (n = 3, and n = 5) had a normal brain MRI at the first evaluation (17 and 18 years, respectively). Six patients had cerebellar atrophy or hypoplasia, six showed cortical atrophy or hypoplasia, and five had periventricular white matter signal abnormalities.

Hepatosplenomegaly

Most of the patients in this study had mild hepatosplenomegaly. The number of patients who showed this sign has increased progressively over the decades (Fig. 2).

Heart valve disease

Valve regurgitation was common: the mitral valve was affected in all nine patients, the tricuspid valve in five and the aortic valve in three. Valve insufficiency was diagnosed in the second or third decade of life, and was never severe.

Sight

Four patients had myopia, three had astigmatism; one had amblyopia, three had retinopathy, and one had bilateral keratoconus. One patient had vitreous hemorrhage at the age of 39 years. Glasses were necessary for three patients.

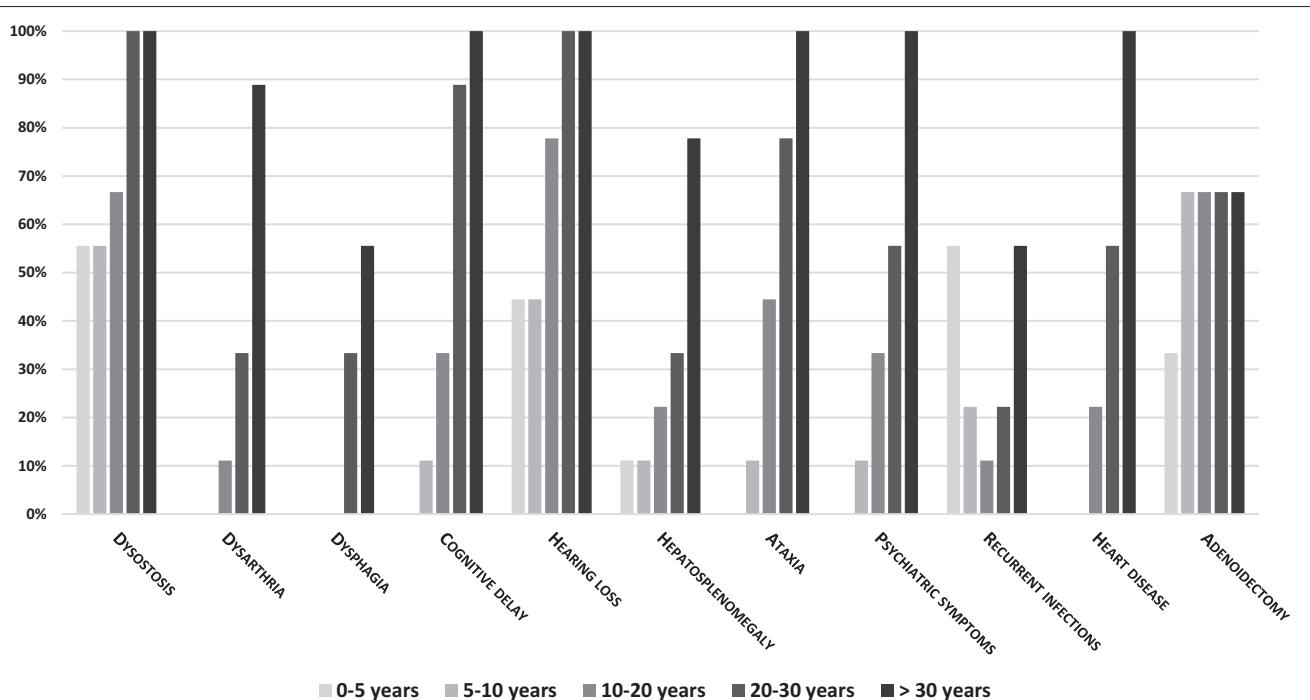
Recurrent infections and immune deficiency

Only a single patient did not experience recurrent infections, while seven patients had recurrent upper respiratory tract infections. Recurrent urogenital infections occurred in two patients, whereas recurrent otitis, recurrent abscesses in several districts and severe cutaneous/subcutaneous infections were reported each in three patients. In blood serum, four patients (n = 2, 3, 4, 8) had IgM deficiency, patient 4 also had IgG and IgA deficiency, and patient 8 had low IgG. Patient 3 also showed a low leukocyte count. Two patients (n = 3 and n = 4) started weekly subcutaneous immunoglobulins administration in the third decade of life, with a good response in terms of reducing infections.

Orthopedic signs/symptoms

The districts involved were the feet, knees, hips, and spine. Pes planus was the most frequent orthopedic sign reported in seven patients; five displayed knee complications (valgus knees, gonarthrosis) and five had coxa valga/hip dysplasia. The spine was affected in several ways, with the most frequent being scoliosis, described

Fig. 2



Disease progression indicated as the percentage of patients showing the signs or symptoms over the decades.

in six patients. Four patients had spondylolisthesis; four had disc protrusions or bulging discs; and three displayed wedge deformities of the vertebral bodies. Two patients developed pathological fractures. Coxarthrosis, spondyloarthrosis, and gonarthrosis were other frequent features, found in six patients between 22 and 39 years of age.

Surgeries

Hernioplasty (umbilical and inguinal) was the most frequent surgery, performed 10 times in seven patients. Six patients underwent adenoidectomy, 6 surgeries were performed to correct pes planus and 4 for median nerve decompression. Each patient underwent a minimum of 1 surgery in the course of their life up to a maximum of 9.

Disease progression

All signs and symptoms of mannosidosis showed considerable worsening with age (with the exception of the necessity for adenoidectomy, which did not increase after the second decade) (Fig. 2).

Height

The final height of the patients ranged between -2 and $+0.4$ SD, being in the lower extremity of the normal range (from -2 to $+2$ SD).

Discussion and conclusion

AM is an ultra-rare, progressively worsening disease, with a consistently wide phenotypic variability. A characteristic feature of this disease is the extremely slow progression of signs and symptoms in most patients, to such an extent that AM can sometimes appear as a non-progressive disease. To our knowledge, only one study has shown the very long-term evolution of 12 patients who were followed up for more than 10 years (Lipinski *et al.*, 2021), highlighting the need for further longitudinal studies on disease progression.

The issue of whether and how signs and symptoms worsen in AM patients, not only in the first years of life but also further on, has acquired increasing importance since etiologic treatments have been proposed. The natural history of the disease may be compared to the evolution of patients who are treated with HSCT, ERT, or other innovative treatments. This comparison might help understand the age limit for performing HSCT, when benefits are expected to be greater than disadvantages, and whether there is an age or condition when particular benefits from ERT are not to be expected.

In our patients, the wide variability of phenotype severity was evident. However, we were able to show the progression of symptoms, including heart valves, joints, gait, language and dysarthria, psychiatric symptoms, IQ, MRI, and hearing (Figs. 1 and 2 and Table 2) in the whole cohort.

Hearing loss was present in most of our patients at a young age, whereas others had a late diagnosis of hearing loss. Although other studies have reported moderate-to-severe and non-evolving hearing loss at a very young age (Lipinski *et al.*, 2021), our findings suggest that hearing loss may worsen over the years, in line with the other signs and symptoms of AM. The pathogenesis of hearing loss is not well defined and might be the objective of future experimental studies. Gait performance is the result of many functions, such as joint integrity, neuromotor and visuo-spatial coordination, and cognitive achievements. Figure 1 clearly shows the progressive worsening of gait in our patients, as a result of the progressive deterioration of joints and neurological functions.

With the exception of ADHD diagnosed in one patient at 7 years of age, psychiatric symptoms (depression and psychotic manifestations) appeared in the second or third decade, and progressively worsened. However, patients seemed to respond well to pharmacological treatment with common antipsychotic drugs. Malm *et al.* (2005) highlighted the relevance of psychiatric manifestations in AM. They reported the presence of mental disturbance in 11/45 patients aged >15 years. None of our patients were free of psychiatric manifestations, with less involvement in the youngest patient who was 19 years old at the latest examination. Psychiatric disturbances were probably the main cause of deterioration in the quality of life of both patients and their caregivers. This underlines the importance of monitoring this aspect with periodic specialist evaluations to avoid overlooking the first manifestations and allow prompt and adequate pharmacological treatment.

According to a recent description of MRI abnormalities in 13 untreated patients (median age, 17 years) (Majovska *et al.*, 2021), the most frequent anomalies in our patients were cerebellar and vermis atrophy, cortical atrophy, and periventricular white matter abnormalities. These lesions appeared early in life in some patients and were progressive with age, correlating with worsening of ataxia and cognitive performances.

Only one patient in our cohort died at 52 years of age due to colon cancer. This was the same patient who was previously reported by Hennermann *et al.* (2022).

The median diagnostic delay (11 years) was high in our cohort of patients, in line with other reports (Adam *et al.*, 2019). AM, compared to other lysosomal storage diseases, is probably more challenging to diagnose, because of its ultra-rare prevalence, very slow progression, and absence of specific or even pathognomonic symptoms. Guffon *et al.* (2019) proposed an algorithm for the diagnosis of AM in patients aged < 10 years and > 10 years of age (Guffon *et al.*, 2019). The first sign considered in patients < 10 years of age was hearing impairment/speech delay. Among our patients only one (n 8) did not

display hearing impairment or speech delay in the first decade of life. However, patient n 8 showed all other relevant symptoms for diagnosis after 10 years (Guffon *et al.*, 2019).

The first signs and symptoms reported in our cohort in the first five years of life included walking delay, orthopedic issues (congenital hip dislocation, pes planus, scoliosis, valgus knees and cranial hyperostosis), hearing loss, speech delay and recurrent infections (otitis and upper respiratory tract infections). The coexistence of some of these signs and symptoms should raise the clinician's suspicion of AM. This is of utmost importance because an early diagnosis could allow earlier and wider access to the therapies available today, and consequently, have a notable impact on the quality of life of the patient and their family.

In conclusion, our case series of nine AM patients followed-up for over two decades showed very early onset of signs and symptoms, with a slow progressive worsening over the years. Consequently, the ideal age to start the available treatments (HSCT, ERT) would be upon the appearance of the first signs/symptoms, or the pre-symptomatic period if the disease is detected through neonatal screening. However, considering the slow progression of the disease, HSCT might be effective even if performed late in the first decade of life (Mynarek *et al.*, 2012). Similarly, ERT may reasonably be useful at all ages, with the limitation that it does not cross the blood-brain barrier, and unlike HSCT, it cannot treat damage to the central nervous system (Harmatz *et al.*, 2018). Due to the slow progression and the rarity of the disease, demonstration of the efficacy of any treatment will undoubtedly be a lengthy process, but necessary to provide the highest standard of care for future patients.

Acknowledgements

We acknowledge the Services of Neuroradiology, Neurology, Surgery and Neurosurgery, Psychiatry, Physiotherapy, Ophthalmology, ENT, Cardiology, Orthopedics, Infection Diseases, Immunology of San Gerardo Hospital and the other Hospitals involved, all the patients and their families, and the wonderful secretaries Vera Marchetti and Gabriella Bertazioli (San Gerardo Hospital) for their attentive collaboration. We are also grateful to Dr Francesca Lanfranconi, M.D., University of Milano-Bicocca, Monza, for her technical assistance and Dr Serena Melgrati, Institute for Research in Biomedicine, Bellinzona (CH) for English editing.

The patients and/or their caregivers have signed a written consent for the publication of their clinical data.

Informed consent has been obtained from patients that grant permission for the publication of images as part of this work.

Conflicts of interest

There are no conflicts of interest.

References

- Adam J, Malone R, Lloyd S, Lee J, Hendriksz CJ, Ramaswami U (2019). Disease progression of alpha-mannosidosis and impact on patients and carers - a UK natural history survey. *Mol Genet Metab Rep* **20**:100480.
- Beck M, Olsen KJ, Wraith JE, Zeman J, Michalski JC, Saftig P, *et al.* (2013). Natural history of alpha mannosidosis a longitudinal study. *Orphanet J Rare Dis* **8**:88.
- Chester MA, Lundblad A, Öckerman PA and Autio S (1982). *Mannosidosis*. In: Durand P, O'Brien JF (eds) Genetic errors of glyco-protein metabolism. Ed: Ermes, Milan, chapt. 4, pp 89–120.
- Desnick R, Sharp HL, Grabowski GA, Brunning RD, Quie PG, Sung JH, *et al.* (1976). Mannosidosis: clinical, morphologic, immunologic, and biochemical studies. *Pediat Res* **10**:985–996.
- Guffon N, Tylki-Szymanska A, Borgwardt L, Lund AM, Gil-Campos M, Parini R, *et al.* (2019). Recognition of alpha-mannosidosis in paediatric and adult patients: Presentation of a diagnostic algorithm from an international working group. *Mol Genet Metab* **126**:470–474.
- Harmatz P, Cattaneo F, Ardigo D, Geraci S, Hennermann JB, Guffon N, *et al.* (2018). Enzyme replacement therapy with velmanase alfa (human recombinant alpha-mannosidase): novel global treatment response model and outcomes in patients with alpha-mannosidosis. *Mol Genet Metab* **124**:152–160.
- Hennermann J, Raebel EM, Donà F, Jacquemont M-L, Cefalo G, Ballabeni A, Malm D (2022). Mortality in patients with alpha-mannosidosis: a review of patients' data and the literature. *Orphanet J Rare Dis* **17**:287.
- Lipinski P, Rozdzynska-Swiatkowska A, Iwanicka-Pronicka K, Perkowska B, Pokora P, Tylki-Szymanska A (2021). Long-term outcome of patients with alpha-mannosidosis – A single center study. *Mol Genet Metab Rep* **30**:100826.
- Majovska J, Nestrail I, Paulson A, Nascene D, Jurickova K, Hlavata A, *et al.* (2021). White matter alteration and cerebellar atrophy are hallmarks of brain MRI in alpha-mannosidosis. *Mol Genet Metab* **132**:189–197.
- Malm D, Nilssen O (2008). Alpha-mannosidosis. *Orphanet J Rare Dis* **3**:21.
- Malm D, Halvorsen DS, Tranebjærg L, Sjursen H (2000). Immunodeficiency in alpha-mannosidosis: a matched case-control study on immunoglobulins, complement factors, receptor density, phagocytosis and intracellular killing in leucocytes. *Eur J Pediatr* **159**:699–703.
- Malm D, Pantel J, Linaker OM (2005). Psychiatric symptoms in alpha-mannosidosis. *J Intellect Disabil Res* **49**:865–871.
- Malm D, Riise Stensland HMF, Edvardsen O, Nilssen O (2014). The natural course and complications of alpha-mannosidosis - a retrospective and descriptive study. *J Inherit Metab Dis* **37**:79–82.
- Mynarek M, Tolar J, Albert MH, Escobar ML, Boelens JJ, Cowan MJ, *et al.* (2012). Allogeneic hematopoietic SCT for alpha-mannosidosis: an analysis of 17 patients. *Bone Marrow Transplant* **47**:352–359.
- Öckerman PA (1967). A generalized storage disorder resembling Hurler's syndrome. *Lancet* **290**:239–241.
- Sbaragli M, Bibi L, Pittis MG, Balducci C, Heikinheimo P, Ricci R, *et al.* (2005). Identification and characterization of five novel MAN2B1 mutations in Italian patients with alpha-mannosidosis. *Hum Mutat* **25**:320.
- Zielonka M, Garbade SF, Kölker S, Hoffmann GF, Ries M (2019). Ultra-orphan lysosomal storage diseases: a cross-sectional quantitative analysis of the natural history of alpha-mannosidosis. *J Inherit Metab Dis* **42**:975–983.