

Lethal recurrent mycotic ascending aortic pseudoaneurysm in a 21-month-old child with repaired subaortic membrane

Khaled A. Alhawri^{1,2}, Usama H. Elsaedy¹, Sami A. Alahdal³, Nabil S. Albahlooli³, Abdullah A. Al Qwae¹, Ali A. Alakhfash^{1,2}

¹Prince Sultan Cardiac Center, Qassim, Saudi Arabia, ²PhD Researcher, La Sapienza University Rome, Italy, ³Prince Sultan Cardiac Center, Riyadh, Saudi Arabia

ABSTRACT

Mycotic pseudoaneurysm of the aorta is a rare and lethal complication of pediatric congenital heart surgery. We report the lethal consequences of recurrent mycotic pseudoaneurysm in an 18-month-old baby, early after subaortic membrane resection. We managed to repair the pseudoaneurysm successfully by replacing the infected ascending aorta using bovine jugular vein graft, but unfortunately, the patient developed new pseudoaneurysm at the site of anastomosis which led to his death. Although prompt diagnosis and surgical management can save the patient life, uncontrolled infection can lead to the recurrence of the problem and lethal results.

Keywords: Case report, congenital heart surgery, endocarditis, mycotic ascending aortic pseudo-aneurysm

INTRODUCTION

Mediastinal pseudoaneurysms are rare but life-threatening complications of ascending aortic operations.^[1] It can be caused by multiple factors including aortic dissection, infection, connective tissue disorders, aortic calcification, and aortotomy site blowout. Several cases have been reported, most of which were secondary to bacterial endocarditis.^[2,3]

During its repair, sternal reentry alone can precipitate fatal hemorrhage or cerebral air embolism. Peripheral cannulation and hypothermic arrest are a well-known surgical entity. We stress this strategy, which helped us prevent an impending rupture and repair the defect.

Our case describes the recurrence of this complication which was managed surgically on time without any surgical complications. Yet, the patient developed again another pseudoaneurysm at the new suture line, which led to his death.

CASE REPORT

A 21-month-old boy, weighing 10 kg, was referred to our center as a case of the aortic mycotic pseudoaneurysm. He underwent uneventful resection of subaortic membrane (SAM) and primary repair of a hole in the right coronary cusp which was causing severe regurgitation, at another hospital. Transesophageal echocardiography showed no more SAM, patent left ventricular outflow, and moderate aortic regurgitation. He received 10 days broad-spectrum antibiotics prophylactically because he had a persistent low-grade fever which started 6 h postoperatively with negative septic screening and low inflammatory markers. He was discharged home in stable condition on the 11th postoperative day. Five days later, he was re-admitted complaining of lethargy, fever 39°C, and mild sternal wound discharge. He was tachycardic (140/min), with leukocytosis ($22 \times 10^9/L$) and raised

This is an open access journal, and articles are distributed under the terms of the Creative Commons Attribution-NonCommercial-ShareAlike 4.0 License, which allows others to remix, tweak, and build upon the work non-commercially, as long as appropriate credit is given and the new creations are licensed under the identical terms.

For reprints contact: reprints@medknow.com

How to cite this article: Alhawri KA, Elsaedy UH, Alahdal SA, Albahlooli NS, Al Qwae AA, Alakhfash AA. Lethal recurrent mycotic ascending aortic pseudoaneurysm in a 21-month-old child with repaired subaortic membrane. *Ann Pediatr Card* 2020;13:252-5.

Access this article online

Quick Response Code:



Website:

www.annalspc.com

DOI:

10.4103/apc.APC_1_20

Address for correspondence: Dr. Khaled A. Alhawri, Prince Sultan Cardiac Center, Qassim, Saudi Arabia. E-mail: alhawri@hotmail.com

Submitted: 01-Jan-2020

Revised: 03-Apr-2020

Accepted: 28-Apr-2020

Published: 19-Jun-2020

acute-phase proteins. His chest x-ray showed widened mediastinum [Figure 1]. The echocardiogram showed a big anterior pseudoaneurysm of the ascending aorta with no thrombi [Figure 2]. Computed tomography (CT) scan showed a huge pseudoaneurysm arising from the anterior wall of the ascending aorta; the dimensions were 4.1 cm × 4.3 cm × 3.9 cm. The neck was 12.3 mm and was compressing the superior vena cava, with mild pericardial effusion [Figure 3]. Blood culture was positive for *Streptococcus mitis*/*Streptococcus oralis*.

The patient was taken to the theater. Femoro-femoral cannulation (arterial size 10, venous 15) was started using Gore-Tex tube size (3.5) mm on the side of the left common femoral artery, and direct femoral venous cannulation. The cardiopulmonary bypass was started through this for femoral approach with flow of 100 ml/kg, and the patient was cooled till 18°C. The sternotomy dissection was started on the diaphragmatic surface of the heart before opening the sternal bone, and an additional inferior vena cava cannula size (20) was added to improve drainage. Then, the sternum was opened uneventfully. A huge pulsating mass was found and covered by kissing lungs. Systemic and surface cooling caused the heart rate to drop. The aneurysmal sac was opened inadvertently during dissection, yet we managed to start total hypothermic circulatory arrest soon, then cardioplegic solution was administered directly in the coronary ostia to arrest the heart and the dissection was finished proximally and distally. An aortic cross-clamp was applied after completing the dissection. The ascending aortic tissue was amalgamated and eaten by the severe infection at the site of aortotomy, yet the sinotubular junction was intact. The aortic valve leaflet was free of vegetation. Due to the unavailability of homo-grafts and the small size of the patient, bovine jugular vein graft (Contegra® Medtronic, USA) size 12 was used to replace the ascending aorta above the sinotubular junction using interrupted 5/0 sutures.

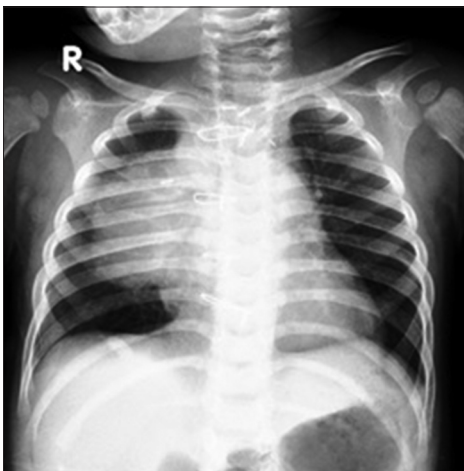

Figure 1 : Chest X-ray showing widening of the mediastinum

The chest was left open and was closed the next morning. The patient was extubated after 48 h. He had good urine output and minimal inotropes and no neurological deficit. On the 8th postoperative day, the patient developed persistent fever (39°C). The patient was already covered with multiple bacterial and antifungal antibiotics as per the advice of our infection department team (vancomycin, linezolid, meropenem, ciprofloxacin, gentamycin, and caspofungin). The blood culture showed no growth. Four days later, the patient started to have shortness of breath, abdominal distension, and hypotension. The hemoglobin dropped (from 10.2 g/dL to 7g/dL), and the arterial blood gas showed metabolic acidosis due to low cardiac output. Mechanical ventilation, inotropes, renal replacement therapy, and blood transfusion were commenced. Echocardiography showed flow turbulence and stenosis of the proximal conduit with new aneurysmal dilatation above the aortic sinuses [Figure 4]. CT scan confirmed the presence of these findings in addition to evidence of aneurysmal leak with a huge anterior mediastinal hematoma [Figure 5].

The case was discussed thoroughly. Given the aggressiveness of the infection, the rapid deterioration, and hemodynamic instability, the risk outweighed the benefit of surgical intervention, and a form of do not resuscitate was signed after discussion with the family. The patient continued to deteriorate with hypotension, tachycardia, abdominal distension, low urine output, and metabolic acidosis. The patient died shortly after that.

DISCUSSION

Aortic pseudoaneurysms are rare but recognized complications of cardiac surgery. They are uncommon in children, though several case reports are available in the literature.^[2,3]

Edwin emphasized ways to prevent postoperative pseudoaneurysm which include performing proper suture technique, careful handling of the aorta wall, strict asepsis, and aggressive treatment of perioperative infection.^[4]

The term “mycotic aneurysm” is a misnomer. It was initially used to describe aneurysms associated with bacterial invasion of the blood vessel wall by organisms other than syphilis due to their resemblance to “fresh fungus vegetations.” Currently, the term describes an aneurysm or pseudoaneurysm caused by any infectious agent.^[5]

The most prevalent organism associated with infective endocarditis (IE) is *Streptococcus viridans* in addition to other streptococcal species, *Staphylococcus aureus*, *Salmonella*, and the HACEK organisms (*Hemophilus* species, *Actinobacillus actinomycetemcomitans*, *Cardiobacterium hominis*, *Eikenella corrodens*, and

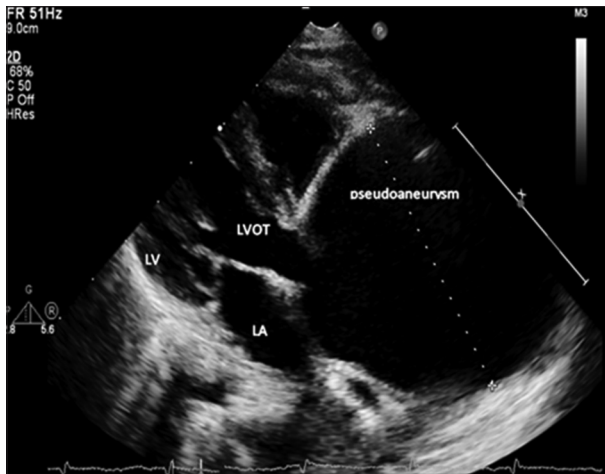


Figure 2: Long-axis parasternal echocardiogram showing the pseudoaneurysm with no thrombus in it

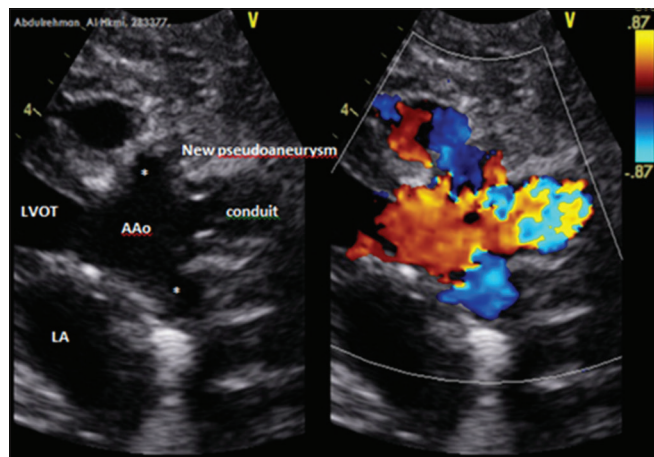


Figure 4: Postoperative echo showing the newly formed pseudoaneurysm star (*), AAO: Ascending aorta, LVOT: Left ventricular outflow tract, LA: Left atrium

Kingella species). *Staphylococcus* species are more common in early postoperative infections.^[6]

Our patient had *S. mitis*/*S. oralis* that was isolated only preoperatively from the blood culture. *S. mitis* and *S. oralis* are human oral colonizers, opportunistic pathogens, and species of the viridans group streptococci.^[7] Although 50%–75% of the patients have organisms isolated after early open repair of the mycotic aneurysm,^[8] we were not able to isolate the bacteria by culture of the surgical specimen, probably because the patient was already on antibiotics when he reached our center.

Chest X-ray and echocardiogram are easy and helpful investigations that can detect this disease early with a high index of suspicion [Figures 2 and 4]. CT angiogram can confirm and delineate the aneurysm's size and extension [Figures 3 and 5].

Both percutaneous and surgical repairs have been advocated in the literature. However, percutaneous

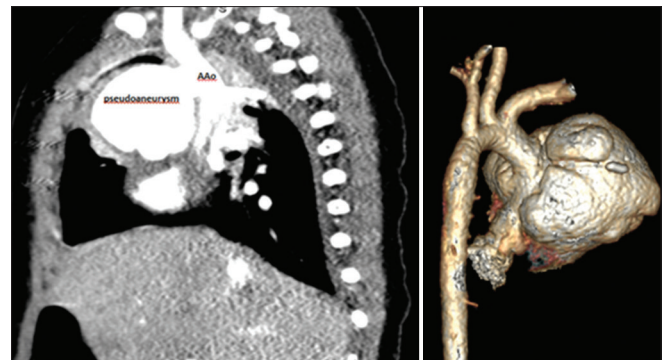


Figure 3: Computed tomography angiogram which shows a pseudoaneurysm arising from the anterior wall of the ascending aorta. Dimensions were 4.1 cm × 4.3 cm × 3.9 cm with a 12.3 mm neck. AAO: Ascending aorta

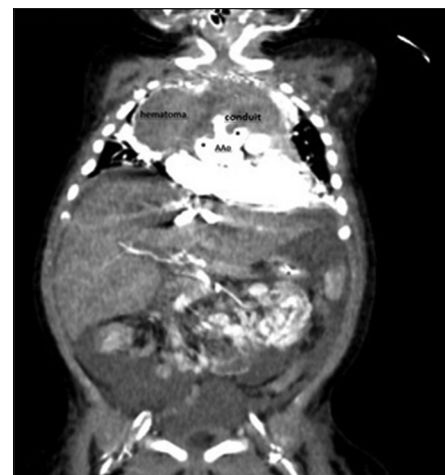


Figure 5: Computed tomography scan of the new pseudoaneurysm, AAO ascending aorta, * newly formed pseudoaneurysm. AAO: Ascending aorta

closure has been successfully reported in the adult population only.^[9] Infection precludes the use of percutaneous devices.

The most important part of the surgery is to avoid bleeding during re-sternotomy and to maintain proper cerebral perfusion. Different methods have been proposed to establish cardiopulmonary bypass before re-sternotomy. Neck cannulation is preferred by some, especially in neonates and infants because the femoral vein is too small in neonates and infants to accommodate a large enough cannula for appropriate blood drainage. Others prefer femoral cannulation to avoid the possible neurological injury associated with carotid cannulation. Femoral arterial cannulation can produce ipsilateral limb ischemia which can be avoided by inserting a distal reperfusion cannula in the superficial femoral artery or even posterior tibial artery. This can be difficult in children. Alternatively, an end-to-side polytetrafluoroethylene (PTFE) graft may be sewn onto the femoral artery with the cannula placed into the end of the graft, thus preserving flow through

the distal femoral artery.^[10] The latter way was adopted in our case.

Deep hypothermia circulatory arrest (DHCA) has been widely used with satisfactory results.^[11] It helps to avoid cerebral injury by air embolism or low cardiac output secondary to unintentional bleeding. The size, location of the pseudoaneurysm, and the severity of adhesions prevent putting cross-clamp. In fact, our patient was cooled to 18°C, heart rate dropped subsequently, then the dissection was started around the pseudoaneurysm, so when the sac was opened inadvertently, DHCA was started and cardioplegic solution was given in the coronary ostia soon, preventing air embolism and cardiac ischemia.

Although the aortic wall was eaten up by infection, the sinotubular junction and aortic valve were preserved. A homograft conduit could have been the conduit of choice in such situation. Other options include the use of Gore-Tex or Dacron grafts. Due to its unavailability, a bovine jugular vein graft (Contegra)-off label use, was used as an interposition graft. It was fixed using interrupted pledgeted 5/0 polypropylene sutures.

Our patient developed again new aneurysmal dilatation at the site of the proximal anastomosis 12 days after the operation, with leak into the pericardial space; this was attributed to the aggressiveness of the infection and the type of conduit's tissue used. Other possible cause would include a genuine immunocompromised condition which we could not prove although hematological and multidisciplinary teams were involved.

Groning *et al.* reported the increased incidence of IE in the right ventricle-to-pulmonary artery conduits when bioprosthesis was used (Contegra and Melody valves), compared to homografts. This has been confirmed by other reports too.^[12]

Our patient deteriorated quickly after we discovered this newly formed pseudoaneurysm and needed high inotropic support, peritoneal dialysis, and blood transfusion. The option to take the patient back to theater appeared too risky with a very low probability of success this time due to the aggressiveness of the infection and friability of the tissues, in addition to his unstable and critical hemodynamic condition.

CONCLUSION

Aortic pseudoaneurysms are rare but recognized complications of cardiac surgery. Although prompt diagnosis and surgical management can save the patient life, uncontrolled infection can lead to the recurrence of the problem and lethal results.

Declaration of patient consent

The authors certify that they have obtained all appropriate patient consent forms. In the form the

patient(s) has/have given his/her/their consent for his/her/their images and other clinical information to be reported in the journal. The patients understand that their names and initials will not be published and due efforts will be made to conceal their identity, but anonymity cannot be guaranteed.

Financial support and sponsorship

Nil.

Conflicts of interest

There are no conflicts of interest.

REFERENCES

1. Brunner S, Engelmann MG, Nábauer M. Thoracic mycotic pseudoaneurysm from *Candida albicans* infection. *Eur Heart J* 2008;29:1515.
2. Bergsland J, Kawaguchi A, Roland JM, Pieroni DR, Subramaniam S. Mycotic aortic aneurysm in children. *Ann Thorac Surg* 1984;37:314-8.
3. Barth H, Moosdorf R, Bauer J, Schranz D, Akintürk H. Mycotic pseudoaneurysm of the aorta in children. *Pediatr Cardiol* 2000;21:263-6.
4. Edwin F. eComment: Pseudoaneurysms of the ascending aorta following cardiac surgery-are they preventable? *Interact Cardiovasc Thorac Surg* 2010;10:822.
5. Haas B, Wilt HG, Carlson KM, Lofland GK. Streptococcus pneumoniae causing mycotic aneurysm in a pediatric patient with coarctation of the aorta. *Congenital Heart Dis* 2012;7:71-5.
6. Agnihotri AK, McGiffin DC, Galbraith AJ, O'Brien MF. The prevalence of infective endocarditis after aortic valve replacement. *J Thorac Cardiovasc Surg* 1995;110:1708-20.
7. Adams HM, Joyce LR, Guan Z, Akins RL, Palmer KL. *Streptococcus mitis* and *S. oralis* lack a requirement for CdsA, the enzyme required for synthesis of major membrane phospholipids in bacteria. *Antimicrob Agents Chemother* 2017;61:e02552-16.
8. Restrepo MS, Turek JW, Reinking B, Bergen NV. Mycotic aneurysm in a child with history of coarctation of the aorta repair. *Ann Pediatr Cardiol* 2014;7:138-41.
9. Atiyah M, Mohsin S, Al Faraidi L, Al-Hawri K, Al Otay A, Al Najashi K. Surgical management of ascending aortic pseudoaneurysm in a 2-year-old boy: A case report. *J Med Case Rep* 2018;12:98.
10. Finck C, Gadepalli SK, Ruzic A, Rader C. Cannulation for ECLS. In Waldhausen, J, Powell D, Hirschl R (Eds.), *Pediatric Surgery NaT*. American Pediatric Surgical Association 2016. Retrieved May 21, 2020, from https://www.pedsurglibrary.com/apsa/view/Pediatric-Surgery-NaT/829154/all/Cannulation_for_ECLS.
11. Katsumata T, Moorjani N, Vaccari G, Westaby S. Mediastinal false aneurysm after thoracic aortic surgery. *Ann Thorac Surg* 2000;70:547-52.
12. The Center for Devices and Radiological Health, Pediatric Advisory Committee Meeting, Executive Summary, Medtronic Contegra® Pulmonary Valved Conduit Models 200 (unsupported) and 200S (supported); 2019.