

Technical innovations

Open Access

## A novel surgical procedure for bridging of massive bone defects

Ulf R Knothe\*<sup>1</sup> and Dempsey S Springfield<sup>2</sup>

Address: <sup>1</sup>Department of Orthopedic Surgery and Orthopedic Research Center, The Cleveland Clinic Foundation, Cleveland, OH, USA and  
<sup>2</sup>Department of Orthopedic Surgery, The Mount Sinai School of Medicine, New York, NY, USA

Email: Ulf R Knothe\* - [knotheu@ccf.org](mailto:knotheu@ccf.org); Dempsey S Springfield - [Dempsey.Springfield@msnyuhealth.org](mailto:Dempsey.Springfield@msnyuhealth.org)

\* Corresponding author

Published: 03 February 2005

Received: 04 November 2004

World Journal of Surgical Oncology 2005, 3:7 doi:10.1186/1477-7819-3-7

Accepted: 03 February 2005

This article is available from: <http://www.wjso.com/content/3/1/7>

© 2005 Knothe and Springfield; licensee BioMed Central Ltd.

This is an Open Access article distributed under the terms of the Creative Commons Attribution License (<http://creativecommons.org/licenses/by/2.0>), which permits unrestricted use, distribution, and reproduction in any medium, provided the original work is properly cited.

### Abstract

**Background:** Bony defects arising from tumor resection or debridement after infection, non-union or trauma present a challenging problem to orthopedic surgeons, as well as patients due to compliance issues. Current treatment options are time intensive, require more than one operation and are associated with high rate of complications. For this reason, we developed a new surgical procedure to bridge a massive long bone defect.

**Methods:** To bridge the gap, an *in situ* periosteal sleeve is elevated circumferentially off of healthy diaphyseal bone adjacent to the bone defect. Then, the adjacent bone is osteotomized and the transport segment is moved along an intramedullary nail, out of the periosteal sleeve and into the original diaphyseal defect, where it is docked. Vascularity is maintained through retention of the soft tissue attachments to the *in situ* periosteal sleeve. In addition, periosteal osteogenesis can be augmented through utilization of cancellous bone graft or *in situ* cortical bone adherent to the periosteal sleeve.

**Results:** The proposed procedure is novel in that it exploits the osteogenic potential of the periosteum by replacing the defect arising from resection of tissue out of a pathological area with a defect in a healthy area of tissue, through transport of the adjacent bone segment. Furthermore, the proposed procedure has several advantages over the current standard of care including ease of implementation, rapid patient mobilization, and no need for specialized implants (intramedullary nails are standard inventory for surgical oncology and trauma departments) or costly orthobiologics.

**Conclusions:** The proposed procedure offers a viable and potentially preferable alternative to the current standard treatment modalities, particularly in areas of the world where few surgeons are trained for procedures such as distraction osteogenesis (e.g. the Ilizarov procedure) as well as areas of the world where surgeons have little access to expensive, complex devices and orthobiologics.

### Background

Replacement of bone where there is none is one of the most challenging problems facing orthopedic surgeons today. In the case of tumor resection or trauma, massive bone defects must be filled with regenerate bone as

quickly as possible in order to restore function. Current standards for bridging of massive bone defects in long bones generally follow a theme of i) filling the defect with bone autograft or allograft (including cancellous bone graft or bone transplantation via vascularized or non-vas-

cularized fibula transfer) and ii) accelerating functional remodeling and integration through addition of physical and/or chemical stimuli such as tension (e.g. Ilizarov technique, which is a standard surgical treatment modality for bone transport whereby an osteotomy is performed far from the defect site and the transport segment thus created is moved, approximately one millimeter per day, under the constant tension by wires attached to a cumbersome external fixator, until the defect is bridged and the segment can be docked onto the other side of the defect), and orthobiologics (e.g. bone graft or bone graft replacement, BMP's). Surgical treatment modalities involving auto/allografting and bone regeneration via distraction osteogenesis are complex, time intensive procedures of inherently high risk due to vagaries of organ donation, in the case of allografts, and the complexity of soft and hard tissue salvage during the process of distraction osteogenesis. In addition, orthobiologics are costly and their dosage regimes as well as efficacy are currently the subject of much research [1-3].

Both bone grafting and bone transport procedures are complex for the surgeon as well as for the patient. Furthermore, they are susceptible to complications such as delayed union, extensive treatment time periods, infections, and insufficient mechanical function outcomes that can result in fractures. The high complication rates of these procedures exacerbate the previously mentioned difficulties associated with these treatment modalities, from the perspective of the surgeon as well as that of the patient. In short, the inherent risk of complications increases the need for patient compliance and clinical follow-up. Despite the effort associated with these procedures, their results are often less than satisfactory. Hence, the complexity and shortcomings of current state-of-the-art surgical procedures have provided impetus to develop a new treatment modality that provides a relatively straightforward, single step procedure with a high probability of success for the bridging of massive bone defects in long bones. The procedure is straightforward and can be implemented in operating rooms across the world without the need for high-tech equipment or expensive orthobiologics. The purpose of this manuscript is to describe the novel procedure.

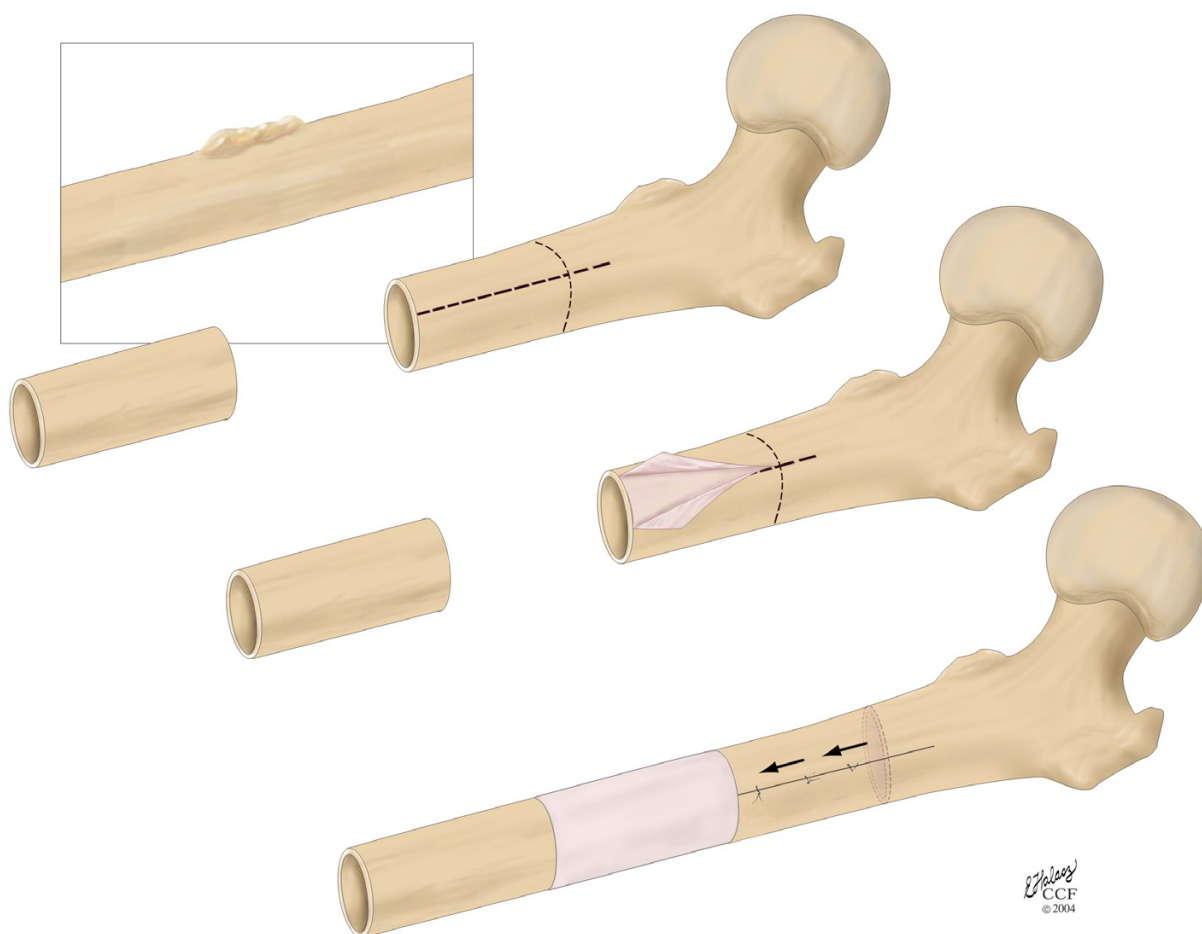
### Technical innovation – methodology and proof of feasibility

The proposed procedure is applicable for clinical scenarios including tumor resection as well as debridement after an infection or non-union. In the case of reconstruction after tumor resection (Fig. 1A), a transport-segment of the diaphysis adjacent to the defect is peeled out of the surrounding periosteum (Fig 1B,C), an osteotomy is performed and the transport-segment is moved out of the periosteal sleeve and docked to the other side of the defect

(Fig. 1D). The periosteal sleeve is then closed like a tube surrounding the newly created defect. Either an internal fixation device such as an intramedullary nail, a plate or an internal fixator or an external fixator can be used to provide stabilization through the healing and regeneration phase.

The proposed procedure depends to a large degree on bone's inherent healing strategies. Bone is a remarkably resilient tissue capable of adaptation to the most extreme biological and mechanical environments; this capacity for self-regeneration without scarring is based on bone's endogenous healing strategies. First, bone remodels itself through osteoclastic resorption and osteoblastic matrix apposition; by constantly reweaving itself, the structure is dynamic and optimal for prevailing mechanical function. Furthermore, the natural healing cascade of bone after trauma recapitulates embryonic endochondral ossification. Hence, modeling, growth and remodeling confer a means to regenerate functional tissue at any time in the life cycle of a bone. The "raw materials" necessary to replace bone are located in the environment or produced by the cells that do the work of regeneration, i.e. osteoclasts and osteoblasts. In the case of regeneration of bone in defects, further potentially key constituents to the formation of a functional regenerate in situ include a patent blood supply, chemical gradients of morphogens and/or cytokines, a template onto which the cells can anchor themselves during the rebuilding process (e.g. graft or a scaffold), and biophysical stimuli such as fluid flow and/or cell level strains. The proposed procedure essentially replaces the defect site in a pathological zone with a defect site in a healthy bed of tissue and provides for progenitor cells through the surrounding, healthy periosteum as well as many of the other key constituents for successful tissue regeneration, as defined above.

A clinical case described below demonstrates the osteoinductive potential of the periosteum and serves as a *proof of feasibility* for the proposed procedure. An 11-year old male presented with a low grade surface osteosarcoma of the tibia. After resection of the tumor, the fibula was resected for transfer and the surrounding periosteum was left behind to serve as an osteo-inductive and -conductive sleeve (Figure 2A). Already 3 weeks after the procedure, bone regenerate is visible within this sleeve (Figure 2A). Impressive remodeling of the fibula is also evident in follow up radiographs and includes extensive remodeling of the intramedullary canal by three months post procedure (Figure 2B and 2C). Based on this clinical case as well as one author's previous experience with an *in vivo* segmental defect in an ovine model [4,5], the osteogenic potential of the periosteum as a source of progenitor cells and as a "membrane" or boundary template for guided bone generation is demonstrated. Taking this one step further, the



**Figure 1**  
Schematic diagram showing the concept for the new surgical procedure.

corresponding author conceived of the idea to exploit the potential of the healthy periosteum by moving the defect site from a pathological zone to a healthy one and then providing sufficient mechanical stability to let bone's endogenous healing capacity regenerate functional tissue within the new defect zone.

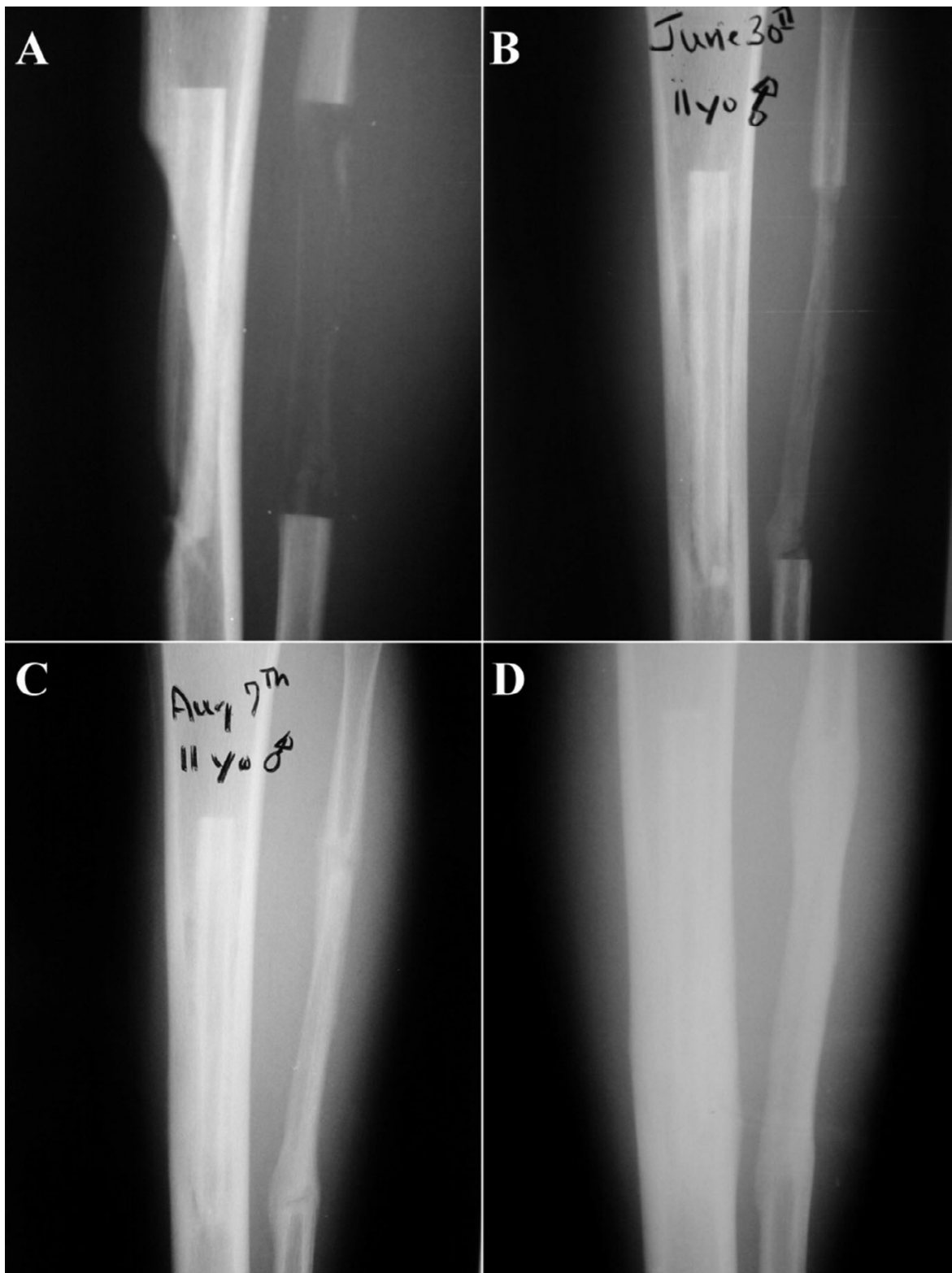
### Discussion

The proposed procedure is novel in that it introduces for the first time the possibility to bridge a massive defect in a long bone using a single stage procedure. Furthermore, the proposed procedure has several advantages over the current standard of care including ease of implementation, lack of requirement for specialized implants (intramedullary nails are standard inventory for surgical oncology and trauma departments) or costly orthobio-

logics, and rapid patient mobilization. This makes the proposed procedure a viable and potentially preferable alternative to the current standard treatment modalities, particularly areas of the world where few surgeons are trained for procedures such as distraction osteogenesis (e.g. the Ilizarov procedure) as well as where surgeons have less access to expensive, complex devices and orthobiologics.

### Conclusion

In summary, the authors propose a new procedure which obviates the need for several surgical procedures, reduces the risk for complications, reduces the time frame for the treatment and is much more comfortable for and requires less compliance of the patient. This novel, one stage procedure exploits the osteogenetic potential of the



**Figure 2**

11 year male with malignant tumor. Fibula-pro-tibia following local resection. Cortical regeneration from periosteum. Performed at Mt. Sinai Medical Center, NYC, 2000. **A:** 3 weeks post-operative radiograph, **B:** 6 weeks post-operative, **C:** 3 months post-operative, **D:** approximately 6 months post-operative.

periosteum for bone formation to bridge the defect with concomitant bone transport and does not require the use of expensive hardware or orthobiologics.

### Competing interests

The author(s) declare that they have no competing interests.

### Authors' contributions

UK conceived of the technical innovation, organized its design and coordination, and drafted the manuscript. DSS was the senior surgeon in the clinical case showing feasibility. Both authors read and approved the final manuscript.

### Acknowledgements

Permission was obtained from the patient's guardian regarding publication of his case report and x-ray photographs.

### References

1. Salkeld SL, Patron LP, Cook SD: **The effect of osteogenic protein-I on the healing of segmental bone defects treated with allograft bone.** *J Bone Joint Surg Am* 2001, **83-A**:803-816.
2. Torricelli P, Fini M, Giavaresi G, Rimondini L, Giardino R: **Characterization of bone defect repair in young and aged rat femur induced by xenogenic demineralized bone matrix.** *J Periodontol* 2002, **73**:1003-1009.
3. Sheller MR, Crowther RS, Kinney JH, Yang J, Di Jorio S, Breunig T, Carney DH, Ryaby JT: **Repair of rabbit segmental defects with the thrombin peptide, TP508.** *J Orthop Res* 2004, **22**:1094-1099.
4. Klaue K, Knothe U, Anton C, Masquelet AC, Petten SM: **Biological implementation of autologous foreign body membranes in corticalization of massive cancellous bone grafts.** *Trans Orthopedic Trauma Association* 1996.
5. Hertel R, Knothe U, Gerber A, Cordey J, Rahn R: **The osteogenic potential of vascularized periosteum and cancellous bone graft in sheep.** *Trans Orthopedic Research Society* 1997.

Publish with **BioMed Central** and every scientist can read your work free of charge

"BioMed Central will be the most significant development for disseminating the results of biomedical research in our lifetime."

Sir Paul Nurse, Cancer Research UK

Your research papers will be:

- available free of charge to the entire biomedical community
- peer reviewed and published immediately upon acceptance
- cited in PubMed and archived on PubMed Central
- yours — you keep the copyright

Submit your manuscript here:  
[http://www.biomedcentral.com/info/publishing\\_adv.asp](http://www.biomedcentral.com/info/publishing_adv.asp)

