

Brachial–Ankle Pulse Wave Velocity: A Most Predictable Arterial Measure for Cerebral Small Vessel Disease

Masanori Munakata

Research Center for lifestyle-related disease, Tohoku Rosai Hospital, Sendai, Japan

See article vol. 27: 922-933

At present, the term “cerebral small vessel disease (CSVD)” is commonly used to describe the neuroimaging diagnosis of brain microvascular injuries. The imaging features of CSVD include lacunes (LACs), white matter hyperintensities (WMHs), cerebral microbleeds (CMBs), and perivascular spaces (PVSs). Patients with CSVD are usually asymptomatic and are less likely to be aware of the silent disease progression. However, accumulated evidence indicates that the development of any CSVD is associated with the incidences of stroke and/or dementia¹⁾. Thus, small vessel diseases are definite vascular damages associated with normal and symptomatic brain diseases. Therefore, the detection of cerebral microvascular lesions at an early stage in patients is of great significance in view of the prevention of symptomatic diseases. However, the diagnosis of CSVD is only possible by brain magnetic resonance imaging (MRI), which involves high cost when applied in a large population. Moreover, such diagnoses by brain MRI are difficult at small clinics. Therefore, the development of a simple screening tool to well discriminate patients at risk and those not at risk of having small vessel diseases would be of great value.

It has been suggested that stiffening of large artery significantly affects cerebral small vessel damage through modulating pulsatile hemodynamic stress²⁾. Moreover, some studies have demonstrated that the structural alteration of the carotid artery is significantly associated with some CSVDs^{3, 4)}. However, to the best of our knowledge, no study has comprehensively examined the best predictive factor for CSVD among several arterial measures, including arterial stiffness, carotid atherosclerosis, and arterial obstruc-

tive markers not related to cerebral circulation. It is challenging to clarify this issue because the simultaneous examination of MRI and multiple arterial measures in a large population is warranted.

In this issue of the Journal of Atherosclerosis and Thrombosis, Kexun Zhang *et al.* examined the relationship between four extracranial arterial measures [i.e., brachial–ankle pulse wave velocity (baPWV), ankle–brachial index, carotid intima–media thickness (IMT), and carotid plaque] and four CSVD markers (i.e., LAC, WMH, CMB, and PVS) and their total burden in 904 participants in the general population recruited from the Taizhou Imaging Study⁵⁾. A total of 443 (49.0%) participants were identified to have at least one of the CSVD markers: 172 (19.0%) with WMH, 184 (20.4%) with LAC, 147 (16.3%) with CMB, and 226 (25.0%) with PVS. Increased baPWV was significantly associated with the all the markers, increased carotid IMT was associated with LAC and PVS, and the presence of carotid plaque was associated with WMH and PVS. Moreover, per standard deviation increment of baPWV and the presence of carotid plaque were significantly associated with greater total CSVD scores. Surprisingly, ankle–brachial index was not significantly associated with any CSVD marker. Therefore, this study showed that 1) among four well-known vascular measures, baPWV best predicted the presence of CSVD and 2) good predictive vascular markers such as ankle–brachial index for cardiovascular events do not necessarily superiorly predict the presence of CSVD.

The prevention of cardiovascular events is certainly an important mission in the treatment of lifestyle-related diseases; however, if we consider the reduction in the number of patients with disability in the aged society, the early detection and prevention of CSVD is also crucial because cerebrovascular diseases

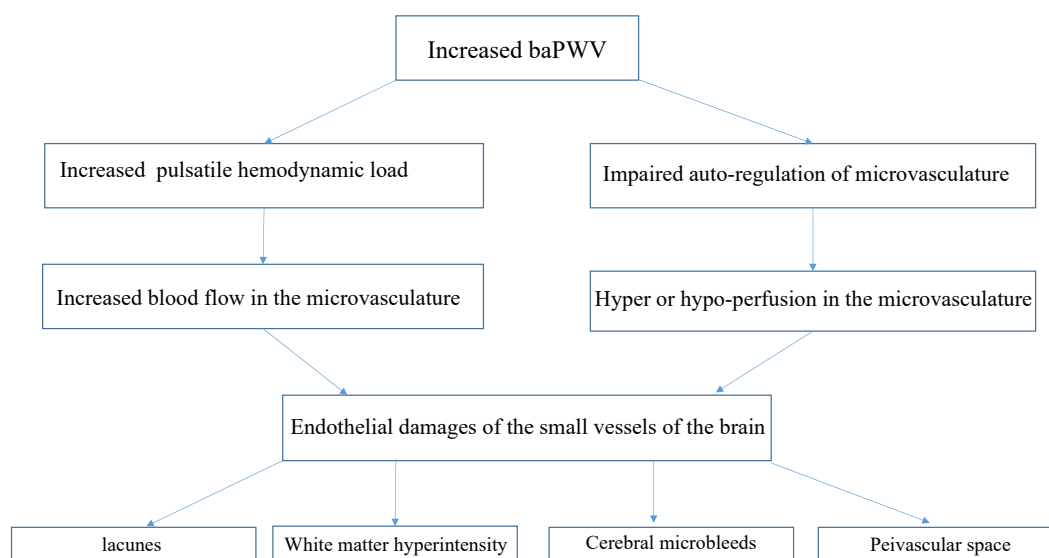


Fig. 1. Possible mechanisms associated with increased baPWV and CSVD

as well as dementia have been suggested as significant causes of disability⁶). The present study suggested baPWV as the best biomarker for predicting the presence of CSVD. Receiver operating characteristic curve analysis demonstrated that the optimal cutoff value of baPWV to discriminate the presence/absence of CSVD was 1,529 cm/s. This is a very reasonable value because it is higher than that to predict incident hypertension but lower than that to predict cardiovascular events in the general population⁷).

The reasons why baPWV was suggested as the best biomarker in relation with the burden associated with the four CSVD markers are worth considering. As noted in this paper, it is possible that increased arterial stiffness of the large artery exerts an excessive pulsatile load and increases the blood flow into the small vessel territory of the brain, leading to endothelial damage and excess permeability (Fig. 1)²). These effects could well explain the development of the four CSVDs. Conversely, the other three arterial biomarkers like ankle-brachial index, carotid intima-media thickness, and carotid plaque explain only the magnitude of organic changes in the large artery and may not well associate it with circulatory changes in the small vessel territory, which would be crucial for determining the small vessel endothelial damage in the brain. Another important possibility that has not been described by the authors is that increased baPWV is associated with the impaired autoregulatory function of the cerebral small vessel, leading to impaired blood flow regulation in the arterial territory, as that hypothesized in the kidney⁸). Actually, this study has demon-

strated the positive correlation between high baPWV and the high risk of LAC as well as PVS even in non-hypertension conditions. These results suggest that cerebral small vessel damage could occur without increasing the central pulsatile stress. A recent review has suggested that both organic and functional alterations of microvascular structures are associated with CSVD⁹). baPWV examines broad arterial stiffness of the large artery to the muscular artery. Therefore, the association between high baPWV and functional changes in microvasculature in the brain is interesting. This issue would be worth studying in the future.

Conflict of Interest

The author declares no conflict of interest.

References

- 1) Rensma SP, van Sloten TT, Launer LJ, Stehouwer CDA. Cerebral small vessel disease and risk of incident stroke, dementia and depression, and all-cause mortality: A systematic review and meta-analysis. *Neurosci Biobehav Rev*, 2018; 90: 164-173
- 2) O'Rourke MF, Safar ME. Relationship between aortic stiffening and microvascular disease in brain and kidney: cause and logic of therapy. *Hypertension*, 2005; 46: 200-204
- 3) Romero JR, Beiser A, Seshadri S, Benjamin EJ, Polak JF, Vasan RS, Au R, DeCarli C, Wolf PA. Carotid artery atherosclerosis, MRI indices of brain ischemia, aging, and cognitive impairment: the Framingham study. *Stroke*, 2009; 40: 1590-1596
- 4) Brisset M, Boutouyrie P, Pico F, Zhu Y, Zureik M, Schil-

-
- ling S, Dufouil C, Mazoyer B, Laurent S, Tzourio C, Debette S. Large-vessel correlates of cerebral small-vessel disease. *Neurology*, 2013; 80: 662-669
- 5) Zhang K, Jiang Y, Wang Y, Suo C, Xu K, Zhu Z, Zhu C, Zhao G, Jin L, Ye W, Cui M, Chen X. Associations of Arterial Stiffness and Carotid Atherosclerosis with Cerebral Small Vessel Disease in a Rural Community-Based Population. *J Atheroscler Thromb*, 2020; 27: 922-933
- 6) Naruse T, Sakai M, Matsumoto H, Nagata S. Diseases that precede disability among latter-stage elderly individuals in Japan. *Biosci Trends*, 2015; 9: 270-274
- 7) Munakata M. Brachial-Ankle Pulse Wave Velocity: Background, Method, and Clinical Evidence. *Pulse (Basel)*, 2016; 3: 195-204
- 8) Munakata M, Miura Y, Yoshinaga K; J-TOPP study group. Higher brachial-ankle pulse wave velocity as an independent risk factor for future microalbuminuria in patients with essential hypertension: the J-TOPP study. *J Hypertens*, 2009; 27: 1466-1471
- 9) Anne M. Dorrance, Bana Abolibdeh, Janice M. Diaz-Otero. Cerebral Small Vessel Disease and Vascular Cognitive Impairment: Preclinical Aspects pp275-285 in *Textbook of Vascular Medicine* Rhian M. Touyz & Christian Delles eds. Springer, 2019