

## Case Report

## Handlebar versus gallbladder: A case of gallbladder rupture in blunt thoracoabdominal trauma without other major injury

Elizabeth B. Lockie\*, Samuel P. Banting, Aaron Y.S. Hui

*Department of General Surgery, The Royal Melbourne Hospital, Australia*

### Case report

A 51-year-old male presented to the emergency department 4 h after falling off a pushbike onto his right side at 20 km/h. He presented to hospital after initially returning home for a brief period, where he reported symptoms of dizziness and nausea and noticed increased swelling to of right side of his abdomen. Primary assessment was significant for blood pressure of 75/48 mmHg (heart rate 86 bpm), which improved to 105/67 with 1 L intravenous 0.9% saline. Focused abdominal ultrasound showed free fluid in right upper quadrant. Secondary survey identified right chest wall tenderness, right upper quadrant tenderness and distension, and grazes on the abdomen. He proceeded to contrast enhanced computer tomography (CT) that demonstrated haemoperitoneum, grade II splenic laceration [2], right sixth to eighth rib fractures, and right transverse process fracture of the first lumbar vertebra (Fig. 1). The patient underwent an emergency trauma laparotomy, that revealed one litre haemoperitoneum, perforated gallbladder with free gallbladder calculi, grade I duodenal haematoma and a grade II splenic laceration. The bleeding was from the gallbladder mucosa and peritoneal covering; the duodenal and splenic injuries were not bleeding. His gallbladder was resected (Fig. 2), and calculi retrieved. His gallbladder appeared fibrosed, as confirmed on histopathology that showed fibrosis. The duodenum and spleen were managed conservatively. He had an uncomplicated recovery post-operatively, with conservative management of the rib and vertebral fractures, and was discharged home seven days later.

### Discussion

Gallbladder rupture following blunt trauma is a rare condition, reported in only 2% of trauma laparotomies for blunt trauma, with isolated gallbladder rupture occurring in under 1% of cases [1]. We present an interesting case of gallbladder rupture due to blunt thoracoabdominal trauma, without other major injury.

Risk factors for gallbladder rupture are related to the mechanism of trauma and gallbladder factors. Gallbladder injuries are far more likely in penetrating trauma than blunt trauma, the former accounting for 90% of gallbladder injuries [3,4]. In greater than 90% of cases, there is other major intra-abdominal injury, most commonly to liver [4,5]. In this case, the mechanism of injury was direct blunt trauma, likely from the pushbike handlebar, force applied directly to the gall bladder through the abdominal wall. Other minor abdominal injuries reported, to the spleen and small bowel could also be attributable to the direct blow by the handle bars or the fall itself.

Being a balloon-like structure, the risk of rupture is related to the wall thickness and filling of the gallbladder. The literature describes that a thin-walled gallbladder is more prone to rupture in blunt trauma than a thick-walled fibrosed gallbladder, and a distended post-prandial gallbladder is also more likely to rupture [6]. In this case however, the patient had a fibrosed gallbladder, and it was likely not distended. Alcohol consumption has also been proposed as a risk factor for gallbladder rupture, through increasing sphincter of Oddi tone thus biliary tract pressure [6], but we do not think it was a factor in this case.

Diagnosis of gallbladder rupture is often missed [6], due to low index of suspicion, variable clinical presentation, and variable

\* Corresponding author at: Royal Melbourne Hospital, 300 Grattan Street, Parkville, 3050, Australia.

E-mail address: [Elizabeth.Lockie@mh.org.au](mailto:Elizabeth.Lockie@mh.org.au) (E.B. Lockie).

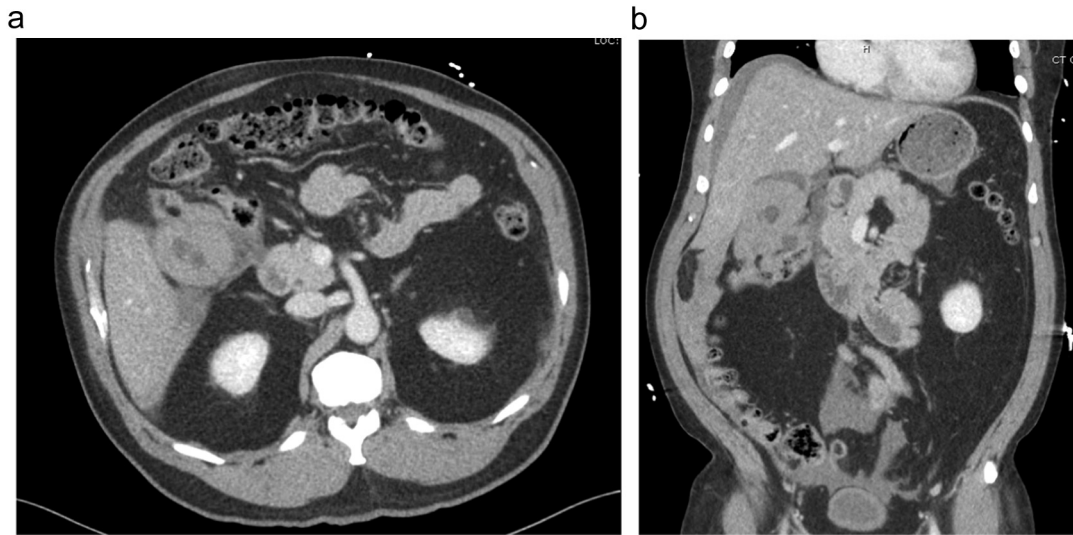


Fig. 1. Computer tomography scan demonstrating haematoma within gallbladder lumen and around gallbladder; (a) Axial slice; (b) Coronal slice.

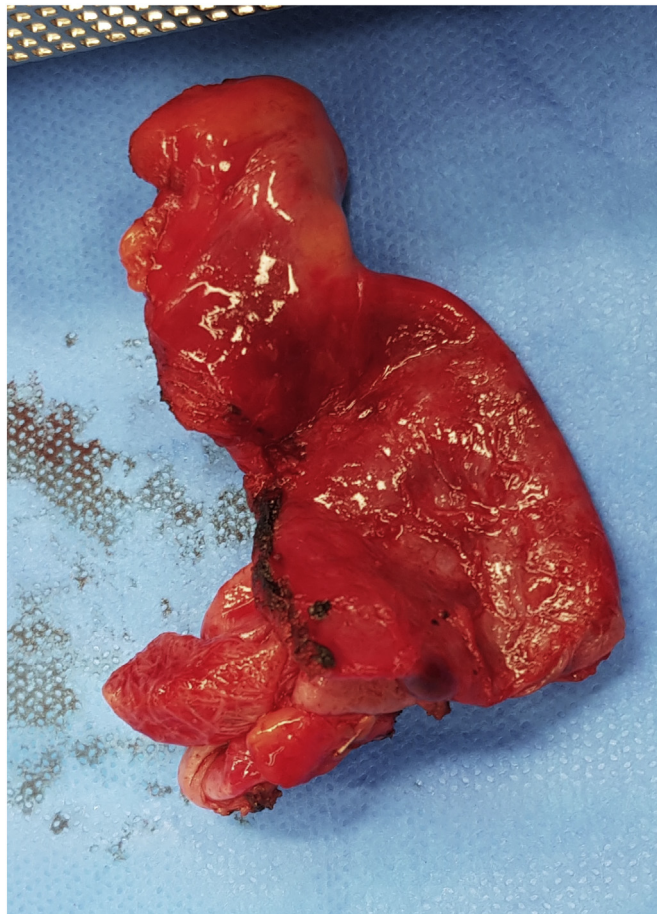


Fig. 2. Resected gallbladder specimen.

imaging findings. The spectrum of contrast-enhanced CT findings includes pericholecystic fluid, ill-defined contour of the gallbladder wall, high density intraluminal material (haemorrhage), active contrast extravasation into the lumen, and gallbladder collapse [7,8]. The addition of delayed post-contrast CT can assist in differentiating traumatic from nontraumatic conditions such as cholelithiasis,

which can mimic intra-luminal haemorrhage, as haemorrhage will show an increase in amount of dense fluid or extravasation on the delayed phase [8]. In this case, diagnosis of gallbladder rupture was made intra-operatively, which is the more common situation. In a retrospective review of 45 patients, diagnosis was made on CT in seven and intra-operatively in the remaining 38 patients [4]. In this case, there were findings suggestive of gallbladder rupture on CT, including haematoma within the gallbladder lumen and surrounding the gallbladder, but these findings were appreciated only by the radiologist, not by the emergency physicians or surgeons. This reflects the difficulty of diagnosis, even by experienced doctors in a trauma centre. Nevertheless, the treatment in this case was not delayed, as decision for trauma laparotomy was made based on the positive abdominal ultrasound scan and haemodynamic instability of the patient. The patient underwent cholecystectomy, the gold standard of management for gallbladder rupture [9].

## Conclusion

This case is a rare example of gallbladder rupture without other major injury following blunt thoracoabdominal trauma, and it illustrates the difficulties in diagnosis of this unusual injury. When managed promptly, the outcome of this injury has a good prognosis.

## Acknowledgements

We acknowledge the patient for giving permission to share his case.

## Declaration of Competing Interest

We declare no competing interests.

## References

- [1] Kaehr D, Jones LM, Miller SF, Finley RK Jr. Traumatic cholecystectomy. *J. Trauma* 1984; 24(6): 544–5.
- [2] E.E. Moore, T.H. Cogbill, M.A. Malangoni, G.J. Jurkovich, S.R. Shackford, H.R. Champion, J.W. McAninch, Organ injury scaling, *Surg. Clin. North Am.* 75 (1995) 293–303.
- [3] R. Zellweger, P.H. Navsaria, F. Hess, J. Omshoro-Jones, D. Kahn, A.J. Nicol, Gall bladder injuries as part of the spectrum of civilian abdominal trauma in South Africa, *ANZ J. Surg.* 75 (7) (2005) 559–561.
- [4] G.B. Ball, E. Dixon, A.W. Kirkpatrick, F.R. Sutherland, K.B. Laupland, D.V. Feliciano, A decade of experience with injuries to the gallbladder, *J. Trauma Manag. Outcomes* 4 (3) (2010).
- [5] O. Sharma, Blunt gallbladder injuries: presentation of twenty-two cases with review of the literature, *J. Trauma* 39 (3) (1995) 576–580.
- [6] C.A. Soderstrom, K. Maekawa, R.W. DuPriest Jr., R.A. Cowley, Gallbladder injuries resulting from blunt abdominal trauma: an experience and review, *Ann. Surg.* 193 (1) (1981) 60–66.
- [7] R.E. Erb, S.E. Mirvis, K. Shanmuganathan, Gallbladder injury secondary to blunt trauma: CT findings, *J. Comput. Assist. Tomogr.* 18 (5) (1994) 778–784.
- [8] A.D. Lyles, J.T. Rexroad, Isolated traumatic gallbladder avulsion: a case report, *Emerg. Radiol.* 17 (5) (2010) 419–421.
- [9] B.N. Thomson, B. Nardino, K. Gumm, A.J. Robertson, B.P. Knowles, N.A. Collier, R. Judson, Management of blunt and penetrating biliary tract trauma, *J. Trauma Acute Care Surg.* 72 (6) (2012) 1620–1625.