


# Nasal mask average volume-assured pressure support in an infant with congenital central hypoventilation syndrome

Vishal Saggi<sup>1,2</sup> , Arthur Teng<sup>1,2</sup>, Ganesh Thambipillay<sup>1,2</sup>, Hugh Allen<sup>1</sup>, Sonia Pithers<sup>1</sup> & Colin Sullivan<sup>1,2,3</sup>

<sup>1</sup>Department of Sleep Medicine, Sydney Children's Hospital, Sydney, New South Wales, Australia.

<sup>2</sup>School of Women and Children's Health, Faculty of Medicine, University of New South Wales, Sydney, New South Wales, Australia.

<sup>3</sup>David Read Laboratory, Discipline of Sleep Medicine, University of Sydney, Sydney, New South Wales, Australia.

## Keywords

Average volume-assured pressure support, congenital central hypoventilation syndrome, infant, transcutaneous carbon dioxide.

## Correspondence

Vishal Saggi, Department of Sleep Medicine, Sydney Children's Hospital, Sydney, NSW 2031, Australia.  
E-mail: vishal.saggi@health.nsw.gov.au

Received: 15 April 2019; Revised: 7 May 2019;

Accepted: 16 May 2019; Associate Editor:

Daniel Ng.

*Respirology Case Reports*, 7 (6), 2019, e00448

doi: 10.1002/rcr2.448

## Abstract

Congenital central hypoventilation syndrome (CCHS) is a rare disorder characterized by alveolar hypoventilation and autonomic dysregulation secondary to mutations of the *PHOX 2B* genes. Treatment consists of assisted ventilation using positive pressure ventilators via tracheostomy, bi-level positive airway pressure (BPAP), negative pressure ventilators, or diaphragm pacing. Previous case reports have highlighted early use of nasal non-invasive BPAP use in infants with CCHS. We present a case of a 10-month-old infant who was successfully managed on a new feature of non-invasive ventilation called average volume assured pressure support (AVAPS) without the need for tracheostomy. The AVAPS feature enables the machine to automatically adjust the inspiratory pressures to deliver a constant targeted tidal volume. This feature enabled a better control of ventilation as indicated by a more stable transcutaneous carbon dioxide profile compared to conventional nasal non-invasive BPAP, making non-invasive ventilation a more accessible method of managing sleep hypoventilation in CCHS.

## Introduction

Congenital central hypoventilation syndrome (CCHS) is a rare disorder characterized by alveolar hypoventilation and autonomic dysregulation due to a gene mutation in the paired-like homeobox 2B gene (*PHOX2B*) [1].

The goal of the treatment is to ensure adequate gas exchange using assisted ventilation during sleep [2]. Assisted ventilation in CCHS patients is provided using positive pressure ventilation mainly done through two approaches: bi-level positive airway pressure (BPAP) via tracheostomy or BPAP administered non-invasively through a mask.

## Case Report

We present the case of a 10-month-old female infant with CCHS with improved gas exchange on the average volume assured pressure support (AVAPS) feature.

The infant was born with a birth weight of 4590 g to healthy parents after an uneventful pregnancy. Hypoxia,

respiratory distress and hypotonia were noted soon after delivery. Her initial capillary blood gas revealed respiratory acidosis with a pH of 7.18, pCO<sub>2</sub> of 90 mmHg. She was placed on nasal mask administered BPAP due to hypercarbia and hypoxemia. Investigations including creatinine kinase, urine metabolic screen, echocardiography, ophthalmology review, thyroid function testing, amplitude integrated encephalography, magnetic resonance imaging brain, comparative genomic hybridization array and spinal muscular atrophy gene testing were all normal. A nasoendoscopy showed mild laryngomalacia. In view of unexplained hypercarbia, a *PHOX2B* gene testing was requested. A polysomnography was scheduled during the hospital admission to better study her gas exchange and investigate the cause for hypercarbia.

The initial study at 1 month of age was commenced off pressure support and showed multiple central apnoeas (29.2/h). In addition, there were six obstructive events per hour. Transcutaneous carbon dioxide (TcCO<sub>2</sub>) ranged

from 37 to 54 mmHg. Continuous positive airway pressure (CPAP) was considered a suitable option and commenced using a Maskmedic (Sydney, Australia) mask interface in view of both central and obstructive events. Five days later, a CPAP titration study was organized. CPAP was commenced at 5 cm H<sub>2</sub>O at the start of the study; however, due to rise in TcCO<sub>2</sub>, BPAP was commenced midway through the study. At inspiratory positive airway pressure (IPAP) of 11 cm H<sub>2</sub>O, expiratory positive airway pressure (EPAP) of 4 cm H<sub>2</sub>O, back up rate 27/min, and inspiratory time of 1 s in the ST mode, ventilation was well controlled, and there were no central or obstructive events. The patient was discharged home on the above settings to be used only during sleep. In the meanwhile, DNA analysis revealed that she carried a 25-repeat polyalanine expansion mutation of the *PHOX 2B* gene.

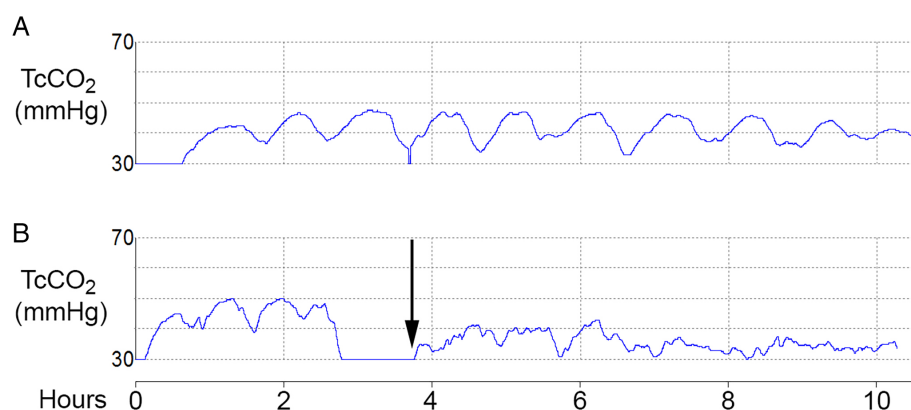
Patient was reviewed in our airway pressure support clinic and was thriving and achieving developmental milestones.

To ensure adequate ventilation, a repeat sleep study was organized at 6 months. While oxyhaemoglobin saturation was well maintained, there was a cyclic pattern of TcCO<sub>2</sub> through the night showed varying by 10 mmHg from 35 to 45 mmHg (Fig. 1). In view of high TcCO<sub>2</sub> variability, a decision was made to trial her on the AVAPS feature which combines both the pressure and volume characteristics of ventilation and delivers a range of inspiratory pressures to guarantee a prefixed inspiratory tidal volume and a more stable level of minute ventilation. The study was performed four weeks after the previous study on conventional BPAP. During the AVAPS titration study, the IPAP ranged from IPAP maximum of 14 cm H<sub>2</sub>O and IPAP

minimum of 10 cm H<sub>2</sub>O to ensure a set tidal volume of 80 mL with a breath rate of 21/min. EPAP was set at 4 cm H<sub>2</sub>O. The inspiratory time was 1.3 s, trigger type autotrak sensitive, AVAPS rate 5 cm per minute on PC mode. Adequate tidal volume was calculated at 9 mL/kg. AVAPS was provided using a Philips Respironics Trilogy 100 (Philips, Murrsville, Pa.) as the machine can deliver small tidal volumes. The initial part of the study on conventional BPAP recorded a total sleep time of 140 min. The second part of the study on AVAPS recorded a total sleep time of 334 min. Sleep efficiency was better on BPAP (80%) compared to AVAPS (75%). There was no apnoea recorded on either BPAP mode or AVAPS feature. Average oxygen saturation was well maintained in the BPAP (97%) and the AVAPS (98%) part of the study. The TcCO<sub>2</sub> fluctuation improved significantly on the above AVAPS settings (Fig. 1).

## Discussion

Some centres prefer non-invasive BPAP only in stable older children who require ventilatory support during sleep. However, at our centre, we approach the issue of ventilatory support on a case by case basis. The challenges of using non-invasive BPAP in the very young infants with CCHS, such as in our case, include finding appropriate interfaces, ensuring proper parental education and awareness of prompt institution of BPAP during daytime naps and the overnight sleep, and prevention of mid-facial hypoplasia from mask use. Achieving a stable level of ventilation during sleep in CCHS when using either non-invasive or invasive (tracheostomy) is also a challenge



**Figure 1.** Transcutaneous carbon dioxide (TcCO<sub>2</sub>) on conventional bi-level positive airway pressure (BPAP) and average volume assured pressure support (AVAPS). (A) TcCO<sub>2</sub> trace on polysomnography using conventional nasal BPAP. Note the highly regular slow oscillation of TcCO<sub>2</sub> of 10 mmHg varying between 35 and 45 mmHg. While the mechanism of this periodicity is uncertain, it may reflect slow oscillations in breathing control induced by the BPAP settings or by slower changes in acid-base levels revealed in the absence of usual chemoreceptor control. (B) TcCO<sub>2</sub> trace on polysomnography. Arrow indicates change from conventional nasal BPAP to nasal BPAP with AVAPS feature. Note the more consistent control of TcCO<sub>2</sub>.

because of changes in the patient's level of spontaneous drive to breathe during arousals and wake, and additional differences in drive in different sleep states.

Our case did not demonstrate discrete obstructive or central events on BPAP. The highly regular but slow oscillations (1 h) in  $TcCO_2$  seen in this patient on BPAP possibly indicates the presence of slow feedback control of breathing from a non-chemoreceptor source (e.g. slow changes in acid-base cerebrospinal fluid levels) or may reflect changes in wake/sleep during the night of ventilatory assistance. The use of the AVAPS feature readily enabled a stable overnight ventilation.

CCHS is characterized by reduced physiological response to elevated carbon dioxide, especially in non-rapid eye movement (NREM) sleep. BPAP with fixed-level pressure support delivery is less adaptive to changes in respiratory mechanics during different sleep stages. Because the hypoventilation is much worse in NREM, BPAP with fixed pressure support may provide too much pressure in rapid eye movement, leading to inconsistent ventilation. Furthermore, children with CCHS characteristically have diminished tidal volume when asleep. BPAP with fixed pressure does not compensate for changes in tidal volume. On the other hand, BPAP with AVAPS allows the system output to automatically adjust inspiratory pressure to ensure delivery of a constant target tidal volume resulting in better  $CO_2$  control as compared to BPAP.

The use of AVAPS for CCHS has been described in a 16-year-old child who successfully transitioned from tracheostomy to conventional non-invasive BPAP [3]. Intelligent volume-assured pressure support (iVAPS) (ResMed Ltd, Bella Vista, Australia) is a similar feature to AVAPS. A case series of eight older children (age 9.1–12.5 years) with CCHS showed that it was more effective in reducing maximum  $TcCO_2$  compared to conventional BPAP [4].

A previous case report successfully used AVAPS feature in a child to achieve effective non-invasive ventilation [5]. The minimum tidal volume threshold of 50 mL and high trigger sensitivity limits the use of AVAPS in younger infants. Data from randomized control trial in children on use of AVAPS are lacking.

In summary, our case reports the successful use of the AVAPS feature in an infant with CCHS. This case highlights that the AVAPS feature may be a reliable alternative to tracheostomy and conventional non-invasive BPAP in infants with CCHS. Prospective, longitudinal studies are needed to evaluate the benefits of BPAP AVAPS feature for the treatment of CCHS.

### Disclosure Statement

Appropriate written informed consent was obtained for publication of this case report and accompanying images.

### Acknowledgments

We are grateful to Dr Mark Norman, Research Unit Manager, The University of Sydney, for assistance in preparing the figure.

### References

1. Zaidi S, Gandhi J, Vatsia S, et al. 2018. Congenital central hypoventilation syndrome: an overview of etiopathogenesis, associated pathologies, clinical presentation, and management. *Auton. Neurosci.* 210:1–9.
2. Weese-Mayer DE, Berry-Kravis EM, Ceccherini I, et al. 2010. An official ATS clinical policy statement: congenital central hypoventilation syndrome: genetic basis, diagnosis, and management. *Am. J. Respir. Crit. Care Med.* 181:626–644.
3. Vagiakis E, Koutsourelakis I, Perraki E, et al. 2010. Average volume-assured pressure support in a 16-year-old girl with congenital central hypoventilation syndrome. *J. Clin. Sleep Med.* 6:609–612.
4. Khayat A, Medin D, Syed F, et al. 2017. Intelligent volume-assured pressured support (iVAPS) for the treatment of congenital central hypoventilation syndrome. *Sleep Breath.* 21: 513–519.
5. Gentin N, Williamson B, Thambipillay G, et al. 2015. Nocturnal respiratory failure in a child with congenital myopathy – management using average volume-assured pressure support (AVAPS). *Respirol. Case Rep.* 3:115–117.