



Functional medicine

A rare case report - Ovary attached to testicle inside hernia sac

Halit Maloku^a, Ragip Shabani^b, Naim Haliti^c, Nora Shabani^d, Qenan Maxhuni^e, Rrahman Ferizi^{f,*}^a University of Prishtina, Faculty of Medicine, Department of Surgery, Prishtina, Kosovo, 10000, Albania^b University of Prishtina, Faculty of Medicine, Department of Pathology Anatomy, Prishtina, Kosovo, 10000, Albania^c University of Prishtina, Faculty of Medicine, Department of Forensic Medicine, Prishtina, Kosovo, 10000, Albania^d Johannes Westling Klinikum Minden, Universitatlinikum Der Ruhr-Universitat Bochum, Minden, 32425, Germany^e Heimerer College, Laboratory Technician Programme, Veranda D4, Kalabri, Prishtina, Kosovo, 10000, Albania^f University of Prishtina, Faculty of Medicine, Premedical Department, Prishtina, Kosovo, 10000, Albania

ARTICLE INFO

Keywords:

Ovary
Testicle
Uterus
Cervix
Mullerian duct syndrome
Hernia sac

ABSTRACT

We report the case of a 67-year-old man, father of 3 children with left indirect inguinal hernia containing uterus with cervix, fallopian tube and an ovary attached to the testicle, also spread ovarian tissue and right congenital cryptorchidism. Coincidentally detected during an operation for left inguinal hernia. Persistent Mullerian duct syndrome is a rare form of male pseudo-hermaphroditism detected coincidentally during surgical operation on cryptorchidism or inguinal hernia.

Introduction

Persistent Mullerian duct syndrome - PMDS is a rare form of male pseudo-hermaphroditism characterized by the presence of the uterus, fallopian tube and ovary caused by persistent Mullerian duct structures in a phenotypically, as well as genotypically normal man.¹

Persistent Mullerian duct syndrome manifested by the presence structure ovaries at a male with 46XY genotype.² The lack of necessary amount of anti-Mullerian hormone or the hormone receptors insensitivity generate the syndrome.³

Pre-operative ultrasonography, computerized tomography and MRI allow diagnosing and pre-operative case management. Approximately 150–200 cases are reported in literature.⁴

Case presentation

A 67-year-old man presented in our hospital with a unilateral left inguinal swelling for 10 years and right side cryptorchidism since birth. The swelling increased during upright standing, coughing and abdominal tension, but would decrease in size during supine position.

The patient had primary and secondary sexual normal characteristics. He was married and had 3 kids. Physical examination presented a

male with average male osteo-muscular and pilosity, well developed penis with urethral opening in glans penis.

A partly repairable swelling measuring 15 × 10 cm was detected in left scrotal sac. The right scrotum contained atrophied scrotal sac lacking the testicle even in inguinal canal. The left testicle was palpable and visible in scrotum.

Patient went through preoperative preparation and procedures including laboratory tests, necessary specialists consulting as well as written surgery consent form. As the inguinal canal was opened sigma was found in hernia sac, afterwards a pear like structure measuring 5x4x2.5 cm resembling to uterus was found, scrotal sac measuring 3.4x2.4 × 1.8 cm contained fallopian tube 8 × 0.6 cm and a testicle. In the abdominal wall of the same side a testicle measuring 2.5x1.5 × 1.5 cm attached to four connected formations was found, formations did not resemble macroscopically to normal ovary. The found structure was well attached to testicle and epididymis resembling to a tumor (Fig. 1 a).

Preparation of connected formation to the testicle started, but the connection was as strong and resembled as if even tunica albuginea is changed.

Orchiectomy was performed by removing the atrophic testicle, also the total removal of the uterus and fallopian tubes together with four tumor formations and the surgery ended with Lichtenstein inguinal

* Corresponding author. University of Prishtina, Premedical Department, Faculty of Medicine Prishtina, Kosovo, 10000, Albania.

E-mail addresses: dr_hmaloku@hotmail.com (H. Maloku), ragip.shabani@uni-pr.edu (R. Shabani), naim.haliti@uni-pr.edu (N. Haliti), shbnora2020@gmail.com (N. Shabani), qenan.maxhuni@kolegji-heimerer.eu (Q. Maxhuni), rrahman.ferizi@uni-pr.edu (R. Ferizi).

<https://doi.org/10.1016/j.eucr.2021.101673>

Received 13 March 2021; Accepted 29 March 2021

Available online 3 April 2021

2214-4420/© 2021 The Authors.

Published by Elsevier Inc.

This is an open access article under the CC BY-NC-ND license

(<http://creativecommons.org/licenses/by-nc-nd/4.0/>).

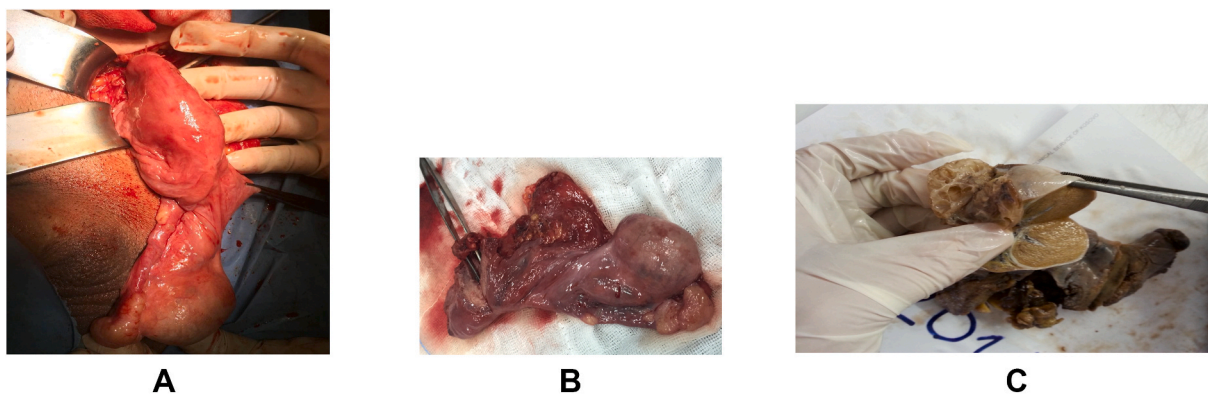


Fig. 1. a) Testicle, uterus, falopian tubes, ovary
 b) Testicle uterus and four structures close to testis, the first one is attached to the testis the second one connected to epididymis and two others standing free
 c) Testis attached to polycystic ovary.

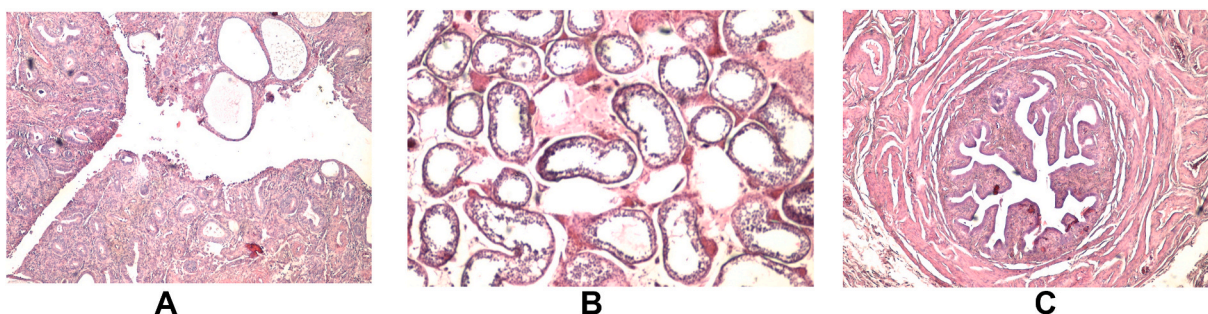


Fig. 2. a) Uterus and endometrium
 b) Tube and epididymis
 c) Testicle.

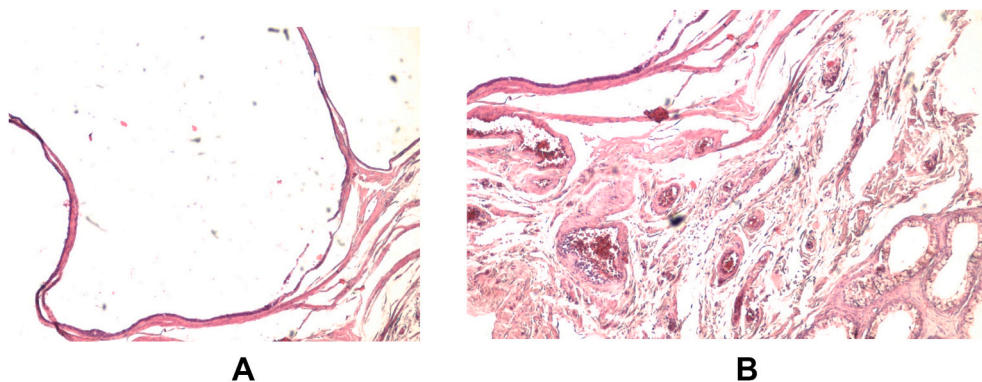


Fig. 3. a) Polycystic ovary
 b) Ovary attached to testicle.

hernioplasty.

The pear-shaped uterus was macroscopically detected, it contained well preserved cavity and cervix measuring 5x4x2.5 cm, also secreted clear mucosal discharge, and fallopian tubes were well differentiated and measuring 8x0.6 cm.

The testicle measuring 2.5 x1.8 x1.5 was attached to a tumor structure and three other similar structures in between (Fig. 1 a, b, c).

The endometrial is composed of rich cellular layer consisting regular endometrial glands, some of them are dilated and covered in cylindrical pseudo stratified epithelium (Fig. 2 a).

Intact uterine tubes (Fig. 2 b).

Regular testicular structure (Fig. 2 c).

Ovary with cystic formations of different sizes, covered with layers of atypical, stratified cells. (Fig. 3 a).

Testis to ovary attachment (Fig. 3 b).

Chromosome and karyotype testing could not be performed in our country, but it would be interesting to realize this analysis in the future in eventuality of similar cases.

Discussion

PMDS is a rare pseudo hermaphrodite syndrome with persistent Mullerian ducts in male patient. The cause of this syndrome is not completely clear, but it is supposed to be caused by a defect on synthesis

and secretion of MIF or a defect on MIF receptors.

In human fetus Mullerian and Wolffian ducts are present during the 7 first weeks of pregnancy. In the male fetus the testicle is differentiated by the end of 7 gestational week. Normal sex differentiation is regulated by testosterone, dihydrotestosterone and MIF.

First category, male type where in the scrotum or the inguinal canal of the same side you find a testicle, uterus, fallopian tube and ovary.

Second category describes testicular transversal ectopy (TTE), which is characterized with the herniation of both testes, with a whole uterus and both fallopian tubes on the same side of the scrotum or inguinal canal.

Third category type female is characterized by bilateral cryptorchidism, the testes are in the ovarian position connected to the uterus, which is fixed on the pelvis.

On our case we have type two, where the testes, uterus, fallopian tubes and ovaries are found in the scrotum sack also the intra abdominal testes are found near the inner annulus of the inguinal canal.

A collection of literature shows that in patients with intra-abdominal testes, both gonads are found in analogous position with the ovaries, with a rudimentary uterus at the center where the remains of the Muller ducts inhibit the mobilization of the testes to the scrotum.⁵

In the ovarian positioned intra abdominal testes cases, the division of Muller remains from the testis and vascular structures in order to enable the elongation for the desired orchidopexy is difficult and with high risk of testicular vascularization disorders, especially when the ducts are not properly separated.

In PMDS, the testes are usually histological normal, despite the duration of cryptorchidism.

Conclusion

Persistent Mullerian duct syndrome is a rare form of male pseudo-

hermaphroditism detected coincidentally during surgical operation on cryptorchidism or inguinal hernia. Ovarian tissue is well attached to the testis and epididymis, also located in other places resembling to a tumor of these structures. Vascular and tubular structures often are not well detached from uterus and cervix. In these cases, it is better not to perform hysterectomy in order to avoid the damage of vascularization of testis and ductus.

In case if uterus remains in abdominal cavity there is no increased risk of pathological changes.

Ethics

Informed consent from the patient.

Declaration of competing interest

The authors have no conflict of interest to reveal.

References

1. Sherwani AY, Shah AQ, Wani AM, et al. Hysterectomy in a male? A rare case report. *Int. J.Surg.Case Rep.* 2014;5(12):1285–1287. Jan 1.
2. Kravarusic D, Segulier-Lipszyc E, Feigin E, Nimri R, Nagelberg N, Freud E. Androgen insensitivity syndrome: risk of malignancy and timing of surgery in a paediatric and adolescent population. *Afr J Paediatr Surg.* 2011;8(2):194. May 1.
3. Khattala K, Bouabdallah Y. Homme à utérus ou syndrome de la persistance des canaux de Müller (PMDS). *The Pan African Med J.* 2012;13.
4. Prakash N, Khurana A, Narula B. Persistent Müllerian duct syndrome. *Indian J Pathol Microbiol.* 2009;52(4):546. Oct, 1.
5. Pettersson G, Bonnier G. Inherited sex-mosaic in man. *Hereditas.* 1937;23(1-2):49–69. Mar.