



Grade III subcapsular liver hematoma secondary to HELLP syndrome: A case report of conservative management

Daniel Bradke^a, Ashley Tran^b, Tatiana Ambarus^a, Munir Nazir^a, Maryann Markowski^a, Alexander Juusela^{a,*}

^a Department of Obstetrics and Gynecology, RWJ Barnabas Health, Newark Beth Israel Medical Center, Newark, New Jersey, United States of America

^b Rutgers's University New Jersey Medical School, Newark, New Jersey, United States of America

ARTICLE INFO

Article history:

Received 19 November 2019

Received in revised form 8 December 2019

Accepted 9 December 2019

Keywords:

Pregnancy
Preeclampsia
HELLP syndrome
Subcapsular hematoma
Maternal mortality

ABSTRACT

Subcapsular liver hematoma (SLH) is a rare condition that is associated with preeclampsia and HELLP (hemolysis, elevated liver enzymes, and low platelets) syndrome. A high level of suspicion, early diagnosis, and coordinated, intensive multidisciplinary management are necessary to monitor for serious complications and prevent death. Options include conservative management, hepatic resection, hepatic artery ligation and liver transplantation. This paper describes a 34-year-old woman with HELLP syndrome who developed a large grade III SLH that was managed conservatively.

© 2019 Published by Elsevier B.V. This is an open access article under the CC BY-NC-ND license (<http://creativecommons.org/licenses/by-nc-nd/4.0/>).

1. Introduction

Subcapsular liver hematoma (SLH) is spontaneous bleeding between the Glisson's capsule and the liver parenchyma. It occurs in approximately 2% of pregnancies complicated by HELLP (hemolysis, elevated liver enzymes, and low platelets) syndrome. Unrecognized SLH can have devastating consequences, one of the worst complications being hepatic rupture, which has a significant mortality rate. Due to the acute and critical nature of SLH, even with aggressive medical and/or surgical interventions the outcome can be devastating.

2. Case Report

A 34-year-old woman, gravida 2, para 0, at 37 weeks of gestation presented to the labor and delivery department for evaluation of new-onset hypertension in pregnancy with a blood pressure (BP) of 140/92 mmHg. On initial presentation, the patient had no symptoms of preeclampsia but was noted to have hyperreflexia (3+ deep-tendon reflexes) on physical exam. Laboratory findings were significant for 2+ proteinuria, a platelet count (PLT) of $122 \times 10^3/\text{mCL}$, an aspartate aminotransaminase (AST) level of 116 U/L, alanine aminotransaminase (ALT) level of 162 U/L and lactate dehydrogenase (LDH) level of 300 U/L. Based on the laboratory findings, in conjunction with the physical exam, and elevated BP, the diagnosis of HELLP syndrome was made. HELLP

syndrome is associated with adverse pregnancy outcomes; therefore the decision was made to induce labor. The patient was started on magnesium sulfate for seizure prophylaxis and induction was started using vaginal misoprostol for cervical ripening.

During the induction process, serial samples were drawn for laboratory analysis. AST trended upwards to a maximum of 3110 U/L, ALT to 2607 U/L, LDH to 2991 U/L, and platelets fell to $58 \times 10^3/\text{mCL}$ (Table 1). The patient progressed appropriately, leading to an uncomplicated vaginal delivery of a viable male infant with APGAR scores of 8 and 9. Within hours of delivery, the patient had an abrupt onset of pain in the right upper quadrant, which proved to be persistent. Physical exam revealed a tender right upper quadrant with rebound and a liver edge beyond the costal margin. A subcapsular liver hematoma was suspected and confirmed on abdominal ultrasound (Fig. 1). A computerized tomography (CT) angiogram was performed with liver mass protocol, which demonstrated a $16 \times 6 \times 22$ cm subcapsular liver hematoma without evidence of active extravasation (Fig. 2). A multidisciplinary consultation was rapidly convened that included obstetrics, maternal-fetal medicine, general surgery, radiology, intensive care, and hematology. The decision was made to transfer the patient to the intensive-care unit (ICU) for conservative management, blood product repletion, and monitoring.

Once in the ICU, the patient underwent close continuous monitoring and serial abdominal exams were performed. The patient was transfused a total of 5 units of packed red blood cells (PRBC) and 2 units of platelets. Laboratory results remained stable. A repeat CT scan on postpartum day 1 showed a stable hematoma (Fig. 3). Pain was managed initially with patient-controlled intravenous hydromorphone, and

* Corresponding author at: OB/GYN Department, Newark Beth Israel Medical Center, 201 Lyons Ave, Newark, NJ 07112, United States of America.

E-mail address: alexander.juusela@rwjbh.org (A. Juusela).

Table 1
Laboratory values.

	Prior to induction	T+ 7.5 h	T+ 12 h	Delivery +2 h	Delivery +6 h	Delivery +14 h	Postpartum day 1	Postpartum day 2	Postpartum day 3
Leukocytes (4.5–11.0 × 10 ³ /mCL)	11.4	15.1	11.5	12.3	12.4	14.4	15.4	13.5	13.6
Hemoglobin (12.0–15.0 g/dL)	12.2	8.2	9.4	8.9	9.1	8.9	8.5	7.8	8.7
Hematocrit (35.0–45.0%)	35.3	23.1	26.9	25.8	25.8	25.8	24.7	22.1	24.9
Platelet (150–450 × 10 ³ /mCL)	79	70	58	85	85	98	117	136	203
PT (9.8–11.7 Seconds)	9.4	9.9	10.3	9.8	9.7	9.5	9.6	9.5	10.5
INR (0.9–1.1)	0.9	0.9	1	0.9	0.9	0.9	0.9	0.9	1
PTT (24.3–30.4 Seconds)	23.2	21.3	22.9	23.3	23.3	23.3	23.7	25	24.4
Fibrinogen (210–400 mg/dL)	520	399	341	367	314	385	424	546	–
Glucose (90–110 mg/dL)	110	96	91	91	84	78	87	90	122
BUN (6.0–23.0 mg/dL)	12	23	22	18	16	12	11	11	8
Creatinine (0.60–1.30 mg/dL)	0.48	0.63	0.52	0.46	0.43	0.4	0.35	0.38	0.38
Uric Acid (2.6–7.4 mg/dL)	6.3	8.8	8.4	7.7	6.9	6.4	–	4.5	–
Urine Protein (0–10.0 mg/dL)	117.1	75.4	–	47.8	–	–	–	–	–
Urine Creatinine (mg/dL)	151.2	184.6	–	109.2	–	–	–	–	–
ALT (6–52 Unit/L)	332	2444	2607	2445	2186	1962	1464	932	580
AST (15–40 Unit/L)	327	2615	3110	2606	2262	1739	762	289	110
LDH (95–230 Unit/L)	513	3028	3223	2438	2055	1399	551	356	–
ALP (46–116 Unit/L)	172	159	162	155	158	160	152	147	142

then switched to oral hydromorphone and cyclobenzaprine. The patient improved clinically and was eventually downgraded to the postpartum unit. A repeat CT scan on postpartum day 8 showed that the hematoma had decreased in size (Fig. 4) and laboratory values were noted as ALT 207 U/L, AST 81 U/L, LDH 1132 U/L, and PLT 464 × 10³/mCL. Marked improvement continued and the patient was discharged home on postpartum day 10. The patient then proceeded to a full recovery with resolved transaminitis. Long-term follow-up was with gastroenterology and a CT scan 2 months after delivery showed interval organization of the hematoma; otherwise, the CT scan of the liver was grossly normal (Fig. 5).

3. Discussion

Subcapsular liver hematoma (SLH) is a rare but potentially fatal complication of HELLP syndrome, occurring in about 1–2% of all patients with preeclampsia and HELLP syndrome [1,2]. The pathogenesis of SLH in HELLP syndrome is not well understood but may involve fibrin deposition leading to platelet activation, thrombus formation, and occlusion of capillaries, which ultimately progresses to hepatic necrosis and

hemorrhage [2,3]. The most concerning potential complication of SLH is hepatic rupture, which may occur in the setting of trauma, such as abdominal palpation, manual removal of the placenta, and uterine contractions [1]. Hepatic rupture due to SLH most commonly involves the right lobe of the liver [2]. Maternal mortality of SLH ranges from 17% to 59%, depending on rupture of the hematoma, timing of diagnosis, and availability of therapeutic interventions [2].

The signs and symptoms of SLH are nonspecific. They include hemodynamic instability and sudden-onset pain in the right upper quadrant or epigastric pain, severe pain in the right shoulder, and/or nausea and vomiting due to distention of the hepatic parenchyma and Glisson's capsule [2,4]. In the case of hepatic rupture, abdominal distension due to hemoperitoneum and hypovolemic shock may be seen [2]. The clinical presentation of SLH may be confused with the usual pain in the right upper quadrant seen in preeclampsia, other intra-abdominal pathology such as cholecystitis, or even pulmonary embolism [2].

As with this case, early suspicion for SLH should lead to prompt evaluation and diagnosis. The choice of imaging studies should be based on availability and how quickly they can be performed. Therefore, portable ultrasound is a good screening tool as it is the quickest and can be

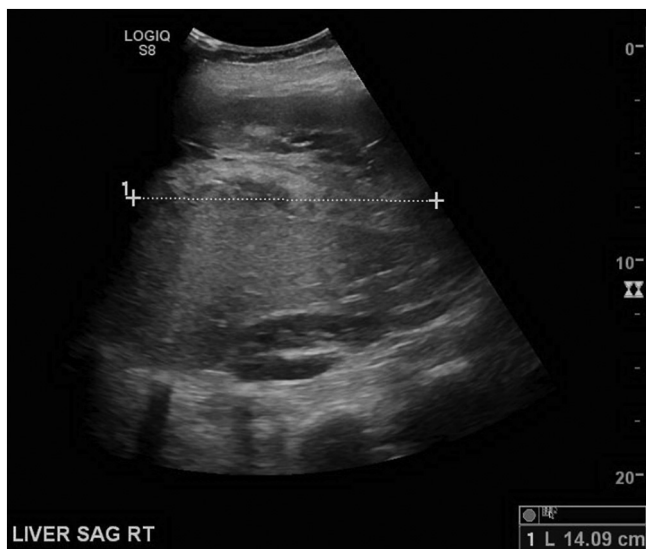

Fig. 1. Ultrasound scan of the right upper quadrant.

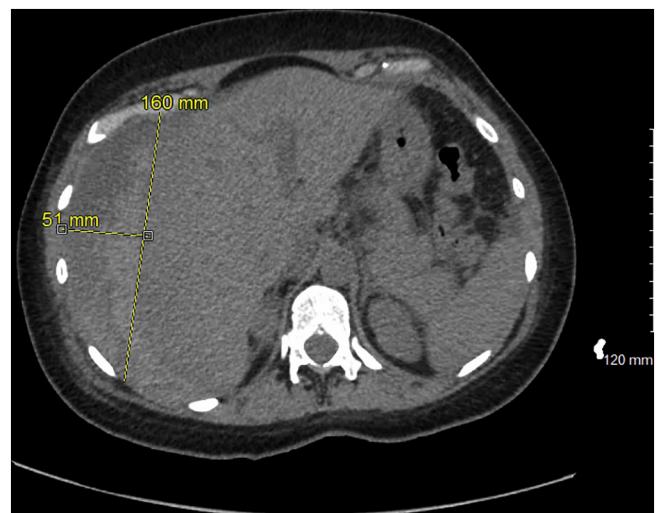

Fig. 2. Computerized tomography angiogram, postpartum day 0.

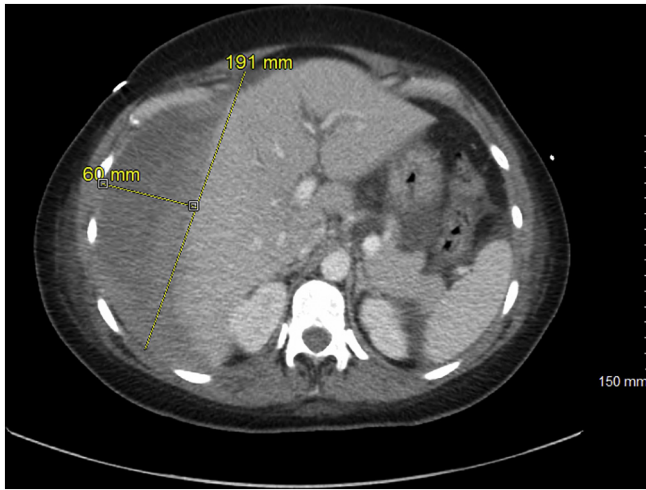


Fig. 3. Computerized tomography scan with intravenous contrast, postpartum day 1.

performed at the bedside [2,5] and a FAST (focused abdominal ultrasound for trauma) exam should be the main imaging modality in unstable patients. CT and magnetic resonance imaging (MRI) are both highly sensitive for the detection and evaluation of SLH [3]. However, as CT is more readily available and takes less time to complete, it is more appropriate in emergency cases where patients are becoming hemodynamically unstable [6]. In the case presented, abdominal ultrasound was used to establish the diagnosis of SLH while CT angiogram was used to confirm the diagnosis and further describe the extent of the hematoma. MRI should be reserved for non-emergency case or for pregnant patients [2].

In order to classify injuries and help guide management, the American Association for the Surgery of Trauma (AAST) created a classification system that grades the extent of injury from grade I to grade VI (Table 2). As hepatic hematomas from HELLP syndrome are rare, critical care management can be guided using the AAST classification. In data published by the National Trauma Data Bank (NTDB), approximately 67% of hepatic injuries were between grade I and grade III [8]. Hemodynamically stable patients with low-grade injuries (I, II, III) were able to be successfully managed without surgical intervention [8]. For patients with grade IV and V injuries, non-surgical management was less successful, and patients with grade VI trauma (hepatic avulsion) were

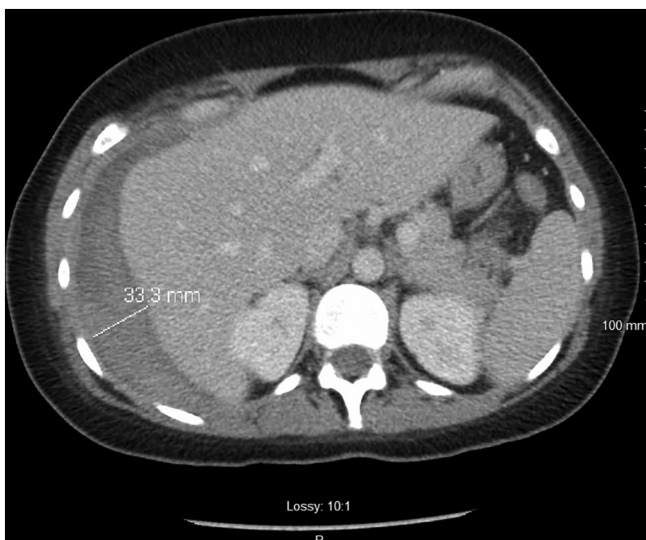

Fig. 4. Computerized tomography scan with intravenous contrast, postpartum day 8.

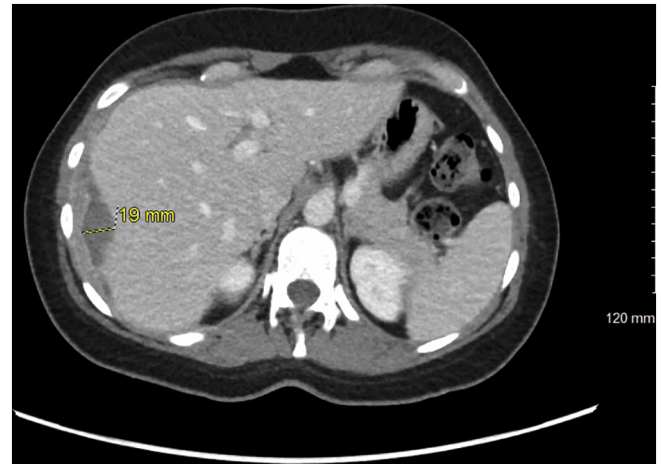

Fig. 5. Computerized tomography scan with intravenous contrast, 2 months postpartum.

universally unstable and required surgical intervention [8]. Our patient had a hematoma that was >10 cm intraparenchymal and therefore categorized as grade III. Similar to the published trauma literature, our patient's grade III hematoma responded to non-surgical management.

Multiple case reports stress that the management of patients with SLH should be at tertiary centers, in order for timely recognition and for treatment to have an optimal outcome [7]. Traditionally, first-line treatment for SLH has been surgical management. Patients with hepatic rupture and unstable patients are managed with immediate exploratory laparotomy and transfusion of blood products [5]. Surgical options for stabilization of patients with a ruptured hematoma include perihepatic packing and drainage of the surgical site, ligation of the appropriate branch of the portal vein or hepatic artery, patching of the omentum and partial liver resection [2,12]. Liver transplant should be considered in patients with refractory hepatic hemorrhage or with rapidly progressing fulminant liver failure [12]. However, in non-bleeding, hemodynamically stable patients with SLH, as was the case with our patient, non-operative, conservative management is the preferred approach [2,9].

While no specific guidelines exist to aid in clinical decision-making, the AAST scoring system is a useful tool in deciding between surgical and non-surgical management in hemodynamically stable patients. Conservative management has been shown to be successful in treating non-ruptured hematomas and should be advocated in these cases to

Table 2

AAST liver injury scale.

Source: Moore et al. Organ injury scaline: spleen and liver (1994 revision). Journal of Trauma-Injury Infection & Critical Car. 38(3):323–4, 1995 March.

Grade ^a	Type of injury	Description of injury
I	Hematoma	Subcapsular, <10% Surface Area
	Laceration	Capsular tear, <1 cm. Parenchymal Depth
II	Hematoma	Subcapsular, 10% to 50% of Surface Area Intraparenchymal <10 cm in Diameter
	Laceration	Capsular Tear 1–3 Parenchymal Depth, <10 cm in Length
III	Hematoma	Subcapsular, >50% Surface Area of Ruptured Subcapsular or Parenchymal Hematoma Intraparenchymal Hematoma >10 cm or Expanding
	Laceration	>3 cm Parenchymal Depth
IV	Laceration	Parenchymal Disruption Involving 25% to 75% Hepatic Lobe or 1–3 Couinaud's Segments
V	Laceration	Parenchymal Disruption Involving >75% of Hepatic Lobe or > 3 Couinaud's Segments Within a Single Lobe
	Vascular	Juxtahepatic Venous Injuries. Ex: Retrohepatic Vena Cava or Central Major Hepatic Veins
VI	Vascular	Hepatic Avulsion

^a For Multiple Injuries, Advance One Grade up to Grade III.

avoid unnecessary liver trauma, which could lead to rupture and catastrophic bleeding [2,9,13]. This involves intensive care with infusion of fluid, transfusion of blood products when necessary, correction of coagulopathy, and serial imaging with ultrasound or CT to monitor the size of the SLH [10]. Percutaneous transcatheter hepatic artery embolization by interventional radiology has also been shown to be a successful alternative to control hemorrhage [2,11]. Surgical evaluation is necessary if the hematoma increases in size or the condition of the patient deteriorates. While complete resolution of the hematoma can take several months, if the patient's condition and the size of the hematoma remain stable, the patient can be discharged and followed up as an outpatient [2]. As SLH due to HELLP is a rare condition, long-term outcome data are limited to case reports or are extrapolated from trauma surgery and critical care medicine. At this time, long-term outcomes appear to depend on the liver injury grade, amount of or lack of hepatic necrosis and/or fibrosis, and the existence of patient co-morbidities.

In conclusion, SLH is a rare complication of HELLP syndrome but should be considered due to the risk of hepatic rupture. Early recognition and treatment are crucial to optimizing patient outcomes. While surgical management has traditionally been the first-line treatment for SLH, conservative management with a multidisciplinary team that includes critical care, surgery, hematology, and gastroenterology should be considered in hemodynamically stable patients with AAST grade I, II and III hematomas, such as the patient presented in this report.

Contributors

Daniel Bradke contributed to the conception and design of the study, acquisition of data, analysis and interpretation of data, and drafting or revision of the article.

Ashley Tran contributed to the conception and design of the study, acquisition of data, analysis and interpretation of data, and drafting or revision of the article.

Tatiana Ambarus contributed to the conception and design of the study, acquisition of data, analysis and interpretation of data.

Munir Nazir contributed to the conception and design of the study, acquisition of data, analysis and interpretation of data.

Maryann Markowski contributed to the conception and design of the study, acquisition of data, analysis and interpretation of data.

Alexander Juusela contributed to the conception and design of the study, acquisition of data, analysis and interpretation of data, and drafting or revision of the article.

Conflict of Interest

The authors declare that they have no conflict of interest regarding the publication of this case report.

Funding

No funding from an external source supported the publication of this case report.

Patient Consent

Written patient consent was obtained.

Provenance and Peer Review

This case report was peer reviewed.

References

- [1] A. Karateke, D. Silfeler, F. Karateke, R. Kurt, A. Guler, I. Kartal, HELLP syndrome complicated by subcapsular hematoma of liver: a case report and review of the literature, *Case Rep. Obstet. Gynecol.* 2014 (2014) 1–3, <https://doi.org/10.1155/2014/585672>.
- [2] A. Ditisheim, B.M. Sibai, Diagnosis and management of HELLP syndrome complicated by liver hematoma, *Clin. Obstet. Gynecol.* 60 (1) (2017) 190–197, <https://doi.org/10.1097/grf.0000000000000253>.
- [3] M.C. Marinaş, G. Mogoş, R.C. Drăguşin, Ş. Tudorache, D.G. Iliescu, Postpartum Spontaneous Subcapsular Hepatic Hematoma (SSHH)- conservative management. Case report and review of literature, *Curr. Health Sci. J.* 44 (4) (2018) 387–391, <https://doi.org/10.12865/CHSJ.44.04.11>.
- [4] M. Ghorbanpour, H.R. Makarchian, B. Yousefi, M. Taghipour, Conservative Management of Postpartum HELLP syndrome and Intraparenchymal liver hematoma; a case report, *Bull. Emerg. Trauma* 7 (2) (2019) 196–198, <https://doi.org/10.29252/beat-070218>.
- [5] A. Troja, A. Abdou, C. Rapp, S. Wienand, E. Malik, H.R. Raab, Management of Spontaneous Hepatic Rupture on top of HELLP syndrome: case report and review of the literature, *Viszeralmedizin* 31 (3) (2015) 205–208, <https://doi.org/10.1159/000376601>.
- [6] T.I. Kanonge, F. Chamunyonga, N. Zakazaka, C. Chidakwa, M.G. Madziyire, Hepatic rupture from haematomas in patients with pre-eclampsia/eclampsia: a case series, *Pan Afr. Med. J.* 31 (2018) 86, Published 2018 Oct 4 [10.11604/pamj.2018.31.86.15975](https://doi.org/10.11604/pamj.2018.31.86.15975).
- [7] Moore, et al., *Organ injury scaline: spleen and liver (1994 revision)*, *J. Trauma* 38 (3) (1995) 323–324 March.
- [8] G. Tinkoff, T.J. Esposito, J. Reed, P. Kilgo, J. Fildes, M. Pasquale, J.W. Meredith, American Association for the surgery of trauma organ injury scale I: spleen, liver, and kidney, validation based on the national trauma data bank, *J. Am. Coll. Surg.* 207 (5) (2008) 646.
- [9] M. Kapan, M.S. Evsen, M. Gumus, A. Onder, G. Tekbas, Subcapsular liver hematoma in HELLP syndrome: case report, *Gastroenterol. Res.* 3 (3) (2010) 144–146, <https://doi.org/10.4021/gr2010.04.178e>.
- [10] M.T.C. Lam, E. Dierking, Intensive care unit issues in eclampsia and HELLP syndrome, *Int. J. Crit. Illn. Inj. Sci.* 7 (3) (2017) 136–141, https://doi.org/10.4103/IJCIS.IJCIS_33_17.
- [11] D. Anyfantakis, M. Kastanakis, G. Fragiadakis, P. Karona, N. Katsougris, E. Bobolakis, Postpartum spontaneous subcapsular hepatic hematoma related to preeclampsia, *Case Rep. Emerg. Med.* 2014 (2014), 417406. <https://doi.org/10.1155/2014/417406>.
- [12] S.G. Wilson, A.D. White, A.L. Young, M.H. Davies, S.G. Pollard, The management of the surgical complications of HELLP syndrome, *Ann. R. Coll. Surg. Engl.* 96 (7) (2014) 512–516, <https://doi.org/10.1308/003588414X13946184901362>.
- [13] V. Brown, J. Martin, D. Magee, A rare case of subcapsular liver haematoma following laparoscopic cholecystectomy, *BMJ Case Rep.* (2015) <https://doi.org/10.1136/bcr-2015-209800> Published 2015 Jun 25.