



Contents lists available at ScienceDirect

North American Spine Society Journal (NASSJ)

journal homepage: www.elsevier.com/locate/xnsj

Clinical Studies

The use of robot-assisted surgery for the unstable traumatic spine: A retrospective cohort study



Luis Daniel Diaz-Aguilar, MD^{a,*}, Nolan J. Brown, BS^b, Nicholas Bui, BS^b, Bejan Alvandi, MD^c, Zach Pennington, MD^d, Julian Gendreau, MD^e, Sunil P. Jeswani, MD^a, Martin H. Pham, MD^a, David R. Santiago-Dieppa, MD^a, Andrew D. Nguyen, MD, PhD^a

^a Department of Neurosurgery, University of California San Diego, La Jolla, CA, 92093 USA

^b Department of Neurosurgery, University of California Irvine, Orange, CA, 92868 USA

^c Department of Orthopaedic Surgery, Northwestern University Feinberg School of Medicine, Chicago, IL, 60611 USA

^d Department of Neurologic Surgery, Mayo Clinic, Rochester, MN, 55905 USA

^e Johns Hopkins Whiting School of Engineering, Baltimore, MD, 21205 USA

ARTICLE INFO

Keywords:

Trauma
Robotics
Imaging
Registration
Radiograph
Spine

ABSTRACT

Background: Robotic assistance has been shown to increase instrumentation placement accuracy in open and minimally invasive spinal fusion. These gains have been achieved without increases in operative times, blood loss, or hospitalization duration. However, most work has been done in the degenerative population and little is known of the utility of robotic assistance when applied to spinal trauma. This is largely due to the uncertainty stemming from the disruption of normal anatomy by the traumatic injury. Since the robot depends upon registration for instrumentation guidance according to the fiducials it uses, trauma can introduce unique challenges. The present study sought to evaluate the safety and efficacy of robotic assistance in a consecutive cohort of spine trauma patients.

Methods: All patients with Thoracolumbar Injury Classification and Severity Scale (TLICS) >4 who underwent robot-assisted spinal fusion using the Globus ExcelsiusGPS at a single tertiary care center for trauma between 2020 and 2022 were identified. Demographic, clinical, and surgical data were collected and analyzed; the primary endpoints were operative time, fluoroscopy time, estimated blood loss, postoperative complications, admission time, and 90-day readmission rate. The paired t-test was used to compare differences between mean values when looking at the number of surgical levels.

Results: Forty-two patients undergoing robot-assisted spinal surgery were included (mean age 61.3±17.1 year; 47% female). Patients were stratified by the number of operative levels, 2 (n = 10), 3-4 (n = 11), 5 to 6 (n = 13), or >6 (n = 8). There appeared to be a positive correlation between number of levels instrumented and odds of postoperative complications, admission duration, fluoroscopy time, and estimated blood loss. There were no instances of screw malposition or breach.

Conclusions: This initial experience suggests robotic assistance can be safely employed in the spine trauma population. Additional experiences in larger patient populations are necessary to delineate those traumatic pathologies most amenable to robotic assistance.

Introduction

Recent advances in robotic surgery have led to the successful application of robotic assistance for screw placement in both minimally

invasive (MIS) and open spine surgery [1–7]. The chief advantages of robotic-assistance are an improvement in placement accuracy relative to freehand and fluoroscopic techniques [3], and reduced radiation exposure relative to fluoroscopic techniques [8]. Furthermore, after the

FDA device/drug status: Approved.

Author disclosures: **LDD-A:** Nothing to disclose. **NJB:** Nothing to disclose. **NB:** Nothing to disclose. **BA:** Nothing to disclose. **ZP:** Nothing to disclose. **JG:** Nothing to disclose. **SPJ:** Nothing to disclose. **MHP:** Nothing to disclose. **DRS-D:** Nothing to disclose. **ADN:** Nothing to disclose.

Previous presentations: This manuscript is original and has not been published/presented.

* Corresponding author. Daniel Diaz-Aguilar, MD, Department of Neurosurgery, University of California, San Diego Medical Center, 9500 Gilman Dr, La Jolla, CA, 92093 USA.

E-mail address: Ddiazag1@gmail.com (L.D. Diaz-Aguilar).

<https://doi.org/10.1016/j.xnsj.2023.100234>

Received 24 March 2023; Received in revised form 29 May 2023; Accepted 29 May 2023

Available online 12 June 2023

2666-5484/© 2023 The Author(s). Published by Elsevier Ltd on behalf of North American Spine Society. This is an open access article under the CC BY-NC-ND license (<http://creativecommons.org/licenses/by-nc-nd/4.0/>)

initial learning curve, placement with robotic assistance is associated with similar operating room time, operative blood loss, and hospital length of stay compared to freehand instrumentation [3,9].

At present, all commercially available systems – ExcelsiusGPS, Mazor X Stealth, and ROSA One – employ fiducial markers to map the position of the robot to the patient within 3-dimensional space [10]. The fidelity of such mapping is contingent on the stability of the positions of the reference frame and levels to be instrumented. While the positions of these points relative to one another remain reasonably constant in most cases of degenerative pathology and spinal deformity, such stability is frequently lost in the context of traumatic injuries to the spinal column. The literature regarding the safety of applying robot-assisted instrumentation to spine trauma is sparse. The objective of the present study was to present our institutional experience applying a single modern generation spinal robot to instrumented fusion of patients with traumatic spine pathologies as a means of highlighting the potential role of spinal robotics in spine trauma.

Regardless of the system used, the success of 3D navigation in robotic spine surgery hinges on maintaining accurate registration [11,12]. Although evidence is continually emerging that registration using robotics platforms is not a mitigating factor across a wide range of minimally invasive and complex open spinal procedures even including deformity correction, there is currently no evidence regarding the utility of robotic assistance in spinal trauma. As such, it is presently not known whether robotic surgery is safe to perform in trauma cases, or whether the planning software involved would prove effective when attempting surgical fixation of spines with the high degree of instability as often seen in trauma. Given the successful application of robotic platforms in spine surgery to date, we sought to evaluate the safety and efficacy of robotic assistance in a consecutive cohort of trauma patients who underwent robotic spinal surgery.

Methods

Patient sample

Following Institutional Review Board approval, a consecutive series of patients who underwent robot-assisted spinal instrumented fusion

for traumatic spinal injury at a single institution were retrospectively reviewed. All surgeries were performed by 1 of 3 surgeons using the ExcelsiusGPS (Globus) at an academic center between 2020 and 2022. Figs. 1–5 illustrate an example case from this series.

Outcomes and statistical analysis

Data were collected on patient demographics (age, sex, body mass index [BMI]), medical comorbidities, injury morphology (including thoracolumbar injury classification and severity score [TLICS]), operative details (eg, instrumented levels, estimated blood loss (EBL), fluoroscopy time), and perioperative complications (durotomy, pseudoarthrosis, wound infection, readmission, surgical revision). One-way ANOVA followed by post-hoc Tukey's test was used to assess for significant differences between mean values when stratifying based on the number of surgical levels. When possible, categorical comparisons were performed using Chi-squared testing. Statistical significance was defined as $p < 0.05$.

Results

Forty-two patients were identified with mean age 61.2 ± 17.1 year, of whom 20 (47%) were female (Table 1). Mean BMI was 27.5 ± 7.7 kg/m², 12% were active smokers, 17% had type 2 diabetes mellitus, and 4.8% had a known history of osteoporosis. By morphology, the most common fracture types were burst (28 patients, 66%), translation (5 patients, 12%), distraction (9 patients, 42%). Distribution of injuries along the craniocaudal axis showed 4 thoracic spine fractures (9.5%), 22 thoracolumbar (52.3%), 18 lumbar (42.8%), and 6 lumbosacral (14.2%). Comparing complications between groups showed postoperative complications were highest for patients undergoing 5 to 6 and >6 level instrumented fusion, notably higher rates of postoperative radiculopathy (45% and 52.5%) and longer hospitalizations (23 days and 21 days), respectively, as compared to (Table 2). Mean fluoroscopy time (137 ± 95.2 minutes) and EBL (317.5 ± 213.1) were highest in the >6 level group. The mean operative durations for the 2 level (198 ± 28.8 minutes) and 5 to 6 level (196.3 ± 97.8 minutes) groups were similar ($p = .96$), as were the mean operative durations for the 3 to 4 level (306.2 ± 98.7 minutes)

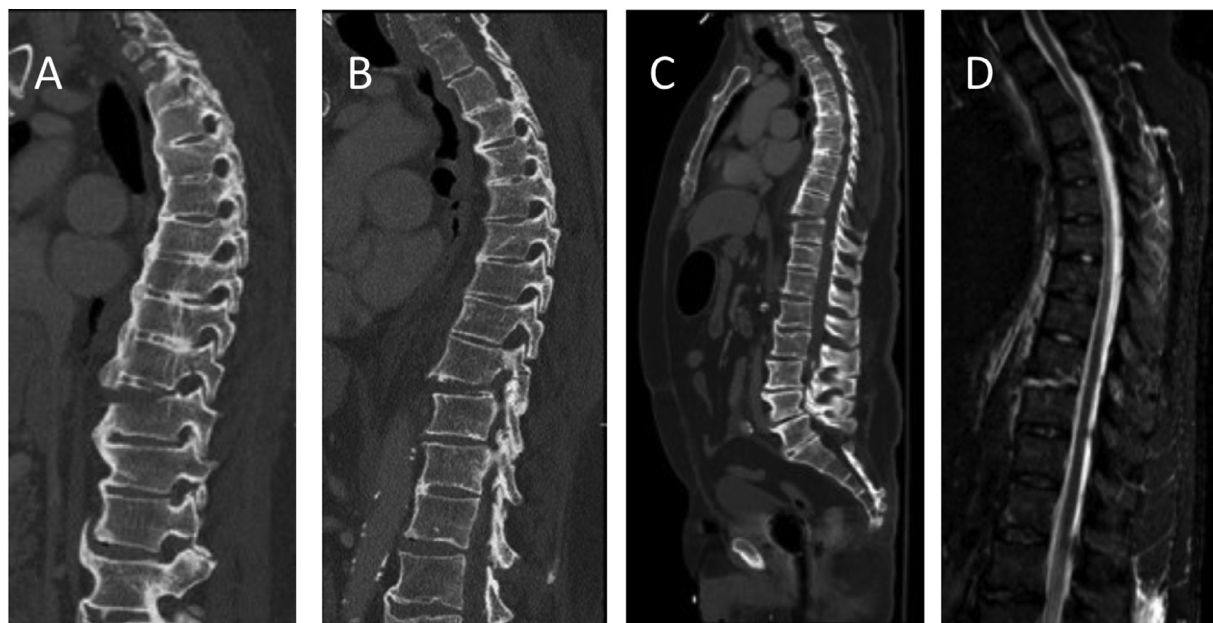


Fig. 1. Case illustration: 79-year-old male with history of ankylosing spondylitis was found to have sustained T9-T10 Chance fracture requiring percutaneous long-segment posterior pedicle screw fixation from T7-L1. Preoperative CT study: Sagittal plane (A–C) reveals Chance fracture at T9 to T10 with distraction through the superior end plate of T10 with horizontal fracture extending into the T9 to T10 disc space and involving the bilateral posterior elements at T9. Also evident was anterior distraction measuring 8 mm with Grade 1 anterolisthesis at T9 to T10. Preoperative sagittal T2-weighted MRI (D) showing presence of ruptured anterior longitudinal ligament with no significant bony central canal narrowing.

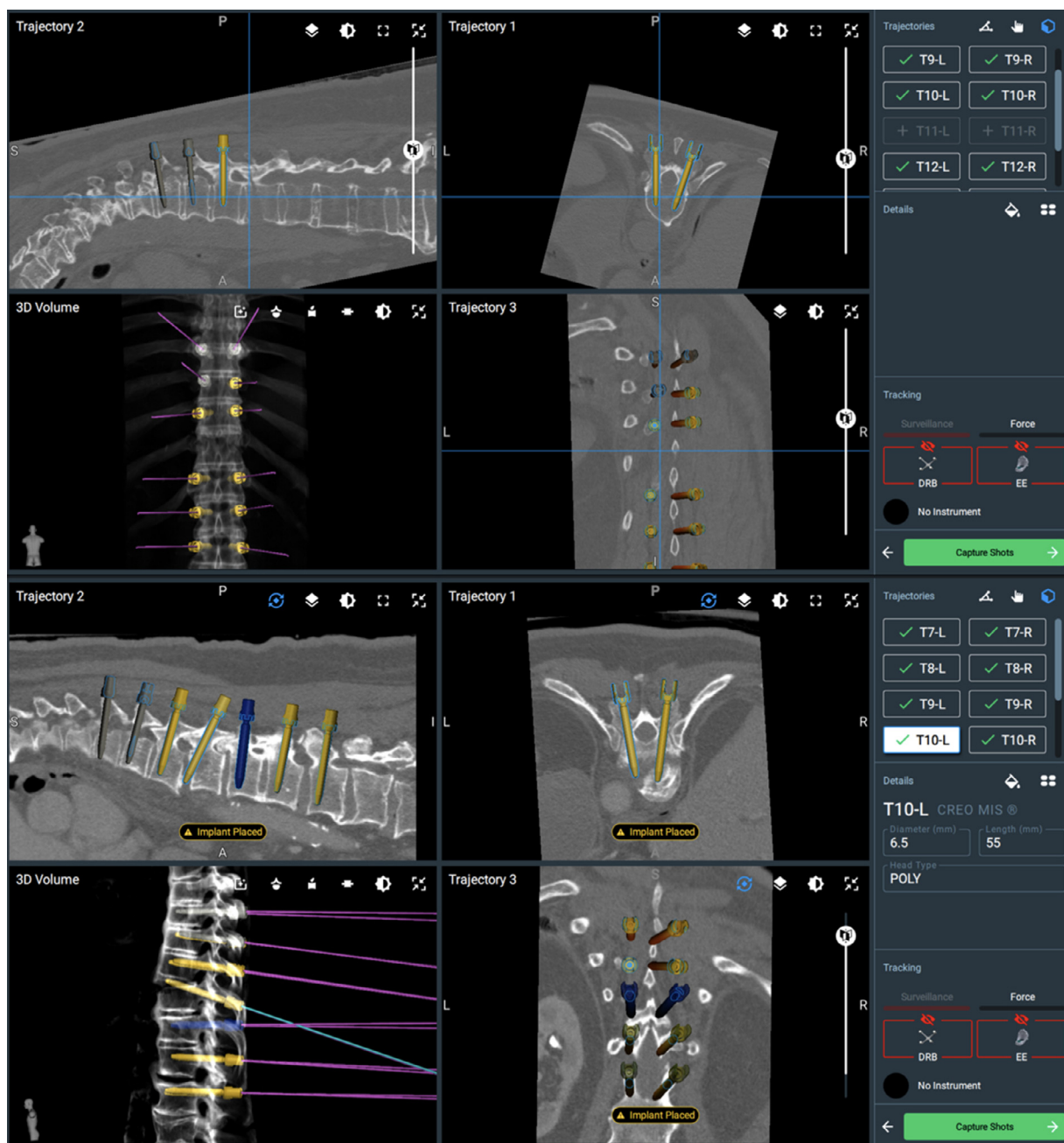


Fig. 2. Demonstration of the Globus ExcelsiusGPS robotic planning and intraoperative guidance system used to perform posterior pedicle screw placement from T7 to L1 for fixation and stabilization of T9 to 10 chance fracture. Shown here is the planning and successful placement of 6.5 mm diameter pedicle screw at T10.

and >6 level (276.8 ± 147.1 minutes) groups ($p=.607$). The longest procedures occurred in the 3 to 4 level (306.2 minutes) and >6 level (276.8) level groups. Three to four level procedures were significantly longer than those involving only 2 levels ($p<.05$), and >6 level surgeries took significantly longer than 5 to 6 level surgeries ($p<.05$). Interestingly, operative durations for 5 to 6 level surgeries were much longer than operative durations for surgeries involving 3 to 4 levels ($p<.05$). There were no instances of pedicle screw breach and thus no subjects required screw replacement or revision surgery. With respect to perioperative complications (Table 3), there were none resulting from surgeries involving < 5 levels. For 5+ level surgeries, the complication rate was 6/21 (29%). Among these complications, none involved wound or surgical site infection and there was only 1 case of durotomy resulting in cerebrospinal fluid (CSF) leak. There were no severe complications or deaths.

Discussion

Since the FDA approval of the first spine robot in 2004, multiple studies have suggested robotic-assistance improves instrumentation placement accuracy relative to conventional freehand placement [13]. Nearly all publications have examined spinal robotics in the context of degenerative disease due to its relatively high prevalence. However, examination of the application of spinal robots to spinal trauma have been limited. One of the outstanding questions in the spine trauma population is whether robotics can be applied safely given that all modern robotic systems require the positions of the reference frame and instrumented segment to remain stable. In the current study, we present our preliminary experience employing a next-generation robotic system (ExcelsiusGPS) for the management of unstable thoracolumbar fractures undergoing treatment with instrumented fusion. Ultimately,

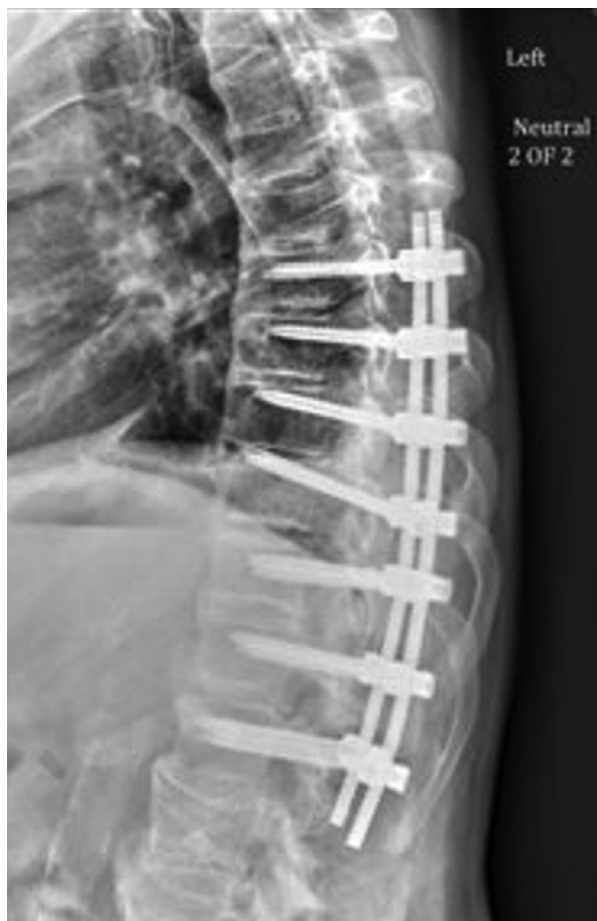

Fig. 3. Postoperative lateral view radiograph illustrating hardware at T7 to L1.

Table 1
Demographics of Patients Included in the Present Series

	Incidence (N = 42)	SD
Age (mean)	61.3	17.1
Female	20 (47%)	7.6
BMI (mean; kg/m ²)	27.7	
Smoking	5 (11.9%)	
Diabetes	4 (9.5%)	
Osteoporosis	1 (2.3%)	
Fracture Morphology	28 (66%)	
Burst	5 (12%)	
Translation	9 (42%)	
Distraction	ion	
Region of instrumentation	4 (9.5%)	
Thoracic	22 (52.3%)	
Thoracolumbar	18 (42.8%)	
Lumbar	6 (14.2%)	
Lumbo-sacral	3	
Previous spine surgery	(7.1%)	

Table 2
Operative data

	2 level (N = 10; SD or %)	3–4 levels (N = 11; SD or %)	5–6 levels (N = 13; SD or %)	>6 levels (N = 8; SD or %)	p
Operative time (min)	198.0 (28.8)	306.2 (98.7)	196.3 (97.8)	276.8 (147.1)	<.05
Screws	10 (100%)	9 (80%)	10 (83.3%)	6 (87.5%)	Reference
Percutaneous	0 (0%)	2 (20%)	3 (17.3%)	6 (87.5%)	.930
Open	0 (0%)	0 (0%)	0 (0%)	2 (12.5%)	-
Pedicle Screw Breach	0 (0%)	0 (0%)	0 (0%)	0 (0%)	-
Screw Replacement	106.8 (±30.0)	77.2 (38.1)	55.3 (19.3)	0 (0%)	<.05
Fluoroscopy time (min)	100	217.5	307.5	139.8 (97.1)	<.05
Estimated Blood Loss (cc)	(±0)	(203.0)	(365.7)	337.5 (203.1)	

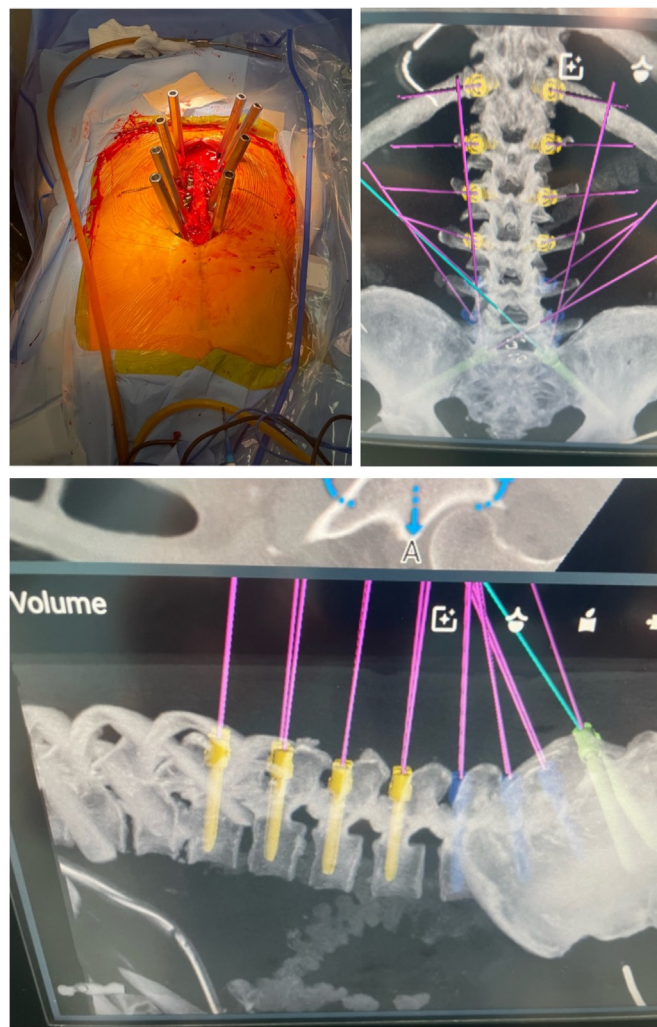


Fig. 4. Intraoperative robotics planning of pedicle screw placement and use of multiple rod construct for instrumentation and stabilization of the spinal column in a patient with traumatic spinal fracture.

we found that robot-assisted surgery in a cohort of 42 patients was effective and safe for surgeries involving less than 3 to 4 levels, but that complications began to arise when surgical levels were >5. Several studies have previously compared the accuracy of instrumentation placed with robotic assistance as compared to freehand or fluoroscopic techniques. There have been several meta-analyses of these studies, including the work just recently published by Matur et al. [14].

Open fixation of thoracolumbar fractures – generally performed with posterior segmental instrumentation placed 2 to 3 levels above and below the fracture level – can be associated with significant morbidity [15]. Percutaneous fixation – an MIS technique with minimal soft tis-

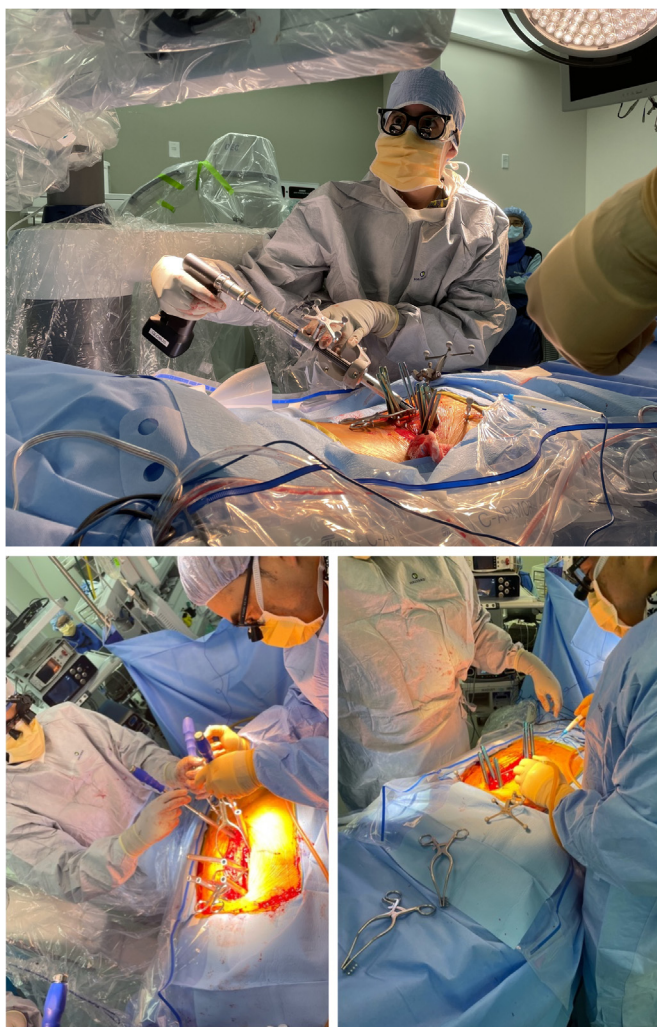


Fig. 5. Intraoperative workflow of pedicle screw placement and use of multiple rod construct for instrumentation and stabilization of the spinal column in a patient with traumatic spinal fracture.

sue dissection – is an increasingly popular approach [16]. Grossbach et al. [17] reported their experience treating 39 patients thoracolumbar flexion-distraction injuries over 10 years at an academic center. Those treated with percutaneous fixation had significantly less intraoperative blood loss and nonsignificantly shorter operative times as compared to patients treated with open approaches. They also endorsed the former as having less associated tissue damage. Others have endorsed similar benefits with percutaneous fixation [16,18].

MIS approaches seem ideally suited to robotic assistance; the percutaneous approach hides normal anatomic landmarks used to facilitate freehand instrumentation, and fluoroscopy-guided instrumentation is associated with significant radiation burden to the practicing surgeon [8,19]. The major concern associated with robotic instrumentation in the context of trauma is the loss of stability between the reference frame and segment undergoing instrumentation. Here in our initial experience, we demonstrate robot-assisted instrumentation to be a safe approach to the management of unstable thoracolumbar fractures. With respect to the concern over loss of registration, there were no instances of robotic misregistration in the present experience. Additional investigation in expanded cohorts is merited, but the present study serves as a proof-of-concept that this approach is a safe option.

This study recognizes the need for high-quality, relevant data for the application of robotics in traumatic spine surgery. The primary aim of the present study was to examine the efficacy and safety of robot-assisted spine surgery in the trauma population. In addition, out of all patients undergoing surgery following spinal trauma in our study, only one was readmitted within 90 days. No screws required replacement and no medial/lateral breeches were encountered in any cases.

Study limitations

This study has several limitations. The first is that it is a single-armed retrospective cohort. There is no control group that underwent instrumentation without robotic assistance to elaborate on the safety and efficacy of robotic-assistance in this trauma population. Nevertheless, we saw no perioperative complications attributable to the spinal robot, which would suggest this approach is safe, at least based upon this preliminary study. The small cohort size also precludes us from establishing whether there are specific fracture morphologies for which instability is so significant that the navigation frame tracking fidelity may be too poor to allow for robot-assisted instrumentation. Without controls, it is also impossible to determine if surgical preoperative planning times significantly differed from that of a control group. Previous studies have observed that robot-assisted surgeries require more lengthy preoperative planning which would not be conducive to emergent surgical stabilization [13,19,20]. However, with increasing case experience, there is noted to be significant reductions in operative times [9], so the feasibility of applying this technology to the trauma population may be dependent upon the relative familiarity of the operating team with robotic surgery. This present study is also limited by its retrospective nature; retrospective studies are well-known to be susceptible to inherent limitations such as selection and reporting bias. Finally, this study only explored outcomes up to 90-day follow-up. Longer-term outcomes for these patients will be important to investigate in the near future, and we encourage others to report any relevant data that may be pertinent to the topic of robot-assisted surgery in spinal trauma patients undergoing instrumented fusion for traumatic fractures.

Table 3 Postoperative data

	2 level (N = 10; SD or %)	3–4 levels (N = 11; SD or %)	5–6 levels (N = 13; SD or %)	>6 levels (N = 8; SD or %)	p
CSF leak	0 (0%)	0 (0%)	1 (7.6%)	0 (0%)	-
Pseudoarthrosis	0 (0%)	0 (0%)	0 (0%)	0 (0%)	-
Postop complications	0 (0%)	0 (0%)	0 (0%)	0 (0%)	-
Wound Infection	0 (0%)	0 (0%)	0 (0%)	2 (25%)	-
A. fibrillation	0 (0%)	0 (0%)	1 (7.6%)	1 (12.5%)	-
DVT	0 (0%)	0 (0%)	0 (0%)	1 (12.5%)	-
Pneumonia	4 (3.9)	7.8 (5.2)	23 (35.9)	13.4 (4.7)	>.05
Admission time (days)	0 (0%)	0 (0%)	1 (7.6%)	0 (0%)	-
90-d readmission Revision surgery	0 (0%)	0 (0%)	0 (0%)	0 (0%)	-

Conclusion

The present study provides preliminary data suggesting that robotic assistance can be safely employed for patients with traumatic fractures undergoing instrumented fusion. Forty-two patients with traumatic fractures were successfully treated with robot-assisted instrumented fusion; the results found instrumentation placement to be consistent and reproducible. Larger studies will be needed to confirm the results obtained in our study, and future investigations should determine whether there are specific fracture morphologies not amenable to robot-assisted instrumentation.

Declarations of Competing Interest

The authors declare that they have no known competing financial interests or personal relationships that could have appeared to influence the work reported in this paper.

Acknowledgments

There are also no disclosures of funding for this study. Institutional Review Board (IRB) approval was obtained prior to analysis.

References

- [1] Diaz-Aguilar LD, Shah V, Himstead A, Brown NJ, Abraham ME, Pham MH. Simultaneous robotic single-position surgery (SR-SPS) with oblique lumbar interbody fusion: a case series. *World Neurosurg* 2021;151:e1036–43.
- [2] Shahrestani S, Brown NJ, Acharya N, Diaz-Aguilar LD, Pham MH, Taylor WR. A case report of robotic-guided prone transpoas lumbar fusion in a patient with lumbar pseudarthrosis, adjacent segment disease, and degenerative scoliosis. *Int J Surg Case Rep* 2022;94:106999.
- [3] Himstead AS, Shahrestani S, Brown NJ, et al. Bony fixation in the era of spinal robotics: a systematic review and meta-analysis. *J Clin Neurosci* 2022;97:62–74.
- [4] Staub BN, Sadrameli SS. The use of robotics in minimally invasive spine surgery. *J Spine Surg* 2019;5(Suppl 1):S31–40.
- [5] Pham MH, Shah VJ, Diaz-Aguilar LD, Osorio JA, Lehman RA. Minimally invasive multiple-rod constructs with robotics planning in adult spinal deformity surgery: a case series. *Eur Spine J* 2022;31(1):95–103.
- [6] Vo CD, Jiang B, Azad TD, Crawford NR, Bydon A, Theodore N. Robotic spine surgery: current state in minimally invasive surgery. *Global Spine J* 2020;10(2 Suppl) 34S–40S.
- [7] Joseph JR, Smith BW, Liu X, Park P. Current applications of robotics in spine surgery: a systematic review of the literature. *Neurosurg Focus* 2017;42(5):E2.
- [8] Pennington Z, Cottrill E, Westbroek EM, et al. Evaluation of surgeon and patient radiation exposure by imaging technology in patients undergoing thoracolumbar fusion: systematic review of the literature. *Spine J* 2019;19(8):1397–411.
- [9] Jiang B, Pennington Z, Azad T, et al. Robot-assisted versus freehand instrumentation in short-segment lumbar fusion: experience with real-time image-guided spinal robot. *World Neurosurgery* 2020;136:635–45.
- [10] Huang M, Tetreault TA, Vaishnav A, York PJ, Staub BN. The current state of navigation in robotic spine surgery. *Ann Transl Med* 2021;9(1):86.
- [11] Crawford N, Johnson N, Theodore N. Ensuring navigation integrity using robotics in spine surgery. *J Robot Surg* 2020;14(1):177–83.
- [12] Rahmathulla G, Nottmeier EW, Pirris SM, Deen HG, Pichelmann MA. Intraoperative image-guided spinal navigation: technical pitfalls and their avoidance. *Neurosurg Focus* 2014;36(3):E3.
- [13] D'Souza M, Gendreau J, Feng A, Kim LH, Ho AL, Veeravagu A. Robotic-assisted spine surgery: history, efficacy, cost, and future trends. *Robot Surg* 2019;6:9–23.
- [14] Matur AV, Palmisciano P, Duah HO, et al. Robotic and navigated pedicle screws are safer and more accurate than fluoroscopic freehand screws: a systematic review and meta-analysis. *Spine J* 2023;23(2):197–208.
- [15] Shahrestani S, Ballatori AM, Chen XT, Ton A, Buser Z, Wang JC. Identifying risks factors in thoracolumbar anterior fusion surgery through predictive analytics in a nationally representative inpatient sample. *Eur Spine J* 2022;31(3):669–77.
- [16] Wang H, Zhou Y, Li C, et al. Comparison of open versus percutaneous pedicle screw fixation using the sextant system in the treatment of traumatic thoracolumbar fractures. *Clin Spine Surg* 2017;30(3):239–46.
- [17] Grossbach AJ, Dahdaleh NS, Abel TJ, Woods GD, Dlouhy BJ, Hitchon PW. Flexion-distraction injuries of the thoracolumbar spine: open fusion versus percutaneous pedicle screw fixation. *Neurosurg Focus* 2013;35(2):E2.
- [18] Denis F, Armstrong GW, Searls K, Matta L. Acute thoracolumbar burst fractures in the absence of neurologic deficit. A comparison between operative and nonoperative treatment. *Clin Orthop Relat Res* 1984(189):142–9.
- [19] Liounakos JI, Khan A, Eliahu K, et al. Ninety-day complication, revision, and readmission rates for current-generation robot-assisted thoracolumbar spinal fusion surgery: results of a multicenter case series. *J Neurosurg Spine* 2021;36(5):1–8.
- [20] Urakov TM, Chang KHK, Burks SS, et al. Initial academic experience and learning curve with robotic spine instrumentation. *Neurosurg Focus* 2017;42(5):E4.